wjpmr, 2022,8(5), 75-78

SJIF Impact Factor: 5.922

WORLD JOURNAL OF PHARMACEUTICAL AND MEDICAL RESEARCH

www.wjpmr.com

Case Report

ISSN 2455-3301

WJPMR

PANCREATIC SARCOIDOSIS: A CASE REPORT

***M. Figuigui, J. Hammani, A. Lamine, M. Lahlali, H. Abid, N. Lahmidani, M. EL Yousfi, M.EL Abkari, A. Ibrahimi and D. Benajah**

Hepato-Gastroenterology Service, Hassan II University Hospital Center Faculty of Medicine and Pharmacy of Fez – Sidi Mohammed Ben Abdellah University of Fez, Morocco.

***Corresponding Author: M. Figuigui**
Hepato-Gastroenterology Service, Hassan II University Hospital Center Faculty of Medicine and Pharmacy of Fez – Sidi Mohammed Ben Abdellah University of Fez, Morocco.

Article Received on 16/03/2022 **Article Revised on 06/04/2022** **Article Accepted on 26/04/2022**

SUMMARY

Sarcoidosis is a multisystemic inflammatory disease of indeterminate etiology characterized in histology by the presence of non-caseating granulomas. The mediastino-pulmonary localization is the most frequently found, the other extra-thoracic locations including digestive are rarely encountered. Through an observation we present a very rare extra-pulmonary manifestation of sarcoidosis that of pancreatic sarcoidosis This is a young 47-year-old female patient with a history of antibacillary treatment for microscopic tuberculosis (TB) in 1986, who presented to the emergency department in an angiocholitis panel and whose imaging had suspected sarcoidosis due to double mediastino-pulmonary and pancreatic localization The diagnosis was retained histologically by the revelation of an epithelioid and gigantocellular granuloma without caseous necrosis Treatment is based essentially on systemic corticosteroid therapy 0.5 mg per kg per day with good clinical progress. Pancreatic involvement during sarcoidosis is very rare, and usually with favorable prognosis on corticosteroid treatment.

KEYWORDS: Noncaseating Granuloma, Pancreatic Sarcoidosis, Sarcoidosis.

INTRODUCTION

Sarcoidosis is a systemic granulomatosis of unknown etiology. Several organs can be affected at a time. The digestive localization, especially the pancreas, is rare.[1,2] The diagnosis is not always easy, in the absence of sarcoidosis previously known. We report an observation of pancreatic sarcoidosis by detailing its clinical and paraclinical presentation.

OBSERVATION

We report the case of the patient Mrs G .H aged 47, with a history of antibacillary treatment for a microscopy positive tuberculosis in 1986, and a chronic dry cough with dyspnea never explored, admitted in February 2012 to emergencies in a table of angiocholitis, the examination reveals a mucocutaneous jaundice with pruritus and alteration of the general condition in a febrile patient, dyspneic with epigastric and right hypochondriumsensitivity.

An emergency abdominal ultrasound and a scan revealed: pancreatic head tumor with dilation ofthe intrahepatic bile ducts and the main bile duct (fig1-fig2).

The diagnosis of tumor of the pancreatic head locally advanced with mediastino pulmonary secondary locations was retained, decision to install a biliary prosthesis.

Endoscopic retrograde cholangiopancreatography (ERCP)
Short stenosis at the middle portion of the main bile duct. Placement of a plastic biliary prosthesis measuring 8cm/10Fr

The patient came out of emergencies after drainage, but lost sight of since! She returns in consultation 4 years after either in 2016, in perfect general state, WHO to 0, anicterical without any complaints, decision to redo all the radiological assessment given the diagnostic doubt. (fig3-fig4)

In view of the scannographic stability of the lesions and the good clinical evolution, the diagnosis of pancreatic tumor with pulmonary metastases was ruled out, a systemic disease and especially a sarcoidosis with a double mediastino-pulmonary and pancreatic localization was strongly suspected.

Bronchial fibroscopy
Carina: thickened with presence of nodules on both sides at the entrance of the 2 bronchial strains.

Right bronchial tree: very inflammatory aspect with presence of multiple submucosal vessels, the spurs are thickened and the orifices free.

Long bronchial tree: presence of 2 granules at the entrance of the left bronchus

BAL: neutrophilic

Staged bronchial biopsy: epithelioid and gigantocellular granuloma without caseous necrosis It is therefore a pancreatic and mediastino-pulmonary sarcoidosis.

Patient undergoing corticotherapy at the dose of 0.5 mg per kg per day with very good evolution.

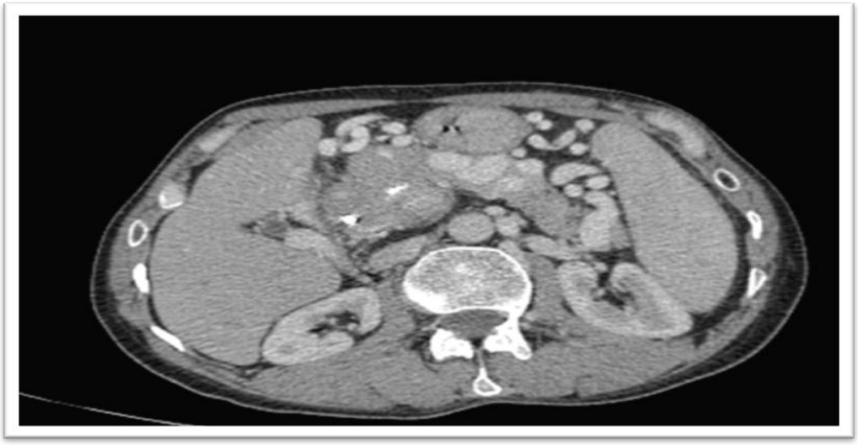

Fig. 1: Tumoral mass of the pancreatic bilio junction partially calcified invading portal vascular structures, upper mesenteric, common bile duct and pancreas head. On the thoracic floor.

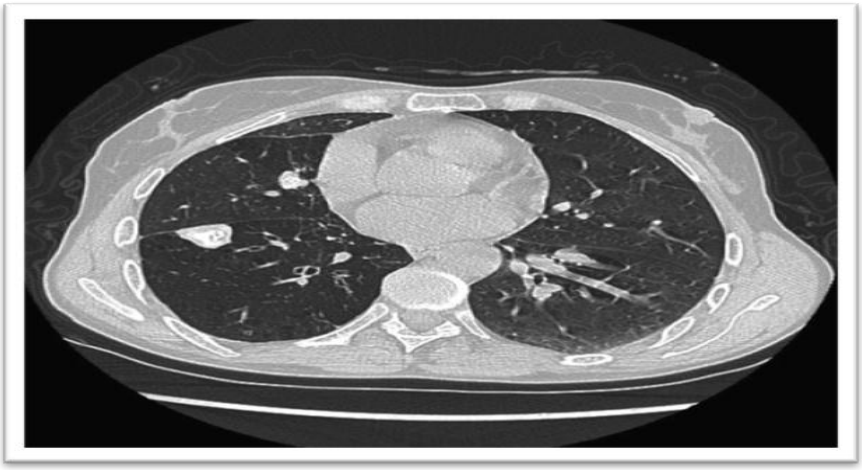

Fig. 2: Multiple suspicious pulmonary macro-nodules and mediastinal lymphadenopathy.

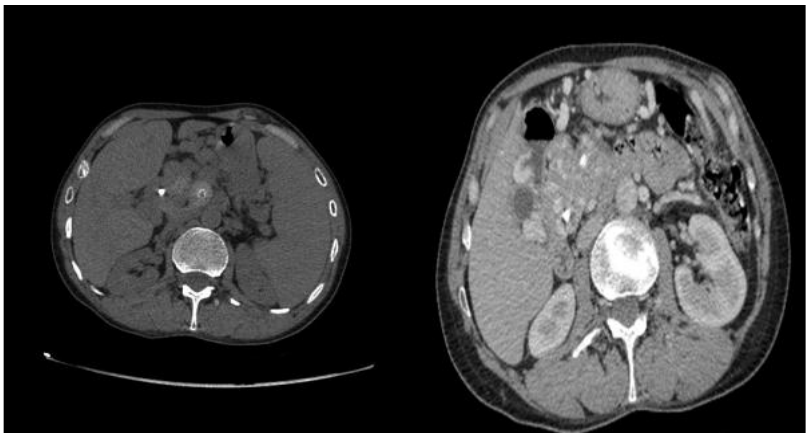

Fig. 3: CT scan in the month 06-2016: substantially stable appearance of the mass of the hepatic hile and the bilio-pancreatic crossroads.

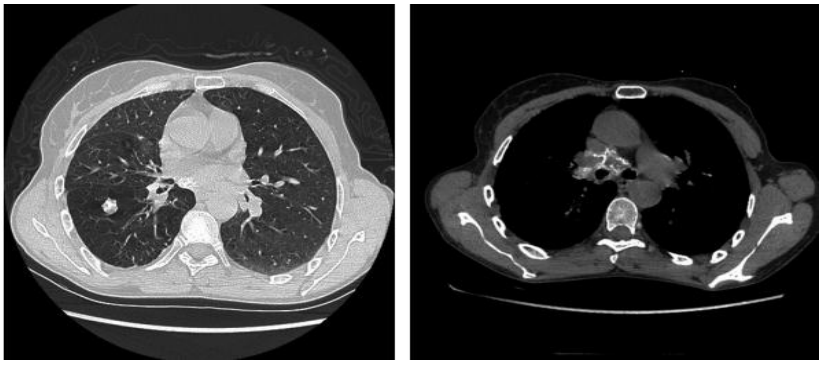

Fig. 4: Stable appearance of the right intra-parenchymal pulmonary nodules having kept the same size, the majority of which includes calcifications. Persistence of tracheal preoperative tracheal lymphadenopathy and right and left hilar caries.

DISSCUSSION

Sarcoidosis is a systemic disorder of unknown origin characterized by the formation of granulomas without caseous necrosis.[3] Genetic factors appear to play a role in the pathogenesis of the disease, as it is likely that genetically predisposed hosts are exposed to antigens that trigger an exaggerated cellular immune response and granuloma formation.[4,5,6] It affects people of all races and all ages and both sexes. It has a particular propensity for adults under 40 and for certain racial and ethnic groups, being more prevalent among blacks.[4] The clinical manifestations of sarcoidosis can be generalized or involve only one organic system. The majority of patients experience systemic symptoms such as fatigue, anorexia, weight loss and fever. In 20-50% of patients with acute events, Lofgren's syndrome (nodular erythema, bilateral hilar lymphadenopathy and polyarthralgia) was noted. Respiratory tract involvement is present in the majority of patients with sarcoidosis, with radiographic evidence of hilar ganglion enlargement in up to 90% of patients.[4,5] Other organs and / or systems may be involved: the heart, the skin, the eyes, the nervous system, the nasal tract, the kidneys and the endocrine system.

The gastrointestinal manifestations of sarcoidosis are rare.
Gastrointestinal manifestations are usually secondary to organ infiltration or compression by enlarged lymph nodes. The liver is the most commonly affected organ followed by the stomach.[7,8] Nickerson first reported sarcoidosis of the pancreas in 1937. Following autopsy, he observed pancreatic involvement with granulomas without caseous necrosis.[9,10] Patients may have acute pancreatitis, chronic pancreatitis or nonspecific abdominal pain resulting from involvement of the organ affected by granulomatous disease. The clinical presentation may be similar to that of pancreatic adenocarcinoma.[11,12]

Pancreatic sarcoidosis may occasionally be encountered in the evaluation of other abdominal conditions.

The disease most often presents as a mass of the pancreatic head and its symptoms most often include abdominal pain (50%), weight loss (44%) and obstructive jaundice (44%). Retroperitoneal or peripancreatic lymph nodes are present in two-thirds of these patients.[13,14] A granulomatous mass may be difficult to differentiate from a cancerous mass both radiologically and during a laparotomy.[9,11,15,16] Chronic pancreatitis without obstructive pancreatic mass has been reported twice and was caused by granulomatous replacement of the pancreatic gland CT results are not specific for pancreatic sarcoidosis. Poorly defined pancreatic head mass, narrowing and dilation of the main bile duct with or without dilation of the pancreatic duct, and increased lymph node volume are the most common results of computed tomography reported in the literature.[15,17,18,19,20]

Our patient had on her initial CT scan an image of a tumor mass of the pancreatic bilio junction partially calcified invading the portal vascular structures, the superior mesenteric, the common bile duct and the pancreas head. The diagnosis was retained thanks to a bronchial fibroscopy that was performed due to the presence of mediastinal-pulmonary lesions on imaging, and showing a thickened carina with presence of nodules on both sides and 2 granulations at the entry of the left bronchus. The staged bronchial biopsies were made thus showing an epithelioid and gigantocellular granuloma without caseous necrosis.

We have had good results after corticotherapy at the dose of 0.5 mg per kg per day, and our patient is currently under surveillance in perfect condition.

CONCLUSION

Pancreatic sarcoidosis must be taken into account in the differential diagnosis of multiple pancreatic masses in imaging.

REFERENCES

1. Mayock RL, Bertrand P, Morrison CE, Scott JH. Manifestations of sarcoidosis. Analysis of 145

patients, with a review of nine series selected from the literature. Am J Med, 1963; 35: 67–89.
2. Palmer ED. Note on silent sarcoidosis of the gastric mucosa. J Lab Clin Med, 1958; 52: 231– 4.
3. Sagalow BR, Miller CL, Wechsler RJ. Pancreatic sarcoidosis mimicking pancreatic cancer. J Clin Ultrasound, 1988; 16(2): 131–134. [PubMed]
4. Iannuzzi MC, RybickiBA, TeirsteinCOMME. Sarcoïdose, N Eng J Med, 2007; 357: (pg. 2153-65).
5. Homme nouveau LS, Rose CS, MaierLA. Sarcoïdose, N Engl J Med, 1997; 336: (pg. 1224-34).
6. Martinetti M, Luisetti M, Cuccia M. HLA et sarcoïdose: nouvelles perspectives pathogénétiques, Sarcoïdose Vasc Diffuse Poumon Dis, 2002; 19: (pg. 83-95).
7. Harder H, Büchler MW, Fröhlich B, Ströbel P, Bergmann F, Neff W, et al. Extrapulmonarysarcoidosis of liver and pancreas: a case report and review of literature. World journal of gastroenterology: World J Gastroenterol, 2007; 13: 2504-9. [PMID: 17552036]
8. Owen N, Sohaib S, Peppercorn P, Monson J, Grossman A, Besser G, Reznek RH. MRI of pancreatic neuroendocrine tumours. Br J Radiol, 2001; 74: 968-73. [PMID: 11675319]
9. Shukla M, Hassan MF, Toor V, Kaur J, Solomon C, Cohen H. Symptomatic pancreatic sarcoidosis. Case report and review of literature. JOP 2007; 8:770-4. [PMID: 17993729]
10. Nickerson D. Boeck'sSarcoid: Report of Six Cases in which Autopsies Were Done. Arch Path, 1937; 24: 19.
11. Gezer NS, Başara I, Altay C, Harman M, Rocher L, Karabulut N, Seçil M. Abdominal sarcoidosis: cross-sectional imaging findings. DiagnInterv Radiol, 2015; 21: 111-7. [PMID: 25512071]
12. Tu C, Lin Q, Zhu J, Shao C, Zhang K, Jiang C, Ding Z, et al. Isolated sarcoidosis of accessory spleen in the greater omentum: A case report. ExpTher Med, 2016; 11: 2379- 2384. [PMID: 27284324]
13. Caceres M, Sabbaghian MS, Braud R, Wilks S, Boyle M. Pancreatic sarcoidosis: unusual presentation resembling a periampullary malignancy. Curr Surg, 2006; 63: 179-85. [PMID: 16757369]
14. Ryrie D. Sarcoidosis with obstructive jaundice. Proc R Soc Med, 1954; 47: 879. [PMID: 13215528]
15. Bacal D, HoshalJr VL, Schaldenbrand JD, Lampman RM. Sarcoidosis of the pancreas: case report and review of the literature. Am Surg, 2000; 66: 675-8. [PMID: 10917480]
16. Thermann P, Dollinger MM. Extrapulmonarysarcoidosis: gastrointestinal involvement - case report and review of literature. Z Gastroenterol, 2016; 54: 238-44. [PMID: 27043887]
17. Ohana G, Melki Y, Rosenblat Y, Kravarusic D, Weil R. Pancreatic sarcoidosis mimicking a malignant tumour. Eur J Surg, 2002; 168: 513-5. [PMID: 12549696]
18. Mayne AIW, Ahmad J, Loughrey M, Taylor MA. Sarcoidosis of the pancreas mimicking adenocarcinoma. BMJ Case Rep, 2013; 2013: bcr2013009118. [PMID: 23784760]
19. Soyer P, Gottlieb L, Bluemke DA, Fishman E. Sarcoidosis of the pancreas mimicking pancreatic cancer: CT features. Eur J Radiol, 1994; 19: 32-3. [PMID: 7859757]
20. Baroni RH, Pedrosa I, Tavernaraki E, Goldsmith J, Rofsky NM. Pancreatic sarcoidosis: MRI features. J Magn Reson Imaging, 2004; 20: 889-893. [PMID: 15503350]