

INDUCED BRONCHOSPASM BY CRIZOTINIB: SEVERE BUT EDIBLE, RARE SIDE EFFECTS***S. Baldé, S. Bouteyeb, C. Elm'hadi, ML Sow, B. El Ghissassi, H. M'rabti and H. Errihani**

Department of Medical Oncology, National Institute of Oncology-Rabat.

***Corresponding Author: S. Baldé**

Department of Medical Oncology, National Institute of Oncology-Rabat.

Article Received on 22/01/2022

Article Revised on 12/02/2022

Article Accepted on 02/03/2022

ABSTRACT

Introduction: Crizotinib is a multi-target tyrosine kinase inhibitor against ALK, HGFR.CM and ROS1. IT is a new therapeutic standard for chest oncology prescribed. In non-small cell lung cancer with ALK-EML rearrangement its use is not devoted to side effects some of which are little described and under a special management. We report the case of a patient with Bronchospasm induced by this molecule as well as the modalities of management. **Clinic Case:** It is about 53 years old patient treated with anticoagulant for pulmonary embolism followed since 2013 for metastatic bronchial adenocarcinoma with bone with mutated EGFR having received Paclitaxel-carboplatin-bevacizumab induction chemotherapy with excellent tolerance. A clinical and radiological progression retained in front of the appearance of pulmonary and pleural metastatic motivated the realization of a new biopsy in search of a mutation of resistance. Molecule screening showed the presence of C-MET amplification and the patient was placed under crizotinib after two months of care. The patient has presented exacerbation of symptomatology respiratory one without majoration of radiological lesions and dyspnea stage III has amended under B2 mimetic and corticotherapy and stop crizotinib. **Conclusion:** Bronchospasm under crizotinib although little reported (2-4%) of the cases can be life threatening. The management is rather based on prevention by B2 mimetic and corticosteroid therapy.

INTRODUCTION

Crizotinib is a multi-target tyrosine kinase inhibitor against ALK, HGFR.CM and ROS 1. IT is a new therapeutic standard for chest oncology prescribed. In non-small cell lung cancer with ALK-EML rearrangement its use is not devoted to side effects some of which are little described and under a special management.

We report the case of a patient with Bronchospasm induced by this molecule as well as the modalities of management.

CASE CLINIQUE

This is a 53-year-old patient treated with anticoagulants for pulmonary embolism, followed since 2013 for bone metastatic bronchial adenocarcinoma with mutated EGFR induction chemotherapy with Paclitaxel-carboplatin-bevacizumab for 4 Cycles, then a maintenance switch by Erlotinib and Bevacizumab with excellent tolerance.

After six cycles of treatment, clinical and radiological progression was retained in the presence of pulmonary and pleural metastases.

A new biopsy was performed looking for a resistance mutation. Molecular screening demonstrated the presence of a C-MET amplification and a customized treatment was based on Crizotinib 250 mg twice daily. After two months of care, the patient has presented well tolerance biological and clinical one. The patient has been admitted for stage IV bronchospasm. Physical examination was marked by polypnea at 120 cycles per minute and oxygen desaturation at 85% at ambient air. Pulmonary radio showed a right pleural effusion and focal lobe of interstitial lung. Thoracic CT showed strong right –wing right interstitial pneumonitis and right apical nodule. The angioscan didn't show signs in favor of pulmonary embolism and biological exam normal.

The patient received symptomatic therapy and corticosteroids at the dose of 120 mg/ jour, nebulization by B2 mimetic the favorable evolution after 48 hours and treatment suspended.

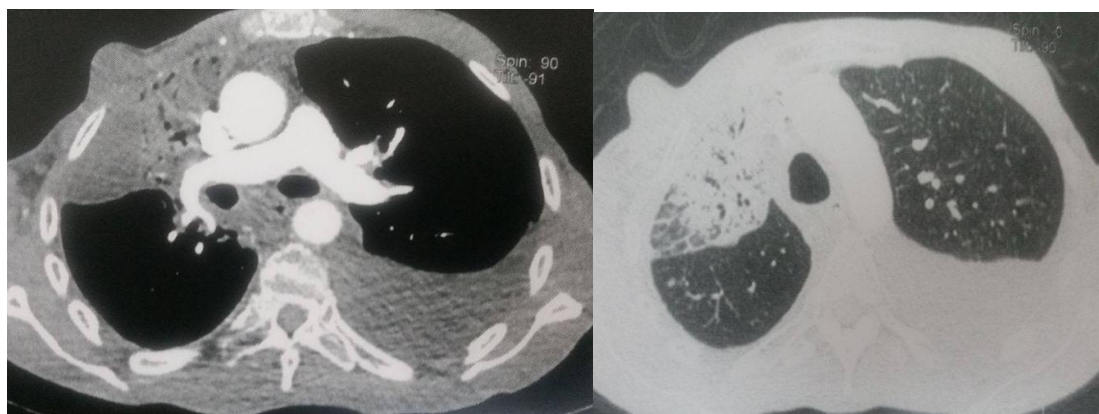


Figure A : Thoracic angiscan: Absence of image in favor of pulmonary embolism

Figure B : Parenchymal window showing the presence of several pulmonary parenchymal nodules and bilateral pleural effusion

DISCUSSION

Non small cell lung cancer is the most frequent histological form of cancer. The main causes of cancer death in the male population half of CNPC was metastatic at the time of diagnosis. Crizotinib has become a standard since 2011 for positive CPNCP ALK and an activity in the rearranged NSCL ROS1 and CM and amplified Data from initial clinical trials with crizotinib indicated that it was safe and generally well tolerated.

In the phase 1, 2 and 3 studies crizotinib the most common adverse events reported were visual changes, nausea, diarrhea, vomiting edema, constipation and elevated transaminases. The most serious toxicities were hepatotoxicity and pneumonia.

As can be expected with increasing clinical experience with crizotinib in recent years other toxicities have been described including and asymptomatic bradycardia and decreased total testosterone in men.

In this clinical case we report a bronchospasm due to crizotinib in a 53 years old patient who was treated with Paclitaxel- Carboplatin-Bevacizumab (4 cycles) then maintained by Erlotinib-Avastin and was given for 2 years and progressed.

Then the patient was put on crizotinib dose during which he presented bronchospasm as a doctor by profession the patient voluntarily took corticosteroids that improved the symptomatology.

The accountability to crizotinib was positive following the resumption of treatment.

The patient was hospitalized and stopped treatment under oxygen and corticotherapy he improved after 48h.

In the review of the literature we found respiratory thoracic and mediastinal toxicities due to crizotinib:

cough superior 4%, dyspnea 3-13%, severe pneumonia 1-2%.

CONCLUSION

Bronchospasm under crizotinib although little reported (2-4%) of the case can be life threatening. The management and care are focused on prevention by B2 mimetic and corticosteroid therapy.

REFERENCES

1. Pfizer Canada Inc. Monographie de produit XALKORI®. Kirkland (Québec), 23 novembre 2012.
2. Shaw AT, Kim D, Nakagawa K, et al. Crizotinib versus chimiothérapie dans le cancer du poumon avancé ALK-positif. N Engl J Med, 2013; 368(25): 2385-2394.
3. Chaari A, Ben Nasr S, Labidi S, Afrit M, Boussen H; Tunis Med, 2015 May; 93(5): 294-6. Metastatic non-small cell lung cancer: a Tunisian retrospective study about 100 cases.