

**MAYER-ROKITANSKY-KÜSTER-HAUSER (MRKH) SYNDROME : ABOUT A CASE  
WITH REVIEW OF THE LITERATURE****Dr. Soukaina Cherradi\*, Imane Benmouna, Mariam Mahtate, Najia Zeraidi, Amina lakhdar and Aziz Baidada**Department of Obstetric and Gynecology and Endoscopy, Souissi Maternity Hospital, Ibn Sina University Hospital,  
Mohammed V University, Rabat, Morocco.**\*Corresponding Author: Dr. Soukaina Cherradi**Department of Obstetric Gynecology and Endoscopy, Souissi Maternity Hospital, Ibn Sina University Hospital, Mohammed V University,  
Rabat, Morocco.

Article Received on 12/01/2022

Article Revised on 02/02/2022

Article Accepted on 22/02/2022

**ABSTRACT**

The Mayer-Rokitansky-Küster-Hauser (MRKH) syndrome is characterized by congenital aplasia of the uterus and the upper part (two-third) of the vagina. It may be isolated (type I) or associated with other malformations (type II or MURCS association). These latter involve the upper urinary tract, the skeleton and, to a lesser extent, the otologic sphere or the heart. The incidence of MRKH syndrome has been estimated as 1 in 4500 women. The prime feature is a primary amenorrhea in women presenting otherwise with normal development of secondary sexual characteristics and normal external genitalia. However, the vagina is reduced to a vaginal dimple with variable depth. The ovaries are normal and functional as well as the endocrine status. Karyotype is 46,XX, with no visible chromosome modification. The phenotypic manifestations of MRKH syndrome overlap with various other syndromes or malformations and thus require accurate delineation as well as differential diagnosis. For a long time, the syndrome has been considered as a sporadic anomaly, but increasing familial cases now support the hypothesis of a genetic cause currently under investigation. The syndrome appears to be transmitted as an autosomal dominant trait with incomplete penetrance and variable expressivity.

**KEYWORDS:** Agenesis of the uterus, Diagnosis, Génétique, Malformation, MRKH syndrome, MURCS.**Definition**

Mayer-Rokitansky-Küster-Hauser (MRKH) syndrome is characterized by a physiological development of the secondary sexual characters and by a normal female karyotype 46 XX, but with a congenital aplasia of the uterus and of two-third superior parts of upper vagina.<sup>[1]</sup> Schematically, we may distinguish between a simple syndrome, of first type (I), and complex syndrome, of second type (II). In the second type, other associated malformations are found out Mullerian duct aplasia Renal Dysplasia and Cervical Somite anomalies (MURCS) with renal unilateral agenesis, renal ectopia, or horseshoed kidney,<sup>[2]</sup> skeletal alterations with a particular reference to vertebral anomalies with Klippel-Feil syndrome, melted vertebrae, and scoliosis,<sup>[3]</sup> anomalies of auditory system; only in some cases heart defects and syndactyly or polydactyly,<sup>[2]</sup> are associated with it. During our experience, our patient had a MRKH without other associated malformations.

**Patient and Observation**

We report the case of a 19 year old female patient with no particular medical history, who presented with primary amenorrhea. On clinical examination, the external genitalia were without anomalies and the breasts were well developed with the presence of other

secondary sexual characteristics. The patient was a virgin so the vaginal examination was not done. Hormonal analysis was normal. The pelvic ultrasound noted the non visualization of the uterus. A complement by MRI confirming the agenesis of the uterus and the upper two-third of the vagina with hypoplasia of the left ovary and a right ovary was normal (**Figure 1-2-3**), with Kidneys in place without anomalies. Thus making the diagnosis of MRKH syndrome.

**DISCUSSION****Epidemiology**

The incidence of MRKH syndrome has been estimated as 1 in 4500 female births.<sup>[4-5]</sup> The majority of cases appears to be sporadic,<sup>[6]</sup> however family cases have also been described.<sup>[4-7-8]</sup> The mode of inheritance seems to be autosomal dominant with an incomplete degree of penetrance and variable expressivity.<sup>[4-9-10]</sup> suggesting that the prevalence of the syndrome may probably be underestimated. Type I (isolated) MRKH is less frequent than MURCS association.<sup>[11]</sup>

**Clinical description****Principle features of MRKH syndrome**

The first clinical signal is generally a primary amenorrhea in patients presenting with a normal female

phenotype, normal 46, XX karyotype,<sup>[12-15]</sup> and normal and functioning ovaries with no sign of androgen excess.<sup>[16,17]</sup> External examination reveals completed puberty with normal secondary female sexual characteristics (pubic hair and breast development are Tanner stage 5) and normal external genitalia. At the same time, the vagina is reduced to a more or less deep (2–7 cm) vaginal dimple.

Anatomic examination is however necessary to diagnose an MRKH syndrome of either type. Complete uterus aplasia in the presence of two rudimentary horns linked by a peritoneal fold and normal Fallopian tubes correspond to isolated or MRKH type I syndrome.<sup>[18]</sup> Type II MRKH is characterized by uterine symmetric or asymmetric hypoplasia, accompanied by aplasia of one of the two horns or by a size difference between the two horn rudiments, coupled with tubar malformations such as hypoplasia or aplasia of one or the two tubes.<sup>[19]</sup> Other malformations are often associated with MRKH type II syndrome and involve the upper urinary tract, the skeleton and the otologic sphere, heart malformations are more rarely reported. In this case, the acronym MURCS is generally used instead.<sup>[14,20]</sup> Cases of polycystic ovaries,<sup>[21-23]</sup> and ovarian tumors,<sup>[24-26]</sup> have been described in women presenting otherwise with normal 46, XX karyotypes. Moreover, aplasia or absence of Müllerian derivatives suggestive of MRKH syndrome have been described in cases of gonadal dysgenesis,<sup>[27,28]</sup> or agenesis,<sup>[29,30]</sup> in XY or XO patients presenting with female phenotypes. At present, these types of ovarian pathologies are not considered to be part of the MRKH or MURCS clinical spectrum, since no single group of patients showing a random association between any of these pathologies and uterovaginal aplasia has been reported so far. However, such studies should be undertaken on large cohorts of women with MRKH, to confirm this assumption.

#### **Associated malformations in MRKH syndrome type II (MURCS association)**

##### **Associated upper urinary tract malformations**

Altogether, associated upper urinary tract malformations are found in about 40% of cases with MRKH syndrome.<sup>[19]</sup> Mainly, they include unilateral renal agenesis (23–28%), ectopia of one or both kidneys (17%), renal hypoplasia (4%), horseshoe kidney and hydronephrosis.<sup>[31,32]</sup> It should be noted that in our patient no other malformation was noted. Moreover, a case of bilateral renal agenesis (Potter sequence) associated with absence of uterus and oviducts has been reported in a medically aborted fetus,<sup>[33]</sup> reinforcing the idea that Müllerian aplasia, the principle feature of MRKH syndrome, could be an extra manifestation of hereditary renal adysplasia (HRA),<sup>[9]</sup> in some cases. Renal dysplasia seems to be either the prime characteristic of HRA where Müllerian malformations of various types are sometimes encountered or a secondary manifestation of MRKH syndrome. Although similar, these syndromes can probably be distinguished from

each other when family histories are available: HRA is transmitted as a strict autosomal dominant trait,<sup>[36,37]</sup> whereas MRKH shows incomplete penetrance coupled with a highly variable expressivity when described in relatives.<sup>[5,10,38,39]</sup>

It is therefore, noteworthy that renal evaluation is not only required when diagnosing MRKH syndrome, but is also fully justified in probands relatives.

##### **Associated skeletal abnormalities**

These anomalies mainly involve the spine (30 to 40%),<sup>[19,31,40]</sup> and, less frequently, the face and the limb extremities. Rachidial malformations encountered in MURCS association are scoliosis (20%),<sup>[31]</sup> isolated vertebral anomalies (asymmetric, fused or wedged vertebrae), Klippel-Feil association (fusion of at least two cervical segments, short neck, low hair line, restriction of neck motion)<sup>[41]</sup> and/or Sprengel's deformity,<sup>[42]</sup> rib malformation or agenesis, and spina bifida.<sup>[40]</sup> Face and limb malformations are mainly brachymesophalangy,<sup>[43]</sup> ectrodactyly,<sup>[44]</sup> duplicated thumb,<sup>[45]</sup> absent radius,<sup>[46]</sup> atrio-digital dysplasia (Holt-Oram like syndrome),<sup>[47,48]</sup> and facial asymmetry.<sup>[49-51]</sup>

##### **Associated hearing impairment**

Auditory defects or deafness are associated with 10 to 25% of MURCS patients,<sup>[42,52,53]</sup> they often concern conductive deafness due to middle ear malformations, such as stapedia ankylosis,<sup>[42]</sup> or sensorineural defects of varying severity.<sup>[53]</sup> Patients with hearing loss associated with adysplasia of the auditory meatus and/or malformed ears have also been reported.<sup>[49,54]</sup>

##### **Associated heart malformations**

The association of MRKH with heart malformations is less common. All reports involved lethal or severe cardiac defects evocating Holt-Oram or velocardiofacial-like syndromes requiring surgery when possible. Such reported malformations were aorto-pulmonary window,<sup>[48]</sup> atrial septal defect,<sup>[47]</sup> and conotruncal defects such as pulmonary valvular stenosis,<sup>[55]</sup> or Tetralogy of Fallot.<sup>[56]</sup>

##### **Etiology**

The MRKH syndrome was initially considered to be of sporadic occurrence, suggesting the involvement of non genetic or environmental factors,<sup>[57]</sup> such as gestational diabetes,<sup>[58]</sup> or thalidomide-like teratogens.<sup>[1,14,31,59]</sup> However, studies analyzing available pregnancy histories failed to identify any association with drug use, illness, or exposure to known teratogens.<sup>[58,60-62]</sup> Another explanation of the sporadic occurrence of the syndrome was the hypothesizes of a polygenic/multifactorial inheritance,<sup>[5,39,57,63]</sup> characterized by a low recurrence risk for first-degree relatives. The most plausible explanation actually relies on the description of significant and increasing number of familial aggregates based on accurate delineation of the syndrome in the probands as well as in their relatives. Indeed, utero-

vaginal aplasia is often found associated with other malformations, mainly renal and skeletal, these two latter being sometimes observed in combination with the first and interestingly, occurring in more distant relatives as well as mothers of MRKH patients.<sup>[1,7,9,10,64]</sup>

Utero-vaginal aplasia can thus represent only one manifestation of a variably expressed genetic defect. This latter appears to be transmitted as an autosomal dominant trait with incomplete penetrance coupled with variable expressivity of a single mutant gene, as previously hypothesized.<sup>[1,9,10,65]</sup> or of a limited chromosomal imbalance undetectable in standard karyotypes.

The etiology of MRKH syndrome has remained quite unclear until now.<sup>[65,66]</sup> although the spectrum of malformations encountered suggests a developmental field defect.<sup>[14,20]</sup> involving organ systems which are closely related during embryogenesis.

More precisely, MRKH syndrome may be attributed to an initial affection of the intermediate mesoderm, consequently leading (by the end of the fourth week of fetal life) to an alteration of the blastema of the cervicothoracic somites and the pronephric ducts.<sup>[14]</sup> These latter subsequently induce the differentiation of the mesonephroi and then the Wolffian and Müllerian ducts.

The lack of families with informative genetic histories has initially led to a candidate gene approach for determination of the underlying etiology of the syndrome based either on association with other genetic diseases or on involvement during embryogenesis.

As a result, the genetic association of MRKH with galactosemia,<sup>[67]</sup> or with cystic fibrosis,<sup>[68]</sup> was analyzed, but neither the gene for galactose-1-phosphate uridyl transferase (GALT),<sup>[69]</sup> nor the gene encoding the cystic fibrosis transmembrane regulator (CFTR) chloride channel.<sup>[68]</sup> showed any mutation or polymorphism associated with the disorder. Aberrant expression of anti-Müllerian hormone (AMH) or its receptor, both involved in Müllerian duct regression<sup>[70]</sup> was hypothesized as a cause of MRKH syndrome,<sup>[2,71]</sup> however, this theory was later discounted as a result of contradictory findings from a study of 32 patients.<sup>[72]</sup>

Moreover, incomplete aplasia of Müllerian structures is often observed in MRKH syndrome, showing that Müllerian differentiation does take place but is incomplete. Genes with a broad spectrum of activity during early development (such as WT1,<sup>[72]</sup> PAX2,<sup>[73]</sup> HOXA7 to HOXA13<sup>[64,74]</sup> and PBX1<sup>[75]</sup>) have also been suggested as candidates, on the basis of phenotypes observed in mutant mice. However, their role in MRKH syndrome has not been subsequently demonstrated.

WNT4 is another developmental gene, belonging to the WNT family of genes that regulate cell and tissue growth and differentiation during embryogenesis.<sup>[76]</sup> its homozygotic inactivation in the mouse model leads to a total failure of Müllerian duct formation and numerous lethal defects at birth.<sup>[77]</sup> In addition, WNT4 is known to be critical for successful nephrogenesis.<sup>[78-80]</sup> A loss-of-function mutation in the WNT4 gene has been recently described in an 18-year-old woman, in association with absence of Müllerian-derived structures, unilateral renal agenesis, and clinical signs of androgen excess.<sup>[81]</sup> The congenital malformations observed in this patient suggested an MRKH-like phenotype and were similar to those observed in the *Wnt4*<sup>-/-</sup> mouse,<sup>[77]</sup> indicating a dominant effect.<sup>[81]</sup> In this pathological case as well as in the mouse model, it seems that loss-of-function of WNT4 which is essential for normal ovarian differentiation,<sup>[77]</sup> has led to a masculinization of the fetal gonads consequently producing androgens.

The WNT4 protein is known to repress male-specific genes such as those encoding steroidogenic enzymes CYP17A1 and HSB3B2, which are essential for the synthesis of testosterone.<sup>[77]</sup> Mutated WNT4 may not be able to suppress the expression of androgen-synthesizing enzymes in ovarian cells, therefore leading to the observed hyperandrogenic phenotype.<sup>[81,82]</sup> Furthermore, WNT4 appears to be essential for the initial differentiation of the Müllerian ducts.<sup>[66,77,83]</sup> The dominant-negative mutation of WNT4 may then produce two distinct effects, hyperandrogenism and uterine aplasia. The sequencing of the WNT4 gene in 19 MRKH patients has confirmed that this gene is not involved in MRKH syndrome.<sup>[84]</sup> Finally, the very recent report on a second patient bearing another WNT4 mutation has led to the conclusion that WNT4 deficiency is responsible for a clinical phenotype distinct from the classic MRKH syndrome.<sup>[82]</sup>

This new syndrome due to WNT4 mutations in XX women and characterized by absence of Müllerian ducts derivatives, hyperandrogenism and kidney optional adysplasia [81,82], is close but different from MRKH syndrome, therefore, it should be referred to as a proper name, such as "WNT4 syndrome" or "WNT4 defects" and be consequently recorded under an appropriate OMIM number. This latter could well be 277000 if amended, OMIM 601076 would then be restricted to MRKH type I and II or MURCS. The TCF2 gene (formerly v-HNF1 or HNF-1 $\beta$ ) was originally found associated with MODY-type diabetes.<sup>[85]</sup> and with diabetes mellitus, renal cysts and other renal developmental disorders.<sup>[86,87]</sup>

Interestingly, genital malformations such as bicornuate uterus,<sup>[88]</sup> uterus didelphys,<sup>[89]</sup> and Müllerian aplasia.<sup>[89]</sup> (OMIM 158330) were occasionally found associated with renal anomalies in some familial aggregates showing mutations within the TCF2 gene.

Defects of this later gene can thus account for some rare cases of Müllerian malformations, including aplasia, making this gene one of the candidates for MRKH, but restricted to familial cases with renal and/or diabetes history. Finally the hypothesis of polygenic/multifactorial causes for MRKH syndrome has been reinforced by recent findings, in adults, of interstitial and terminal deletions involving chromosomes 22.<sup>[90]</sup> and 4.<sup>[91]</sup> respectively. However, the large number of genes included in each of these deletions has not allowed yet to precise any specific gene responsible for the syndrome.

Only analysis of large cohorts of MRKH patients will certainly help to delineate new candidate genes and to establish phenotype/genotype correlations necessary for the genetic diagnosis of the syndrome.

### Diagnostic methods

#### Transabdominal ultrasonography

Transabdominal ultrasonography is a simple and non-invasive method, and must be the first investigation in evaluating patients with suspected Müllerian aplasia. This technique reveals an absence of the uterine structure between the bladder and the rectum. However, a quadrangular retro-vesical structure may be wrongly identified as a hypoplastic or juvenile uterus: this fact corresponds to the vestigial lamina located underneath the peritoneal fold, itself situated transversally to the posterior side of the bladder, where uterosacral ligaments attach.

Since the vestigial lamina shows no cavity, there is no evidence of a hyperechogenic line, which normally corresponds to the uterine mucous membrane.<sup>[92]</sup>

Finally, renal malformations must be systematically evaluated during this scan.

#### Magnetic resonance imaging (MRI)

MRI is a non-invasive technique that provides a more sensitive and more specific means of diagnosis than ultrasonography. It should be performed when ultrasonographic findings are inconclusive or incomplete, since failure to clearly identify the uterus or Müllerian rudiments or ovaries does not necessarily imply their absence.

MRI allows an accurate evaluation of the uterine aplasia, as well as a clear visualization of the rudimentary horns and ovaries.<sup>[93,94]</sup> The uterine aplasia is best characterized on sagittal images, while vaginal aplasia is best evidenced on transverse images.<sup>[95]</sup> Moreover, MRI can be used at the same time to search for associated renal and skeletal malformations.

#### Celioscopy

This is an invasive technique requiring hospitalization and anesthesia. It is performed in cases of doubtful diagnosis after ultrasonography and/or MRI.

Celioscopy is nowadays mainly reserved for women in whom interventional therapy is likely to be undertaken (construction of a neo-vagina: see Treatment section). It defines the precise anatomical location and abnormalities of the uterus, the possible tubar remnants, the vestigial lamina and the ovaries.

#### Biological status

The karyotype of MRKH patients is always 46, XX with no visible chromosome modification. The endocrine balance (plasmatic follicle stimulating hormone (FSH), luteinizing hormone (LH) and 17 $\beta$ -oestradiol) is normal and provides evidence of normal and functional ovaries.<sup>[16,96]</sup>

There is no external or endocrine sign of hyperandrogenism, as shown by a normal plasmatic level of testosterone, delta-4-androstenedione, 17-hydroxyprogesterone and dehydroepiandrosterone. Once MRKH syndrome is diagnosed, a full check-up must be undertaken to search for associated malformations.

Since renal and skeletal abnormalities may not be symptomatic, it is necessary to perform at least transabdominal ultrasonography and spine radiography. In case of suspicion of hearing impairment and/or a cardiac anomaly, complementary audiogram and/or heart echography must also be carried out.

Moreover, when diagnosing an MRKH syndrome in a patient, it is important to consider the family history. Depending on the background, investigation of the patient's relatives may also be recommended, mainly for renal but also for skeletal malformations.

#### Differential diagnosis

Differential diagnosis of Müllerian aplasia includes patients presenting with primary amenorrhea and with normal secondary sexual characteristics (**Table 1**). This should first lead to exclusion of gonadal dysgenesis. The differential diagnosis includes congenital absence of uterus and vagina (aplasia or agenesis), isolated vaginal atresia and androgen insensitivity [97,98]. Transverse vaginal septum and imperforate hymen, which can be initially misleading, are not included. Indeed, patients with these latter conditions have normal cervix and uterus, both of which are palpable on rectal examination. Ultrasonography can be used to define the Müllerian structures in infrequent cases where palpation is unrevealing.

**Isolated vaginal atresia :** Questioning will generally reveal pelvic pain in association with cryptomenorrhea on physical examination. Vaginal atresia is found in various syndromes, mainly Winter syndrome (characterized by renal, genital, and middle ear anomalies) (OMIM 267400),<sup>[99,100]</sup> and McKusick Kaufman syndrome, which associates hydrometrocolpos, postaxial polydactyly and congenital heart malformation (OMIM 236700) and is due to mutations in the MKKS



gene located on chromosome 20p12.<sup>[101]</sup> It is noteworthy that while partial or total Müllerian aplasia found in MRKH syndrome confers irreversible sterility, vaginal atresia can be surgically corrected to permit pregnancy.<sup>[100]</sup>

**WNT4 defects :** To date, only two cases of WNT4 defects have been published.<sup>[81,82]</sup> This condition is similar but distinct from MRKH syndrome (see Etiology section) and may therefore lead to confusion. It seems quite clear that other cases will soon be reported in the literature, making it important to include this new syndrome in the differential diagnosis of MRKH/MURCS. Evidence of hyperandrogenism in women presenting with normal female phenotype should then initially direct the clinicians to suspect WNT4 as a cause.

**Androgen insensitivity syndrome (AIS):** AIS, also called testicular feminization syndrome (TFM), (OMIM 300068), is a male pseud hermaphroditism disorder caused by mutations in the gene for the androgen receptor.<sup>[102]</sup> AIS is an X-linked recessive disorder in which affected males have female external genitalia, female breast development, blind vagina, absent uterus and female adnexa, and abdominal or inguinal testes. Partial androgen insensitivity results in hypospadias and micropenis with gynecomastia, thus the syndrome cannot be confused with MRKH syndrome.

**Müllerian derivative aplasia :** may be suggestive of MRKH syndrome, has been described in association with gonadal dysgenesis. In this case, patients showed abnormal karyotypes, always involving the X chromosome, such as mosaicisms 45, X/46, X, dic(X),<sup>[28]</sup> 46, XX/45, X0,<sup>[103]</sup> 46, XX/47, XXX<sup>[104]</sup> or rearrangements/deletions such as 46, X, del(X)(pter-q22),<sup>[105]</sup> 46, X, i(Xq)<sup>[106]</sup> or more complex karyotypes.<sup>[13]</sup>

However, MRKH syndrome does not seem to be an X-linked trait and it therefore appears that the X chromosome carries one or several genes involved in very early differentiation of at least both gonads and Müllerian ducts.

#### Management including treatment

Young women diagnosed with MRKH syndrome suffer from extreme anxiety and very high psychological distress when they are told they have no uterus and vagina. Thus, it is recommended that the patient and family attend counseling before and throughout treatment. Group programs.<sup>[107]</sup> and/or MRKH patients associations are also of great help. Indeed, psychological adjustment as well as medical attitude will be of great consequence for future decisions of creation of a neovagina and management of sterility.<sup>[2,71,107]</sup>

#### Treatment of utero-vaginal aplasia

Treatment consisting of creating a neovagina must be offered to patients only when they are ready to start sexual activity and also when they are emotionally mature. Treatment may be either surgical or nonsurgical, but the chosen method needs to be tailored to the individual needs, motivation of the patient and the options available.<sup>[2,71,97,108]</sup> There are two main types of procedure.

The first one consists of the creation of a new cavity and can be nonsurgical or surgical. The second is vaginal replacement with a pre-existing canal lined with a mucous membrane (a segment of bowel).

#### Nonsurgical creation of a neovagina

The most commonly used nonsurgical procedure is Franck's dilator method. It involves the application, first by the clinician and then by the patient herself, of vaginal dilators (Hegar candles), progressively increasing in length and diameter. Dilators are placed on the perineal dimple for at least 20 minutes a day. A variation of this procedure, using a bicycle stool, was described by Ingram.<sup>[109]</sup> The whole process takes between six weeks and several months, with a success rate varying from 78%.<sup>[110]</sup> to 92%.<sup>[111]</sup> Complications are rare; they generally consist of urethritis, cystitis, vesico- or retro-vaginal fistula and secondary prolapse. As this non operative approach is non invasive and often successful, it is recommended as a first-line therapy. However, it can be applied only when the vaginal dimple is deep enough (2–4 cm).

#### Surgical creation of a neovagina

A number of techniques are appropriate for the correction of vaginal agenesis and there is no consensus regarding the best option, the approach being most often based on the surgeon's experience. Three methods are currently in use:

The Abbe-McIndoe operation: this involves the dissection of a space between the rectum and the bladder, placement of a mold covered with a skin graft into the space, and diligent postoperative vaginal dilatation. Modifications of this procedure rely on spontaneous epithelialization or on the use of different materials such as peritoneum,<sup>[112]</sup> minora labia grafting, or synthetic materials.<sup>[113,114]</sup>

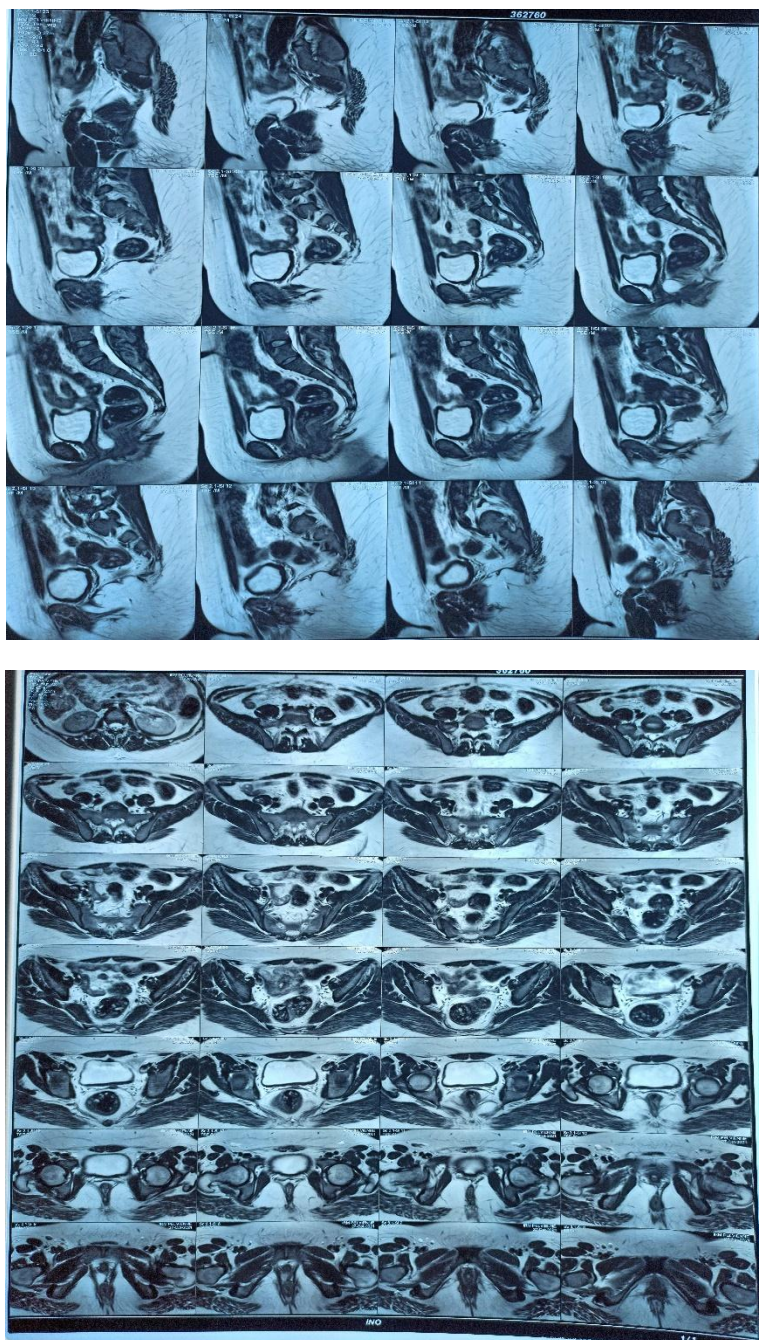
The Vecchiotti operation is a mixture of surgical and non surgical methods. It has been performed frequently in Europe over the last 20 years.<sup>[71]</sup> This procedure involves the creation of a neovagina via dilatation with a traction device attached to the abdomen, sutures placed subperitoneally by laparotomy, and a plastic olive placed in the vaginal dimple. A laparoscopic or celioscopic modification is often preferred and leads to comparable results.<sup>[115]</sup>

Sigmoidal colpoplasty: this technique involves vaginal replacement or creation of a neovagina by grafting a 12–18 cm long segment of sigmoid,<sup>[116]</sup> providing that a single and/or left pelvic kidney does not impair the procedure. Sigmoidal colpoplasty is believed to be an efficient procedure giving excellent results, although complete adequacy for coital function often requires prolonged care and support.<sup>[117]</sup>

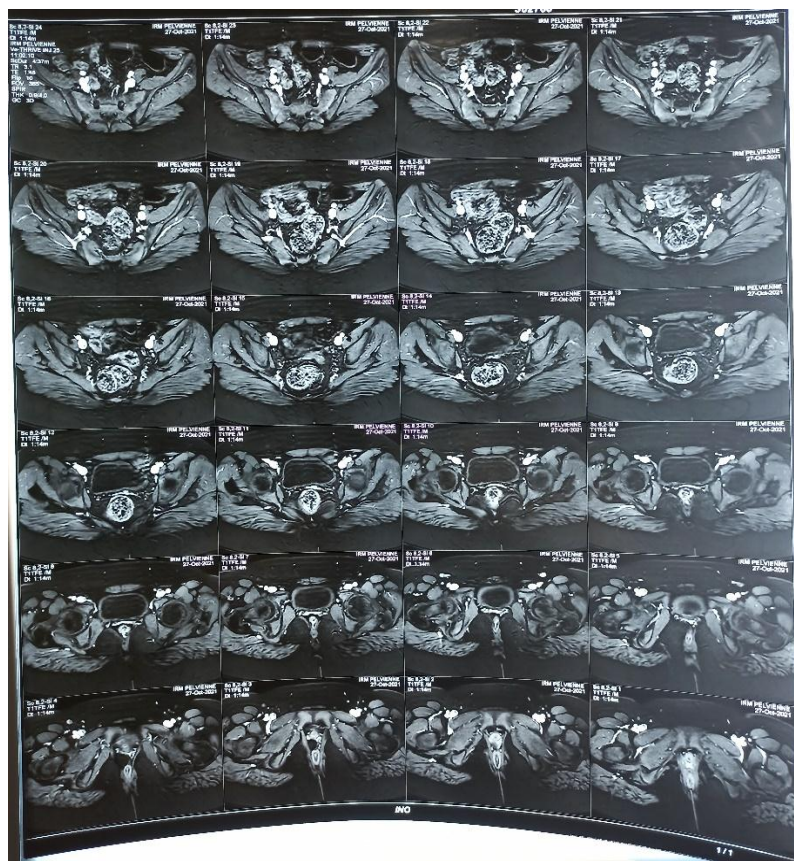
In conclusion, non surgical creation of a neovagina should be the first-line approach, if suitable. When a surgical approach is chosen, the surgeon must be experienced with the procedure. Clinical follow-up and also regular intercourse take place in the mid- and long-term successful process. Above all, a careful

psychological preparation of the patient before any treatment or intervention is of major importance. Our patient refused to receive a treatment for the moment, so we respected her wish.

Ultimately, infertility will be the most difficult aspect of the disorder for the patient to accept. Nowadays medical technologies allow, in many countries, women to appeal for in vitro fertilization of their own eggs and to use surrogate pregnancy.<sup>[97]</sup> However, the risk for transmission of the disease cannot be accurately evaluated, since very little is currently known about genetics of the MRKH syndrome. This strengthens the need for more research in the field.







**Table 1: Summary of differential diagnosis between MRKH syndrome and isolated vaginal atresia, WNT4 syndrome, and androgen insensitivity syndrome.**

	MRKH/MURCS	isolated vaginal atresia	WNT4 syndrome	Androgen insensitivity
Upper vagina	Absent	Variable	Absent	Absent
Uterus	Absent	Present	Absent	Absent
Gonads	Ovary	Ovary	Masculinized ovary	Testis
Breast development	Normal	Normal	Normal	Normal
Pubic-hair development	Normal	Normal	Normal	Spars
Hyperandrogenism	No	No	Yes	Yes
karyotype	46,XX	46,XX	46,XX	46,XX

### Figure 1-2-3

Coronal (1) and Transverse (2-3) T2 weighted images in 19 years old woman with primary amenorrhea shows agenesis of the uterus and the upper two-third of the vagina with hypoplasia of the left ovary and a normal right ovary.

### CONCLUSION

In the case of primary amenorrhea in a young woman with well-differentiated sexual characteristics, it is important to make the most accurate diagnosis possible.

The possible confusion with other syndromes including a uterovaginal anomaly requires knowledge of the different differential diagnoses.

This notion is all the more important since it is now established that there is a genetic component to the

syndrome, hence the need for genetic counselling in the case of MRKH syndrome.

The diagnosis is based essentially on magnetic resonance imaging and its management must be multidisciplinary.

### Conflicts of interest

The authors declare no conflicts of interest.

### Author Contributions

SC contributed substantially to the conception and design, data acquisition, analysis and interpretation of the data, participated in the drafting of the manuscript and critically reviewed it for important intellectual content. IB, MM, AL, NZ, AB contributed substantially to the interpretation of the data, drafting of the manuscript, and critically reviewed it for its important intellectual content. All authors read and approved the final version of the manuscript.

## REFERENCES

1. K. Morcel, D. Guerrier, T. Watrin, I. Pellerin, and J. Leveque, "The Mayer-Rokitansky-Kuster-Hauser (MRKH) syndrome: clinical description and genetics," *Journal de Gynecologie Obstetrique et Biologie de la Reproduction*, 2008; 37(6): 539–546.
2. J. E. Griffin, C. Edwards, and J. D. Madden, "Congenital absence of the vagina. The Mayer-Rokitansky-Kuster-Hauser syndrome," *Annals of Internal Medicine*, 1976; 85(2): 224–236.
3. K. Fisher, R. H. Esham, and I. Thorncroft, "Scoliosis associated with typical Mayer-Rokitansky-Kuster-Hauser syndrome," *Southern Medical Journal*, 2000; 93(2): 243–246.
4. Griffin JE, Edwards C, Madden JD, Harrod MJ, Wilson JD: Congenital absence of the vagina. The Mayer-Rokitansky-Kuster-Hauser syndrome. *Ann Intern Med*, 1976, 85: 224-236.
5. Varner RE, Younger JB, Blackwell RE: Mullerian dysgenesis. *J Reprod Med*, 1985; 30: 443-450.
6. Carson SA, Simpson JL, Malinak LR, Elias S, Gerbie AB, Buttram VC Jr., Sarto GE: Heritable aspects of uterine anomalies. II. Genetic analysis of Mullerian aplasia. *Fertil Steril*, 1983; 40: 86-90.
7. Jones HW Jr., Mermut S: Familial occurrence of congenital absence of the vagina. *Am J Obstet Gynecol*, 1972; 114: 1100-1101.
8. Tiker F, Yildirim SV, Barutcu O, Bagis T: Familial mullerian agenesis. *Turk J Pediatr*, 2000; 42: 32.
9. Opitz JM: Vaginal atresia (von Mayer-Rokitansky-Kuster or MRK anomaly) in hereditary renal adysplasia (HRA). *Am J Med Genet*, 1987; 26: 873-876.
10. Pavanello Rde C, Eigier A, Otto PA: Relationship between Mayer-Rokitansky-Kuster (MRK) anomaly and hereditary renal adysplasia (HRA). *Am J Med Genet*, 1988; 29: 845-849.
11. Strubbe EH, Cremers CW, Willemsen WN, Rolland R, Thijn CJ: The Mayer-Rokitansky-Kuster-Hauser (MRKH) syndrome without and with associated features: two separate entities? *Clin Dysmorphol*, 1994; 3: 192-199.
12. Azoury RS, Jones HW Jr.: Cytogenetic findings in patients with congenital absence of the vagina. *Am J Obstet Gynecol*, 1966; 94: 178-180.
13. Sarto GE: Cytogenetics of fifty patients with primary amenorrhea. *Am J Obstet Gynecol*, 1974; 119: 14-23.
14. Duncan PA, Shapiro LR, Stangel JJ, Klein RM, Addonizio JC: The MURCS association: Mullerian duct aplasia, renal aplasia, and cervicothoracic somite dysplasia. *J Pediatr*, 1979; 95: 399-402.
15. Leduc B, van Campenhout J, Simard R: Congenital absence of the vagina. Observations on 25 cases. *Am J Obstet Gynecol*, 1968; 100: 512-520.
16. Fraser IS, Baird DT, Hobson BM, Michie EA, Hunter W: Cyclical ovarian function in women with congenital absence of the uterus and vagina. *J Clin Endocrinol Metab*, 1973; 36: 634-637.
17. Shane JM, Wilson EA, Schiff I, Naftolin F: A preliminary report on gonadotropin responsivity in the Rokitansky-Kuster-Hauser syndrome (congenitally absent uterus). *Am J Obstet Gynecol*, 1977; 127: 326-327.
18. Jones KL: Rokitansky sequence. In *Smith's recognizable patterns of human malformations* (Fourth ed) Edited by: Saunders WB. Philadelphia, 1988; 570-571.
19. Strubbe EH, Willemsen WN, Lemmens JA, Thijn CJ, Rolland R: Mayer-Rokitansky-Kuster-Hauser syndrome: distinction between two forms based on excretory urographic, sonographic, and laparoscopic findings. *Am J Roentgenol*, 1993; 160: 331-334.
20. Braun-Quentin C, Billes C, Bowing B, Kotzot D: MURCS association: case report and review. *J Med Genet*, 1996; 33: 618-620.
21. Ugur M, Karakaya S, Zorlu G, Arslan S, Gulerman C, Kukner S, Gokmen O: Polycystic ovaries in association with mullerian anomalies. *Eur J Obstet Gynecol Reprod Biol.*, 1995; 62: 57-59.
22. Appelman Z, Hazan Y, Hagay Z: High prevalence of mullerian anomalies diagnosed by ultrasound in women with polycystic ovaries. *J Reprod Med*, 2003; 48: 362-364.
23. Raybaud C, Richard O, Arzim M, David M: [Mayer-Rokitansky-Kuster-Hauser syndrome: associated pathologies]. *Arch Pediatr*, 2001; 8: 1209-1213.
24. Ghirardini G, Magnani A: Mayer-Rokitansky-Kuster-Hauser syndrome and ovarian cancer. Report of a case. *Clin Exp Obstet Gynecol*, 1995; 22: 247-248.
25. Rodriguez E, Pombo F, Alvarez C, Arnal F: Tumor in ectopic omental ovary in Mayer-Rokitansky-Kuster-Hauser syndrome: CT findings. *J Comput Assist Tomogr*, 1998; 22: 758-759.
26. Tsaur GT, Lee MH, Su SL, Wu MJ, Huang TW: Mayer-Rokitansky-Kuster-Hauser syndrome with immature teratoma of the ovary at age 4 years. *Gynecol Oncol*, 1995; 56: 456-459.
27. Marrakchi A, Belhaj L, Boussouf H, Chraïbi A, Kadiri A: [Pure gonadal dysgenesis XX and XY: observations in fifteen patients]. *Ann Endocrinol (Paris)*, 2005; 66: 553-556.
28. Guitron-Cantu A, Lopez-Vera E, Forsbach-Sanchez G, Leal-Garza CH, Cortes-Gutierrez EI, Gonzalez-Pico I: Gonadal dysgenesis and Rokitansky syndrome. A case report. *J Reprod Med*, 1999; 44: 891-893.
29. Kaya H, Sezik M, Ozkaya O, Kose SA: Mayer-Rokitansky-Kuster-Hauser syndrome associated with unilateral gonadal agenesis. A case report. *J Reprod Med*, 2003, 48 : 902-904.
30. Gorgojo JJ, Almodovar F, Lopez E, Donnay S: Gonadal agenesis 46,XX associated with the atypical form of Rokitansky syndrome. *Fertil Steril*, 2002; 77: 185-187.



31. Pittock ST, Babovic-Vuksanovic D, Lteif A: Mayer-Rokitansky-Kuster-Hauser anomaly and its associated malformations. *Am J Med Genet A*, 2005; 135: 314-316.
32. Oppelt P, S PR, Kellermann A, Brucker S, G AH, K SL, P LS, Strick R, Wallwiener D, M WB: Clinical aspects of Mayer-Rokitansky-Kuester-Hauser syndrome: recommendations for clinical diagnosis and staging. *Hum Reprod*, 2005.
33. Devriendt K, Moerman P, Van Schoubroeck D, Vandenberghe K, Fryns JP: Chromosome 22q11 deletion presenting as the Potter sequence. *J Med Genet*, 1997; 34: 423-425.
34. Biedel CW, Pagon RA, Zapata JO: Mullerian anomalies and renal agenesis: autosomal dominant urogenital adysplasia. *J Pediatr*, 1984; 104: 861-864.
35. Schimke RN, King CR: Hereditary urogenital adysplasia. *Clin Genet*, 1980; 18: 417-420.
36. McPherson E, Carey J, Kramer A, Hall JG, Pauli RM, Schimke RN, Tasin MH: Dominantly inherited renal adysplasia. *Am J Med Genet*, 1987; 26: 863-872.
37. Doray B, Gasser B, Reinartz I, Stoll C: Hereditary renal adysplasia in a three generations family. *Genet Couns*, 1999; 10: 251-257.
38. Basile C, De Michele V: Renal abnormalities in Mayer-Rokitanski-Kuster-Hauser syndrome. *J Nephrol*, 2001; 14: 316-318.
39. Petrozza JC, Gray MR, Davis AJ, Reindollar RH: Congenital absence of the uterus and vagina is not commonly transmitted as a dominant genetic trait: outcomes of surrogate pregnancies. *Fertil Steril*, 1997; 67: 387-389.
40. Strubbe EH, Lemmens JA, Thijn CJ, Willemsen WN, van Toor BS: Spinal abnormalities and the atypical form of the Mayer-Rokitansky-Kuster-Hauser syndrome. *Skeletal Radiol*, 1992; 21: 459-462.
41. Baird PA, Lowry RB: Absent vagina and the Klippel-Feil anomaly. *Am J Obstet Gynecol*, 1974; 118: 290-291.
42. Cremers CW, Strubbe EH, Willemsen WN: Stapedial ankylosis in the Mayer-Rokitansky-Kuster-Hauser syndrome. *Arch Otolaryngol Head Neck Surg* 1995; 121: 800-803.
43. Strubbe EH, Thijn CJ, Willemsen WN, Lappohn R: Evaluation of radiographic abnormalities of the hand in patients with the Mayer-Rokitansky-Kuster-Hauser syndrome. *Skeletal Radiol*, 1987; 16: 227-231.
44. Massafra C, Bartolozzi M, Bartolozzi P, Scillone L: Rokitansky-Kuster-Hauser syndrome with ectrodactyly. *Acta Obstet Gynecol Scand*, 1988; 67: 557-560.
45. Lopez AG, Fryns JP, Devriendt K: MURCS association with duplicated thumb. *Clin Genet*, 2002; 61: 308-309.
46. Behera M, Couchman G, Walmer D, Price TM: Mullerian agenesis and thrombocytopenia absent radius syndrome: a case report and review of syndromes associated with Mullerian agenesis. *Obstet Gynecol Surv*, 2005; 60: 453-461.
47. Fakih MH, Williamson HO, Seymour EQ, Pai S: Concurrence of the Holt-Oram syndrome and the Rokitansky-Kuster-Hauser syndrome. A case report. *J Reprod Med*, 1987; 32: 549-550.
48. Ulrich U, Schrickel J, Dorn C, Richter O, Lewalter T, Luderitz B, Rhiem K: Mayer-von Rokitansky-Kuster-Hauser syndrome in association with a hitherto undescribed variant of the Holt-Oram syndrome with an aorto-pulmonary window. *Hum Reprod*, 2004; 19: 1201-1203.
49. Wulfsberg EA, Grigbsy TM: Rokitansky sequence in association with the facio-auriculo-vertebral sequence: part of a mesodermal malformation spectrum? *Am J Med Genet*, 1990; 37: 100-102.
50. Van Bever Y, van den Ende JJ, Richieri-Costa A: Oculo-auriculo-vertebral complex and uncommon associated anomalies: report on 8 unrelated Brazilian patients. *Am J Med Genet*, 1992; 44: 683-690.
51. Pillay K, Matthews LS, Wainwright HC: Facio-auriculo-vertebral sequence in association with DiGeorge sequence, Rokitansky sequence, and Dandy-Walker malformation: case report. *Pediatr Dev Pathol*, 2003; 6: 355-360.
52. Strubbe EH, Cremers CW, Dikkers FG, Willemsen WN: Hearing loss and the Mayer-Rokitansky-Kuster-Hauser syndrome. *Am J Otol*, 1994; 15: 431-436.
53. Letterie GS, Vauss N: Mullerian tract abnormalities and associated auditory defects. *J Reprod Med*, 1991; 36: 765-768.
54. Winer-Muram HT, Muram D, Wilroy RS, Cupp C: The concurrence of facioauriculovertebral spectrum and the Rokitansky syndrome. *Am J Obstet Gynecol*, 1984; 149: 569-570.
55. Kula S, Saygili A, Tunaoglu FS, Olgunturk R: Mayer-Rokitansky-Kuster-Hauser syndrome associated with pulmonary stenosis. *Acta Paediatr*, 2004; 93: 570-572.
56. M LG, Shulman LP: Tetralogy of Fallot, imperforate anus, and Mullerian, renal, and cervical spine (MURCS) anomalies in a 15-year-old girl. *J Pediatr Adolesc Gynecol*, 2002; 15: 231-233.
57. Simpson JL: Genetics of the female reproductive ducts. *Am J Med Genet*, 1999; 89: 224-239.
58. Martinez-Frias ML, Bermejo E, Rodriguez-Pinilla E, Prieto L, Frias JL: Epidemiological analysis of outcomes of pregnancy in gestational diabetic mothers. *Am J Med Genet*, 1998; 78: 140-145.
59. Hoffmann W, Grospietsch G, Kuhn W: Thalidomide and female genital malformations. *Lancet*, 1976; 2: 794.
60. Schinzel A: Phocomelia and additional anomalies in two sisters. *Hum Genet*, 1990; 84: 539-541.
61. Steinkampf MP, Dharia SP, Dickerson RD: Monozygotic twins discordant for vaginal agenesis

- and bilateral tibial longitudinal deficiency. *Fertil Steril*, 2003; 80: 643-645.
62. Martinez-Frias ML: Epidemiological analysis of outcomes of pregnancy in diabetic mothers: identification of the most characteristic and most frequent congenital anomalies. *Am J Med Genet*, 1994; 51: 108-113.
  63. Golan A, Langer R, Bukovsky I, Caspi E: Congenital anomalies of the mullerian system. *Fertil Steril*, 1989; 51: 747-755.
  64. Karam KS, Salti I, Hajj SN: Congenital absence of the uterus. *Clinicopathologic and endocrine findings*. *Obstet Gynecol*, 1977; 50: 531-535.
  65. Guerrier D, Mouchel T, Pasquier L, Pellerin I: The Mayer-Rokitansky-Kuster-Hauser syndrome (congenital absence of uterus and vagina)--phenotypic manifestations and genetic approaches. *J Negat Results Biomed*, 2006; 5: 1.
  66. Kobayashi A, Behringer RR: Developmental genetics of the female reproductive tract in mammals. *Nat Rev Genet*, 2003; 4: 969-980.
  67. Cramer DW, Goldstein DP, Fraer C, Reichardt JK: Vaginal agenesis (Mayer-Rokitansky-Kuster-Hauser syndrome) associated with the N314D mutation of galactose-1-phosphate uridyl transferase (GALT). *Mol Hum Reprod*, 1996; 2: 145-148.
  68. Timmreck LS, Gray MR, Handelin B, Allito B, Rohlf E, Davis AJ, Gidwani G, Reindollar RH: Analysis of cystic fibrosis transmembrane conductance regulator gene mutations in patients with congenital absence of the uterus and vagina. *Am J Med Genet A*, 2003; 120: 72-76.
  69. Klipstein S, Bhagavath B, Topipat C, Sasur L, Reindollar RH, Gray MR: The N314D polymorphism of the GALT gene is not associated with congenital absence of the uterus and vagina. *Mol Hum Reprod*, 2003; 9: 171-174.
  70. Josso N, Picard JY, Rey R, Clemente N: Testicular Anti-Mullerian Hormone: History, Genetics, Regulation and Clinical Applications. *Pediatr Endocrinol Rev*, 2006; 3: 347-358.
  71. Lindenman E, Shepard MK, Pescovitz OH: Mullerian agenesis: an update. *Obstet Gynecol*, 1997; 90: 307-312.
  72. Resendes BL, Sohn SH, Stelling JR, Tineo R, Davis AJ, Gray MR, Reindollar RH: Role for anti-Mullerian hormone in congenital absence of the uterus and vagina. *Am J Med Genet*, 2001; 98: 129-136.
  73. Van Lingen BL, Reindollar RH, Davis AJ, Gray MR: Further evidence that the WT1 gene does not have a role in the development of the derivatives of the mullerian duct. *Am J Obstet Gynecol*, 1998; 179: 597-603.
  74. Van Lingen BL, Reindollar RH, Davis AJ, Gray MR: Molecular genetic analysis of the PAX2 gene in patients with congenital absence of the uterus and vagina. *Fertil Steril*, 1998; 70: S402 (abstract).
  75. Burel A, Mouchel T, Odent S, Tiker F, Knebelmann B, Pellerin I, Guerrier D: Role of HOXA7 to HOXA13 and PBX1 genes in various forms of MRKH syndrome (congenital absence of uterus and vagina). *J Negat Results Biomed*, 2006; 5: 4.
  76. Peifer M, Polakis P: Wnt signaling in oncogenesis and embryogenesis--a look outside the nucleus. *Science*, 2000; 287: 1606-1609.
  77. Vainio S, Heikkila M, Kispert A, Chin N, McMahon AP: Female development in mammals is regulated by Wnt-4 signalling. *Nature*, 1999; 397: 405-409.
  78. Woolf AS, Cale CM: Roles of growth factors in renal development. *Curr Opin Nephrol Hypertens* 1997; 6:10-14.
  79. Sariola H, Sainio K: Cell lineages in the embryonic kidney: their inductive interactions and signalling molecules. *Biochem Cell Biol*, 1998; 76: 1009-1016.
  80. Saulnier DM, Ghanbari H, Brandli AW: Essential function of Wnt4 for tubulogenesis in the *Xenopus* pronephric kidney. *Dev Biol*, 2002, 248: 13-28.
  81. Biason-Lauber A, Konrad D, Navratil F, Schoenle EJ: A WNT4 mutation associated with Mullerian-duct regression and virilization in a 46,XX woman. *N Engl J Med*, 2004, 351: 792-798.
  82. Biason-Lauber A, De Filippo G, Konrad D, Scarano G, Nazzaro A, Schoenle EJ: WNT4 deficiency--a clinical phenotype distinct from the classic Mayer-Rokitansky-Kuster-Hauser syndrome: A Case Report. *Hum Reprod*, 2006.
  83. Heikkila M, Peltoketo H, Vainio S: Wnts and the female reproductive system. *J Exp Zool*, 2001; 290: 616-623.
  84. Clement-Ziza M, Khen N, Gonzales J, Cretolle-Vastel C, Picard JY, Tullio-Pelet A, Besmond C, Munnich A, Lyonnet S, Nihoul-Fekete C: Exclusion of WNT4 as a major gene in Rokitansky-Kuster-Hauser anomaly. *Am J Med Genet A*, 2005; 137: 98-99.
  85. Horikawa Y, Iwasaki N, Hara M, Furuta H, Hinokio Y, Cockburn BN, Lindner T, Yamagata K, Ogata M, Tomonaga O, Kuroki H, Kasahara T, Iwamoto Y, Bell GI: Mutation in hepatocyte nuclear factor-1 beta gene (TCF2) associated with MODY. *Nat Genet*, 1997; 17: 384-385.
  86. Kolatsi-Joannou M, Bingham C, Ellard S, Bulman MP, Allen LI, Hattersley AT, Woolf AS: Hepatocyte nuclear factor-1beta: a new kindred with renal cysts and diabetes and gene expression in normal human development. *J Am Soc Nephrol*, 2001; 12: 2175-2180.
  87. Bingham C, Bulman MP, Ellard S, Allen LI, Lipkin GW, Hoff WG, Woolf AS, Rizzoni G, Novelli G, Nicholls AJ, Hattersley AT: Mutations in the hepatocyte nuclear factor-1beta gene are associated with familial hypoplastic glomerulocystic kidney disease. *Am J Hum Genet*, 2001; 68: 219-224.

88. Bingham C, Ellard S, Cole TR, Jones KE, Allen LI, Goodship JA, Goodship TH, Bakalinova-Pugh D, Russell GI, Woolf AS, Nicholls AJ, Hattersley AT: Solitary functioning kidney and diverse genital tract malformations associated with hepatocyte nuclear factor-1beta mutations. *Kidney Int*, 2002; 61: 1243-1251.
89. Lindner TH, Njolstad PR, Horikawa Y, Bostad L, Bell GI, Sovik O: A novel syndrome of diabetes mellitus, renal dysfunction and genital malformation associated with a partial deletion of the pseudo-POU domain of hepatocyte nuclear factor1beta. *Hum Mol Genet*, 1999; 8: 2001-2008.
90. Cheroki C, Krepischi-Santos AC, Rosenberg C, Jehee FS, MingroniNetto RC, Pavanello Filho I, Zanforlin Filho S, Kim CA, Bagnoli VR, Mendonca BB, Szuhai K, Otto PA: Report of a del22q11 in a patient with Mayer-Rokitansky-Kuster-Hauser (MRKH) anomaly and exclusion of WNT-4, RAR-gamma, and RXRalpha as major genes determining MRKH anomaly in a study of 25 affected women. *Am J Med Genet A*, 2006; 140: 1339-1342.
91. Bendavid C, Pasquier L, Watrin T, Morcel K, Lucas J, Gicquel I, Dubourg C, Henry C, David V, Odent S, Leveque J, Pellerin I, Guerrier D: Phenotypic variability of a 4q34-->qter inherited deletion: MRKH syndrome in the daughter, cardiac defect and Fallopian tube cancer in the mother. *Eur J Med Genet*, 2007; 50: 66-72.
92. Paniel BJ, Haddad B, el Medjadji M, Vincent Y: [Value of ultrasonography in utero-vaginal aplasia]. *J Gynecol Obstet Biol Reprod (Paris)*, 1996; 25: 128-130.
93. Maubon A, Ferru JM, Courtieu C, Mares P, Rouanet JP: [Gynecological malformations. Classification and contribution of different imaging methods]. *J Radiol*, 1996; 77: 465-475.
94. Carrington BM, Hricak H, Nuruddin RN, Secaf E, Laros RK Jr., Hill EC: Mullerian duct anomalies: MR imaging evaluation. *Radiology*, 1990; 176: 715-720.
95. Troiano RN, McCarthy SM: Mullerian duct anomalies: imaging and clinical issues. *Radiology* 2004, 233:19-34.
96. Carranza-Lira S, Forbin K, Martinez-Chequer JC: Rokitansky syndrome and MURCS association--clinical features and basis for diagnosis. *Int J Fertil Womens Med*, 1999; 44: 250-255.
97. ACOG: ACOG Committee Opinion. Number 274, July 2002. Nonsurgical diagnosis and management of vaginal agenesis. *Obstet Gynecol*, 2002; 100: 213-216.
98. Quint EH, Smith YR: Primary amenorrhea in a teenager. *Obstet Gynecol*, 2006; 107: 414-417.
99. Winter JS, Kohn G, Mellman WJ, Wagner S: A familial syndrome of renal, genital, and middle ear anomalies. *J Pediatr*, 1968; 72: 88-93.
100. King LA, Sanchez-Ramos L, Talledo OE, Reindollar RH: Syndrome of genital, renal, and middle ear anomalies: a third family and report of a pregnancy. *Obstet Gynecol*, 1987; 69: 491-493.
101. Slavotinek AM, Searby C, Al-Gazali L, Hennekam RC, SchrandtStumpel C, Orcana-Losa M, Pardo-Reoyo S, Cantani A, Kumar D, Capellini Q, Neri G, Zackai E, Biesecker LG: Mutation analysis of the MKKS gene in McKusick-Kaufman syndrome and selected Bardet-Biedl syndrome patients. *Hum Genet*, 2002; 110: 561-567.
102. Sultan C, Lumbroso S, Paris F, Jeandel C, Terouanne B, Belon C, Audran F, Poujol N, Georget V, Gobinet J, Jalaguier S, Auzou G, Nicolas JC: Disorders of androgen action. *Semin Reprod Med*, 2002; 20: 217-228.
103. Gardo S, Papp Z, Gaal J: XO-XX Mosaicism in the RokitanskyKuster-Hauser syndrome. *Lancet*, 1971; 2: 1380-1381.
104. Linquette M, Gasnault JP, Dupont-Lecompte J, Hubschman B, Andre A: [Rokitansky-Kuster-Hauser and similar syndromes of uter-vaginal aplasia]. *Rev Fr Endocrinol Clin*, 1968; 9: 41-60.
105. Aydos S, Tukun A, Bokesoy I: Gonadal dysgenesis and the Mayer-Rokitansky-Kuster-Hauser syndrome in a girl with 46,X,del(X)(pter-->q22:). *Arch Gynecol Obstet*, 2003; 267: 173-174.
106. De Leon FD, Hersh JH, Sanfilippo JS, Schikler KN, Yen FF: Gonadal and mullerian duct agenesis in a girl with 46,X,i(Xq). *Obstet Gynecol*, 1984; 63: 81S-83S.
107. Weijenborg PT, ter Kuile MM: The effect of a group programme on women with the Mayer-Rokitansky-Kuster-Hauser syndrome. *Bjog*, 2000; 107: 365-368.
108. Edmonds DK: Congenital malformations of the genital tract and their management. *Best Pract Res Clin Obstet Gynaecol*, 2003; 17: 19-40.
109. Ingram JM: The bicycle seat stool in the treatment of vaginal agenesis and stenosis: a preliminary report. *Am J Obstet Gynecol*, 1981; 140: 867-873.
110. Rock JA, Reeves LA, Retto H, Baramki TA, Zacur HA, Jones HW Jr.: Success following vaginal creation for Mullerian agenesis. *Fertil Steril*, 1983; 39: 809-813.
111. Roberts CP, Haber MJ, Rock JA: Vaginal creation for mullerian agenesis. *Am J Obstet Gynecol*, 2001; 185: 1349-52;1352-3.
112. Davydov SN: [Colpopoeisis from the peritoneum of the uterorectal space]. *Akush Ginekol (Mosk)*, 1969; 45: 55-57.
113. Jackson ND, Rosenblatt PL: Use of Interceed Absorbable Adhesion Barrier for vaginoplasty. *Obstet Gynecol*, 1994; 84: 1048-1050.
114. Motoyama S, Laoag-Fernandez JB, Mochizuki S, Yamabe S, Maruo T: Vaginoplasty with Interceed absorbable adhesion barrier for complete squamous epithelialization in vaginal agenesis. *Am J Obstet Gynecol*, 2003; 188: 1260-1264.
115. Borruto F, Chasen ST, Chervenak FA, Fedele L: The Vecchietti procedure for surgical treatment of vaginal agenesis: comparison of laparoscopy and



- laparotomy. *Int J Gynaecol Obstet*, 1999; 64: 153-158.
116. Freundt I, Toolenaar TA, Huikeshoven FJ, Drogendijk AC, Jeekel H: A modified technique to create a neovagina with an isolated segment of sigmoid colon. *Surg Gynecol Obstet*, 1992; 174: 11-16.
117. Louis-Sylvestre C, Haddad B, Paniel BJ: Creation of a sigmoid neovagina: technique and results in 16 cases. *Eur J Obstet Gynecol Reprod Biol*, 1997; 75: 225-229.