

**TORSION OF HEALTHY ADNEXA IN THE SECOND TRIMESTER OF PREGNANCY: A
CASE REPORT****Dr. Soukaina Cherradi*, Imane Benmouna, Mariam Mahtate, Amina Lakhdar, Najia Zerai, Aziz Baidada**Department of Obstetric Gynecology and Endoscopy, Souissi Maternity Hospital, Ibn Sina University Hospital,
Mohammed V University, Rabat, Morocco.***Corresponding Author: Dr. Soukaina Cherradi**Department of Obstetric Gynecology and Endoscopy, Souissi Maternity Hospital, Ibn Sina University Hospital, Mohammed V University,
Rabat, Morocco.

Article Received on 12/01/2022

Article Revised on 02/02/2022

Article Accepted on 22/02/2022

ABSTRACT

Adnexal torsion is a rare pathology secondary to total or partial rotation of the adnexa around its vascular axis. The occurrence of adnexal torsion on a healthy ovary is an even rarer situation. Its diagnosis during pregnancy is complex because it requires the elimination of the classic differential diagnoses (appendicitis, cholecystitis, pyelonephritis or pancreatitis) but also those that may be related to the pregnancy (miscarriage, retroplacental hematoma, uterine rupture). The interest of this situation lies in its diagnostic difficulty, and in the choice of the adequate therapeutic approach. We present the case of an adnexal torsion on a healthy ovary in the second trimester of pregnancy.

KEYWORDS: Adnexal torsion, Healthy adnexa, Pregnancy.**INTRODUCTION**

Adnexal torsion is a rare pathology secondary to total or partial rotation of the adnexa around its vascular axis. The occurrence of adnexal torsion on a healthy ovary is an even rarer situation.^[1] The proportion of adnexal torsion occurring during pregnancy varies from 13 to 28% and its frequency is estimated at 1/5000 pregnancies (7 cases per 1000 pregnancies in the case of an associated adnexal mass). It can occur during all three trimesters of pregnancy, although the increase in size of the uterus in the 2nd and 3rd trimesters reduces the mobility of the adnexa. Ischemia is a direct consequence of the torsion and may progress to necrosis if left untreated. This necrosis will cause loss of the ovary or adnexa and may reduce subsequent fertility in young patients.^[3] More rarely, adnexal torsion can cause potentially lethal complications through necrosis and cytokine release that can lead to pelvic thrombophlebitis or peritonitis.^[4] However, the diagnosis remains difficult, due to differential diagnoses with other surgical emergencies such as acute appendicitis, cholecystitis or acute pyelonephritis. The interest of this situation lies in its diagnostic difficulty, and in the choice of the appropriate therapeutic approach. We present the case of an adnexal torsion on a healthy ovary in the second trimester of pregnancy.

CLINICAL CASE

Mrs L.T, 28 years old, G2P, with no notable medical or surgical pathological history, having a regular cycle with

notion of taking oral contraception for 2 years stopped 5 months before conception. The course of the pregnancy was until then without particularity. She consulted the emergency room for right lateropelvic pain that had been evolving for 20 hours and was resistant to level I/II analgesics. The pain was continuous, of high intensity, of permanent torsion, with hypogastric irradiation, without any analgesic position and associated with two episodes of vomiting during an amenorrhea of 21 weeks. The admission examination found a conscious patient with a GCS 15, a VAS of 10. Hemodynamically and respiratory stable: BP: 12/7mmhg, HR: 90 bpm, RF: 15 C/min, afebrile T: 37. The abdominal examination found a right latero-uterine defense. The obstetrical examination was normal. The biological assessment was normal. Ultrasound (suprapubic and endovaginal) was in favor of an evolving monofetal pregnancy with biometrics corresponding to the term of the pregnancy, normally inserted fundal placenta and a normal quantity of amniotic fluid. A slightly heterogeneous echogenic image with anechoic areas of 78x53mm was present in the right latero-uterine area without taking Doppler scan, suggesting a large twisted ovary. The patient underwent a Pfannenstiel-type laparotomy. We noted during exploration the presence of a thin effusion blade, an enlarged uterus with unremarkable left adnexa. The right adnexa was necrotic (Figure 1), twisted by 3 turns of spiral, with no individualizable cystic mass and an elongated right utero-ovarian ligament. The appendix was macroscopically normal. The decision was therefore to perform a right adnexectomy with contralateral

oophoropexy. Pathological analysis of the adnexa revealed only a corpus luteum without cyst. Post-operative aftercare is uncomplicated with the disappearance of pain. However, we started a tocolytic

treatment and delayed progesterone. An ultrasound monitoring performed after 3 weeks found that pregnancy is still evolving.

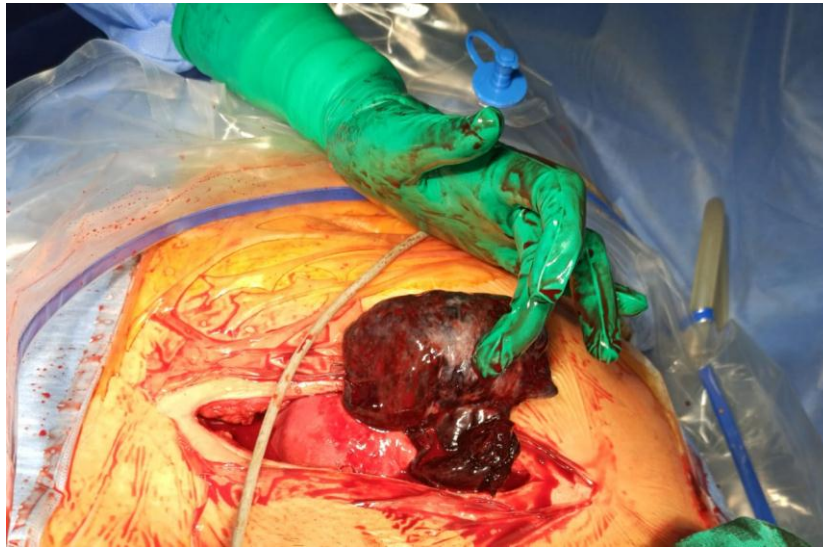


Figure 1: Intraoperative image showing adnexal torsion with ovarian necrosis.

DISCUSSION

Adnexal torsion is a fairly rare entity that occurs in pregnancy in only 13-28% of cases.^[2] In this case, either the adnexal mass pre-exists the pregnancy or it appears and develops during the pregnancy.^[5] In the first case, it is most often an ovarian mass of an organic nature, whereas in the second case, the functional nature is evoked all the more so when it appears in the context of medically assisted procreation and disappears spontaneously before the sixteenth week of pregnancy.^[6,7,8]

The clinical diagnosis of adnexal torsion during pregnancy is usually based on sharp and sudden lateralized pain associated with nausea or vomiting and a known adnexal mass. Its diagnosis during pregnancy is complex because it requires the elimination of classical differential diagnoses but also those that may be related to the pregnancy (miscarriage, retroplacental hematoma, uterine rupture). From the second trimester on, the absence of defense is possible, as the adnexa are located behind the gravid uterus. Torsion is most often predominant on the right side and is favored by benign lesions of the ovary,^[8] or utero-ovarian ligament malformations and their excessive length,^[4] In our patient a long utero-ovarian ligament was found.

The biological assessment is not specific, there may be a hyperleukocytosis or an increase in C-reactive protein, indicating an inflammatory process.

Ultrasound, even if it is poor in positive signs of torsion, remains the reference examination. It allows the elimination of differential diagnoses, and to investigate for factors that may promote torsion as well as indirect

signs of ischemia. Interruption of venous flow leads to reactive oedema which can be identified by the increase in ovarian volume compared to the contralateral adnexa.^[9,10] Moreover, the increase in the number of cortical follicles is a non-specific aspect but has been repeatedly found in the case of torsion on healthy ovaries. MRI is a satisfactory complementary exploration technique in pregnant women, which has a greater accuracy than ultrasound.^[11] The combination of Doppler and MRI allows a better diagnostic approach but should not delay surgical management.

Adnexal torsion is a real surgical emergency. In the first trimester of pregnancy the laparoscopic approach is recommended. It allows most of the therapeutic procedures on the adnexa.^[2,5] Our patient was in the second trimester with a significant uterine height and therefore taking risks with a laparoscopic approach. Laparotomy remains the recommended technique for such a gestational age.

The therapeutic action depends on the appearance of the twisted adnexa. For stages 1 and 2 (lesions with total or partial recovery after detorsion), conservative treatment is recommended, allowing functional recovery in 90% of cases. For a stage 3 (necrotic, black and friable lesions without recovery after detorsion), adnexectomy appears preferable. In our patient, an immediate non-conservative attitude is justified by the total necrosis of the adnexa. Ovariopexy is proposed by some authors to prevent recurrence of adnexal torsion. The recognized indications are a malformation or lengthening of the utero-ovarian ligament, torsion on a single adnexa or contralateral pexy in the case of adnexectomy of the twisted adnexa,^[4] and this is what was done in our patient.

CONCLUSION

The diagnosis of adnexal torsion in pregnancy is rare and difficult, especially in the presence of a healthy adnexa. The clinical symptoms are not very specific, and paraclinical examinations are not very reliable for the positive diagnosis, but they have a place in eliminating differential diagnoses and searching for an adnexal pathology. Surgical treatment should be conservative as much as possible except in cases of irrecoverable necrosis of the adnexa. The prognosis in pregnancy is generally favorable, although some cases of growth retardation and premature delivery have been described.

Conflicts of interest

The authors declare no conflicts of interest.

Author Contributions

SC contributed substantially to the conception and design, data acquisition, analysis and interpretation of the data, participated in the drafting of the manuscript and critically reviewed it for important intellectual content. IB, MM, AL, NZ, AB contributed substantially to the interpretation of the data, drafting of the manuscript, and critically reviewed it for its important intellectual content. All authors read and approved the final version of the manuscript.

REFERENCES

1. Guennoun Ahmed; Krimou Yousra; Mamouni Nisrine; Errarhay Sanaa; Bouchikhi Chahrazed; et al. The Pan African Medical Journal; Kampala, 2017; 27. DOI:10.11604/pamj.2017.27.197.12250.
2. A.Mattuzzi C.Camberlein F. Coatleven J.Horovitz Journal de Gynécologie Obstétrique et Biologie de la Reproduction, 2016; 45(1): 92-93.
3. Huchon C, Fauconnier A. Adnexal torsion: a literature review. Eur J Obstet Gynecol Reprod Biol., 2010; 150(1): 8-12.
4. Cyrille Huchon*, Arnaud Fauconnier Torsion d'annexe : une urgence porteuse de risque. La Lettre du Gynécologue, 2012.
5. Fouedjio JH, Fouogue JT, Fouélifack FY, Nangue C, Sando Z, Mbu RE. Torsion d'annexe en cours de grossesse : à propos d'un cas à l'Hôpital Central de Yaoundé, Cameroun. Pan Afr Med J. janv, 2014; 17: 1-5.
6. Hasiakos D, Papakonstantinou K, Kontoravdis A, Gogas L, Aravantinos L, Vitoratos N. Adnexal torsion during pregnancy: Report of four cases and review of the literature. J Obstet Gynaecol Res. Août, 2008; 34(4pt2): 683-7.
7. Schwartz N, Timor-Tritsch IE, Wang E. Adnexal Masses in Pregnancy: Clin Obstet Gynecol. Déc, 2009; 52(4): 570-85.
8. Schmeler KM, Mayo-Smith WW, Peipert JF, Weitzen S, Manuel MD, Gordinier ME. Adnexal Masses in Pregnancy: Surgery Compared With Observation: Obstet Gynecol. Mai, 2005; 105(5, Part 1): 1098-103.
9. Graif M, Shalev J, Strauss S, Engelberg S, Mashiach S, Itzhak Y. Torsion of the ovary: sonographic features. AJR Am J Roentgenol, 1984; 143(6): 1331-4. PubMed | Google Scholar
10. Pansky M, Smorgick N, Herman A, Schneider D, Halperin R. Torsion of normal adnexa in postmenarchal women and risk of recurrence. Obstet Gynecol, 2007; 109(2 Pt 1): 355-9. PubMed Google Scholar
11. Mage G, Canis M, Manhes H, Pouly JL, Bruhat MA. Laparoscopic management of adnexal torsion: a review of 35 cases. J Reprod Med, 1989; 34(8): 520-4. PubMed | Google Scholar