wjpmr, 2021,7(10), 191-197

SJIF Impact Factor: 5.922

WORLD JOURNAL OF PHARMACEUTICAL AND MEDICAL RESEARCH

www.wjpmr.com

Case Report

ISSN 2455-3301

WJPMR

CASE REPORT: SCORPION STING POISONING, MYOCARDITIS ASSOCIATED LV DYSFUNCTION AND PULMONARY EDEMA

Sahithi Maroju* and Dr. K. Krishna Sumanth

Telangana India.

***Corresponding Author: Sahithi Maroju**

Telangana India.

Article Received on 12/07/2021 **Article Revised on 02/08/2021** **Article Accepted on 22/08/2021**

ABSTRACT

A 19 years female presented with alleged h/o scorpion bite on left index finger on 27/10/19. The occurrence of a myocarditis following a scorpion sting has been very rarely reported. Patient was bought with shortness of breath and orthopnea. After admission she was found to have Global hypokinesia and severe left ventricular dysfunction. Vitals are checked and recorded. Investigations are done. She was also evaluated with Complete blood picture, Liver function tests, Sr. Creatinine. In view of tachypnea and shortness of breath and decreasing saturations further managed with non-Invasive Ventilation. She was discharged in stable condition at request with following advice. Few tests were done like X-RAY Chest on 29/10/19; 31/10/19; 01/11/19 and USG Abdomen Whole on 29/10/19.

KEYWORDS: Scorpion bite, ventricular dysfunction, hypokinesia.

INTRODUCTION

The greater part of the scorpion sting cases is intense dangerous and time-restricting health related crises. Scorpion chomps are normal in our country, especially in the rustic regions.[1] Among 86 types of scorpions present in India. Cardiovascular appearances are especially conspicuous after stings by Indian red scorpion.[2] Such chomps inconsistently have genuine clinical sequelae, including myocardial infraction, intense aspiratory edema (acute pulmonary edema).[3] cardiogenic shock,[4] and even demise. We present thus a case report with the clinical appearances following scorpion chomp impersonating intense myocardial dead tissue related with left ventricular dysfunction and S/P vasopressor. The etiology of the cardiovascular indications in extreme scorpion sting is identified with the toxin impacts,[5] on the thoughtful sensory system and the adrenal discharge of catecholamines just as to the poisonous impacts of the toxin on the myocardium,[6,7] It impacts of scorpion toxin on the cardiovascular framework are not surely known.[8,9,10,11,12]

CASE PRESENTATION

On October 27, 2019, a 19-year-old Indian girl was hospitalized after having been bitten by a scorpion at 5:00pm on the Sunday evening i.e., one hour prior to the admission. At presentation, she was bought with shortness of breath and orthopnea. Physical examinations revealed a mildly distressed patient was conscious and oriented. She had no pallor, no Icterus, no Cyanosis, no clubbing, no pedal edema, no lymphadenopathy. The injured index finger of the left hand, the site of the bite, was mildly swollen and tender.

Table-1: Microbiology lab results.

S.no	Microbiology lab tests	Results
1	Nature of specimen	Blood
2	Blood for culture	Aerobic
3	Methodology	Automated culture (Bactee)
4	Culture	E=" light list accent 4"/>
5	2nd no growth	No growth after 48 hours of incubation

Table-2: The Radiology lab results.

S.no	Organs	Dates		
		29/10/2019	31/10/2019	01/11/2019
1	Lungs	I'll defined non homogenous opacities noted in bilateral mid and lower zones.	Clear	Clear
2	Bilateral domes& Cp angles	Normal	Normal	Normal
3	Trachea	Central	Central	Central
4	Bones	Normal	Normal	Normal
5	Soft tissues	normal	normal	normal

Table-3: Results of The Sonology lab records.

S.no	Organs	Results
1	Liver	Mildly increased in size with normal parenchymal echotexture. No IHBRD. Portal vein is normal.
2	Gall bladder	Partially distended. Wall thickness is normal. No pericholecystic collection. CBD not commentable.
3	Spleen	Mildly increased in size and normal echotexture.
4	Pancreas	Head& body appears normal. Tail not visualized. No evidence of calculi/calcification/peripancreatic fluid collections.
5	Kidneys	Normal in size and echotexture. No evidence of calculi/ hydronephrosis.
6	Urinary bladder	Empty with foleys bulb insitu
7	Pelvis	Not commentable

The total impression showed Mild Hepatosplenomegaly.

The laboratory data revealed leukocytosis of 23,000 with 75 percent neutrophils. The serum electrolytes, liver function tests and serum proteins were normal. The serum glutamic oxalacetic transaminase (SGOT) was 26 units, and the serum glutamic pyruvic transaminase (SGPT), 15 units. The electrocardiogram was taken on admission showed sinus tachycardia of 145/min.

Patient condition has been explained to patient relatives i.e., scorpion bite and its released complications, morbidity and mortality, need for investigations and necessary managements in their own language.

Day-1: Alleged history of scorpion bite on Sunday evening. She had swelling and pain. Her general appearance was emaciated and was vulnerable. On Physical examination the patient was conscious and coherent. She was kept on oxygen. Cardiovascular DVT score was zero. Gastro- Urinary I/O Chart intake was noted to be 370; and output was 2210ml. Presented with Foleys catheter. Gastro intestinal bowel sounds and movements were present. Endocrinological GRB was 6th hourly. Dermatological skin intact was seen. Braden pressure risk score was 16. Musculo-skeletal data revealed ambulant with assistance. She was educated with the content on fluid restriction on cardiac condition. Referred to perform USG abdomen. Reassessment at the end of the shift concluded she was tachypneic.

Table-4: Vitals recorded on day 1.

S.no	Vitals	
1	Temperature	Febrile, 99.80F
2	Heart rate	94 bpm
3	Respiratory rate	26 breaths per minute
4	spo2	98%

Day-2: Declared that patient was diagnosed with scorpion sting bite; myocarditis associated Severe dysfunction and pulmonary edema. MEWS score was 2. Bilateral crypts were decreased. No pedal edema has seen. She was on NIV. Cardiovascular capillary time refill time was <2sec and DVT score was 0.8. Gastro-Urinary I/O Chart intake was noted to be 406.6; and output was 290ml. Presented with Foleys catheter. No GI bowel sounds and movements were recorded. Endocrinological GRB was 6th hourly. Dermatological skin intact was seen. Her appetite was good and was on normal diet. Musculo-skeletal data revealed ambulant with assistance. VIP score was zero and no thrombophlebitis was seen. Observed saturation levels and administered medications. Patient was educated on health about NIV. Referred to perform thyroid profile and USG abdomen.

Table-5: Day-2 vitals recordings.

S.no	Vitals	
1	Blood pressure	106/73 mm/hg
2	Pulse rate	113bpm
3	Respiratory rate	40bpm
4	Temperature	98.4F
5	Pain score	1/10
6	Spo2	99%

Day-3: She was hemodynamically monitored and tachypnea decreased. GCS score was 15/15. She was kept on oxygen. She was recommended to take coconut water thrice a day. Per abdomen results were soft. Cardiovascular capillary time refill time was <2sec and DVT score was zero. Gastro- Urinary I/O Chart intake was noted to be 714.6; and output was 546ml. Presented with Foleys catheter. Bowels sounds were present but bowel movements were absent. Endocrinological GRB was 8th hourly. Dermatological skin intact was seen, Braden pressure risk score was 16. USG abdomen and pelvis test was done. Patient was educated regarding the need of NIV.

Table-6: Day-3 vitals recordings.

S.no	Monitored Vitals	
1	Blood pressure	112/69 mm/hg
2	Temperature	98F
3	Pulse rate	87bpm
4	Respiratory rate	22bpm
5	Pain score	1/10
6	Spo2	98%

Day-4: Patient was conscious and coherent on examination. She was well nourished. Shortness of breath decreased. GCS score was 15/15. Cardiovascular capillary time refill time was <2sec and DVT score was zero. Gastro- Urinary I/O Chart intake was noted to be 750; and output was 890ml. Presented with Foleys catheter. Bowels sounds were present but bowel movements were absent. Endocrinological GRB was 6th hourly. Dermatological skin intact was seen, Braden pressure risk score was 16. Observed saturations. GRBS checked and medications were given as per chart.

Table-7: Day 4 monitored vitals.

S.no	Monitored Vitals	
1	Blood pressure	100/70 mm/hg
2	Temperature	98F
3	Pulse rate	77bpm
4	Respiratory rate	22bpm
5	Pain score	1/10
6	Spo2	98%

Day-5: Patient was conscious and coherent. Blood culture showed no growth. Shortness of breath subside. Gastro- Urinary I/O Chart intake was noted to be 777; and output was 890ml. Presented with Foleys catheter. Gastro intestinal bowel sounds and movements were present. Endocrinological GRB was 8th hourly. Dermatological skin intact was seen, Braden pressure risk score was 15. Psychological data revealed she was bit anxious. Observed saturations. GRBS checked and medications were given as per chart.

Table-8: Day 5 monitored vitals.

S.no	Monitored Vitals	
1	Blood pressure	98/60 mm/hg
2	Temperature	Afebrile
3	Pulse rate	99bpm
4	Respiratory rate	22bpm
5	Pain score	1/10
6	Spo2	98%

Day-6: Patient's general condition was better. Done 2D echo. Fluid restriction was given 1.2Lit/day. She was shifted to room air. Cardiovascular capillary time refill time was <2sec and DVT score was 0.1. Gastro- Urinary I/O Chart intake was noted to be 360.6; and output was 415ml. Presented with Foleys catheter. Bowels sounds were present but bowel movements were absent. Endocrinological GRB was 6th hourly. Dermatological skin intact was seen, Braden pressure risk score was 17. Nasal prones were removed. GRBS checked. Administered medications as per chart. Patient was educated about personal hygiene. 2D echo it was completed. Intake and output were strictly monitored and recorded.

Table-9: Day-6 monitored vitals.

S.no	Monitored Vitals	
1	Blood pressure	98/60 mm/hg
2	Temperature	98F
3	Pulse rate	88bpm
4	Respiratory rate	22bpm
5	Pain score	1/10
6	Spo2	98%

Day-7: Patient's general appearance was emaciated and was vulnerable. Temperature- 98.8F; Pulse rate was 72bpm; Respiratory rate was 22breaths per minute. Blood pressure was noted to be 90/60. Pain score was 1/10; SPO2 was 98%. MEWS score was 02. GCS score was E4V5M6. She was shifted to room air. Cardiovascular capillary time refill time was <2sec and DVT score was 0.1. Gastro- Urinary I/O Chart intake was noted to be 400; and output was 1030ml. Presented with Foleys catheter. Bowels sounds were present but bowel movements were absent. Endocrinological GRB was 6th hourly. Dermatological skin intact was seen, Braden pressure risk score was 17. 2D echo was done. Patient was educated regarding limb exercises.

Table-10: Day 6 monitored vitals.

S.no	Monitored Vitals	
1	Blood pressure	90/60 mm/hg
2	Temperature	98F
3	Pulse rate	88bpm
4	Respiratory rate	22bpm
5	Pain score	1/10
6	Spo2	98%
7	MEWS score	02

Medications

She was treated with the proper treatment plan.

Table-11: Drug Medication chart.

S. no.	Drug	Generic name	Use	Frequency	Route	Dose
1	Inj. Tazact	Piperacillin/Tazobactam	It is utilized to treat different kinds of bacterial diseases.	BID (twice a day)	IV	4.5g
2	Inj. Optineuron	Thiamine (vitaminB1)	It is a combination of nutritional supplements and nourishing insufficiencies just as nutrient B12 deficiency.	BID	IV	2amp
3	T. Mucinac	Acetylcysteine	It is utilized in the treatment of paracetamol overdose. It ensures your liver and assists with diminishing the degree of the injury.	BID	PO	600mg
4	T Carnitol	Levocarnitine	It is used to prevent and treat low blood levels of carnitine.	BID	PO	500mg
5	T. Carvidon	Trimetazidine	It prevents new assaults of angina however doesn't stop an intense assault whenever it has begun.	BID	PO	35mg
6	T. Dulcolax	Bisacodyl	It is used to treat constipation. It might likewise be utilized to clear out the digestion tracts before a gut assessment/medical procedure.	Before sleep at night	PO	
7	T. Lanoxin	Digoxin	It is used to treat arrhythmias and heart failure.	5-7times a day	PO	0.25mg
8	T. Shelcal	Cholecalciferol (vitaminD3)	It is ordinarily utilized for the finding or treatment of dietary enhancement, bones weaking, acridity, acid reflux, stomach ulcer. It has some incidental effects like clogging, migraine, loss of craving, retching.	OD (once daily)	PO	500mg
9	T. Mega 10	Co-enzyme Q10	It is a multivitamin and iron item used to treat or forestall nutrient lack because of less than stellar eating routine, certain diseases, or pregnancy.	OD	PO	
10	Inj. Fondared	Fondaparinux	It is used to prevent and treat profound vein apoplexy and aspiratory embolism, stroke, unsteady angina, coronary episodes.	OD	SC	2.5mg
11	Inj. Zofer	Ondansetron	It utilized in the avoidance of spewing and sickness that typically happen after malignancy chemotherapy, radiation therapy or medical procedure.		IV	8mg
12	Syp. Duphalac	lactulose	It works by expanding the measure of water and stool mass in the inside, advancing typical entrail action.		PO	30ml

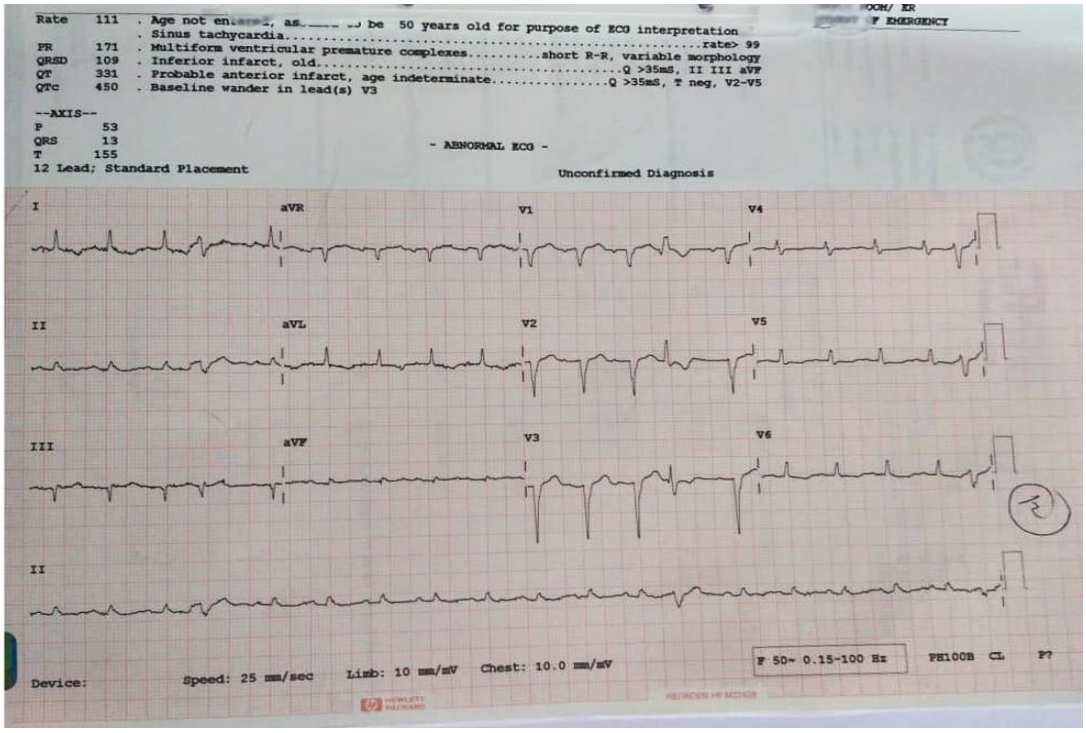

Fig. 1: Electrocardiogram showing left ventricular dysfunction; observed Tachycardia during echo. Left ventricle is mildly dilated. Normal sized RA/RV/LA. LV- EF:22%.

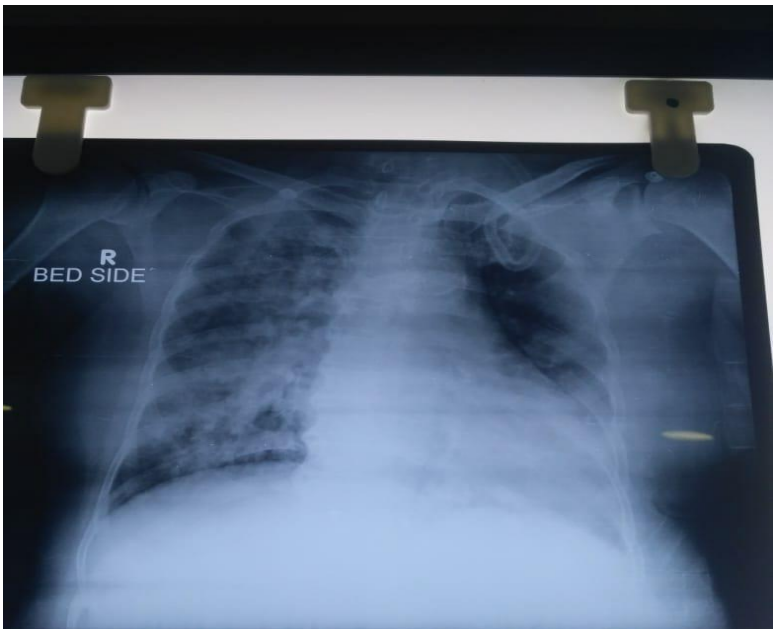

Fig. 2: Chest AP X-RAY bed side view seen with pulmonary edema.

DISCUSSION

Scorpion stings are painful but rarely life-threatening. The etiology of cardiovascular indications in serious scorpion sting is identified with toxin impact on thoughtful sensory system and the adrenal discharge of catecholamines just as to the poisonous impact of the toxin on the actual myocardium.

Direct cardiotoxic impact of the toxin causing harmful myocarditis by decrease of Na-K-ATPase and adrenergic myocarditis by delivering adrenaline and noradrenaline from neurons, ganglia and adrenals, in this manner expanding myocardial oxygen interest by direct inotropic and chronotropic impact on as of now compromised myocardial blood supply.

Cardiologist opinion was taken and evaluated with 2D echo and drop t in casuality and found to have global hypokinesia and severe left ventricular dysfunction with positive trop t values. Started on Inj. Noradrenaline, Inj. Dobutamine infusion, Inj. Lasix, Tab. Digoxin. Further evaluated with complete blood picture, liver function

tests, sr. creatinine, and started on Inj. Penicillin + Tazobactam in v/o increased WBC count [15800/mm3]. In view of tachypnea and shortness of breath and decreasing saturations further managed with non-invasive ventilation. Gradually shortness of breath subsides dobutamine and noradrenaline weaned, blood pressure improved and is being discharged in stable condition at request with following advice.

Scorpions tend to avoid contact. If you are in an area where scorpions are common, prevent chance of contact by the following:

- Keep grass firmly cut, and prune hedges and overhanging tree limbs, which can give a way to your rooftop for scorpions.
- Inspect and shake out planting gloves, boots and apparel that haven't been utilized for some time.

When going in regions where deadly scorpions are normal particularly in case you're exploring the great outdoors or remaining in natural facilities destroy shoes and shake your dress, sheet material, stuff and bundles regularly.

Scorpions gleam under a dark light, so you should utilize one around evening time to review your environmental factors. In the event that you discover a scorpion, use utensils to delicately move it away from individuals.

CONCLUSION

In the event that a scorpion stings you or your kid, follow the ideas underneath. Sound grown-ups may not require further treatment, and these tips can assist with guarding kids until they see a specialist:

- Clean the injury with gentle cleanser and water.
- Apply a cool pack to the influenced region. This might assist with decreasing torment.
- Don't burn-through food or fluids in case you're experiencing issues gulping.
- Take an over-the-counter pain killer depending on the situation.

Myocarditis might prompt indications of cardiovascular breakdown, where your heart experiences difficulty siphoning blood the manner in which it ought to. In uncommon cases, it prompts different issues. There are no means to prevent myocarditis, however staying away from genuine contaminations might help.

Abbreviations

- LV Dysfunction- Left Ventricular Dysfunction
- USG Abdomen- Ultrasonogram Abdomen
- IHBRD- Intra Hepatic Biliary Radicle Dilatation.
- CBD- Common Bile Duct
- SGOT- serum glutamic-oxaloacetic transaminase.
- SGPT- serum glutamic-pyruvic transaminase
- DVT- Deep Vein thrombosis.
- GRB – General Random Blood Sugar
- MEWS Score- Modified Early Warning Score
- NIV- Non-invasive ventilation.
- VIP- Vasoactive Intestinal Peptide.
- GCS score- The Glascow Coma Scale.

ACKNOWLEDGEMENT

Though only our names appear on the cover of this dissertation, many people have contributed to its production. However, it would not have been possible without the kind support and help of many individuals and organizations. We would like to extend our sincere thanks to all of them. Foremost, thankful to other faculty for the continuous support to our study and research on this case study for his patience, motivation, enthusiasm and immense knowledge, their guidance helped us in all the time of research and writing of this case reports. We would like to express our special gratitude and thanks to Gleneagles Aware global hospital staff for giving us such attention and time for this study.

REFERENCES

1. Warrell DA. Venomous Bites, Stings, and Poisoning: An Update. Infect Dis Clin North Am [Internet], 2019; 33(1): 17–38. Available from: https://doi.org/10.1016/j.idc.2018.10.001 https://europepmc.org/article /med/22632635.
2. Agrawal A, Kumar A, Consul S, Yadav A. Scorpion bite, a sting to the heart! Indian J Crit Care Med, 2015; 19(4): 233–6. https://www.ncbi.nlm.nih.gov /pmc/articles/PMC4397632/.
3. Maheshwari M, Tanwar CP. Scorpion sting-induced myocardial damage and pulmonary oedema. Journal, Indian Acad Clin Med, 2012; 13(3): 239–41. https://pesquisa.bvsalud.org/portal/resource/pt/sea-145716.
4. Abdi A, Farshidi H, Rahimi S, Amini A, Tasnim Eftekhari SF. Electrocardiologic and echocardiographic findings in patients with scorpion sting. Iran Red Crescent Med J., 2013; 15(5): 446–7. http://eprints.hums.ac.ir/5159/.
5. Patra S, Satish K, Singla V, Ravindranath KS. Acute myocardial infarction following scorpion sting in a case with obstructive coronary artery disease. BMJ Case Rep., 2013; 1–4. https://casereports.bmj.com /content /2013/bcr-2013-009865.short.
6. Horen WP. Insect and Mite, 2015; 1(655). https://www.cabdirect.org/cabdirect/abstract/199113 70967
7. H b -82 ~ to total leucocyte count. :1–5. https://jcp.bmj.com/content/34/2/163.abstract.
8. Naik R, Sciences N. Scorpion Sting - A Rare Cause of Stroke in the Young, 1996; https://nimhans.ac.in /wp-content/uploads/2020/10/2.-Scorpion-Sting-A-Rare-Cause-of-Stroke-in-the-Young_89-92.pdf.
9. Gueron M, Stern J, Cohen W. Severe myocardial damage and heart failure in scorpion sting. Report of five cases. Am J Cardiol, 1967; 19(5): 719–26. https://pubmed.ncbi.nlm.nih.gov/6023468/.
10. El-Amin EO, Elidrissy A, Hamid HS, Sultan OM, Safar RA. Scorpion sting: A management problem.

Ann Trop Paediatr. 1991; 11(2): 143–8. https://www.tandfonline.com/doi/abs/10.1080/02724936.1991.11747493

11. Pourahmad M, Sepidkar A, Farokhnia MH, Tadayon SMK, Salehi H, Zabetian H. Mucormycosis after scorpion sting: Case report. Mycoses. 2013; 56(5): 589–91. https://onlinelibrary.wiley.com/doi/abs/10.1111/myc.12066
12. Singhal A, Mannan R, Rampal U. Epidemiology, clinical presentation and final outcome of patients with scorpion bite. J Clin Diagnostic Res., 2009; 3(3): 1523–8. https://www.researchgate.net/profile/Rahul-Mannan/publication/245023906_Epidemiology_clinical_presentation_and_final_outcome_of_patients_with_scorpion_bite/links/02e7e51d5c27c1b967000000/Epidemiology-clinical-presentation-and-final-outcome-of-patients-with-scorpion-bite.pdf.