wjpmr, 2021,7(9), 147 – 173.

SJIF Impact Factor: 5.922

WORLD JOURNAL OF PHARMACEUTICAL AND MEDICAL RESEARCH

www.wjpmr.com

Research Article

ISSN 2455-3301

WJPMR

COMPARATIVE STUDY ON OUTCOMES FOLLOWING ILEOSTOMY VERSUS COLOSTOMY FOR DEFUNCTIONING COLORECTAL ANASTOMOSIS.

[1]Dr. Saravanakumar, [2]Dr. S. Velavan and [3]*Dr. P. Isakkirajan

[1]MS., DA, Associate professor of General Surgery, Government Sivagangai Medical College, Sivagangai.
[2]MS, Post-graduate in Department of General Surgery, Madurai Medical College, Madurai.
[3]Post-Graduate in Department of General Surgery, Madurai Medical College, Madurai.

***Corresponding Author: Dr. P. Isakkirajan**
Post-Graduate in Department of General Surgery, Madurai Medical College, Madurai.

Article Received on 07/06/2021 **Article Revised on 28/06/2021** **Article Accepted on 18/07/2021**

INTRODUCTION

- Colonic intestinal obstruction can be mechanical or non mechanical.
- Operative interventions are done for mechanical causes of obstruction such as

1) volvulus,
2) intussusceptions,
3) malignancy,
4) diverticulitis,
5) stricture.

- Loop stomas are commonly used to temporarily defunction distal colorectal anastomosis, but there are complications associated with the stoma.
- Either a loop ileostomy or a loop transverse colostomy can be used to defunction a low colorectal anastomosis.
- Controversy still exists in choosing between loop ileostomy and loop transverse colostomy for defunctioning colorectal anastomosis.
- This study is a prospective comparision of loop transverse colostomy and loop ileostomy.

AIMS AND OBJECTIVES

AIM OF THE STUDY

- To compare the outcomes following ileostomy and colostomy for defunctioning colorectal anastomosis in GRH, Madurai

OBJECTIVES OF THE STUDY

- To come to a conclusion whether to choose loop ileostomy or transverse loop colostomy for defunctioning colorectal anastomosis.

REVIEW OF LITERATURE

Small intestine

Small intestine is the longest organ in the Gastrointestinal tract. Its main function is in absorption of nutrients, water & electrolyte homeostasis, act as an immunological barrier and secretory function.

Embryology[1]

During 4th week of gestation, embryonic endoderm forms gut tube which consists of foregut, mid gut and hindgut. Distal duodenum, jejunum and ileum arise from midgut. Endoderm gives rise to epithelium, whereas muscle and peritoneal components arise from splanchnic mesoderm.

Anatomy[2]

Starting from pylorus till ileo-caecal valve small intestine is approximately 7 metres in length. It is divided into 3 parts: duodenum, jejunum & ileum. Majority of the duodenum is retroperitoneal in location whereas jejunum & ileum are intra peritoneal.

Wall of Small intestine contains 4 layers: mucosa, sub mucosa, muscularis propria & serosa.

1. Mucosa

- innermost layer
- Main function – absorption of nutrients & water
- Contains 3 separate layers: epithelium, lamina propria & muscularis mucosae.
- Contains finger like projections called- villi, which increase the absorptive area by 10-fold
- Villi are longest in the duodenum – where most of the digestion and absorption occurs and shortest in distal ileum.

2. Sub mucosa

- 2nd layer
- composed of dense connective tissue and is the strength layer of GIT
- Blood vessels and lymphatics, including Peyer patches are found in this layer
- The Meissner, or submucosal plexus, located in this layer is an integral part of Enteric nervous system

which regulates bowel motility and secretion from mucosal glands

3. Muscularis propria
- smooth muscle layer composed of an outer longitudinal layer and inner circular layer
- Myenteric or Auerbach plexus located between these 2 layers of muscularis propria and control gut motility & secretions of glands.

4. Serosa.
- Outermost layer
- Made up of single layer of mesothelial cells.

Duodenum

- 1st part of small intestine, extending from pylorus till ligament of trietz[1]
- It is approximately 25 cms in length and is mostly retroperitoneal in location
- It is divided in to 4 parts.

1. Bulb -1st part
2. Descending- 2nd part
3. Transverse – 3rd part
4. Ascending – 4th part

- 1st part.
- begins at the pylorus, and is approximately 5 cm.
- Posteriorly related to gastroduodenal artery (GDA), common bile duct, and portal vein.
- Hepatoduodenal ligament connects 1st part of duodenum superiorly to porta hepatis
- It is related to pancreas inferiorly.

- 2nd part.
- The second part is retroperitoneal in location and is of nearly 10 cms long.
- Posteriorly it is related to right kidney and ureter and the lateral border of the IVC.
- Medial border is related to the head of the pancreas.
- Along the posteromedial wall of the midportion of 2nd part of duodenum lies Ampulla of Vater, which is the opening of the combined main pancreatic duct and common bile duct.
- The minor pancreatic duct also empties into 2nd part of duodenum as the minor papilla

- 3rd part.
- Retroperitoneal in location
- Related to uncinate process of the pancreas superiorly and to hepatic flexure & superior mesenteric vessels anteriorly.
- Posteriorly related to the right ureter, right gonadal vessels, IVC and aorta.

- 4th part.
- It runs in cephalad direction to the left of the aorta and inferior to the neck of the pancreas.
- Ligament of Treitz marks the end of the 4th part of duodenum.

Jejunum & Ileum

- Jejunum & ileum are approximately 5 metres in length with 40% comprising jejunum and 60% comprising ileum.
- Extends from ligament of Trietz to ileocecal valve distally.
- Compared to ileum, Jejunum has a thicker mucosal lining, thicker wall, larger diameter, less fatty mesentery, longer and straighter vasa recta and plicae circulares.

Blood Supply

- Duodenum receives blood supply from both celiac artery via branches of gastroduodenal artery and Superior mesenteric artery.
- Jejunum and ileum are supplied by Superior mesenteric artery.

Venous Drainage

- Pancreaticoduodenal, right gastroepiploic, and portal vein drain duodenum.
- Jejunum and ileum drain into superior mesenteric vein.

Lymphatic drainage

- Lymph drains first into adjacent nodes and then into mesenteric nodal arcade and lumbar lymphatic chain and finally empties into cisterna chili.

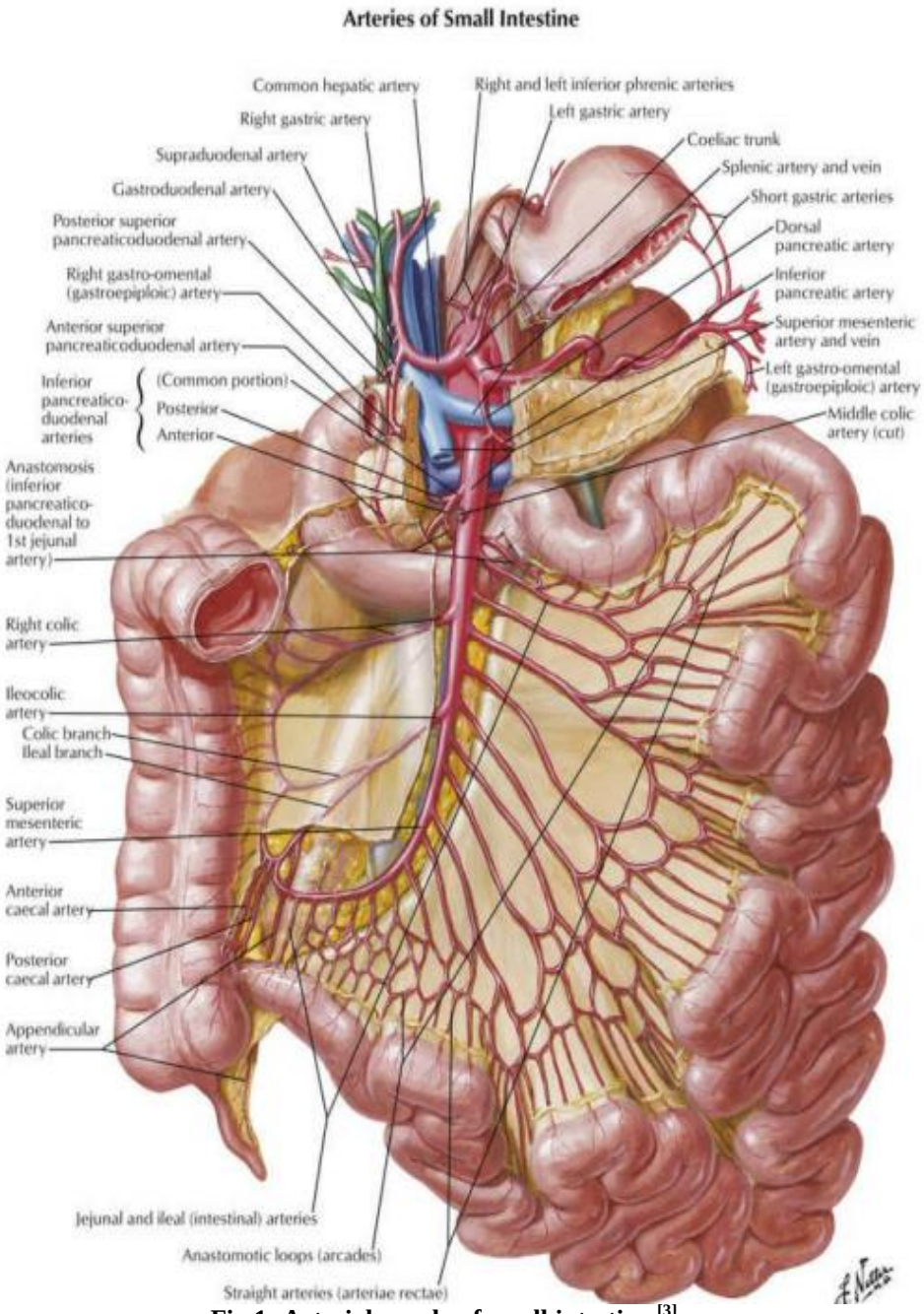

Fig.1: Arterial supply of small intestine.[3]

Nerve supply

- Nerve supply to small intestine is from Autonomic nervous system and Enteric nervous system.

1. Autonomic nervous system.

- Composed of sympathetic and parasympathetic system
- Sympathetic nerve supply is from T5- L2 thoracolumbar segments.
- Stimulation of the sympathetic system results in reduced intestinal motility, reduced secretion, and vasoconstriction.
- Parasympathetic fibres arise from vagus and sacral spinal nerves.
- Stimulation of parasympathetic system results in increased intestinal motility & secretions.

2. Enteric nervous system

- This is an independently functioning system derived from neural crest which controls intestinal motility, glandular secretion, vascular tone, and hormone release.
- It is made up of more than 100 million neurons.
- It consists of

1.The myenteric or Auerbach plexus located between the longitudinal and circular muscle layers, runs along the entire length of the gut wall and supplies muscular layers. The main function of the myenteric plexus is to control motor activity of the intestine.
2. The submucosal or Meissner plexus located in the submucosa, innervate intestinal glands, endocrine cells, and blood vessels and controls the secretion, absorption, and contraction within each segment of the small intestine.

Motility

- Small intestinal motility is controlled by a combination of myogenic, neural, and hormonal factors.

Functions

1. Digestion & absorption.
- Except for indigestible cellulose almost all food delivered to small bowel is absorbed.
- Pancreatic enzymes and small intestine brush border enzymes like maltase, sucrase-isomaltase, lactase and trehalase split disaccharides into monosaccharides.
- In normal individuals, 80 -90% of the protein digestion and absorption is completed in jejunum mediated by pancreatic & brush border enzymes.
- Essentially all fat digestion occurs in the small intestine with most of the fat absorption occurring in proximal small intestine.
- Enterohepatic circulation: absorption of unconjugated bile acids in jejunum and conjugated bile acids in distal ileum occurs which then passes through the portal vein to liver for secretion as bile. The total bile acid pool recirculates about 6 times per day with only 0.5 gram lost in stool per day.
- Small intestine is also the site for absorption of water, minerals and vitamins.
2. Secretory function:
- Small intestine is the largest endocrine organ of the body secreting a lot of hormones which act locally in autocrine or paracrine manner.
- These include gastrin, cholecystokinin, secretin, somatostatin, motilin, vasoactive intestinal peptide, neurotensin.
3. Immunological function
- Small intestine contains abundant lymphatic tissue concentrated at 3 areas- Peyer's patches, lamina propria lymphoid cells and intraepithelial lymphocytes.
- Ig A bearing B cells serve vital role in mucosal immunity. Ig A inhibits bacterial adherence to epithelial cells and prevents colonization and multiplication. IgA neutralizes bacterial toxins and viral activity and inhibits absorption of antigens from gut.

Colon

Surface Anatomy[1]

The unique identifying features of colon are.

- Taenia -longitudinal bands on external surface which cause puckering of the bowel wall to form sacculations called haustra.
- Appendices epiploicae - Small irregular stalks of fat found on colon
- Presence of Columnar epithelium that lacks villi.
- Presence of ileocecal valve- a muscular valve that separates the small bowel and colon.

Anatomy of colon

1. Ceacum

- It is the 1st segment of colon, lying in right iliac fossa. Saccular in shape and gives rise to appendix.
- The entry of ileum into ceacum is guarded by ileo-ceacal valve whose main function is to delay transit from ileum to cecum.

2. Appendix

- Appendix is approximately of 8-10 cms length and 5-10 mm in width. Arises most commonly from retroceacal position (65%)
- Other locations of appendix can be pelvic, subceacal, pre-ileal and post ileal.
- The posterior layer of the ileal mesentery continues as the meso-appendix.

3. Ascending colon

- Continues cephalad from cecum till hepatic flexure
- Throughout its course it is related posteriorly to iliacus muscle, inferior pole of right kidney and retro-peritoneal portion of duodenum.
- Posteriorly, ascending colon is relatively fixed to the abdominal wall and attached laterally by the peritoneal reflection or the white line of Toldt.

4. Transverse colon

- This is the longest segment of colon, measuring up to 50 cm in length.
- Begins at hepatic flexure and arcs in a slight anteroinferior direction and ends at the splenic flexure.
- Transverse colon is almost completely covered by visceral peritoneum.
- At splenic flexure, colon is fixed by 2 ligaments: splenocolic and phrenocolic ligament.
- The greater omentum attaches to the anterosuperior transverse colon as the gastrocolic ligament, and then continues as greater omentum proper.

5. Descending colon

- Begins at the downward turn at the splenic flexure, and descends in gradual left-to-right direction and terminates at the pelvic brim. It is of 25 cm in length.
- Posteriorly it is related to the inferior pole of the left kidney and lies between psoas and quadratus lumborum muscles.
- Peritoneum covers its anterior and lateral surfaces, and posteriorly, it is in contact with loose areolar retroperitoneal tissue.

6. Sigmoid colon

- Beyond the pelvic brim descending colon continues as the sigmoid colon and terminates at the sacral promontory. It lacks taenia.
- sigmoid colon is of 40 to 45 cm in length and has a sigmoidal course as it descends the left pelvis, then across to the right pelvis, and finally courses retrograde toward the midline.
- It has a mobile V shaped mesocolon.
- Sigmoid colon is the most muscular portion of the colon.

Arterial supply of colon

- Colon receives its blood supply from superior mesenteric artery and inferior mesenteric artery.

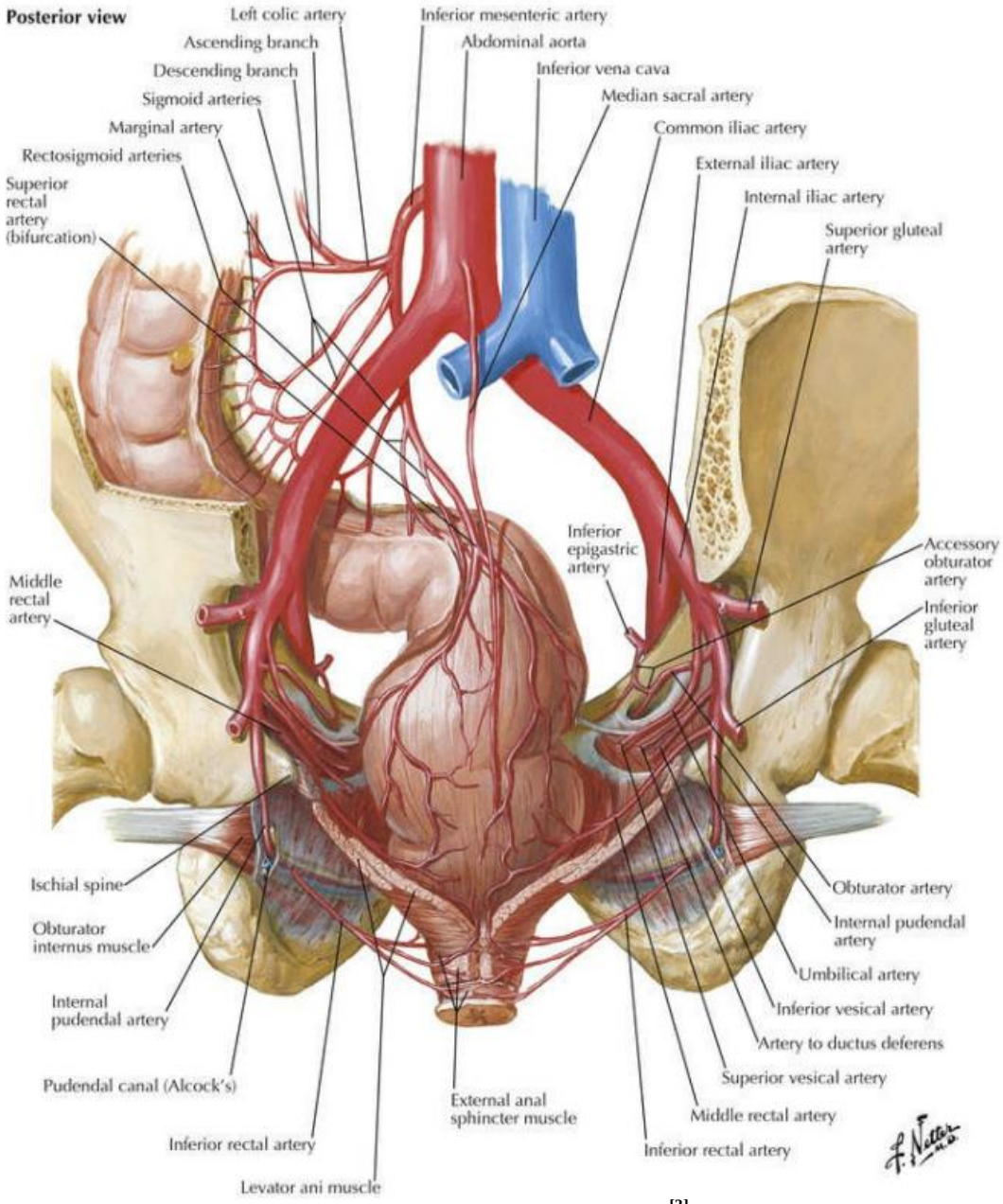

Fig 2: Arterial supply of large bowel.[3]

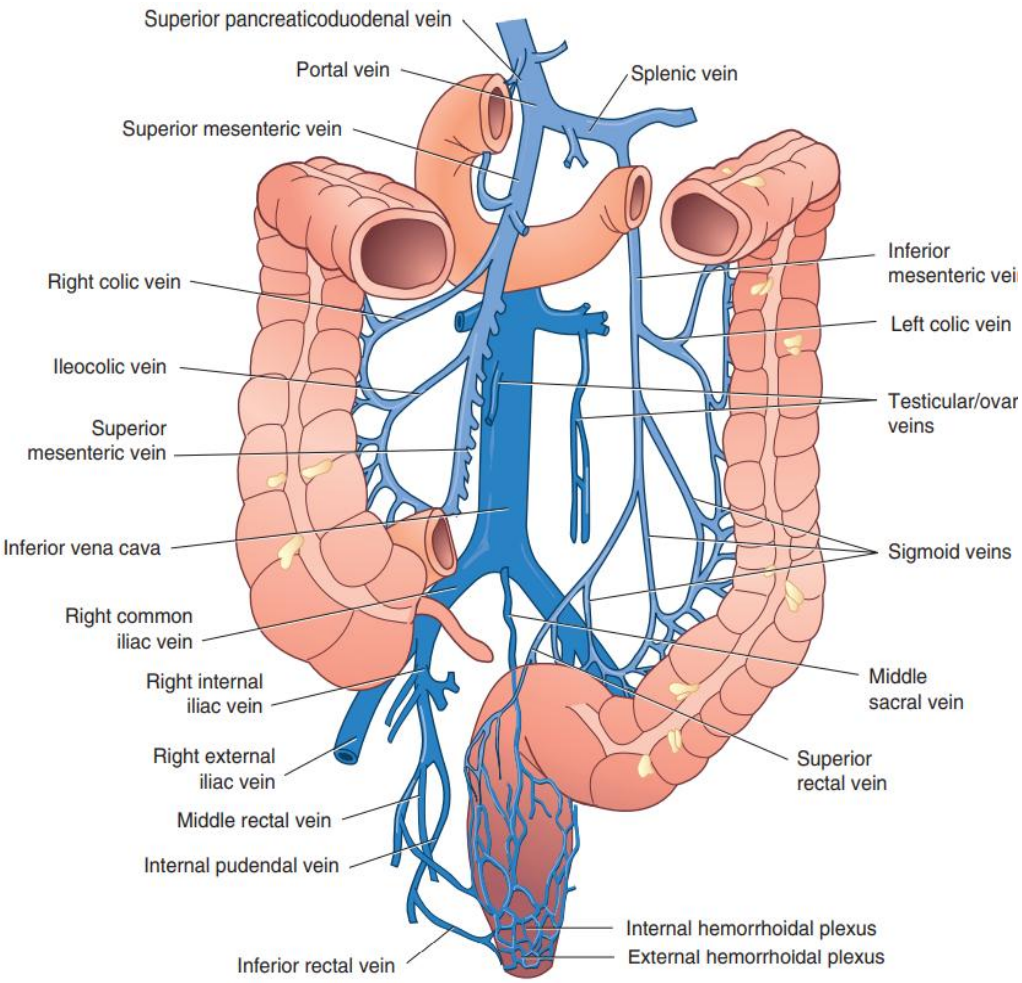

Fig 3: Venous drainage of large bowel.

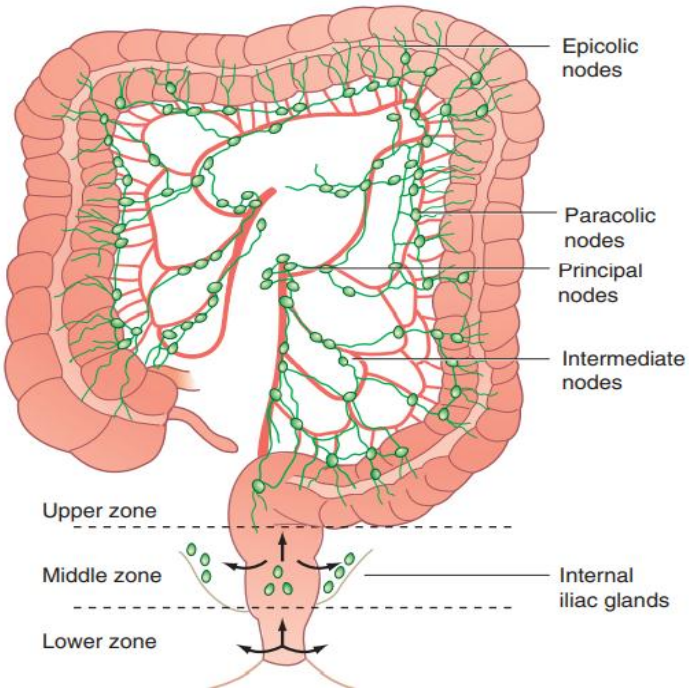

Fig 4: Lymphatic drainage of large bowel.

Superior mesenteric artery[2]

- Three branches of SMA are: the right colic, middle colic, and ileocolic arteries.
- Branches of the SMA supplies upto the proximal two-thirds of the transverse colon.

Inferior mesenteric artery

- It divides into the left colic artery and several sigmoidal arteries and terminates as the superior rectal artery (SRA).
- The left colic artery divides into ascending and descending branches. The ascending branch supplies the distal one third of the transverse colon and splenic flexure via the arcade of Riolan. The descending branch is the main supply of descending colon.
- The sigmoidal arteries form an arcade to supply the sigmoid colon and collateralize with the marginal artery (of Drummond).

Marginal artery of Drummond

- This small-caliber artery run along the entire course of colon within the outer limits of the mesentery.
- It connects SMA to IMA, and serve as the channel of flow in stenosis or occlusion of either of the one.

Griffith point

- At the splenic flexure, which is the transition point from midgut to hindgut, there is inadequate/absent collateralization in nearly 50% of individuals. This watershed area is called as Griffith point.

Arc of Riolan

- The meandering mesenteric artery (MMA), or the arc of Riolan, is the second major collateral pathway between SMA & IMA, connecting middle colic artery and the proximal left colic artery.

Venous drainage

- The ascending colon drains via the superior mesenteric vein (SMV).
- Descending colon, sigmoid colon, and rectum are drained by inferior mesenteric vein (IMV).

Lymphatic drainage

- Lymph from colon is drained mainly into 4 groups of lymph nodes epiploic, paracolic, intermediate, and principal.
- The epiploic group – found most abundant in the sigmoid colon.
- Paracolic nodes – are located along the entire course of colon along the marginal artery.
- The principal "main" nodes - present along the course of the SMA and IMA.
- Intermediate nodes – run along the colic arterial branches.
- All four nodal basins drain into the paraaortic nodes, then into cisterna chyli, and finally into the thoracic duct.

Nerve supply of the colon

- Sympathetic nerve supply is from T6 to T12 spinal nerves via celiac, preaortic and superior mesenteric ganglia.
- Parasympathetic suuply to the cecum, appendix, ascending colon, and proximal two-thirds of the transverse colon is derived from right branch of vagus nerve and celiac plexus.
- Parasympathetic innervation for the distal one-third of the transverse colon, descending, and sigmoid colon are from S2, S3, and S4 spinal nerves.

Rectum & Anal canal

Anatomy

1. Rectum

- The transition of sigmoid colon to rectum begins after the disappearance of taenia and from the level of sacral promontory.
- It is 15 cm in length and divided into 3 segments based on the distance from the anal verge:
  - lower (0 to 7 cm),
  - middle (7 to 12 cm), and
  - upper (12 to 15 cm).
- The rectum descends posteriorly in the pelvis along the concavity of the sacral hollow.
- The upper one third of the rectum is covered with peritoneum anteriorly and laterally; while the middle one third of the rectum is covered with peritoneum anteriorly only; and the lower third is completely extraperitoneal.
- Rectum is covered anteriorly by a thick investing layer known as Denonvillier fascia which separates the rectum from seminal vesicles and prostate (men) and vagina (women).
- Posteriorly, it is closely invested with the mesorectum – thick perirectal tissue containing blood vessels and lymphatics.
- There are 3 semilunar folds, known as valves of Houston arranged in a left, right, left configuration from distal to proximal which are located at 7 to 8 cm (left), 9 to 11 cm (right), and 12 to 13 cm (left) from the anal verge.

2. Anal canal

- The distal rectum descends into the pelvis and passes through the fibres of puborectalis, marking the beginning of the anal canal.
- Anteriorly, the anal canal is separated from the lower vagina in women and the penile bulb in men by perineal body.
- Posteriorly anal canal is fixed to the coccyx by the anococcygeal ligament.
- Laterally it is surrounded by the ischiorectal fossa containing soft tissue.
- The "surgical anal canal" comprises from the anorectal ring (proximal internal anal sphincter and puborectalis muscle) to the anal verge.
- It is of about 4.4 cm in males and 4.0 cm in females.
- Anal Transition zone (ATZ).

- It begins about 5 mm above the dentate line, marked by a visible change from the pink, columnar epithelium of the rectum to perse squamous epithelium of the anal canal.
- At this level there are redundant folds of tissue, known as the columns of Morgagni which contains anal crypts and anal glands.

➢ Internal anal sphincter:

- It is composed of circular smooth muscular layer of the rectum, measuring 2 to 3 mm in thickness and 35 mm in length.
- It is responsible for 50% to 85% of involuntary resting anal tone.

➢ External anal sphincter:

- Made up of skeletal muscle but in contrast to the other skeletal muscles, external anal sphincter maintains an unconscious resting tone via the reflex arc contributing to 25% of resting tone.
- During periods of distention of the rectum or increased abdominal pressure, the external anal sphincter contracts voluntarily up to 60 seconds to avoid incontinence.
- External anal sphincter is divided into three components:

- deep (most proximal),
- superficial (intermediate portion)
- and subcutaneous (most distal).

Arterial Supply

➢ Rectum receives its blood supply from three branches

1. Superior rectal artery – continuation of IMA beyond left iliac vessels. It gives 1 or 2 sigmoid branches, one upper rectal branch and bifurcates into right and left branches.
2. Middle rectal artery – arises from Internal iliac artery.
3. Inferior rectal artery - arises from Internal iliac artery.

Venous Drainage

➢ Venous drainage is via the superior, middle, and inferior rectal veins.

➢ Upper two-thirds of the rectum is drained by Superior rectal vein into the IMV and then into portal system.

➢ Inferior one-third of the rectum and anal canal is drained by the middle and inferior rectal veins into the internal iliac veins and then into inferior vena cava.

Lymphatic Drainage

➢ Proximal two-thirds draining lymph channels course along the IMA nodal chain and drain into paraaortic nodes.

➢ Distal one-third of the rectum and the anal canal above the dentate line drain into superior rectal nodes and inferior mesenteric nodes located cephalad and also laterally into the middle rectal nodal chain into internal iliac nodes.

➢ Although closely related, no communication is found between inferior mesenteric and internal iliac lymphatics—an important concept concerning the locoregional spread of rectal cancer.

➢ Anal canal below the dentate line drains to ipsilateral inguinal lymph nodes.

Nerve Supply

➢ The sympathetic supply is from preganglionic fibres arising from L1, L2, and L3.

➢ Parasympathetic supply is from S2, S3, and S4 segments and are termed as nervi erigentes.

➢ Internal anal sphincter derives Sympathetic innervation from L5 and parasympathetic innervation from nervi erigentes.

➢ External anal sphincter receives bilateral innervation from S2 and S3 (inferior rectal branch of the pudendal nerve) and via S4 (perineal branch).

Functions of Colon

Function of colon is mainly recycling of nutrients and that of rectum is elimination of stool.

➢ The main function of the colon is absorption of water and electrolytes.

➢ Of the 1000mL of ileal content entering caecum per day, only around 200mL is excreted as faeces.

➢ Sodium is absorbed actively, whereas chloride and water are absorbed passively.

➢ Absorption of other nutrients like glucose, fatty acids, amino acids and vitamins also occur to an extent in colon.

➢ Formation of stool and defecation.

Large bowel obstruction[4]: Intestinal obstruction is classified into two types.

1. **Dynamic obstruction-** due to presence of mechanical obstruction. It is characterised by the presence of increased peristalsis to overcome the obstruction. Causes are.

● Intraluminal causes

➢ Faecal impaction
➢ Foreign bodies
➢ Bezoars
➢ Gallstones

● Intramural causes

➢ Stricture
➢ Malignancy
➢ Intussusception
➢ Volvulus

● Extramural

➢ Bands/adhesions
➢ Hernia

2. **Adynamic obstruction** – there is no mechanical obstruction, but there is absence of peristalsis or inadequate peristalsis. Causes are

➢ Paralytic ileus

- Pseudo-obstruction

Pathophysiology of Mechanical obstruction:

- Mechanical obstruction causes dilation of the bowel proximal to the obstruction due to gas and fluids (saliva 500mL/day, bile 500mL/day, pancreatic secretions 500mL/day, gastric secretions 1 litre/day) with increased peristalsis initially.
- If the obstruction is not relieved, the bowel continues to dilate leading to decreased strength of peristalsis and eventual flaccidity and paralysis.
- Direct pressure on the bowel wall or Interrupted mesenteric blood flow or Closed-loop obstruction can cause strangulation of the bowel wall and ischemic gangrene can follow.

Clinical features of Mechanical obstruction

- Clinical manifestations depend on factors like
- location of obstruction;
- nature of obstruction- complete/incomplete;
- duration of obstruction - acute/ chronic or
- blood supply is intact or compromised and
- underlying etiology.
- Clinical features of large bowel obstruction include.
- Distension.

Distension can be a late feature in colonic obstruction.

- Pain.

Pain is usually colicky in nature to begin and located to lower abdomen , where as diffuse pain indicates peritonitis.

- Vomiting.

The more distal the obstruction, the longer the interval for manifestation of nausea and vomiting. With continued obstruction vomiting can vary from digested food initially to faeculent material.

- Constipation:

Constipation can be absolute (i.e. neither faeces nor flatus is passed) or relative (only flatus is passed). Absolute constipation is seen in complete intestinal obstruction.

- Dehydration

Dehydration occurs due to repeated vomitings and fluid sequestration.

- Other manifestations include
- oliguria,
- Electrolyte imbalance
- fever
- hypovolaemic shock,
- peritonitis and sepsis

Investigations[4]

1. Routine blood investigations

Complete blood counts, Serum electrolytes, Renal function test.

2. Plain X-rays

- Erect and supine views are taken.
- Radiological findings in obstruction include.
- Caecum –colonic obstruction is usually associated with huge gas accumulation in cecum, which is visualized as rounded gas shadow in the right iliac fossa.
- Large bowel - except for the caecum, has haustral folds, which, are spaced irregularly, and they do not cross the entire bowel diameter and indentations are not opposite to one another.
- Distal colonic obstruction usually does not produce air- fluid levels unless advanced, whereas air fluid levels in small bowel are seen in initial stages itself in proximal colonic obstruction.

3. Contrast X rays

- A limited water-soluble enema helps to differentiate large bowel obstruction from pseudo-obstruction.
- Barium follow-through is contraindicated in case of acute intestinal obstruction and can be life-threatening.

Fig. 5: X Ray of Large Bowel Obstruction Showing Distended Colon With jPaucity of Air In Rectum.

4. Computed Tomography.

- CT scan has replaced X Ray as the most common imaging modality to diagnose intestinal obstruction due to its high accuracy.
- CT findings suggestive of bowel wall ischemia are:

1. Reduced bowel wall enhancement
2. Presence of mesenteric fluid.

Fig. 6: CT abdomen of patient with sigmoid volvulus.

MANAGEMENT

- The cases are selected with diagnosis of intestinal obstruction diagnosed by physical examination, radiological investigation.
- Baseline laboratory investigations,plain X-ray abdomen for all patients and other investigations done appropriately (CT or MRI).
- All the patients are managed with IV fluids, blood if needed, preparation of bowel before taking up for surgery in elective cases.
- Laparotomy done and if the lesion is operable limited resection or left hemicolectomy is done whichever is appropriate and colorectal anastomosis is done.
- For defunctioning colorectal anastomosis either a loop ileostomy or transverse loop colostomy is done.

Loop colostomy

Indications

- The primary indication for loop colostomy is a distal obstruction requiring temporary or palliative fecal diversion.
- Patients with symptomatic fistulas between the rectum and urethra, bladder, or vagina may also find relief with a loop colostomy.
- A downside of using the colon rather than the ileum for diversion in the case of fistula is the potential compromise of a segment of colon that may be needed to reach a low pelvic anastomosis for the purposes of reconstruction.
- Other indications for loop colostomy include trauma to the extraperitoneal rectum or perineum, and complicated soft tissue infection of the perineum requiring significant debridement.[5-7]
- A loop colostomy may divert a high-risk distal anastomosis, but a loop ileostomy is the more common choice.
- As a loop colostomy may be incompletely diverting if the posterior wall sits below skin level, ongoing distal fecal drainage may require conversion to an end colostomy.
- The ideal segment of colon to use for a loop colostomy is the sigmoid, as it is the most mobile part of the distal colon.
- In cases of unresectable obstructing lesions at the splenic flexure or left colon, or when the sigmoid is not available for use, the use of the transverse colon may be necessary.
- Loop transverse colostomies are associated with a high rate of complications including prolapse and pouching difficulties due to liquid output, and should be avoided unless absolutely necessary.

Open Technique

- Make the stoma defect in the fashion described for end colostomy.
- Mobilize the loop of sigmoid or transverse colon so that it will reach through the abdominal wall.
- Make a defect at the junction between the colon and the mesentery, and pass a ½-inch umbilical tape or Penrose drain through this defect.
- Prior to bringing the bowel through the abdominal wall, wrap the bowel in Seprafilm to facilitate the takedown procedure.

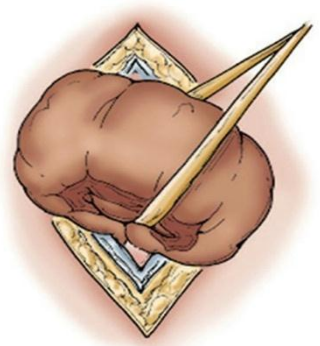

Figure 7: Use an umbilical tape or Penrose drain to guide the loop of colon through the stoma defect while pushing it out from the inside of the abdomen.

- Excess traction on the umbilical tape or Penrose drain may cause tearing of the bowel or mesentery. After closing the abdominal incision, mature the loopcolostomy.
- Some surgeons prefer the use of stoma rods that can be placed through the mesentery defect to replace the umbilical tape.
- Transversely incise the antimesenteric border of the distal side of the loop.
- This division should be more than half the bowel circumference so that the functioning proximal limb and nonfunctioning distal limb are separated.
- Suture the free edge of the bowel to the dermis or epidermis with interrupted 3-0 Chromic sutures.
- Eversion of the proximal limb, and making sure the posterior wall is at least at the level of the fascia, will prevent stool from passing into the distal limb.

Laparoscopic Technique

- If a laparoscopic approach is safe and feasible, mobilize the loop of colon adequately to reach the anterior abdominal wall while the abdomen is insufflated.
- Make the stoma defect and dilate it to two to three fingerbreadths under pneumoperitoneum, and slide a Babcock clamp alongside the fingers to grasp the mobilized loop of colon. Bring the loop gently through the stoma defect.
- Check laparoscopically to determine the orientation of the colon, and mature the proximal side.
- A single-port or reduced-port laparoscopic technique using the planned stoma site as the port site results in fewer or no additional incisions aside from the stoma defect itself.[8]

Technique for Closure of Loop Colostomy

- Loop colostomy closure starts with a circumferential incision around the colostomy, about 3 mm from the mucocutaneous junction.
- Use this skin edge for retraction by placing Allis clamps on it while sharply dissecting the bowel wall away from the subcutaneous tissue and fascia.
- In the rare event that this dissection is so difficult that mobilization of the colon from the abdominal wall is not possible through the stoma site, a midline incision may be necessary.
- When the colon is completely mobilized from the abdominal wall, unevert the proximal and distal bowel edges.
- Examine the bowel wall for partial- or full-thickness defects and repair them transversely with interrupted 3-0 Vicryl sutures.
- If the colon is largely intact, then resection is not necessary.

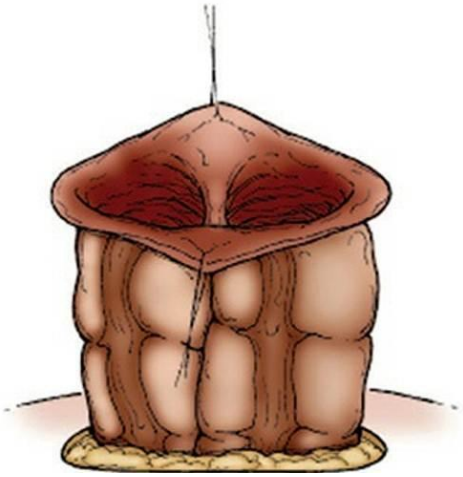

Figure 8: Trim away the skin edge, leaving only a transverse defect in the antimesenteric aspect of the colon.

- Close the defect transversely using interrupted 3-0 absorbable seromuscular sutures.
- To handle a significant size discrepancy between the proximal and distal limb, make a longitudinal slit in the antimesenteric side of the smaller limb (Cheatle slit).
- Match the apex of the Cheatle slit to the midpoint of the larger caliber bowel edge. Close the defect transversely.
- A stapled closure using a linear noncutting stapler to close the bowel transversely is another option.
- A final option is to create a side-to-side stapled anastomosis by firing a linear cutting stapler down the lumens of the proximal and distal limbs and closing the end of the anastomosis with a linear stapler.
- If resection of a colon segment is necessary due to injuries sustained during mobilization of the colostomy, then create the anastomosis in a handsewn end-to-end fashion, or a stapled side-to-side fashion.

Divided Loop Colostomy (Separated Loop Colostomy)

INDICATIONS

- The indications for a divided loop colostomy are similar to those for a loop colostomy, which include a distal obstruction, a symptomatic fistula between the rectum and urethra, bladder, or vagina, trauma to the extraperitoneal rectum or perineum, and complicated soft tissue infection of the perineum with a large perineal wound.[5-7]
- The benefit of a divided loop colostomy over a loop colostomy is more definitive fecal diversion.
- A divided loop colostomy has two advantages over an end colostomy: reversal of a dividedloop colostomy can be performed through the stoma site, and it can be used in the case of distal obstruction since the distal limb remains open.

Technique

- Mobilize the loop of colon, create the stoma defect, and bring the loop of colon through the defect in the same fashion as a loop colostomy.
- Make a defect in the mesentery adjacent to the bowel wall, avoiding the mesenteric vasculature.
- Divide the colon with a linear cutting stapler.
- Excise the corner of the distal staple line and suture the bowel wall to one side of the stoma defect, creating a mucus fistula. Remove the entire staple line of the proximal limb, and mature the colostomy with interrupted full-thickness 3-0 Chromic sutures to the skin.
- Part of the colostomy will be adjacent to the mucus fistula.
- Suture the bowel wall edges together.
- Converting a loop colostomy to a divided loop colostomy is indicated if there is persistent and symptomatic drainage of feces distally, which occurs because the posterior wall of the loop colostomy has fallen below the level of the fascia.
- Incise the stoma circumferentially at the mucocutaneous junction.
- Sharply dissect the bowel free of the surrounding subcutaneous tissue and fascia to bring the entire width of the colon above the skin level.
- Create a defect in the mesentery adjacent to the bowel and divide it with a linear cutting stapler. Mature the colostomy and the mucus fistula.

Loop-End Colostomy

Indications

- A patient with a short colonic mesentery and/or thick abdominal wall that precludes the end of the colon to reach through the abdominal wall may require a loop-end colostomy.

- The segment just proximal to the distal end of the colon will often reach farther through the abdominal wall than the end.

Technique

- Mobilize the colon and create a stoma defect.
- Make a defect at the bowelmesentery border and pass a ½-inch umbilical tape or Penrose drain through the defect.
- Use this to guide the loop of colon through the defect while pushing the colon and mesentery from the inside.
- Wrap the bowel in Seprafilm prior to passing through the abdominal wall if the stoma is temporary.
- Exchange the umbilical tape for a stoma rod and suture it in place.
- Divide the colon transversely at the distal side of the loop. Mature the stoma as a loop colostomy.

Colostomy Function

- Colostomy function varies greatly among patients and depends on several factors, including diet and fluid intake, and preexisting bowel habits.
- While most patients wear stoma appliances at all times, a smaller proportion of patients choose to irrigate their colostomies to reduce the need to wear an appliance.
- Colostomy irrigation is a daily high-volume enema and gives patients control over the timing of bowel movements.
- Patients who irrigate successfully may only need to wear a bandage or a gauze pad over the colostomy for the rest of the day.
- Patients who use colostomy irrigation have decreased flatus and odors, and higher quality of life compared to those who do not use irrigation.
- Water or agents such as polyethylene glycol or glyceryl trinitrate solution are the irrigants most commonly used.[9,10]

Ileostomy

- The consistency of ileostomy output is more watery, and the composition is more caustic to the skin.
- These two differences increase the risk for pouch leaks and subsequent skin breakdown in patients with ileostomies compared to those with colostomies.
- It is very important that ileostomies be budded to allow the os to be above the surface of the skin and within the pouch, decreasing the risk of pouch leakage.

Loop Ileostomy

Indications

- Distal colonic obstruction in the setting of an incompetent ileocecal valve.
- Distal colorectal anastomosis with a high risk for an anastomotic leak.
- Severe perianal Crohn's disease, perineal or perianal trauma, perineal wounds that require fecal diversion, and fistulas between the bowel and genitourinary tract which are not ready for definitive repair.

Technique

- Choose as distal a segment of ileum as possible that will reach without tension through the abdominal wall.
- Place orienting sutures of loosely tied knots to prevent inadvertent maturation of the distal side.

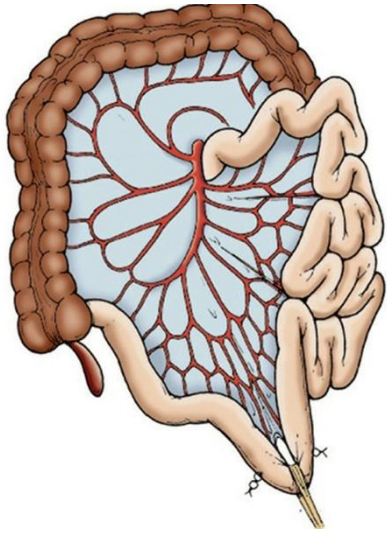

Figure 9: Choose as distal a segment of ileum as possible that will reach without tension through the abdominal wall.

- Make a small defect in the mesentery just adjacent to the bowel wall, taking care not to damage the mesenteric vasculature.
- Bring a ½-inch umbilical tape or Penrose drain through this defect without tension through the abdominal wall, and place orienting proximal and distal sutures on the bowel wall.
- The ileostomy defect is created in the same manner as for an end ileostomy.
- The chosen loop of ileum is wrapped in Seprafilm and brought through the ileostomy defect using the tape to guide the loop through the abdominal wall while pushing the loop of bowel through the defect from the inside out. Placing excess traction on the bowel and mesentery can cause the mesentery or bowel wall to tear. The mesentery–bowel junction should be at the level of the skin.
- After fascial closure and before stoma maturation, some surgeons prefer to place a stoma rod through the mesenteric defect to prevent ileostomy retraction.
- In obese patients it is critical to sew the rod or Robnel to the skin, as it might otherwise fall into the abdominal cavity, necessitating reoperation.
- Remove the stoma rod 3 to 5 days after the operation.

- Mature the loop ileostomy by transversely incising the distal side of the loop.
- This transverse enterotomy should encompass at least half the circumference of the bowel wall. Place three-point sutures of 3-0 Chromic full-thickness through the free edge of the bowel, seromuscular through the bowel at the base of the stoma, and through the dermis.
- Place these sutures in the midline of the antimesenteric bowel wall and on each side near the stoma rod.
- While placing gentle tension on the sutures, evert the stoma by pushing the back of a forceps just under the free edge of the bowel.
  - Tie the sutures down. Suture the distal bowel with interrupted 3-0 Chromic sutures between the full-thickness bowel wall and dermis.

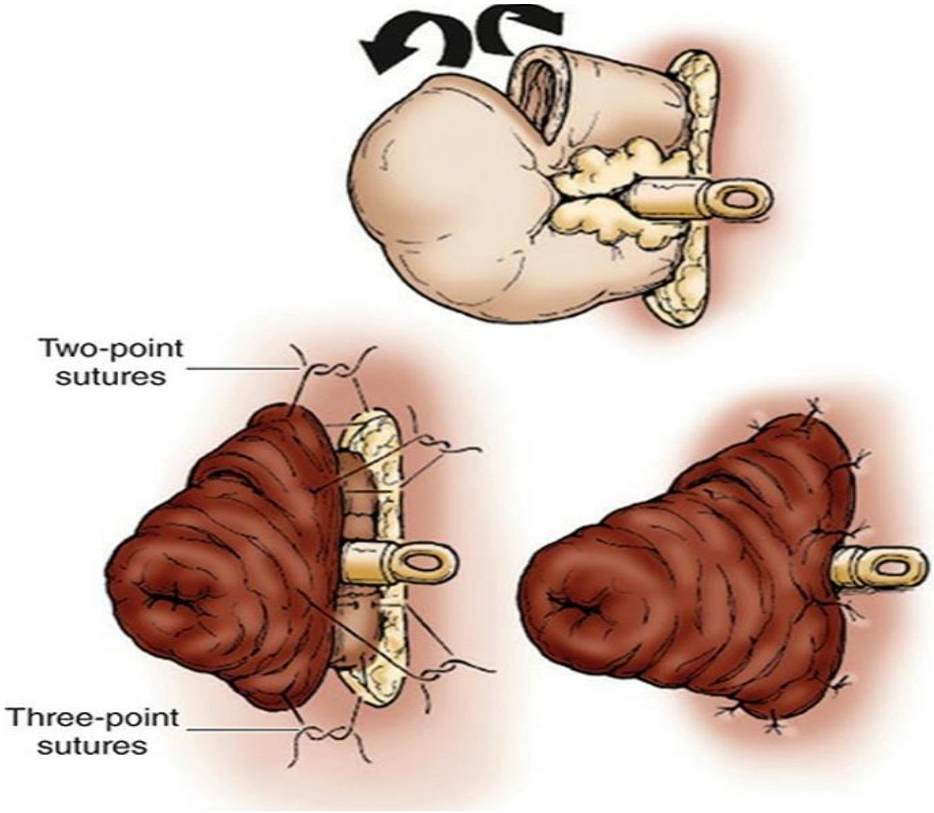

Figure 10: Use three-point sutures to evert the proximal limb of the loop ileostomy (inferior limb in this figure) so that the functional lumen is budded. The distal lumen (superior limb in this figure) can be at the skin level.

Complications

- Patients with loop ileostomies are at particularly high risk for high stoma output and pouching difficulties.
- High stoma output is more likely when the stoma is proximal to the terminal ileum, as is the case for a loop ileostomy proximal to an ileoanal pouch, or a more proximal loop ileostomy in obese patients with thick abdominal walls and thick, foreshortened mesenteries that technically preclude the use of the terminal ileum.
- Patients with loop ileostomies are more likely to experience pouch leakage due to the more liquid output of ileostomies, as well as the conformation of the proximal os, which may not be as centered as the os of an end ileostomy.
- An inferior tilt of the proximal os, especially combined with stomal retraction, causes the stoma effluent to run under the lip of the stoma appliance.
- Pouch leaks can lead to maceration of the peristomal skin, further aggravating the problem.

Closure of Loop Ileostomy

- Closure of a loop ileostomy is usually performed at least 3 months after its creation, provided that imaging studies confirm that the distal pathology has resolved, or the colorectal anastomosis is patent and intact.
- While closing a loop ileostomy sooner than that may be feasible, some patients may still have dense scar tissue around the stoma.
- Dense adhesions increase the risk for injury to the small bowel or mesentery, and the need for laparotomy.
- Placement of an anti-adhesion barrier such as Seprafilm around the ileostomy at the time of its creation may reduce these risks.
- Make a circumferential incision around the stoma, leaving a 3-mm rim of skin for retraction.

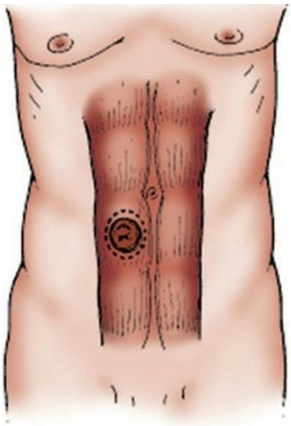

Figure 11: Make a circumferential incision around the ileostomy in the peristoma skin.

- Sharply dissect the ileal loop free of the subcutaneous tissues and fascia.
- After completely mobilizing the bowel, carefully sweep around the anterior abdominal wall to check for additional adhesions, being mindful of the risk of inadvertent injury to small bowel.
- Successful mobilization of the ileostomy can usually be accomplished through the stoma defect.

Figure 12: Mobilize the ileostomy through the stoma defect.

- However, some cases with dense adhesions may require a laparotomy, especially if injuries to the small bowel have occurred.
- The everted end of the bowel can be straightened with sharp dissection.
- Infuse Betadine using a bulb syringe into the proximal and distal limbs of the loop ileostomy to detect serosal or fullthickness defects.
- Close any partial- or full-thickness defects transversely with interrupted 3-0 Vicryl sutures.
- If there are extensive bowel wall injuries, it may be necessary to resect a segment of small bowel.
- A second layer of Lembert sutures may be used for reinforcement.
- If there is a size discrepancy between the proximal and distal limbs, then make a Cheatle incision on the antimesenteric bowel wall of the smaller side.
- If a small bowel resection was necessary, then perform a handsewn end-to-end anastomosis by approximating the mesenteric side of the bowel with interrupted sutures of 3-0 Vicryl that are full-thickness through the bowel wall, making sure that the mucosa is tucked into the lumen.
- Close the antimesenteric side of the bowel with interrupted seromuscular sutures of 3-0Vicryl.
- In either case, the stapled option involves firing a linear cutting stapler down the proximal and distal lumens, creating a side-to-side anastomosis.
- Fire a linear stapler to close the end of the anastomosis.

Ileostomy Care and Skin Complications

- A well-placed and well-constructed ileostomy should offer the patient a good quality of life, minimal restrictions on activity, and ability to enjoy a range of foods.
- Most patients use a two-piece ileostomy appliance system comprised of a faceplate with a skin barrier and a pouch.
- The stoma opening of the skin barrier must match the exact size of the ileostomy, so that all the peristomal skin remains protected from the ileostomy effluent.
- The faceplate typically lasts 3 to 5 days, but if the patient experiences leakage under the appliance, then it requires more frequent changes.
- Maintaining a good seal around the ileostomy is crucial for maintaining the integrity of the peristomal skin and quality of life.
- The chemical dermatitis caused by leakage of ileostomy contents onto the skin can be extremely painful and results in a vicious cycle in which maintaining an adequate seal between the faceplate and macerated skin is impossible, leading to more leaks and skin trauma.
- A retracted ileostomy with an os at skin level, or a tilted ileostomy with an os pointing down, is likely to result in leaks and pouching problems.
- Loop ileostomies are more likely to be associated with pouching problems because the distal opening is flush with the skin, allowing mucus to seep under the faceplate and disrupt the seal.

Management of High-Output Ileostomies

- Many postoperative patients with new ileostomies experience a large volume of liquid output in the first few weeks after the operation.
- The daily volume of ileostomy output may be over a liter shortly after ileostomy creation, but should slow down to 500 to 800 mL after the small bowel has had a chance to adapt and increase its absorptive capacity.
- However, some patients may persistently have high output for various reasons including partial obstruction, short gut syndrome, or intrinsic bowel abnormalities.
- The two main problems with high-output ileostomies are dehydration often accompanied by electrolyte abnormalities and pouching difficulties due to the liquidity and volume of the effluent.

- The first step in the diagnostic workup is to rule out an underlying obstruction, which can cause the bowel proximal to the obstruction to secrete large volumes of fluid.
- Assess for obstruction at the level of the fascia by inserting a finger into the stoma.
- A contrast study or ileoscopy through the ileostomy will demonstrate a more proximal obstruction.
- Other possible etiologies include enteritis, short bowel syndrome, or inflammatory bowel disease.
- Most commonly, high ileostomy output is attributable to dietary indiscretion, and can be managed with a combination of diet changes, fiber supplementation, and medications.
- General principles for managing high ileostomy output are avoidance of concentrated sugars, hydrating with a combination of water and electrolyte beverages, and eating foods with a balance of protein, healthy fats, and soluble fiber.

Foods to slow down and thicken ileostomy output:

Peanut butter (creamy)
Cheese
Potatoes
Bread
Bananas
Tapioca pudding
Marshmallows
Applesauce

Maintaining hydration and electrolyte balance:

8–10 (8 oz) glasses of fluids per day

Water
Dilute fruit juices or sports drinks 1:1 with water, add a pinch of salt
Coconut water (contains less sugar than fruit juice, and also contains sodium, potassium)

Figure 13: Management of high output fistula.

- Patients should be cautioned against drinking large amounts of water in an effort to keep up with the high volumes of watery ileostomy output they are experiencing, as this is may exacerbate electrolyte deficiencies and will not help to slow the output.
- Rather, they should be counseled to eat as well as hydrate with a diluted electrolyte drink.
- Fiber supplementation in the form of the soluble fiber pectin, powders dissolved in drinks, and fiber wafers are more effective than fiber pills.
- Medications such as loperamide, diphenoxylate-atropine, and tincture of opium can also be helpful in reducing the stoma output.
- Introduce one drug at a time and increase the dose as needed.
- Patients with fast transit may not absorb capsules or tablets, so elixir or orally disintegrating formulations may be more effective.
- If all of these measures are unsuccessful at controlling the output and dehydration with electrolyte and/or nutritional deficiencies continues to occur, then the patient may require long-term parenteral replacement of fluids and electrolytes. Malnutrition due to poor absorption may require total parenteral nutrition.

Management of Ileostomy Obstruction

- If a patient with an ileostomy develops obstructive symptoms, the first step is to rule out an obstruction due to a food bolus by irrigating the stoma with saline via a Foley catheter.
- Food particles in the irrigant raise suspicion of a food bolus as the culprit, and continued irrigation with warm saline should resolve the problem.
- If there are no food particles in the irrigant, then the obstruction may be due to other causes such as adhesions, volvulus of small bowel around the ileostomy, or parastomal hernia.
- Cross-sectional imaging or a water-soluble contrast study via the stoma is helpful in making the diagnosis.

Stoma Complications

Parastomal Hernia

- Parastomal hernia occurs in up to 50% of patients.
- Risk factors of parastomal hernia include any condition that causes increased intra-abdominal

pressure including obesity, chronic cough, chronic obstructive pulmonary disease, ascites, and straining behaviors.

- Other patient-related risk factors include older age, malnutrition, systemic steroids, and creation of the stoma during emergency operation.
- Technical factors that may reduce the risk of hernia are using an extraperitoneal route rather than a transperitoneal route, a smaller trephine aperture for the stoma defect, and prophylactic mesh reinforcement of the stoma defect at the time of primary stoma creation.[11,12]
- Most parastomal hernias may be managed nonoperatively, but complications associated with parastomal hernia such as pouching difficulty, bowel obstruction, or incarceration are indications for surgical repair.
- The best treatment for parastomal hernia repair is restoration of bowel continuity, as the recurrence rate of parastomal hernia repair with mesh is as high as 17% in some series.[13]
- Primary suture repair has recurrence rates ranging from 46% to 100%, and there are few indications for this procedure.
- The use of biologic or prosthetic mesh is associated with a low incidence of mesh infection.
- Several options for mesh placement and surgical approach exist.
- An onlay mesh with a central defect for the stoma sits on top of the fascia.
- A sublay mesh with a keyhole opening for the stoma sits between the rectus muscle and the posterior rectus sheath.
- An underlay mesh sits posterior to the peritoneum.
- It may have a keyhole defect for the stoma opening, or it can be placed as a patch over the most distal intraperitoneal part of the colon.
- This Sugarbaker technique creates a short tunnel for the distal colon and has been found to have a lower recurrence rate.[13]
- The final option is stoma relocation with mesh repair of the other stoma defect.
- The success of stoma relocation is equivalent to that of mesh repair.[14]

Stoma Prolapse

- Loop colostomies using the sigmoid or transverse colon have the highest risk of stoma prolapse.
- An accompanying parastomal hernia is common.
- If the prolapse is incarcerated but the bowel is not ischemic, then manual reduction should be attempted immediately.
- If the stoma is edematous, pour a generous amount of sugar onto the prolapsed segment and allow it to sit for at least 10 minutes.
- The sugar will induce an osmotic diuresis of the bowel wall, thus reducing the edema and increasing the chances of a successful reduction.
- Place a gauze sponge over the prolapsed bowel and apply gentle constant pressure to the os of the stoma.
- Giving the patient pain medication or muscle relaxant may aid in this process as well.
- If manual reduction is successful, then the patient may undergo elective repair.
- Inability to reduce the stoma or ischemic bowel is an indication for emergent surgical intervention.
- Operative approach depends on whether the ischemia extends below the fascia.
- Most cases of incarcerated and ischemic stoma prolapse require resection of the prolapsed segment using the existing stoma site, with creation of a new stoma.
- A laparotomy is necessary if operating through the stoma site does not allow adequate access for resection of the ischemic bowel segment, or adequate mobilization of proximal bowel for a new stoma.
- Other indications for surgical management for a prolapsing stoma include pouching difficulty, obstruction, and pressure necrosis or bleeding due to a traumatized stoma.

Stomal Retraction

- Stoma retraction occurs when the bowel wall pulls away from the skin, causing the os of the stoma to sit below skin level.
- Risk factors for stomal retraction include inadequate mobilization of the bowel at the time of initial stoma creation, a thick abdominal wall, a short mesentery, and emergency surgery.
- This complication often occurs in the early postoperative period.
- If it occurs within a week of the initial operation, then it is worth considering reoperation for stoma revision to avoid the long-term sequelae associated with retraction.
- If it occurs more than a week from the time of initial operation, then reoperation may be ill-advised due to dense postoperative adhesions that are likely to preclude the additional mobilization that is needed to fix the problem.
- It is important to determine whether the bowel has retracted below the fascia, as retraction below the fascia may cause intraabdominal stool spillage and is an indication for operative intervention.
- If one encounters obliterative adhesions that preclude mobilization of the bowel, then a safer surgical strategy may involve bringing up a proximal loop stoma in a separate location.
- If stoma retraction occurs too far after the initial operation to safely reoperate, and the distal end of the stoma is above the level of the fascia, then the mainstay of management is pouching strategies that will minimize damage to the peristomal skin and maintain a seal.

Stoma Ischemia

- Risk factors for ischemia of the stoma include a thick abdominal wall, small stoma defect size

relative to the bowel caliber, and excessive dissection or tension of the mesentery.

- The bowel wall may not demonstrate obvious signs of ischemia until several days after the operation. Similar to the case of stoma retraction, it is important to determine whether the ischemia extends below the fascia.
- If the ischemia only involves the bowel above the fascia, then the ischemic mucosa will slough off with time, and usually does not require reoperation.
- Ischemia extending below the fascia is an indication for operative intervention.
- If the cause of ischemia is a tight stoma defect, then a local stoma revision to increase the size of the defect and bring up a healthier segment of bowel may be successful.
- Laparotomy will be necessary if mobilization of additional bowel cannot be performed through the stoma site.
- Often a loop-end stoma is necessary to preserve adequate mesenteric blood flow in the setting of a thick abdominal wall and a short mesentery.

Stoma Stenosis

- Stoma stenosis often occurs in conjunction with stomal retraction, which allows the skin of the stoma defect to close concentrically over the os.
- The most effective way to manage stoma stenosis is surgical revision, but patients who cannot undergo operative intervention may undergo stoma dilations.
- Dilations can be performed in the office setting or under sedation in the operating room, depending on the patient's comfort level.

Mucocutaneous Separation

- Mucocutaneous separation, when the edge of the bowel wall separates from the skin edge at the border of the stoma, occurs as a result of poor wound healing.
- The crevice that is formed by the separation presents a challenge for pouching, and patients may find it difficult to maintain an intact seal around the stoma.
- The key elements to managing this complication are tokeep the peristomal skin in good condition, optimize nutrition, and to employ local wound care techniques to fill in the trough and induce granulation of the wound.
- However, poorly constructed stomas, high-output stomas, and stomas located in suboptimal sites on the abdominal wall are associated with pouching difficulties, appliance leaks, skin breakdown, and poor quality of life.
- In many cases, a temporary or permanent stoma may be a major improvement toquality of life.
- For example, patients with severe medically-refractory inflammatory colitis usually find that having an end ileostomy is far superior to suffering with frequent, painful bloody bowel movements.
- In the decisionmaking processes that involve choices between options that result in a permanent stoma versus options that result in intestinal continuity, patients must be counseled that intestinal continuity does not always equal a better quality of life than a permanent stoma.[15]
- For example, patients undergoing operations for distal rectal cancer may find that a low pelvic anastomosis is extremely disruptive due to clustering of bowel movements, frequency, and urgency. In severe cases, a permanent colostomy may be preferable.[16]
- Surgeons must engage patients in a shared decision making process to help make treatment decisions that will offer optimal quality of life outcomes.

MATERIALS AND METHODS

Inclusion Criteria

- **Inclusion Criteria**

1) Patients more than 30 years of age and less than 60 years of age in both sexes presenting with left sided large bowel obstruction due to malignant and non malignant causes.
2) Patients undergoing temporary diversion loop ileostomy or transverse loop colostomy for defunctioning colorectal anastomosis as emergency or elective procedure.
3) Patients undergoing ileostomy or colostomy reversal within the period of study.
4) Patients consented for inclusion in the study according to designated proforma.

Exclusion Criteria

1) Patients not consented for inclusion in the study.
2) Patients less than 30 years of age.
3) Patients more than 60 years of age.
4) Patients who are inoperable.
5) Patients in whom colorectal anastomosis is not done.
6) Patients who have very severe anaemia.
7) Patients who have previous history of stoma creation and reversal.

METHODOLOGY

- In this study, patients more than 30 years of age and less than 60 years of age presenting with features of intestinal obstruction due to left sided large bowel obstruction due to malignant or non malignant causes who are admitted during 2019-2020 will be recruited in this study.
- The cases are selected with diagnosis of intestinal obstruction diagnosed by physical examination, radiological investigation
- Baseline laboratory investigations, plain X-ray abdomen for all patients and other investigations done appropriately (CT or MRI)
- All the patients are managed with IV fluids, blood if needed, preparation of bowel before taking up for surgery in elective cases
- Patients are takenup for surgery and resection of left sided large bowel either limited resection or left hemicolectomy with colorectal anastomosis and proximal diversion ostomy either loop ileostomy or

transverse loop colostomy whichever is feasible is done.

- A proforma was devised and cases were followed.

Statistical Analysis

- Data to be entered in Microsoft Excel and analysed using SPSS software latest version.
- Categorical datas will be represented as Mean and Standard Deviation.
- Results will be represented as Graphs and Table.

RESULTS

Age Distribution

In my study age distribution was studied and the mean age in loop ileostomy group was 50.4 and the mean age in loop colostomy group was 48.4.

Table 1: Age Distribution.

AGE	LOOP ILEOSTOMY	LOOP COLOSTOMY
31-40	3	2
41 - 50	8	15
51-60	14	8
TOTAL	25	25
MEAN	50.44	48.44
SD	6.789	5.598
P VALUE	0.261 Not significant	

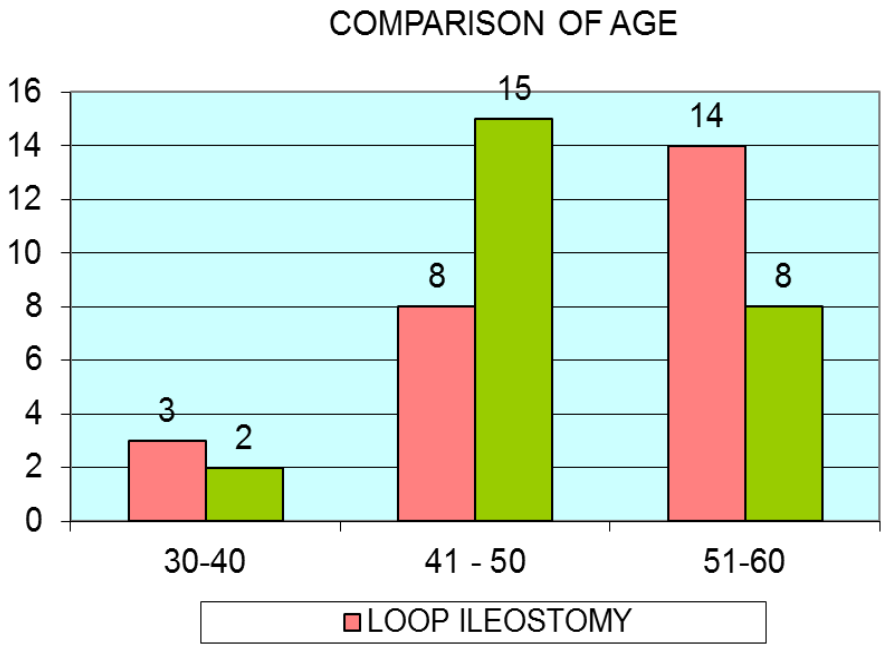

Figure 1: Age Distribution.

Sex Distribution

In my study sex distribution was studied and the male female ratio in loop ileostomy group was 2.5: 1 and the male female ratio in loop colostomy group was 1.5: 1.

Table 2: Sex Distribution.

Sex	Loop ileostomy	Loop colostomy
MALE	18	15
FEMALE	7	10
total	25	25
Chi square value	0.357	
p value	0.55 Not significant	

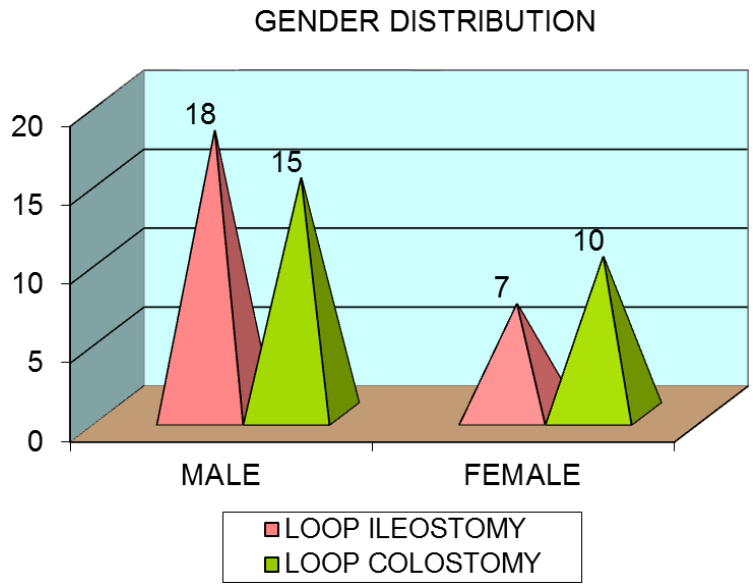

Figure 2: Sex Distribution.

Wound Infection

In my study wound infection was studied and the wound infection in loop ileostomy group was 8% and the wound infection in loop colostomy group was 40%.

Table 3: Wound Infection.

Wound infection	Loop ileostomy	Loop Colostomy
YES	22	10
NO	3	15
total	25	25
Chi square value	10.503	
p value	0.001 Significant	

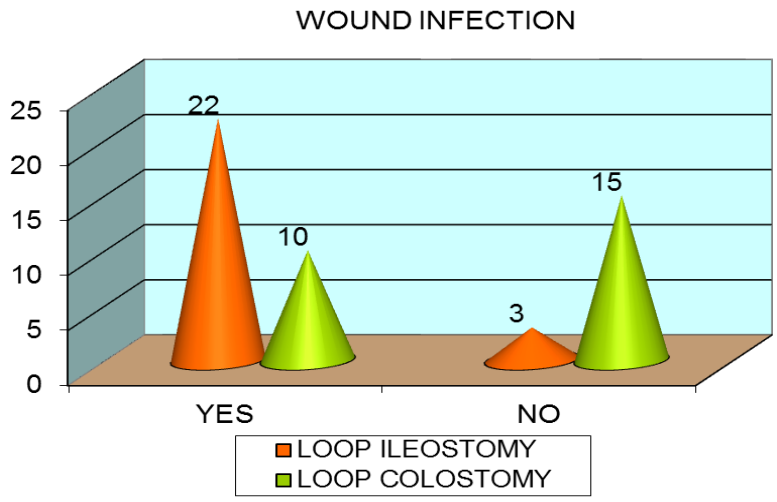

Figure 3: Wound Infection.

High Output

In my study high output was studied and the high output in loop ileostomy group was 36% and the high output in loop colostomy group was 4%.

Table 4: High Output.

High output	Loop ileostomy	Loop colostomy
YES	9	1
NO	16	24
total	25	25
Chi square value	6.125	
p value	0.013 Significant	

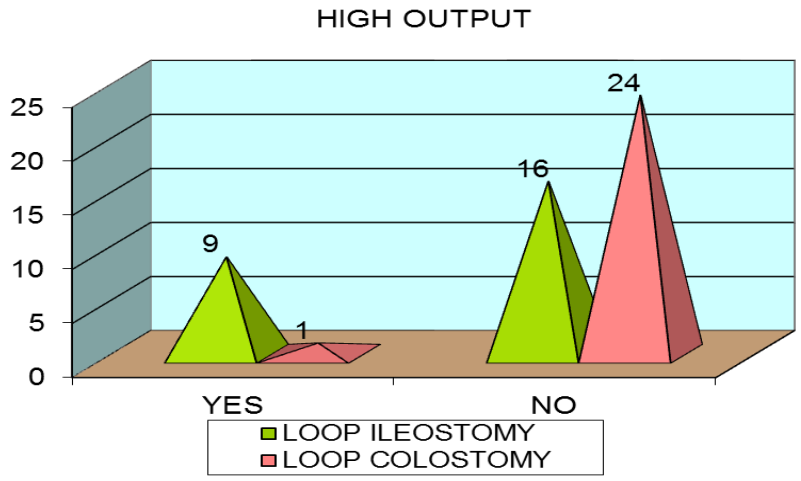

Figure 4: HIGH OUTPUT.

Skin Irritation

In my study skin irritation was studied and the skin irritation in loop ileostomy group was 36% and the skin irritation in loop colostomy group was 4%.

Table 5: Skin Irritation.

Skin Irritation	Loop Ileostomy	Loop Colostomy
YES	9	1
NO	16	24
total	25	25
Chi square value	6.125	
p value	0.013 Significant	

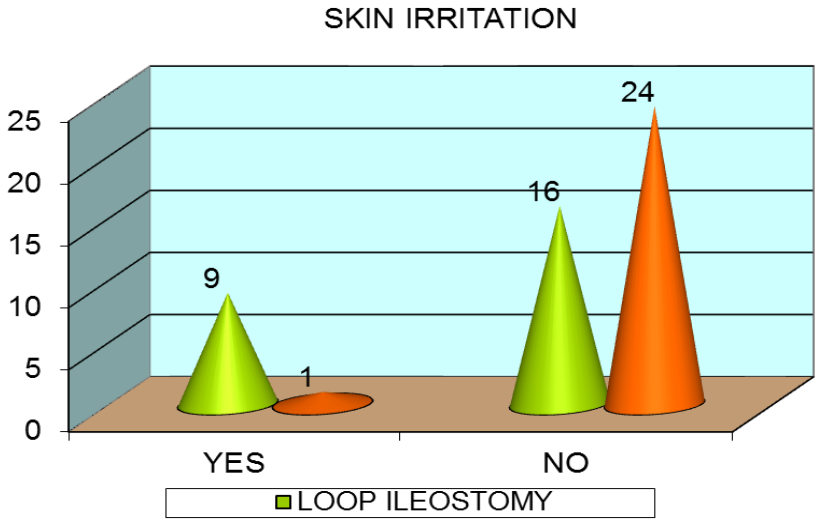

Figure 5: Skin Irritation.

Stoma Prolapse

In my study stoma prolapse was studied and stoma prolapsed in loop ileostomy group was 0% and stoma prolapse in loop colostomy group was 24%.

Table 6: Stoma Prolapse.

Stoma prolapse	Loop ileostomy	Loop colostomy
YES	0	6
NO	25	19
total	25	25
Chi square value	4.735	
p value	0.031 Significant	

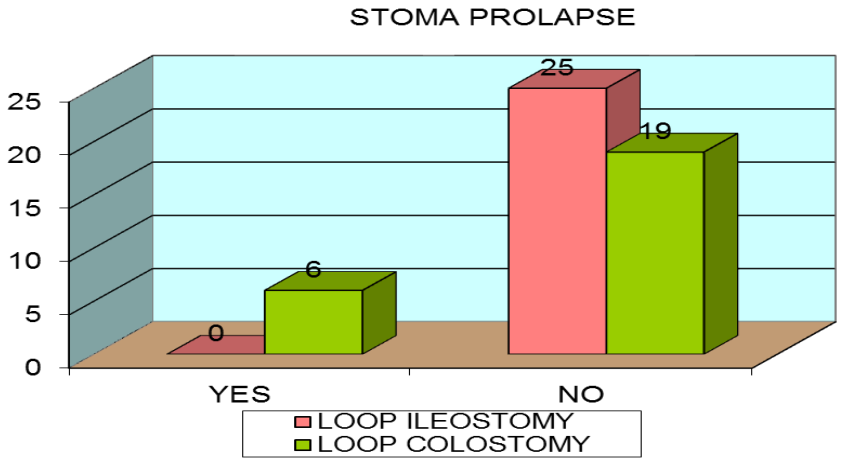

Figure 6: Stoma Prolapse.

Stoma Retraction

In my study stoma retraction was studied and stoma retracted in loop ileostomy group was 4% and stoma retracted in loop colostomy group was 24%.

Table 7: Stoma Retraction.

Stoma retraction	Loop ileostomy	Loop colostomy
YES	1	6
NO	24	19
total	25	25
Chi square value	2.658	
p value	0.103 Not significant	

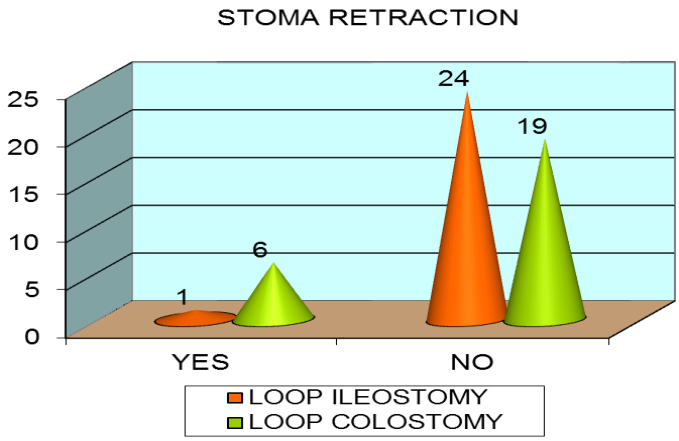

Figure 7: Stoma Retraction.

Parastomal Hernia

In my study parastomal hernia was studied and stoma prolapsed in loop ileostomy group was 0% and parastomal hernia in loop colostomy group was 24%.

Table 8: Parastomal Hernia.

Parastomal hernia	Loop ileostomy	Loop colostomy
YES	0	6
NO	25	19
total	25	25
Chi square value	4.735	
p value	0.031 Significant	

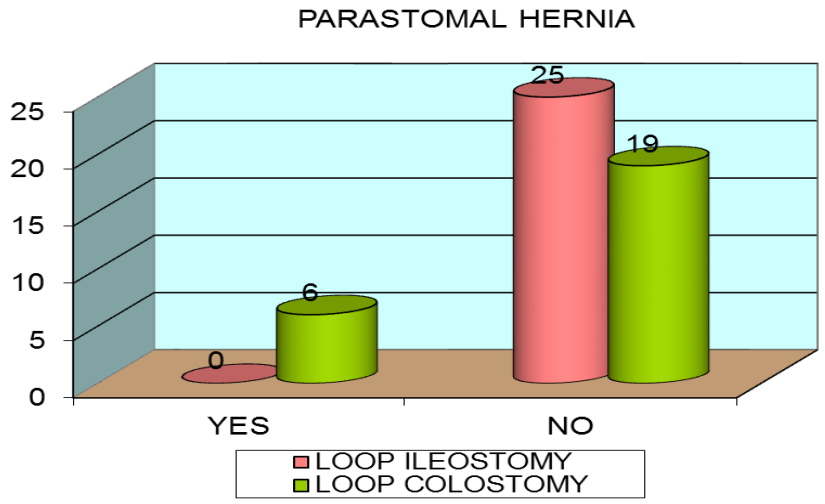

Figure 8: Parastomal Hernia.

Mortality Due to Stoma Related

In my study mortality due to stoma related complications in both groups is 0.

Table 9: Mortality Due to Stoma Related.

Mortality Due To Stoma Related	Loop Ileostomy	Loop Colostomy
YES	0	0
NO	25	25
total	25	25
p value	1.0 Not significant	

Time For Stoma Reversal (Days)

In my study average time taken for stoma reversal in loop ileostomy group was 72.16 days whereas in loop colostomy was 94.8 days.

Table 10: Time for Stoma Reversal (Days).

Time for stoma reversal(days)	Loop ileostomy	Loop colostomy
< 70	12	1
71 - 90	13	6
> 90	0	18
TOTAL	25	25
MEAN	72.16	94.8
SD	8.29	10.786
P VALUE	< 0.001 Significant	

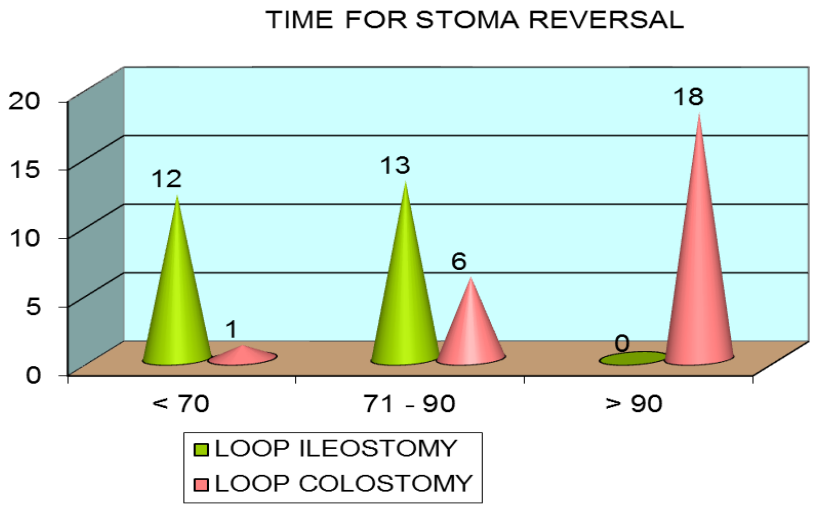

Figure 9: Time for Stoma Reversal (Days).

Time To Pass First Flatus After Reversal

In my study average time taken to pass flatus after stoma reversal in loop ileostomy group was 2.96 days whereas in loop colostomy was 5.44 days.

Table 11: Time To Pass First Flatus After Reversal.

Time To First Flatus After Reversal (Days)	Loop Ileostomy	Loop Colostomy
2	8	0
3	10	0
4	7	3
5	0	8
6	0	14
TOTAL	25	25
MEAN	2.96	5.44
SD	0.79	0.712
P VALUE	< 0.001 Significant	

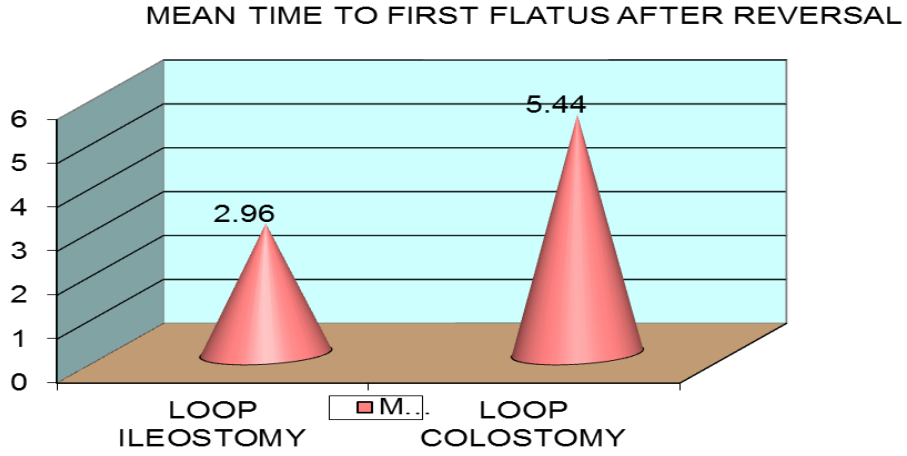

Figure 10: Mean Time To Pass First Flatus After Reversal.

Time To First Defecation After Reversal

In my study average time taken to pass stools after stoma reversal in loop ileostomy group was 3.48 days whereas in loop colostomy was 5.84 days.

Table 12: TIME TO FIRST DEFECATION AFTER REVERSAL.

Time To First Defecation After Reversal (Days)	Loop Ileostomy	Loop Colostomy
3	13	1
4	12	3
5	0	20
6	0	1
7	0	0
TOTAL	25	25
MEAN	3.48	5.84
SD	0.51	0.554
P VALUE	< 0.001 Significant	

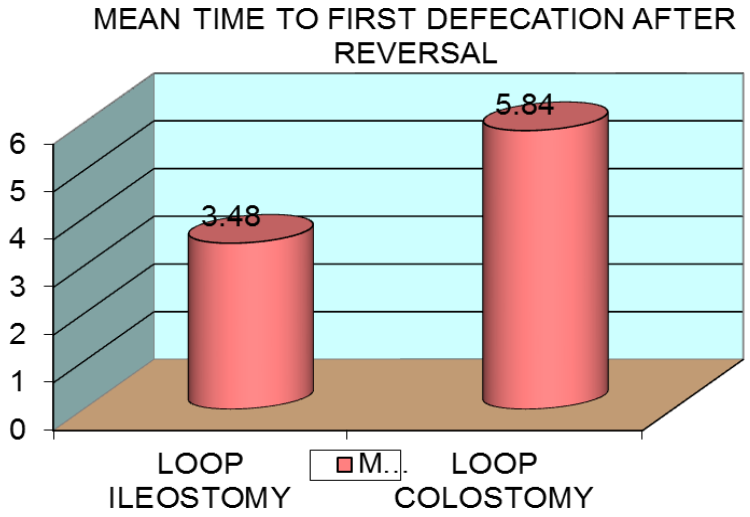

Figure 11: Mean Time To First Defecation After Reversal.

Time to Hospital Discharge

In my study average time taken to hospital discharge after stoma reversal in loop ileostomy group was 6.16 days whereas in loop colostomy was 8.6 days.

Table 13: Time to Hospital Discharge.

Time To Hospital Discharge	Loop Ileostomy	Loop Colostomy
6	21	2
7	4	1
8	0	5
9	0	14
10	0	3
TOTAL	25	25
MEAN	6.16	8.6
SD	0.374	1.041
P VALUE	< 0.001 Significant	

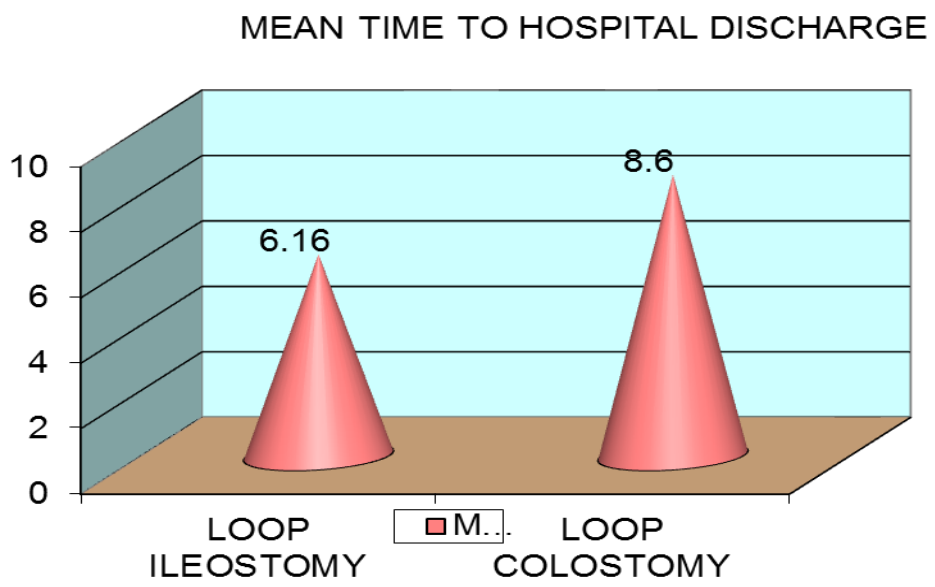

Figure 12: Time To Hospital Discharge.

DISCUSSION

This is a prospective interventional study of 50 patients who presented with left sided large bowel obstruction confirmed with radiological investigations and taken up for surgery. Limited resection of left sided large bowel or left hemicolectomy and colorectal anastomosis done. Proximal diversion loop ileostomy were considered as one group and transverse loop colostomy were considered as another group. Patients are followed for a period of one year JUNE 2019- JUNE 2020.

- Age wise distribution:

In the present study, range was from 30 years to 60 years. Mean age in loop ileostomy group is 50.44 and the mean age in transverse loop colostomy group is 48.44. Age has no statistical significance in the outcomes.

- Sex wise distribution:

In the present study, 18 (72%) patients were males and 7 (28%) were females in loop ileostomy group and 15 (60%) patients were males and 10 (40%) were females in transverse loop colostomy group. Sex has no statistical significance in the outcomes.

- Wound infection:

In the present study, 22 (88%) out of 25 patients in the loop ileostomy group had wound infection and 10 (40%) out of 25 patients in transverse loop colostomy group had wound infection. p value is 0.001- significant.

Whereas in other studies by Williams et al 1986[17] and Edwards et al 2001[18] wound infection in comparing the two groups has no statistical significance.

- High output

In the present study, 9 (36%) out of 25 patients in the loop ileostomy group had high output and 1 (4%) out of 25 patients in transverse loop colostomy group had high output. p value is 0.013- significant.

- Skin irritation

In the present study, 9 (36%) out of 25 patients in the loop ileostomy group had skin irritation and 1 (4%) out of 25 patients in transverse loop colostomy group had skin irritation . p value is 0.013- significant.

Whereas in other studies by Williams et al 1986[17] skin irritation in comparing the two groups has no statistical significance.

- Stoma prolapse

In the present study, 25 patients in the loop ileostomy group had no stoma prolapse and 6 (24%) out of 25 patients in transverse loop colostomy group had skin irritation . p value is 0.031- significant.

In other studies by Williams et al 1986[17] and Edwards et al 2001[18] stoma prolapse in comparing the two groups also had statistically significant difference.

- Stoma retraction

In the present study, 1(4%) out of 25 patients in the loop ileostomy group had stoma retraction and 6 (24%) out of 25 patients in transverse loop colostomy group had stoma retraction. p value is 0.103- not significant.

In other studies by Gooszen AW et al 1998[19], Khoury GA et al 1986[20], and Law WL et al 2002[21] stoma retraction in comparing the two groups also had statistically no significant difference.

- Parastomal hernia.

In the present study, 25 patients in the loop ileostomy group had no parastomal hernia and 6 (24%) out of 25 patients in transverse loop colostomy group had parastomal hernia. p value is 0.031- significant.

In other studies by Gooszen AW et al 1998[19], Edwards et al 2001[18] and Law WL et al 2002[21] parastomal hernia in comparing the two groups had no statistically significant difference.

- Mortality due to stoma related

In the present study no mortality has occurred in both the groups due to stoma related complications and has no statistical difference.

In other studies by Williams et al 1986[17] and Edwards et al 2001[18] mortality due to stoma related complications

in comparing the two groups also had no statistically significant difference.

- Time for stoma reversal (days)

In the present study, average time for stoma reversal (days) in loop ileostomy group was 72.16 and in transverse loop colostomy group was 94.8. p value-<0.001 significant.

Whereas in other study by Edwards et al 2001[18], time for stoma reversal in comparing the two groups has no statistical significance.

- Time to first flatus after reversal (days)

In the present study, average time to first flatus after reversal (days) in loop ileostomy group was 2.96 and in transverse loop colostomy group was 5.44. p value-<0.001 significant.

Whereas in other study by Edwards et al 2001[18], time to first flatus after reversal in comparing the two groups has no statistical significance.

- Time to first defecation after reversal (days)

In the present study, average time to first defecation after reversal (days) in loop ileostomy group was 3.48 and in transverse loop colostomy group was 5.84. p value-<0.001 significant.

Whereas in other study by Edwards et al 2001[18], time to first defecation after reversal in comparing the two groups has no statistical significance.

- Time to hospital discharge (days)

In the present study, average time to hospital discharge after reversal (days) in loop ileostomy group was 6.16 and in transverse loop colostomy group was 8.6. p value-<0.001 significant.

Whereas in other study by Edwards et al 2001[18], time to hospital discharge in comparing the two groups has no statistical significance.

CONCLUSION

Eventhough high output and skin irritation are common in loop ileostomy, increased risk of stoma prolapse and parastomal hernia are common in transverse loop colostomy.

High output and skin irritation can be managed conservatively whereas stoma prolapse and parastomal hernia must be reoperated.

The occurrence of stoma prolapse and parastomal hernia support the choice of loop ileostomy as the technique for faecal diversion for colorectal anastomosis.

REFERENCE

1. Charles J. Yeo, Jeffrey B.Matthews, David W.McFadden, John H.Pemberton, Jeffrey H.Peters. Shakelford's Surgery of the Alimentary Tract.8th ed. China: Elsevier Saunders: 2019. Chapter 71, Anatomy and physiology of small intestine, 817-40.
2. Courtney M. Townsend, Daniel R. Beauchamp, Mark B Evers, Kenneth L.Mattox. Sabiston Textbook of Surgery.20th ed. New Delhi: Elsevier, 2016. Chapter 49, Small intestine; p.1237-8.
3. Peter A Brennan, Susan M Standring, Sam M Wiseman. Gray's Surgical Anatomy. 1st ed. New Delhi: Elsevier; 2019. Chapter 59, Small intestine.
4. 4. Norman S. Williams, Christopher J.K. Bulstrode, P. Ronan O'Connell. Bailey & Love's Short practice of surgery. 27th ed. India: CRC Press Taylor & Francis Group; 2018. Chapter 70, The Large intestine; p1259-71.
5. Watson JD, Aden JK, Engel JE, Rasmussen TE, Glasgow SC. Risk factors for colostomy in military colorectal trauma: a review of 867 patients. *Surgery*, 2014; 155(6): 1052-1061.
6. Mossadegh S, Tai N, Midwinter M, Parker P. Improvised explosive device related pelvi-perineal trauma: anatomic injuries and surgical management. *J Trauma Acute Care Surg*, 2012; 73(2 Suppl1): S24-S31.
7. Glasgow SC, Heafner TA, Watson JD, Aden JK, Perry WB. Initial management and outcome of modern battlefield anal trauma. *Dis Colon Rectum*, 2014; 57(8): 1012-1018.
8. Shah A, Moftah M, Hadi Nahar Al-Furaji H, Cahill RA. Standardized technique for single port laparoscopic ileostomy and colostomy. *Colorectal Dis*, 2014; 16(7): O248-O252.
9. O'Bichere A, Green C, Phillips RK. Randomized cross-over trial of polyethylene glycol electrolyte solution and water for colostomy irrigation. *Dis Colon Rectum*, 2004; 47(9): 1506-1509.
10. O'Bichere A, Bossom C, Gangoli S, Green C, Phillips RK. Chemical colostomy irrigation with glyceryl trinitrate solution. *Dis Colon Rectum*, 2001; 44(9): 1324-1327.
11. Funahashi K, Suzuki T, Nagashima Y, et al. Risk factors for parastomal hernia in Japanese patients with permanent colostomy. *Surg Today*, 2014; 44(8): 1465-1469.
12. Hotouras A, Murphy J, Thaha M, Chan CL. The persistent challenge of parastomal herniation: a review of the literature and future developments. *Colorectal Dis*, 2013; 15(5): e202-e214.
13. Hansson BM, Slater NJ, van der Velden AS, et al. Surgical techniques for parastomal hernia repair: a systematic review of the literature. *Ann Surg*, 2012; 255(4): 685-695.
14. Rubin MS, Schoetz DJ, Matthews JB. Parastomal hernia. Is stoma relocation superior to fascial repair? *Arch Surg*, 1994; 129(4): 413-418; discussion 418-419.
15. Kuruvilla K, Osler T, Hyman NH. A comparison of the quality of life of ulcerative colitis patients after IPAA vs ileostomy. *Dis Colon Rectum*, 2012; 55(11): 1131-1137.
16. Pachler J, Wille-Jørgensen P. Quality of life after rectal resection for cancer, with or without permanent colostomy. *Cochrane Database Syst Rev*, 2012; 12: CD004323.
17. Williams NS, Nasmyth DG, Jones D, Smith AH. Defunctioning stomas: a prospective controlled trial

comparing loop ileostomy with loop transverse colostomy. Br J Surg, 1986; 73: 566-70.
18. Edwards DP, Leppington-Clarke A, Sexton R, Heald RJ, Moran BJ. Stoma-related complications are more frequent after transverse colostomy than loop ileostomy: a prospective randomized clinical trial. Br J Surg, 2001; 88: 360-3.
19. Gooszen AW, Geelkerken RH, Hernans J, Lagaay MB, Gooszen HG. Temporary decompression after colorectal surgery: randomized comparison of loop ileostomy and loop colostomy. Br J Surg, 1998; 85: 76-9.
20. Khoury GA, Lewis MC, Meleagros L, Lewis AA. Colostomy or ileostomy after colorectal anastomosis? A randomized trial. Ann R Coll Surg Engl, 1986; 69: 5-7.
21. Law WL, Chu KW, Choi K. Randomized clinical trial comparing loop ileostomy and loop transverse colostomy for fecal diversion following total mesorectal excision. Br J Surg, 2002; 89: 704-8.