

TOTAL WRIST ARTHRODESIS: LAST RESORT IN THE FACE OF A DEGENERATIVE WRIST

Tarik El Mountassir*, Yassine Benbouzid, Moncef Boufettal, Reda Allah Bassir, Mohamed Kharmaz, Moulay Omar Lamrani and Mohamed Saleh Berrada

Department of Orthopedic Surgery, Ibn Sina Hospital, University Mohamed V, Faculty of Medicine of Rabat, Avenue Mohamed Belarbi El Alaoui B.P.6203 10000, Rabat. Morocco.

*Corresponding Author: Tarik El Mountassir

Department of Orthopedic Surgery, Ibn Sina Hospital, University Mohamed V, Faculty of Medicine of Rabat, Avenue Mohamed Belarbi El Alaoui B.P.6203 10000, Rabat. Morocco.

Article Received on 05/05/2021

Article Revised on 25/05/2021

Article Accepted on 15/06/2021

ABSTRACT

The indication for total wrist arthrodesis is frequent in severe symptomatic lesions of the degenerative wrist. Destructive involvement of the first row of carpal bones makes it difficult to remove and position with the risk of delayed union or pseudarthrosis. Proximal row carpectomy (PRC) in severe involvement has been described. We present the clinical observation and result of a 58-year-old patient operated by these two techniques combined.

KEYWORDS: Total wrist arthrodesis –PRC.

INTRODUCTION

Whatever the etiology of the "degenerative wrist", the pains, the reasons for the consultation, are readily accompanied by a decrease in strength and mobility. Post-traumatic causes dominate, followed by metabolic diseases, the sequelae of inflammatory diseases, and finally osteonecrosis of the lunate. Total arthrodesis is a last resort intervention that provides high satisfaction and effective pain relief in most patients. The main goal of adaptive wrist therapy is to achieve indolence, maintaining strength and mobility where possible. The aim of this work was to evaluate the results of total wrist

arthrodesis associated with PRC in the post-traumatic degenerative wrist.

OBSERVATION

This is a 58-year-old patient, right-handed, manual laborer, with a history: a trauma to the right wrist 3 years ago neglected by the patient. The patient currently presented with an intermittent painful background with relapsing remissions which responded poorly to the usual analgesic treatment. The story worsened 5 months ago with repercussions on daily activities and decreased range of motion as well as muscle strength compared to on the opposite side.

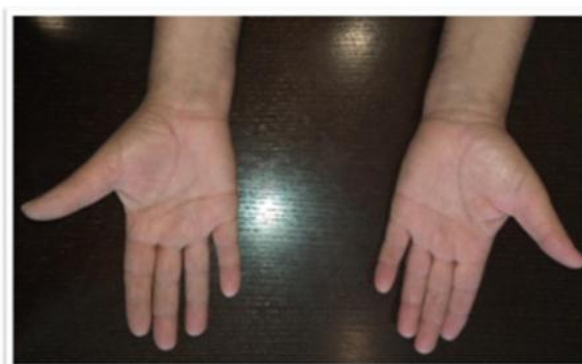
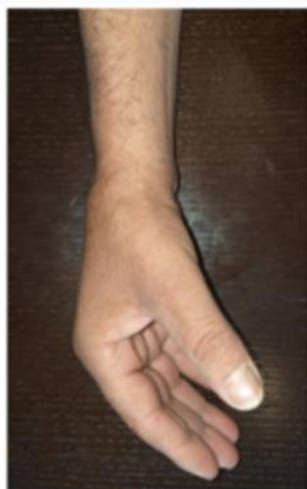
Fig1: No muscular atrophy, the wrist slightly swollen, without other associated signs

On clinical examination

The right wrist slightly swollen on its dorsal surface, pain on palpation of the radial styloid, limited range of motion as well as reduced clamping force (Fig. 1).

Radiographic assessment showing: total radiocarpal and mid-carpal joint pinching, very significant degenerative changes in the bones of the 1st row, with osteoarthritis lesions on the capitatum. (Fig. 2)

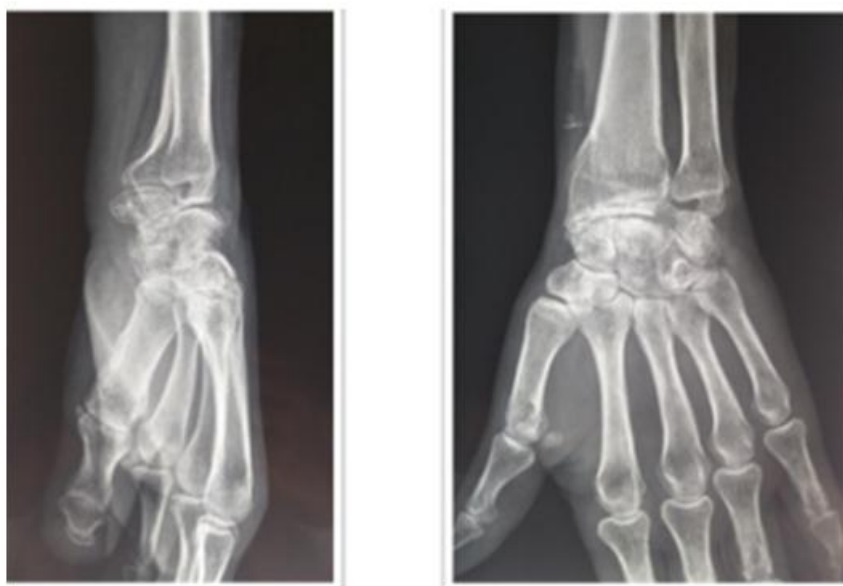

Fig 2: Total destruction of the radio-carpal joint, with changes to the radio-lunar new joint.

SURGICAL TECHNIQUE

Via an elongated S-shaped approach going 3cm downstream from the radiocarpal joint and heading towards the 3rd ray (a).

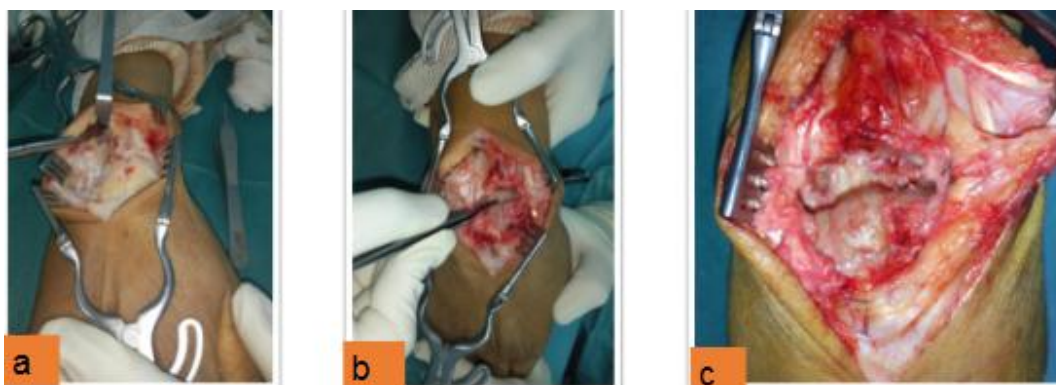
Posterior denervation of the wrist, Z-shaped opening of the dorsal carpal annular ligament (b, c)

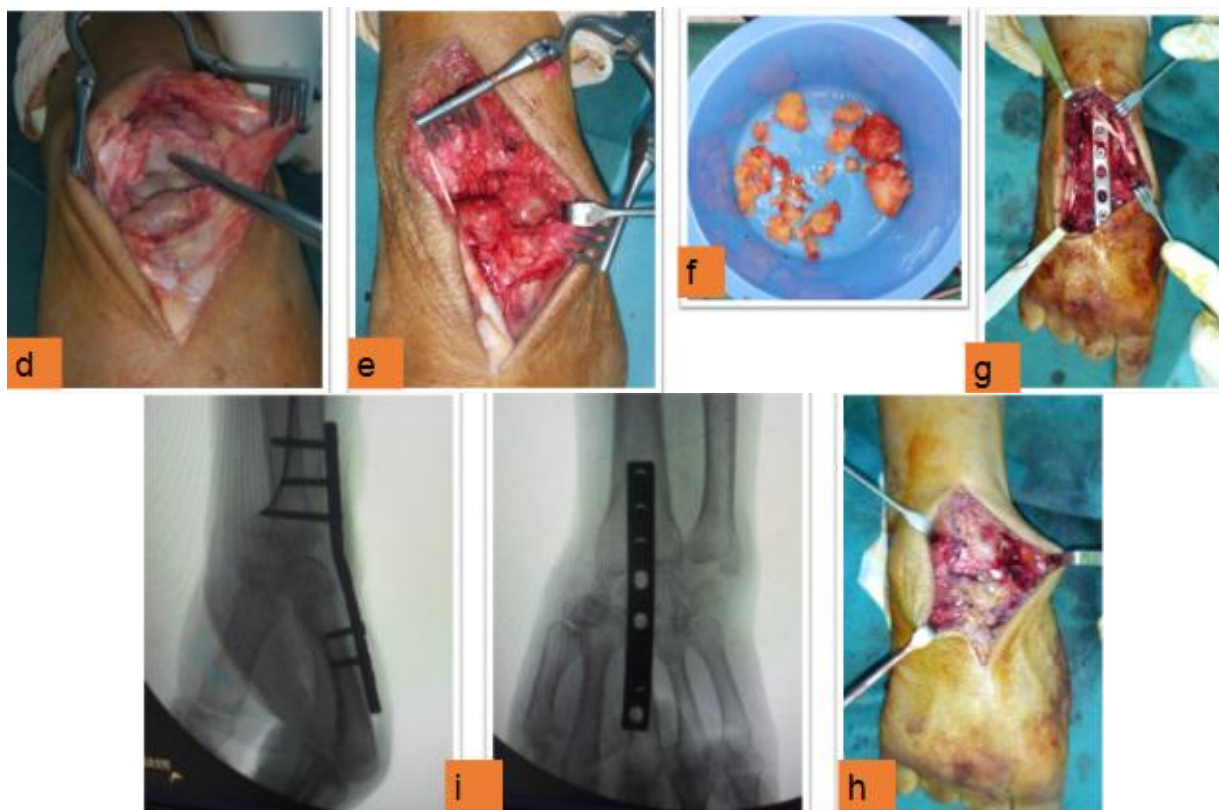T-shaped opening of the posterior capsule discovered of an anterior dislocation of the bones of the 1st row, with the presence of a second radio-lunar cavity (d).

The proximal pole was destroyed as well as the capitate head cartilage and resection of the bones of the 1st row,

which were fragmented (e, f). We also performed a scaphoidectomy (scaphoid was hypermobile), then eagerly joint surfaces (radial glenoid, head of the capitate) (f). The fixation was with the wrist in the functional position (25 ° of extension, and in a slight ulnar inclination) (g), with the installation of a DCP plate that was molded to match the fixation position with 3 radial sockets and 2 on M3.

Finally, closing shot by shot (h). (Satisfactory frontal and lateral fluoroscopic control), Spongy grafting (obtained from the proximal row carpectomy (PRC)) (i).





RESULTS

At 12 months follow-up, the average pain was 2/10 on the EVA pain scale. The average PRWE scores (Patient Rated Wrist Evaluation)^[1] was 25. The grip strength of the operated limb reported to the contralateral was 89%. The patient was satisfied. Consolidation was obtained at 6 months. No influence of the loss of carpal height on the

clinical and radiological parameters evaluated was demonstrated. No real gene linked to the lack of mobility and the patient resumed the same work (the sacrifice of mobility was not experienced as a handicap, the repercussions linked to the loss of mobility being considered as absent for the patient).

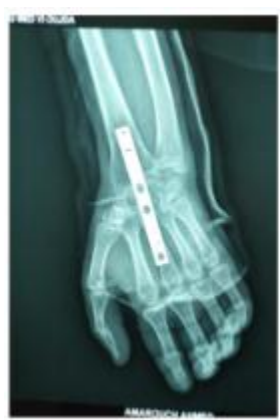
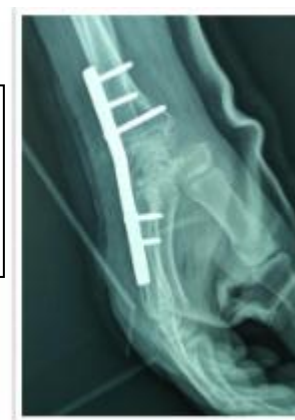
Fig 3: Total arthrodesis (TA) by first-line plate 6 weeks after the operation.



DISCUSSION

While providing results that can be superimposed on data from the literature, performing RPRC associated with arthrodesis has many advantages: simplification of the procedure; a single joint space to merge; use of the resected bones as a bone graft. The expected deleterious effects such as loss of strength or the appearance of digital deformities have not been encountered.^[2] The success rate is higher if the intervention is offered early with better predictability of the result. The early failure

of a palliative intervention is incompletely caught up by AT.^[3] If the wrist involvement (and / or the context) has a poor prognosis and the functional demand is high, AT gives a reliable result in one step^[4] and, more often than not, allows the resumption of the same work.

CONCLUSION

Total wrist arthrodesis associated with PRC provides results equivalent to conventional techniques while simplifying the procedure.

CONSENT

The patients have given their informed consent for the case to be published.

Competing Interests

The authors declare no competing interest.

Authors 'Contributions

All authors have read and agreed to the final version of this manuscript and have equally contributed to its content and to the management of the manuscript.

REFERENCES

1. Hayden RJ, Jebson PJ. Wrist arthrodesis. *Hand Clin.*, 2005; 21: 631—40.
2. Hérard J, Cohen G, Bacle G, Laulan J. Résultats des arthrodèses totales du poignet par plaque dédiée. À propos de 30 cas évalués à 5 ans de recul. *Chir Main*, 2008; 27: 283—4.
3. Jebson PJ, Adams BD. Wrist arthrodesis: review of current technique. *J Am Acad Orthop Surg.*, 2001; 9: 53—60.
4. Bazelli R, Lascar T, Laulan J. Arthrodèses du poignet : partielles ou totales ? *Chir Main*, 2000; 19: 331.