

**FIBROUS DYSPLASIA OF THE TEMPORAL BONE COMPLICATED BY
CHOLESTEATOMA: A CASE REPORT****Ihssane Allouch^{1,3}, Niema Benkhraba^{1,3*}, Hanaa Rahim^{1,3}, Najwa Belhaj^{1,3}, Bencheikh Razika^{2,3}, Benbouzid Mohamed Anas^{2,3} and Leila Essakalli Houssyni^{2,3}**¹Resident physician in otorhinolaryngology, Department of Otorhinolaryngology, Head and Neck Surgery, Ibn Sina University Hospital, Rabat, Morocco.²Professor of otorhinolaryngology, Department of Otorhinolaryngology, Head and Neck Surgery, Ibn Sina University Hospital, Rabat, Morocco.³Faculty of Medicine and Pharmacy of Rabat, Mohammed V University, Rabat, Morocco.***Corresponding Author: Niema Benkhraba**

Resident physician in otorhinolaryngology, Department of Otorhinolaryngology, Head and Neck Surgery, Ibn Sina University Hospital, Rabat, Morocco.

Article Received on 03/05/2021

Article Revised on 23/05/2021

Article Accepted on 13/06/2021

ABSTRACT

Fibrous dysplasia is an uncommon benign bone disorder of unknown origin. It rarely affects the temporal bone. We report a case of fibrous dysplasia of the temporal bone with cholesteatoma, the first complaint of which was right purulent otorrhea, otalgia and hypoacusia. The CT scan found a cholesteatoma extended with fibrous dysplasia of the mastoid. A tympanoplasty using an open technique was performed. We discuss the characteristics of this condition, its differential diagnosis and its treatment.

KEYWORDS: Fibrous dysplasia, benign bone disorder, cholesteatoma, surgery.**INTRODUCTION**

Fibrous dysplasia is an uncommon benign bone disorder of unknown etiology. This abnormality of bone formation was first reported in 1937 by McCune and Bruch, and Lichtenstein named it fibrous dysplasia (1). It has three clinical types: monostotic type (Monostotic fibrous dysplasia), involving only one bone (70%), polyostotic type, involving multiple bones (30%), and McCune Albright's syndrome, a polyostotic type associated with skin pigmentation, precocious puberty and endocrinopathies (3%). It rarely affects the temporal bone. We report the case of a patient with fibrous dysplasia of the temporal bone that was complicated by cholesteatoma.

CASE REPORT

This is a 44-year-old patient, with a history of pulmonary tuberculosis treated and declared to be cured, who presents intense right otalgia evolving for 1 month, associated with right hypoacusia, purulent right otorrhea resistant to local and general antibiotic treatment, without tinnitus and dizziness. Clinical examination found a right pre-auricular tumefaction involving the right parotid region, firm, painful, well limited going back to the right temporal region and associated with trismus. Otoloscopic examination finds a budding tissue filling involving the entire external auditory canal associated with purulent otorrhea, without peripheral

facial paralysis and without associated cervical lymphadenopathy. Tonal audiometry shows an average conductive hearing loss of about 50 dB on the right. The CT scan revealed a right temporomastoid fibrous dysplasia with highly aggressive chronic cholesteatomatous right otitis and right temporomandibular cellulitis. A biopsy of the external auditory canal was performed showing an appearance compatible with a cholesteatoma. The patient has received an intravenous antibiotic therapy; he then underwent tympanoplasty of the right ear using an open technique.

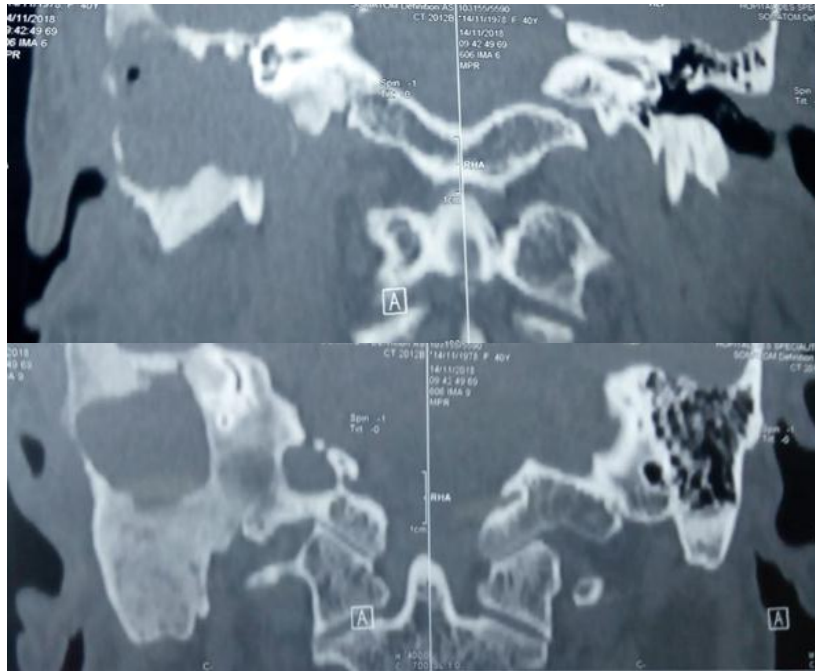


Figure 1: CT-scan: cholesteatoma extended with fibrous dysplasia of the mastoid.

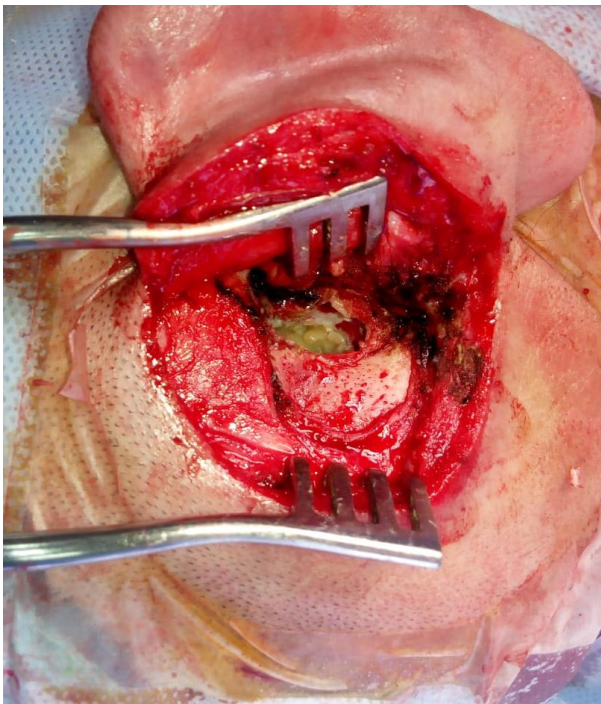


Figure 2: Intraoperative image.

DISCUSSION

Fibrous dysplasia is characterized by replacement of normal bone by fibrous tissue. It usually develops slowly after puberty in the monostotic type, while the polyostotic type usually appears in childhood.^[2]

Monostotic fibrous dysplasia (MFD) lesions usually involve the ribs and femurs. MFD occurs on craniofacial structures in only 10-25% of cases. The maxilla and mandible are the most commonly affected craniofacial

structures.^[3] In the polyostotic type, craniofacial structures are involved in 40 to 60% of cases.^[4]

The most common symptoms of temporal bone fibrous dysplasia are progressive hearing loss (56%), increasing size of the temporal bone (50%), and progressive occlusion of the external auditory canal (42%).^[5] The external auditory canal is involved in 80% of cases.^[6] Stenosis of the external auditory canal causes conductive hearing loss and cholesteatome formation (usually in the external auditory canal). Cholesteatoma occurs in 40% of cases of temporal bone fibrous dysplasia.^[7] The middle ear and inner ear are involved after a long period of external auditory canal stenosis. This sometimes results in sensorineural hearing loss and facial nerve palsy. Sensorineural hearing loss occurs in 14 to 17% of patients, as a result of cochlear destruction, internal auditory canal stenosis, or vestibular fistulization.^[7] Facial nerve palsy is noted in 10% of patients.

Fibrous dysplasia has three types of radiological patterns: pagetoid (56%) with a “ground glass” appearance resulting from a mixture of dense and radiolucent areas of fibrosis, sclerotic (23%) with homogeneous dense areas, and cystic (21%) with a radiolucent ring, oval or round, and surrounded by a capsule of dense bone.^[7] CT is useful in diagnosis and evaluation of the extent of disease.

The differential diagnosis of fibrous dysplasia includes Paget’s disease of bone, osteoma, ossifying fibroma, sarcoma, osteochondroma, and aneurysmal bone cyst.^[6] Radiographic imaging and histological data are also helpful in the diagnosis of fibrous dysplasia.

Surgery should be performed to preserve function, prevent complications, and restore cosmesis. Indications for it are the presence of secondary cholesteatoma, progressive hearing loss, and recurrent infection. Radiation therapy should not be performed, because malignant transformation often occurs (44%).^[8]

Long-term follow-up should be performed, because fibrous dysplasia cannot be removed perfectly and might recur and cause stenosis of the external auditory canal again. CT examination is useful for follow-up.

CONCLUSION

Fibrous dysplasia can cause severe morbidity when it occurs in the temporal and craniofacial bones. Early diagnosis and follow-up is important. This is a clinical rarity, but it should be kept in mind by otologists.

REFERENCES

1. Lichtenstein L. Polyostotic fibrous dysplasia. *Arch Surg*, 1938; 36: 874-98.
2. Papadakis CE, Skoulakis CE, Prokopakis EP, Nikolidakis AA, Bizakis JG, Velegrakis GA, Helidonis ES. Fibrous dysplasia of the temporal bone: report of a case and a review of its characteristics. *Ear Nose Throat J*, 2000; 79: 52-7.
3. Chinski A, Beider B, Cohen D. Fibrous dysplasia of the temporal bone. *Int J Pediatr Otorhinolaryngol*, 1999; 47: 275-81.
4. Casselman JW, De Jonge I, Neyt L, De Clercq C, D'Hont G. MRI in craniofacial fibrous dysplasia. *Neuroradiology*, 1993; 35: 234-7.
5. Nager GT, Kennedy DW, Kopstein E. Fibrous dysplasia: a review of the disease and its manifestations in the temporal bone. *Ann Otol Rhinol Laryngol*, 1982; 92: 1-52.
6. Brown EW, Megerian CA, McKenna MJ, Weber A. Fibrous dysplasia of the temporal bone: imaging findings. *Am J Roentgenol*, 1995; 164: 679-82.
7. Megerian CA, Sofferman RA, McKenna MJ, Eavey RD, Nadol JB Jr. Fibrous dysplasia of the temporal bone: ten new cases demonstrating the spectrum of otologic sequelae. *Am J Otol*, 1995; 16: 408-19.
8. Slow IN, Friedman EW. Osteogenic sarcoma arising in a preexisting fibrous dysplasia: report of case. *J Oral Surg*, 1971; 29: 126-9.