

OSSEOUS METAPLASIA IN BREAST TUMORS: RARE BUT DEADLY

Almutiri Abdullah Bandar*, Kristi Milley, Ebtesam M Aiash, Eman S Abuagiela, Ahmed M Alosaimi, Janine Danks.

Senior Medical Laboratory Scientific Officer (SMLS) / Senior Specialist Histopathology, Cytopathology CT (IAC) and Medical Microbiology. Prince Sultan Military Medical City.

*Corresponding Author: Almutiri Abdullah Bandar

Senior Medical Laboratory Scientific Officer (SMLS) / Senior Specialist Histopathology, Cytopathology CT (IAC) and Medical Microbiology. Prince Sultan Military Medical City.

Article Received on 14/01/2021

Article Revised on 04/02/2021

Article Accepted on 24/02/2021

ABSTRACT

Aims: The type of breast cancer to be investigated is known as metaplastic breast in which one adult cell type is replaced by another adult cell type. Osseous metaplasia is an interesting type of tumour that contains a mixture of cells: It consists of the carcinoma part and bone and/or cartilage. Metaplastic carcinoma appears to be more common in dogs with more than 50% cases while it is less than 1% cases in human. Canine suffer from naturally occurring breast cancer and live in the same environment as humans. The similarity is the main reason for using canine in the clinical studies. This is important in the translation of new studies into human therapies. The aim tool is that the metaplastic carcinomas will be characterized in this project using the dog's breast tissue as a model and by using these five panels of antibodies: Estrogen receptor (ER), epidermal growth factor receptor (HER2), vimentin, Ki67 and CKAE1/AE3 to characterize this tumour. IHC will also be used in the preliminary study of the roll of BMP4, Osteopontin, and RUNX2 which are bone markers. **Methods:** Panels of antibodies used are: HER-2, ER, Vimentin, CKAE1/AE3, Osteopontin, BMP4 and RUNX2 were performed according to the Immunohistochemistry manual protocol in 17 cases from dog breast tissue. **Results:** By using the CKAE1/ AE3 antibody and Vimentin antibody, most of the causes were more Vimentin positivity compared to CKAE1/ AE3 antibody positivity result. When estrogen receptor (ER) anti body was used, the results were negative in most of the causes. For the HER-2 antibody, there was no over expression in all the causes. In terms of proliferation rate, Ki-67 antibody was used and it was found that proliferation rate was low indicating that the tumours are benign (non malignant). For the BMP4 antibody, there was an over expression of this antibody marker in the tumour area of all causes. The osteopontin is associated with poor prognosis in the breast cancer. For the RUNX2, the normal part of the tissue was stained also expressed in breast cancer area in the tissue and appeared to be associated with unfavourable outcomes. **Conclusions:** In conclusion, the aim of the research was partially fulfilled. Since the experiment was not rational and repeatable, our results are not reliable to make a conclusion. However, based on the analysis and the results obtained, we can conclude that some good results were achieved.

KEYWORDS: Bone, cartilage breast cancer, molecular sub typing, canine mammary tumour.

INTRODUCTION

Lumps or masses of tissues often come into existence due to the abnormal growth of cells in an uncontrolled manner. These lumps are referred to as tumours and this disease is known as cancer. Breast cancer is also a form which includes a wide range of heterogeneous illness based on varying molecular, biological, and clinical properties.^[1] Variations in diet, genetic influences, environmental influences, and lifestyles may determine these variations.^[2] A malignant cancerous growth taking place in the tissues of the breast characterizes breast cancer.^[1] Females are majority victims of breast cancer with only a few cases occurring among the males. This is the most common form of cancer in women.^[2] Breast cancer may originate from the inner lining of the milk ducts (ductal carcinomas) or the milk supplying lobules that provide milk to the ducts (lobular carcinomas).^[1]

Humans and other mammals have also been found to suffer from breast cancer.^[3]

Globally, breast cancer constitutes about 22.9% of all the cancers in women. About 458,503 people died due to breast cancer in 2008.^[4] While men may seldom fall victims of breast cancer, they however suffer due to delayed diagnosis.^[4] Compared to men, women are 100 times more susceptible to this kind of disease.

Every woman is at risk of breast cancer as indicated by the recent demographics. A woman may have a risk of getting breast cancer at any time during her lifespan of 85 years. Irrespective of her family history, a woman has increased chances of getting breast cancer with age.^[3,4] Majority of the breast cancers have been found in women aged 50, while fewer than 5% of the cases are found

before the age of 35. This means that the risk of breast cancer in a 25 year old woman is only 1 out of 19,608 which increases to 1 out of 93 by the age 45.^[5]

The rate of survival and prognosis are dependent on the type of cancer, stage of cancer, and the geographical location of the patient.^[4] The tumour size, lymph node, distant metastasis at presentation, tumour grade and histological type, proliferation rate, oestrogen receptor status, and aneuploidy determine the prognosis.^[5,6]

Another type of breast cancer is known as the metaplastic breast in which one adult cell type is replaced by another adult cell type. This is a reversible process.^[7] Processes that cause the reprogramming of the stem cells are normally held responsible for this cancer type.^[6] A wide group of cells with both the sarcomatous and carcinomatous features, including heterologous elements, is referred to as the metaplastic carcinoma of the breast.^[8] The metaplasia of the carcinoma cells lead to these tumours. The presence of a myoepithelial cell origin is confirmed through the ultra structures. Metaplastic carcinoma is a rare type of cancer which constitutes about 1% of all the breast cancers.^[9] The metaplastic carcinoma of the breast may contain bone or the cartilage, as observed through some macroscopic and microscopic studies. This led to the classification of breast cancer into five types. According to the World Health Organization (WHO), these types are as follows: Adenosquamous carcinoma, Mucoepidermoid carcinoma, Squamous cell carcinoma, Adenocarcinoma with spindle cell metaplasia, and Mixed epithelial/mesenchymal metaplastic carcinoma.^[10]

A special type of invasive breast neoplasm in one of the type of breast cancer with cartilaginous or osseous metaplasia found to occur in less than 1% of the cases.^[11] In the mammary cancer tissues, this type of breast cancer is classified as either Cartilaginous or Osseous metaplasia. It is also classified as a transitional zone between the carcinoma and sarcoma-like metaplastic lesions.^[12]

Historical diagnosis is difficult in many cases such as the metaplastic carcinomas which are historically heterogeneous. The presence of glandular and non-glandular components define this unique group of tumour.^[13] The mesenchymal differentiation creates the non-glandular component. It includes cells with spindles, osseous, or cartilaginous features. The clinical presentation of the metaplastic carcinoma will be similar in many reports, but differences may be found in the historical picture.^[14]

The osteosarcoma was found in 1.3% of phyllodes neoplasms with its appearance similar to the skeletal origin, as evident from the histopathological studies of 22 cases of breast cancer.^[15] Osteogenic sarcoma of the breasts increased in a phyllode tumour, as was found in 40% of the cases. The transformation of the connective

tissue elements may have led to the osteogenic sarcomas of the breast, which is sarcomatous in nature as compared to the pre-existing benign breast neoplasms, especially fibroadenomas and intra-ductal papillomas.^[7,15]

Osteogenic sarcoma might seldom represent a non-phyllodes sarcoma of the breast which results from the soft tissues of normal breasts. When malignant bones are created from the breast tumours, then these are known as the metaplastic carcinomas.^[16] After an initial period of being latent, these tumours grow rapidly, which is a haematogenous spread commonly occurring to the lungs.^[11] Other sarcomas of the breast such as malignant melanoma, malignant fibrous histiocytoma, Angiosarcoma, and pleomorphic liposarcoma, may also be found to have the metaplastic bone formation. These instances rarely happen.^[16]

Since the human and canine mammary tumours share many important biochemical features such as epidemiological, clinic-pathological, and morphological features, the canine has been used as models in the recent studies of breast cancer.^[21] As age increased, so did the risk of breast cancer. Both the species have the development of the malignant breast tumour occurring from epithelial tissues, which metastasizes to the lungs or other organs.^[11,12] The body size of canines made them more preferable over rats as it gives an advantage in terms of collection of serum, urine, and serial tissue biopsy samples from the same dog exposed to the experimental conditions.^[13]

The similarity of the hepatic enzyme homology of dogs to the humans is another reason for using canine in the clinical studies. This is important in the translation of new studies into human therapies.^[13] Similarity in the molecular targets is also found in their canines just like humans. This makes them readily usable in the proof-of-target analysis and the proof-of-concept.^[12] The clinical trials can culminate to a faster conclusion due to the short life span of the dogs.^[11,16]

The development and testing of new cancer treatments has been possible due to the integration of pet dogs with cancer in the clinical trials. This will set important objectives for the development of the anticancer therapies, aside from benefitting both humans and canines.^[17]

Majority of the human and canine deaths can be blamed on cancer. In this respect, the canines share clinical, biological, and epidemiological features with human cancer.^[18] These may include aspects of the histological morphology, tumour genetics, molecular targets, biologic behaviour, and response to conventional therapies.^[13,14] The translational cancer research has been benefitted by the valuable input given by the use of naturally occurring cancer in canine, which was made possible by the recently released canine genome sequence showing the

high homology and close similarity with the human genome.^[14,19]

The aim of this project is to characterize metaplastic carcinomas by using breast tissues of dogs as models. Immunohistochemistry (IHC) of six antibodies was performed as markers to characterize tumours. The IHC contains the estrogen receptor (ER), epidermal growth factor receptor (HER2), vimentin, Ki-67 and CKAE1/AE3. IHC also used in the preliminary study of

the role of the following bone markers BMP4, Osteopontin and RUNX2 antibodies.

METHODS AND MATERIALS

Tissue samples

17 cases from dog breast tissue were used and table 1 below summarises all the cases that had been Studied and tumour diagnosis with metaplastic tissue condition in each case.

Table 1: List of all tissue samples and the tumour diagnosis in each cause.

No.	Cases	Tumour diagnosis	Metaplastic tissue
1	10P2-1J	Benign mixed tumour	Cartilage
2	10P8	Benign mixed tumour	Cartilage
3	10P9-1P	Benign mixed tumour	Cartilage
4	10P10-1W	Benign mixed tumour	Cartilage + bone
5	10P12-1C	Benign mixed tumour	Cartilage
6	10P26-1B	Benign mixed tumour	Cartilage
7	10P43-31	Low grade malignant tumour	Cartilage
8	10P49-1D	Benign mixed tumour	Cartilage
9	10P55-1C	Benign mixed tumour	Cartilage +bone
10	10P60-1C	Benign mixed tumour	Cartilage + bone
11	10P66-1D	Benign mixed tumour	Cartilage
12	10P71-2C	Benign mixed tumour	Cartilage ±
13	10P84-1E	Benign mixed tumour	Cartilage +bone
14	10P87	Benign mixed tumour	Cartilage +bone
15	1095-1A	Benign mixed tumour	Cartilage
16	10P99-1C	Malignant tumour	Cartilage
17	10P115	Benign mixed tumour	Cartilage +bone

Table 2: Summary of clone details and antigen retrieval methods for all antibodies.

Antibody	dilution	Clone	Retrieval	Incubation	Source	Control tissue
Anti-ER	1:50	EP1	PH9/20min	30min	Dako, Glostrup, Denmark.	Nirmal canine mammary
Anti-HER-2	Ready to use (RTU)	–	Hercep epi /40min	30min	Dako, Glostrup, Denmark.	Her2+ Cancer
Anti-Ki67	RTU	MIB-1	PH6/20min	30min	Dako, Glostrup, Denmark.	Normal canine mammary
Anti-Vimentin	RTU	V9	High PH/20min	30min	Dako, Glostrup, Denmark.	Mammary tissue
Anti-CKAE1/AE3	RTU	AE1/AE3	High PH/20min	30min	Dako, Glostrup, Denmark.	Skin
Anti-Osteopontin (ab8448)	1:150	Polyclonal	No retrieval	60min	Abcam, Cambridge, UK	Normal canine mammary
Anti-RUNX-2 (ab32981)	1:600	Polyclonal	PH9/20min	30min	Abcam, Cambridge, UK	Normal canine mammary
Anti-BMP-4 (ab39973)	1:100	Polyclonal	PH9/20min	60 min	Abcam, Cambridge, UK	Canine mammary osteosarcoma

Immunohistochemistry manual protocol

Routinely fixed and processed, paraffin-embedded representative tissue sections (4µm thick) of each case were cut and mounted. Immunohistochemistry with antibodies for HER 2, ER, Vimentin, CKA1/AE3, Ki-67, Osteopontin, BMP4 and RUNX2 was performed according to the following protocol: at first, all sections were retrieved for 20 minutes in Dako high PH retrieval

solution (clone details and antigen retrieval methods are summarized in Table 2). Add 200µL from Triton-X for 30 minutes and 200µL from H2O2 block for 10 minutes respectively. After that, 0.4% casein protein block mix for 30 minutes. 200µL primary antibody then will be added for 30 minutes; in this step for the control slides that been used will have different reagents like 200µL for 10 minutes will be added from Dako rabbit to

controls (it is dependent on the controls that have been used). Subsequently, 200 μ L from secondary antibody will be added for 30 minutes. Add 200 μ L of DAB (watch colour change, wash off when good level of brown staining is noted). Note that controls were included in each slide run.^[20,21]

Von kossa staining protocol for calcium

Deparaffinize paraffin sections and hydrate to water. Then rinse in several changes of distilled water. Incubate

sections with 1% silver nitrate solution in a clear glass coplin jar placed under ultraviolet light for 20 minutes. Note: If stain was weak or rinsed off in washing steps, it indicated the UV light was not strong enough. Consequently, rinse in several changes of distilled water. Remove un-reacted silver with 5% sodium thiosulfate for 5 minutes. Rinse in distilled water. Counterstain with nuclear fast red for 5 minutes. Then dehydrate through graded alcohol and clear in xylene. Coverslip using permanent mounting medium.^[22]

RESULTS

Table 3: Summary of Immunohistochemistry findings.

No.	Cases	Vimentin	CKAEA/AE3	HER2
1	10P2-1J	2+	3+	-
2	10P8	2+	2+	-
3	10P9-1P	3+	3+	-
4	10P10-1w	2+	2+	-
5	10P12-1C	3+	2+	-
6	10P26-1B	3+	3+	-
7	10P43-31	2+	3+	-
8	10P49-1D	2+	3+	-
9	10P55-1C	3+	3+	-
10	10P60-1C	3+	3+	-
11	10P66-1D	3+	3+	-
12	10P71-2C	2+	3+	-
13	10P84-1E	3+	3+	-
14	10P87	3+	3+	-
15	10P95-1A	3+	3+	-
16	10P99-1C	3+	2+	-
17	10P115	3+	2+	-

Immunohistochemistry findings are summarized for all cases in table 3 above. It is clearly that by using vimentin and cytokeratins (CKAE1/AE3) antibodies, both of them show a strong positive result. In contrast, human epidermal growth factor 2 (HER2) show negative against HER2 receptor in all cases.

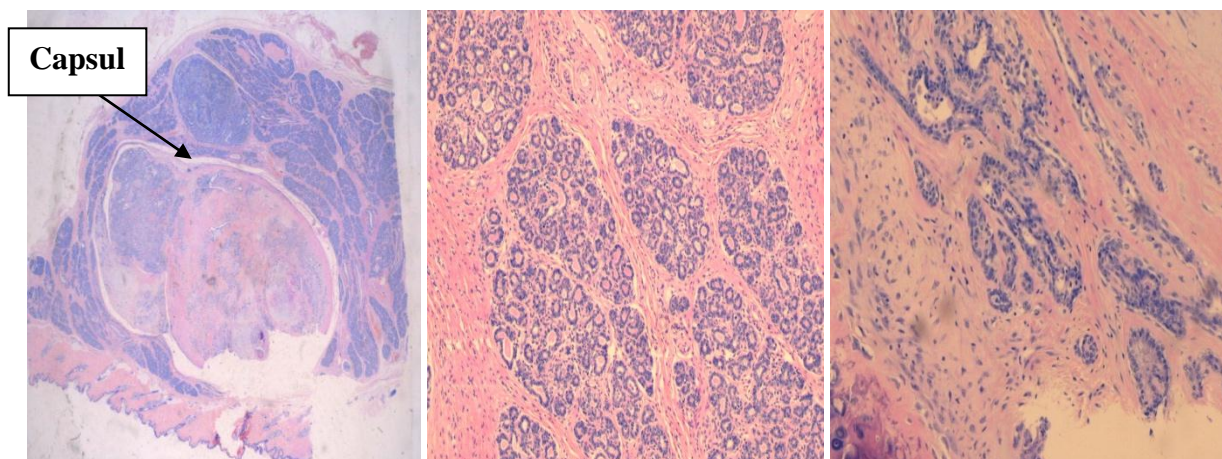


Figure 1: (Case10p84-1E) H&E 4x. Figure2: Normal glands H&E 10x. Figure 3: Abnormal glands H&E 10x.

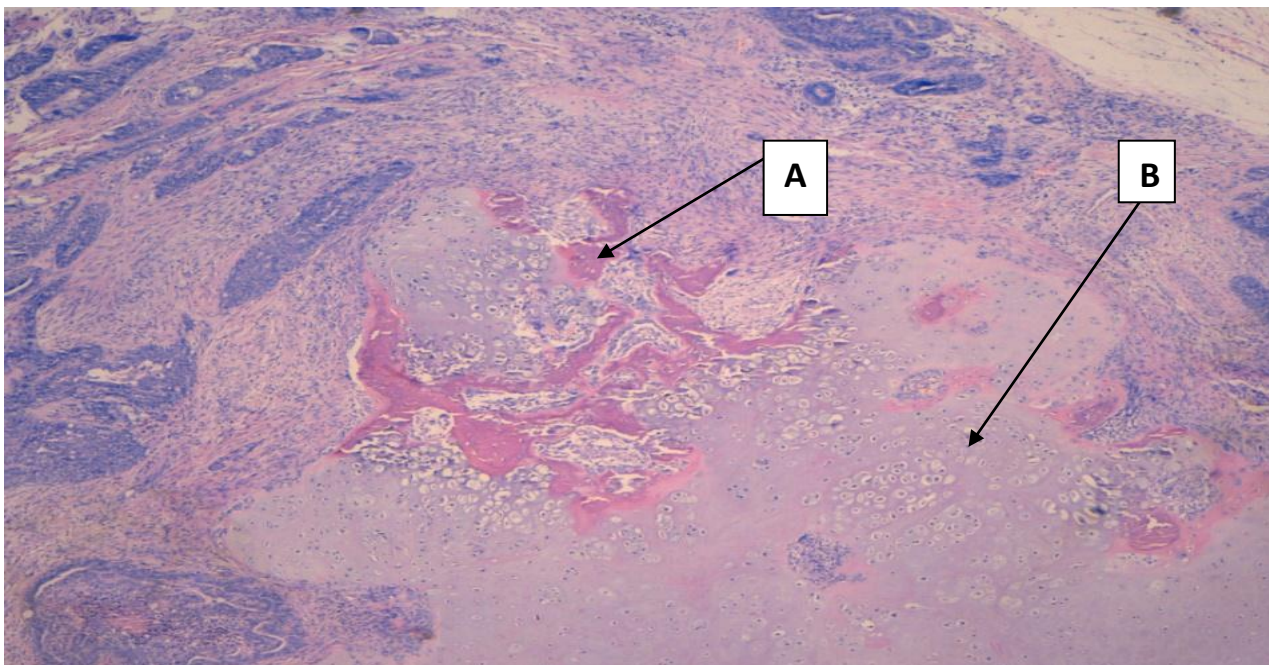


Figure 4: H&E 4x description of osseous metaplasia tumor that contains mixture of cells.

Some photos were taken from the case (10P84-1E) as in figure 1, which shows the tumour area and the normal part of the mammary tissue. It is noted that in most of the cases, the tumours are capsulated as it shown above. Figure 2 shows the normal gland and figure 3 the

abnormal one. In figure 4 it is description of osseous metaplasia tumour that contains a mixture of cells: (A) shows the bone formation in the breast tissue and (B) the cartilage formation in the breast tissue.

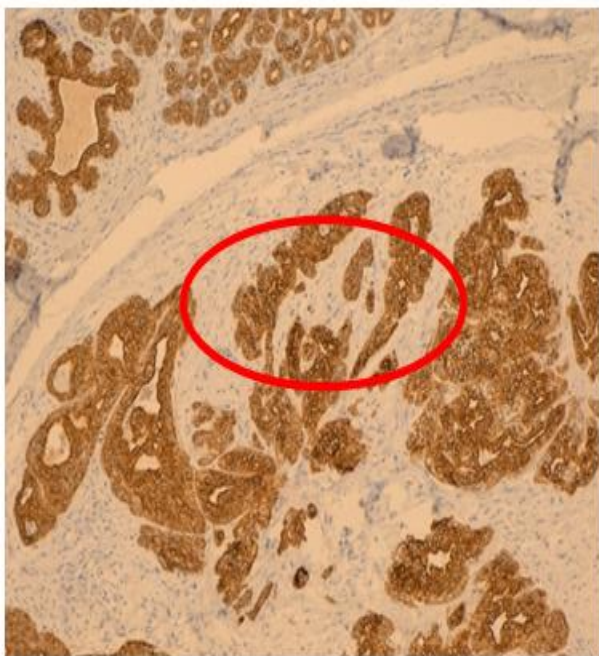


Figure 5: Immunostaining with CKAE1/AE310x (case 10P84).

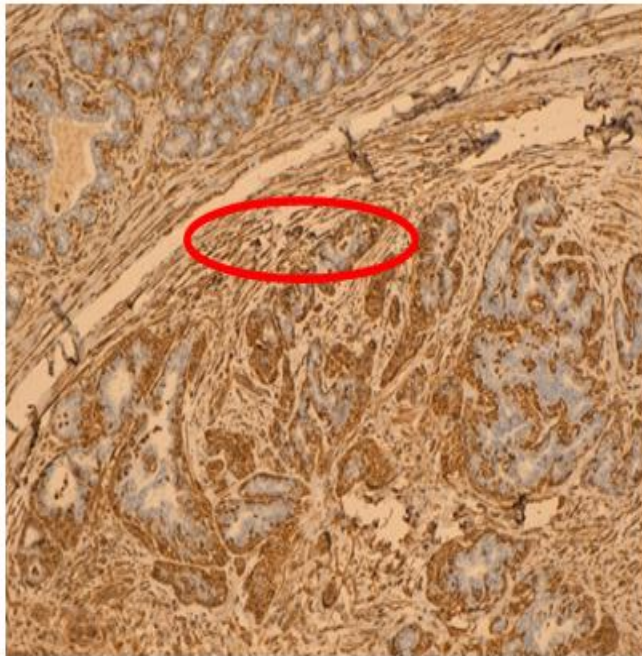


Figure 6: Immunostaining with Vimentin 10x (case 10P84).

In figure5: show that all epithelial cells in glands expressed the antibody in the tumor area. And figure 6 shows mesenchymal part stained.

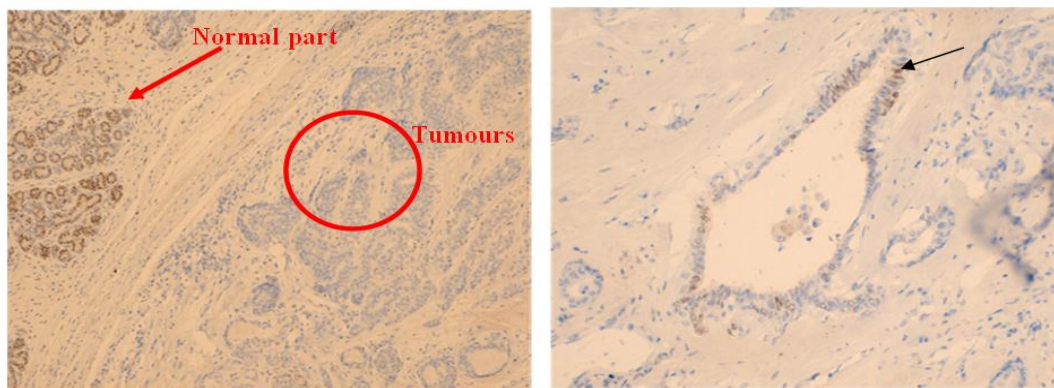


Figure 7: Immunostaining with ER antibody 10x (case10P84). Figure8: Immunostaining with ER antibody 40x (case 10P84).

In figure 7, the capsule defined the normal part from the abnormal part. The normal gland will show positivity agents the ER receptor whereas the tumours in most of the causes were negative for estrogens receptor.

Table 4 shows that all of our causes were negative for ER except two cases (10P60 and 10P115) were positive for estrogens receptor.

Table 4: Summary of Immunohistochemistry findings for ER antibody.

No	Cases	%	ER
1	10P2	30%	-+
2	10P8	-	-
3	10P9	5%	-
4	10P10	17%	-
5	10P12	10%	-
6	10P26	8%	-
7	10P43	-	-
8	10P49	10%	-
9	10P55	10%	-
10	10P60	58%	+
11	10P66	-	-
12	10P71	8%	-
13	10P84	24%	-
14	10P87	17%	-
15	10P95	4%	-
16	10P99	15%	-
17	10P115	42%	+

Table 5: Ki-67 index (proliferation of tumors result).

No	Cases	Ki-67
1	10P2	6%
2	10P8	1%
3	10P9	2%
4	10P10	11%
5	10P12	4%
6	10P26	5%
7	10P43	2%
8	10P49	15%
9	10P55	4%
10	10P60	1%
11	10P66	21%
12	10P71	2%
13	10P84	6%
14	10P87	4%
15	10P95	2%
16	10P99	5%
17	10P115	4%

Regarding the Ki-67 index is for known the proliferation of tumour cells and in most of the cases, the proliferation rate was low (table 5 above).

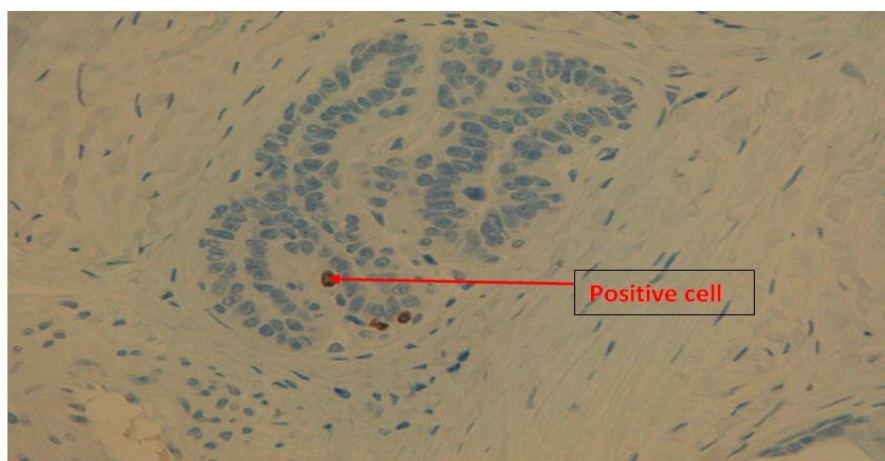


Figure 9: Immunostaining with (Ki-67) antibody, proliferation marker (case10P2) 40x.

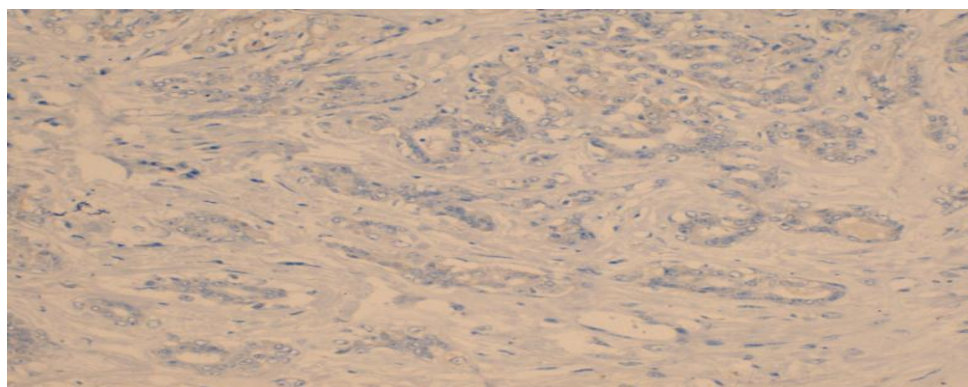


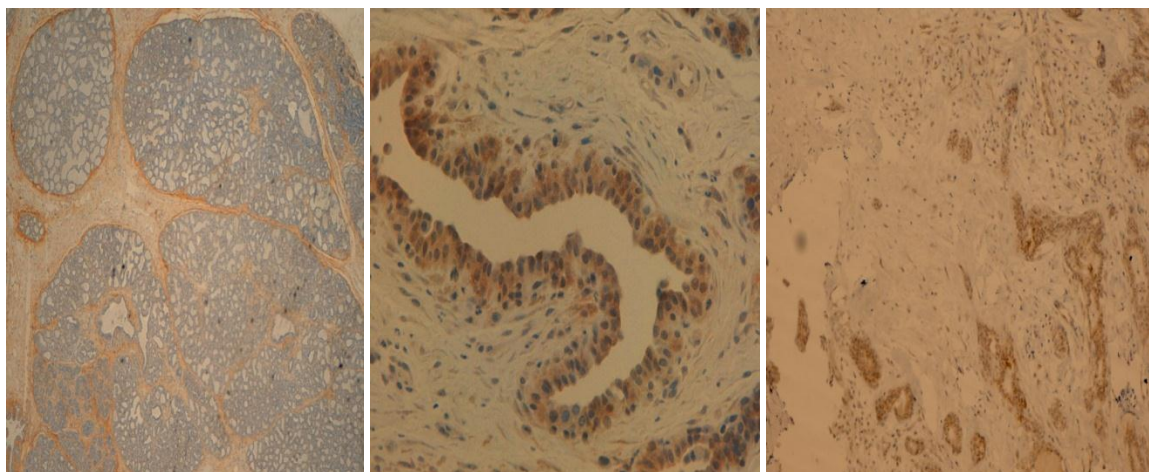
Figure 10: Immunostaining with HER-2 antibody (case10P 84) 20x.

In figure 10 show lace of over expression of HER-2 in this case and this is the result for all cases also.

Table 6: Bone markers results for osteopontin, BMP4 and RUNX-2 antibodies.

No	Cases	osteopontin	BMP4	RUNX-2
1	10P2	2+	2+	2+
2	10P8	3+	1+	2+
3	10P9	2+	1+	2+
4	10P10	2+	2+	1+
5	10P12	3+	2+	2+
6	10P26	3+	2+	2+
7	10P43	3+	1+	2+
8	10P49	3+	3+	2+
9	10P55	3+	3+	2+
10	10P60	3+	3+	1+
11	10P66	3+	2+	1+
12	10P71	2+	2+	2+
13	10P84	2+	1+	2+
14	10P87	2+	3+	2+
15	10P95	3+	3+	2+
16	10P99	2+	2+	2+
17	10P115	2+	3+	2+

Table 6: Summaries the bone markers results (osteopontin, BMP4, and RUNX-2) most of the antibodies were positive even in the normal tissue. This is because osteopontin, BMP4, and RVNX-2 are components of an elastic fibre; most of the breast cells will show the positivity result.

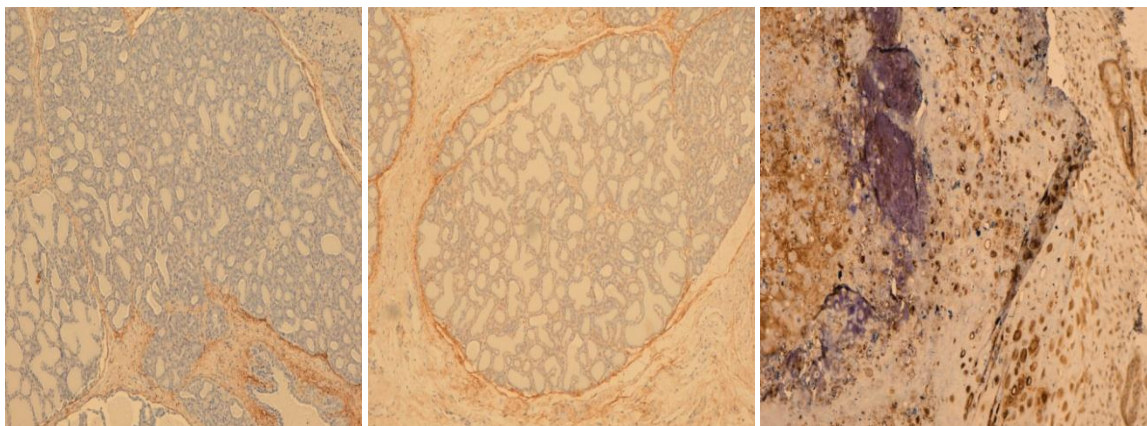


A. Negative control 20x.

B. Positive control 40x.

C. (case10P 84)10x.

Figure 11: Immunostaining with BMP4 antibody: A. Negative control 20x; B. Positive control 40x; C. (case10P 84)10x all cytoplasmic part stained and show positivity, an over expiration of BMP4 molecules in the tumor areas.

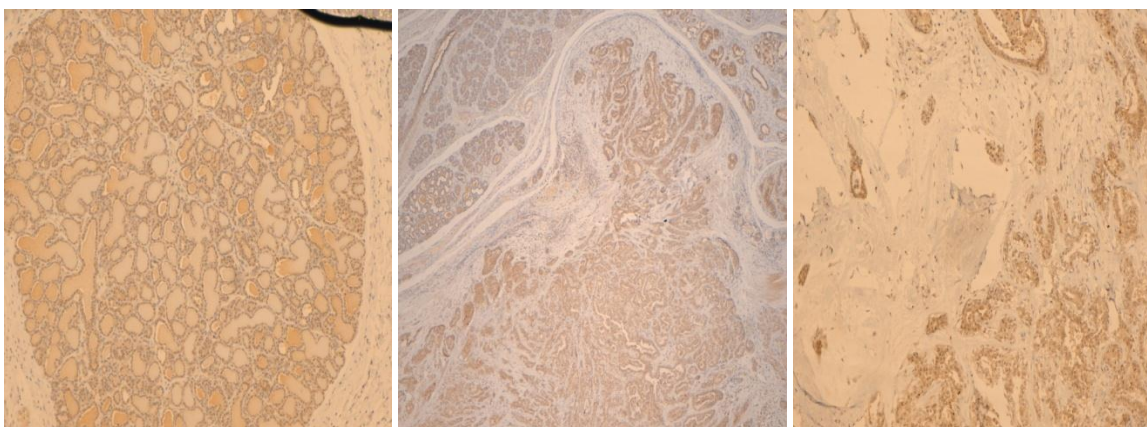


A. Negative control 10x.

B. Positive control 20x.

C. (case10P84) 10x.

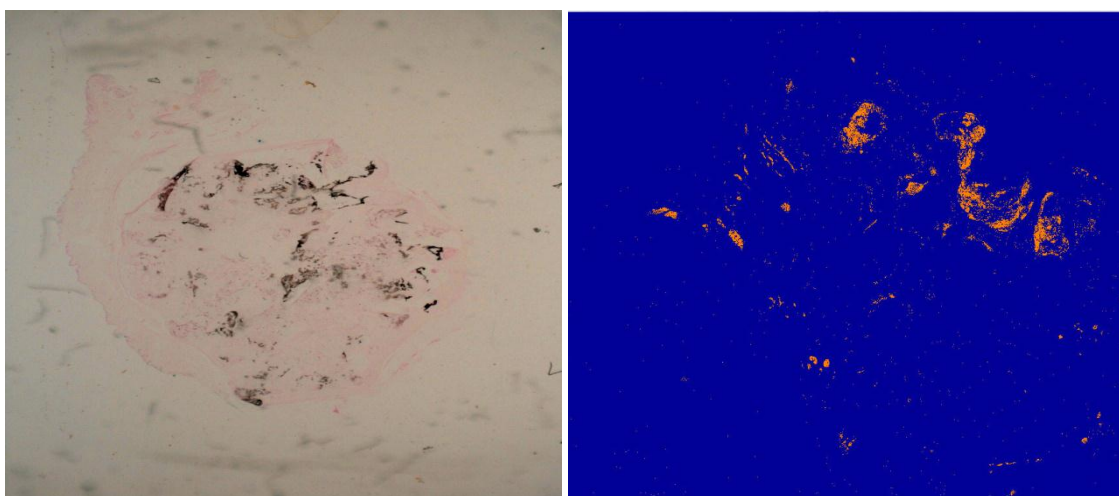
Figure 12: Immunostaining with osteopontin antibody: A. Negative control; B. Positive control ; C. (case10P84) the tumor it is show positivity and here the chondrocytes or chondroblast also stained osteopontin cytoplasmic the part that will be stain is the cytoplasm.



A. Positive control 20x.

B. (case10P84) 4x. C. (case10P84) 10x.

Figure 13: immunostaining with RUNX-2 antibody: A. Positive control 20x; B. (case10p84) 4x; C. (case10P84) 10x. The normal And Abnormal both are stained positively, RUNX-2(nuclear + cytoplasmic).



A. (case10P115) Vonkossa stain 4x.

B. (case10P115) Aperio image analysis.

Figure 14 in (A) show Vonkossa stain, it is well known that it is a stain used to demonstrate extracellular carcinoma calcification that gives black colour when it stain calcium which is form the bones. By using Aperio image analysis software in the PC computer, it will give masers to the surface area of the bone and it will give a picture like the one shown in (B). The result of Aperio image analysis software show that six cases containing bone or the high percentage of the calcium were found in those cases listed in table 7; whereas the rest of the causes were negative.

Table 7: Aperio image analysis software result.

No	Cases	Percentage of bone
1	10P10	0.03%
2	10P55	0.5%
3	10P60	1%
4	10P84	0.02%
5	10P87	2%
6	10P115	4%

DISCUSSION

Osseous metaplasia is an interesting type of tumour that contains a mixture of cells. It consists of carcinoma part which actually consists of an epithelial part and mesenchymal part. Besides, it contains bone or cartilage or mixture of them (see figure 4). In figure 4 it is one of the cases which are the tissue from dog breast that has been diagnosed with osseous metaplasia by histopathology. In table 7, six of the cases show a high percentage of calcium which is important part in bone formation, when Vonkossa stain is used. The Vonkossa stain is technique used to demonstrate deposits of calcium or calcium salts so that it is not specific for the calcium ion itself.^[22] It will show the concentration of bone formation present in the breast tissue (see figure 14). The aim tool is to characterize these tumours by doing the immunohistochemistry.

Previous findings from other studies

In previous findings from other studies, using human tissue showed that this tumour consists of epithelial and mesenchymal components. Also, there are epithelial mesenchymal transitions which take place in this type of tumour and the exact mechanism of this is not fully understood. This tumour characterize by ER is negative and the lack of HER2 over expression. For terms of proliferation, some studies show that there is high proliferation of this kind of tumour, while other studies show low rate proliferation of this tumour.

The project findings

In this project, canine breast tissue used as a model to characterize the tumour behaviour by immunohistochemistry test to stain this canine breast tissue and the following major findings was found:

Epithelial /mesenchymal markers

By using the CKAE1/ AE3 antibody which is the bone cytokeratin that stains different cytokeratin, this bone cytokeratin antibody is actually expressed by all epithelial cells in the tumour glands area,^[20] (see figure 5). While Vimentin antibody shows mesenchymal components of the tumour, its stained result can be seen in (figure 6). After viewing all the cases, it is noticed that in most of the causes, there were more Vimentin positivity compared to epithelial component positivity (mesenchymal). This may be explained as the process called epithelial mesenchymal transition. The identification of tumours as carcinomas or epithelial origin is possible through CKAE1/ AE3 antibody. In

addition, it also helps to identify the differentiated or undifferentiated carcinomas. The classification of the normal and neoplastic tissues as epithelial in origin is possible when a positive result is obtained. While the Vimentin is found in cells of the mesenchymal origin, it is an intermediate filament protein. A portion of the cytoskeleton of the vertebrate cells is formed by the Vimentin. The identification of cells of mesenchymal origin in the normal and the neoplastic tissues are aided by the antibody, which is important in the tumour diagnosis as this antibody labels the primary cells of mesenchymal origin in both normal and neoplastic tissues.^[20]

Hormone receptors(ER)

When estrogen receptor (ER) antibody was used to stain the estrogen in the cases, the results were negative in most of the cases for this antibody and this actually leads to two important conclusions being drawn. The first one is the hormonal cell actuary which indicate that tumours will not respond to hormonal treatment, and the other point is that this kind of tumour will be usually estrogen negative (see figures 7and 8) (tumours are classified to have poor prognosis which indicate other types of breast cancer). The characterization of the ER status in human breast has been aided by this useful tool. Cancers such as, breast, ovarian, and colon cancers were studied leading to an observation of decreased expression and loss of ER expression when compared with the expression in the corresponding normal tissues. The development of tumour was attributed to the alliteration in the ER ratio.^[23] But, how can we measure the positivity of the ER? Beer gland calculates the positive tumour cells which ER antibody stained, calculate all the positivity tumours cells agents all the number of the gland (see figure 8). And we calculate the percentage if it is less than 30% (which is the result of this project in most of the cases) it will considered as negative. However, if it is more than 30 %, it is considered as positive for ER. In table 4 above shows that all of our cases were negative for ER except two cases (10P60 and 10P115) were positive for estrogens receptor.

Her-2 over expression

For the HER-2 over expression, the result was that there is no over expiration in all the cases of HER-2 (see figure 10). Basically, this finding is consistent because it is the same finding that has been established by studying this tumour in human tissue. So, we might conclude that dog tissue can be used to study these kinds of tumours. The HER-2 protein is activated by the antibody, which is phosphorylated at tyrosine residue. It is in 10-40% of the primary invasive breast carcinomas that the over expression of HER-2 protein may be found.^[24] The detection of activated HER-2 protein may be useful in the characterization of breast carcinomas, as the level of HER-2 expression is not absolutely indicative of functional status. The immunochemistry has benefitted from this antibody.^[24]

Proliferation marker (Ki-67)

For proliferation rate, Ki-67 antibody was used which is an antibody that stains specific molecules expressed by the cells when they divide.^[25] It can give a clue on how many cells are active and undergoing proliferations. In these projects, it was found that the proliferation rate was low as it shown in (figure 9). This indicates that the cells are not much proliferated in these tumours. This can be explained from the perspective that the entire tumour that has been used is benign (non malignant). But the proliferation rate is still higher than the normal breast tissue. Valuable input has been provided by the usage of antibodies against the Ki-67 in the diagnostic histopathology and cell biology. It allows direct monitoring of the growth fraction of the normal and neoplastic cells. The demonstration of Ki-67 antigen in normal and neoplastic cells has benefitted from the use of this antibody in diagnosis. This is for instance in soft tissue sarcoma, prostatic adenocarcinoma, and breast carcinoma diagnosis.^[25]

Bone and cartilage markers

BMP4 antibody

For bone and cartilage markers; which are the main focus of this project, BMP4 antibody was used which is signalling molecules that participate in stimulation of bone formation.^[26] It also play a role in the regulation of cell proliferation in cells which is normally expressed in breast tissue by the epithelial cells. In many studies, it is shown an over expressed in 25% of breast cancer cases. It is an epithelial marker used in the human tissue which show an over expiration of these molecules. This also has the same result in this projects since that there is an over expression of this antibody marker in the tumour area of all cases (see figure 11). Anti-BMP4 antibody's main function is the induction of cartilage and bone formation. But it also participates in the induction of mesoderm, tooth development, limb formation and fracture repair.^[26]

Osteopontin antibody

The second molecule is osteopontin which is a cell adhesion molecule.^[27] It is mainly found in the bones and called osteopontin because it was the first time being discovered in the surface of the cytoplasm, but is actually present in other non-skeletal tissue and breast tissue is one of the companions of the extracellular matrix tissue (expressed in normal breast tissue). Again, studies have found that this molecule is up regulated in breast cancer and has been associated with poor prognosis in breast cancer (see figure 12). Osteopontin antibody forms a primary part of the mineralized matrix by binding to the hydroxyapatite. The production of interferon-gamma and interleukin-12 is increased when it acts as a cytokine. The production of interleukin-10 is reduced as a result.^[27] The pathway leading to type I immunity is dependent on it.

RUNX2 antibody

The third antibody that was used is the RUNX2 which is a transcription factor for osteoblast differentiation and with the perforation with the cartilage; this antibody was also expressed by the normal breast tissue.^[28] Therefore, the normal part of the tissue was stained but it was also expressed in the breast cancer area in the tissue (see figure 13). This shows that it is associated with unfavourable outcomes. It is significant in the maturation of osteoblasts and intramembranous and endochondral ossification. The osteoblastic differentiation and skeletal morphogenesis probably involves it as a transcription factor.^[28]

Study impact and Future studies

In this project, it spouses to use more than these antibodies. The BMP4, osteopontin, and RUNX2 were the first time that they were used in dog tissues (mixed canine mammary tumours). But this project need a lot of standardization, but it is luckily to get three of them working good and have accordingly achieved good results. Overall, in this study it can be say that a dog can be a good model for studying human tissue breast cancer and this is the first study being done using the canine mammary as model. That because of some similarity in results found between dogs and human breast cancer in terms of immunohistochemistry test result, this also can play potential role in development of tumours in humans.

Studying human tumours and these molecules might play a role in other types of breast cancers. Accordingly, in the future we might be appalled to get more information if we increase the sample number because we only used 17 cases in this study. Perhaps, we can also include more different breast cancer types to study the role of these molecules in the pathogenesis of this cancer. Other bone and cartilage markers like SOX9 and collagen X may be studied in the future with further investigations being done to actually ascertain accurate result,^[29,30] also further investigation test in breast cancer like PCR and cell culture.

CONCLUSION

In summary, all antibodies that were done were positive, except HER2 and ER which were negative, except of two cases of ER which were positive and accounted for about 11%. The BMP4, osteopontin, and RUNX2 antibodies could play a role in development of this kind of breast cancer. But all what have been done in this project achieved satisfied results in the characterization of these tumours behaviour.

In addition, we can say that canine mammary tissues provide a good model for studying breast cancer and to be as model for studying human tissue breast cancer. This is the first study to study these kinds of tumours in terms of immunohistochemistry test result. Studying human tumours and these molecules might play a crucial role in other types of breast cancer, which also can play a vital role in development of treatment.

REFERENCES

1. Vorobiof G HG, Freinkel W, et al: Primary osteosarcoma of the breast: a case report. *Breast J*, 2003; 9: 231-233.
2. Bahrami A RE, Ro J, et al: Primary osteosarcoma of the breast: report of 2 cases. *Arch Pathol Lab Med*, 2007; 131: 792-795.
3. Uner A OB, Benekli M, et al: Synchronize primary breast osteocarcinoma and contralateral benign cystosarcoma phylloides: radiologic and pathologic imaging. *Breast J*, 2008; 14: 109-110.
4. Balkwill F CK, Mantovani A: Smoldering and polarized inflammation in the initiation and promotion of malignant disease. *Cancer Cell*, 2005; 7: 211-217.
5. Goswami S SE, Wyckoff JB, Cammer M, Cox D, Pixley FJ, Stanley ER, Segall JE, Condeelis JS: Macrophages promote the invasion of breast carcinoma cells via a colony-stimulating factor-1/epidermal growth factor paracrine loop. *Cancer Res.*, 2005; 65: 5278-5283.
6. Schwertfeger KL RJ, Cohen DA: Mammary gland macrophages: pleiotropic functions in mammary development. *J Mammary Gland Biol Neoplasia*, 2006; 11: 229-238.
7. Yamaguchi T KO, Chattopadhyay N, Brown EM. Expression of extracellular calcium (Ca₂Co)-sensing receptor in the clonal osteoblast-like cell lines, UMR-106 and SAOS-2. *Biochem Biophys Res Commun*, 1998; 243(3): 753-7.
8. Rosen PP. Mammary carcinoma with osteoclast-like giant cells. In: Rosen PP, editor. *Rosen's breast pathology*. 2nd ed. Philadelphia7 Lippincott Williams & Wilkins, 2001.
9. Holland R, van Haelst UJ. Mammary carcinoma with osteoclast-like giant cells. Additional observations on six cases. *Cancer*, 1984; 53: 1963-73.
10. Mihai R, Farndon JR. Parathyroid disease and calcium metabolism. *Br J Anaesth*, 2000; 85(1): 29-43.
11. McNeil SE HS, Nipper V, Rodland KD. Functional calciumsensing receptors in rat fibroblasts are required for activation of SRC kinase and mitogen-activated protein kinase in response to extracellular calcium. *J Biol Chem*, 1998; 273(2): 1114-20.
12. Cheng I KM, Chattopadhyay N, Kifor O, Butters RR, Soybel DI, et al. Identification and localization of the extracellular calcium-sensing receptor in human breast. *J Clin Endocrinol Metab*, 1998; 83(2): 703-7.
13. Harris J LM, Morrow M, et al. *Diseases of the Breast*, 2nd ed. Philadelphia, PA: Lippincott Williams and Wilkins, 2000; 440-443.
14. Wada H ET, Tsujimoto M, et al. Carcinoma of the breast: molecular-biological study for analysis of histogenesis. *Hum Path*, 1998; 29: 1324-1328.
15. Yamaguchi T CN, Kifor O, Butters Jr RR, Sugimoto T, Brown EM. Mouse osteoblastic cell line (MC3T3-E1) expresses extracellular calcium (Ca₂Co)-sensing receptor and its agonists stimulate chemotaxis and proliferation of MC3T3-E1 cells. *J Bone Miner Res.*, 1998; 13: 1530-8.
16. McNeil L HS, Nipper V, Rodland KD. Functional calciumsensing receptor expression in ovarian surface epithelial cells. *Am J Obstet Gynecol*, 1998;178(2): 305-13.
17. McNeil SE, Hobson SA, Nipper V, Rodland KD. Functional calciumsensing receptors in rat fibroblasts are required for activation of SRC kinase and mitogen-activated protein kinase in response to extracellular calcium. *J Biol Chem*, 1998; 273(2): 1114-20.
18. Rosen PP. Mammary carcinoma with osteoclast-like giant cells. In: Rosen PP, editor. *Rosen's breast pathology*. 2nd ed. Philadelphia7 Lippincott Williams & Wilkins, 2001.
19. Tavassoli FD, P. *Pathology and Genetics of Tumors of the Breast and Female Genital Organs*. Lyon: IARC Press, 2003.
20. Wang S SM, Frenkel E, Hynan L, Gokaslan ST, Ashfaq R. Laboratory assessment of the status of Her-2/neu protein and oncogene in breast cancer specimens: comparison of immunohistochemistry assay with fluorescence in situ hybridisation assays. *Journal of Clinical Pathology*. 2000 May 1, 2000; 53(5): 374-81.
21. *Histopathology 2 Laboratory Manual MEDS1129/2113* Doh, The University of RMIT, page 65, year, 2012.
22. Sheehan D HB, *Theory and Practice of Histotechnology*, 2nd Ed, 1980, pp 226-227, Battelle Press, Ohil. von Kossa Staining Protocol for Calcium. [updated 8/10/2012]; Available from: http://www.ihcworld.com/_protocols/special_stains/von_kossa.htm.
23. Dako aatc. Monoclonal Mouse Anti-Human Estrogen Receptor β 1. 2012 [updated Copyright 2010 Dako]; Available from: http://www.dako.com/au/ar38/p234883/prod_products.htm.
24. Dako aatc. Monoclonal Mouse Anti-Human HER2-pY 1248, Phosphorylation Site Specific Clone PN2A. 2012 [updated Copyright 2010 Dako]; Available from: http://www.dako.com/au/ar38/p224272/prod_products.htm.
25. Dako aatc. Monoclonal Mouse Anti-Human Ki-67 Antigen, Clone MIB-1. 2012 [updated Copyright 2010 Dako]; Available from: http://www.dako.com/au/ar38/p104960/prod_products.htm.
26. Abcam. Anti-BMP4 antibody. 2012 [updated 2012 Abcam plc]; Available from: <http://www.abcam.com/BMP4-antibody-ab39973.html>.
27. Abcam. Anti-Osteopontin antibody. 2012 [updated 2012 Abcam plc]; Available from: <http://www.abcam.com/Osteopontin-antibody-ab8448.html>.
28. Abcam. Anti-RUNX2 antibody. 2012 [updated 2012 Abcam plc]; Available from: <http://www.abcam.com/RUNX2-antibody-ab23981.html>.

29. Abcam. Anti-SOX9 antibody. 2012 [updated 2012 Abcam plc]; Available from: <http://www.abcam.com/SOX9-antibody-ab26414.html>.
30. Dako aatc. Monoclonal Mouse Anti-Human Collagen IV Clone CIV 22. 2012 [updated Copyright 2010 Dako]; Available from: http://www.dako.com/au/ar38/p103510/prod_products.htm.