wjpmr, 2021,7(2), 61-63

SJIF Impact Factor: 5.922

WORLD JOURNAL OF PHARMACEUTICAL AND MEDICAL RESEARCH

www.wjpmr.com

Case Report

Issn 2455-3301

WJPMR

INGUINOSCROTAL VERRUCOUS CARCINOMA ABOUT ONE CASE

Dohoué Patricia Eliane Agbanglanon*, Salma El Baz, Siham JABA, Gaël Kietga, Wilfried Mossé, Davy N'chiépo, Ibtissam Lahdiri, Hanan KACEMI, Tayeb KEBDANI, Sanaa ELMAJJAOUI, Noureddine Benjaafar

Department of Radiotherapy Oncology, National Institute of Oncology, Mohamed V University, Rabat, Morocco.

***Corresponding Author: Dohoué Patricia Eliane Agbanglanon**
Department of Radiotherapy Oncology, National Institute of Oncology, Mohamed V University, Rabat, Morocco.
DOI: https://doi.org/10.17605/OSF.IO/Q9E4B

Article Received on 13/12/2020 **Article Revised on 03/01/2021** **Article Accepted on 24/01/2021**

ABSTRACT

Verrucous carcinoma is a rare form of well differentiated squamous cell carcinoma. Generally, they are characterized by exophytic and endophytic growths destroying the underlying dermal and other surrounding structures. Grossly, the tumor appears as a large fungating, erythematous, cauliflower-like mass. Radical surgical excision of the tumor is the treatment of choice. The use of chemotherapy and radiotherapy in the management of squamous cell carcinoma is documented in the literature. We report a case of human papillomavirus-negative local wart cell carcinoma in the inguinoscrotal region of a healthy 56-year-old male recused of the surgery treated with concurrent chemoradiotherapy. In the early evaluation after completion of treatment a small ulcer was visible in the region of the previously fungating left inguinal node mass but there was no evidence of residual tumor.

KEYWORDS: Verrucous carcinoma; squamous cell carcinoma; radiation therapy.

INTRODUCTION

Verrucous carcinoma is a rare form of well differentiated squamous cell carcinoma. The tumors have a distinctive cauliflower-like appearance. Cutaneous squamous cell carcinoma presents with a wide variety of clinical manifestations including papules, plagues, nodules, hyperkeratotic, ulcerative, or smooth lesions. These tumors are often localized in the penis and very rarely in the inguinal region.[1] These are low-grade, well-differentiated, broad-based tumors that extend to the underlying stroma. Regional lymph node involvement is rare and few distant metastases have been reported.[1,2] We report a case of a human papilloma virus negative local verrucous carcinoma in the inguino-scrotal area of a 56-year-old healthy man.

CASE REVIEW

A 56 years old, policeman, married with 5 children, sexually active, denied erectile dysfunction, and had never smoked, carrier of viral hepatitis C with no history of human papillomavirus (HPV) infection, syphilitic and human immunodeficiency virus (HIV) serologies were negative. He presented multiple warts bilateral in groin for 37 years, which progressively increased in size. The lesion was not bothersome, and thus, he never sought medical attention. Lesions were not associated with pain and there was no associated itching. The lesion started increasing in size about 1 year ago extending into the bilateral inguinoscrotal area after micro-traumas with appearance of inguinal lymphadenopathy. It became painful and was associated to a burning sensation. He admitted to the hospital in front of the worsening of the clinical symptoms. He reported no fever, weight loss, chills, urinary discomfort and any other skin lesions elsewhere. Local examination showed a large vegetative growth in the bilateral inguinal areas and scrotum base with satellite bilateral inguinal lymphadenopathy. Full screening for sexually transmitted diseases was negative. Examination to exclude involvement of anal canal and rectum was done. A biopsy had objectified a verrucous carcinoma with no infiltration of the dermis. A pelvic MRI scan has found a predominantly bilateral inguino-scrotal lesion process on the left of 55 x 20 x 50 mm and 30 x 20 x 30 mm on the right with infiltration of the epididymis head bilaterally and of the spermatic cord over its entire length and bilateral inguinal lymphadenopathy. The file then has been presented at a multidisciplinary surgical consultation meeting where a decision on surgical resection has been made. The patient has been examined by the surgeons, who determined that the tumor was not resectable, and radiotherapy plus concurrent chemotherapy was decided. The treatment plan was performed with intensity modulated radiotherapy (IMRT). Patient was simulated in the supine position, arms above chest and "frog-leg" with immobilization devices. He was simulated with an empty rectum after bowel preparation and full bladder to minimize small bowel toxicity.

We performed a contrast-enhanced CT-scan from superior field border is placed at the L4-L5 interspace at

the bottom of the obturator foramen with 5 mm slights thickness.

The Gross Tumor Volume (GTV) included the gross tumor based on CT and MRI imaging. The Clinical Target Volume (CTV) was defined as GTV plus a margin of 1 cm, depending on the location and anatomy. The CTV margins were smaller if the GTV was adjacent to the organ at risk. A 1 cm margin in all directions was added to the CTV to obtain the planning target volume (PTV).

Nodal CTV was start from 7 mm below the L4-L5 to the level of the superior aspect of the femoral heads for external iliac and at the level of S3 for the pre-sacral lymph nodes. He was defined as the iliac vessels plus an additional circumferential margin of 7 mm. An additional margin of 7 mm was added in all directions to create nodal PTV.

He received Radiotherapy concurrent with weekly cisplatin-based chemotherapy 40 mg/m^2. The total dose of radiotherapy was 66 Gy (46 Gy, 2 Gy/fr, 5 sessions/week on the pelvis followed by to boost of 20 Gy on the tumor GTV). The total treatment time was 39 days.

Organs at risk (OAR) include bowel, bladder, rectum, and bilateral femoral heads. Dose constraints to OAR were set according to the RECORAD.

The early after completion of treatment a small ulcer was visible in the region of the previously fun gating left inguinal node mass but there was no evidence of residual tumor. The patient had normal urinary, and he returned to normal physical activity.

Picture 1 : inguinoscrotal tumor before radiotherapy treatment

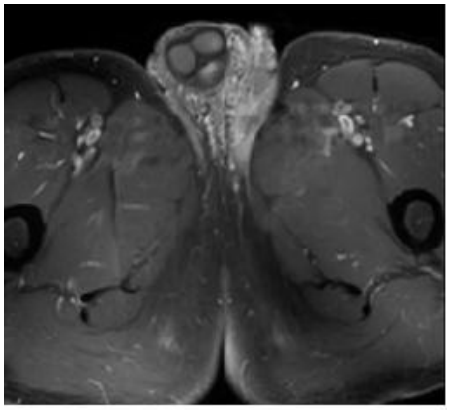

Picture 2 : Coronal T1-weighted MRI of a verrucous carcinoma of the bilateral inguino-scrotal region

Picture 3 and 4 : Inguinoscrotal tumor shortly after completion of radiation treatment

DISCUSSION

Verrucous carcinoma (VC) is a low grade, locally aggressive variant of squamous cell carcinoma.[3] The majority of the literature on managing VC concerns the head and neck region. In the anogenital region, the tumor may be present as condyloma accumi-natum, common genital warts. VC of the scrotum is a less frequent variant of squamous cell carcinoma.[4] These tumors are commonly located on the penis, and very rarely in the inguinal region or fold.[5] Traditional dogma has been that it is a radioresistant tumor with a propensity to anaplastic transformation when irradiated.[3] Generally, they are characterized by exophytic and endophytic growths destroying the underlying dermal and other surrounding structures.[5] Risk factors for VC are low socioeconomic status, drug abuse, sexually transmitted

diseases, diabetes, and smoking.[6] The lesion grows slowly and rarely metastasized to lymph node, but might be locally destructive.[2,7] In our case, the VC was in the inguinoscrotal fold with bilateral inguinal lymph nodes metastasis.

The exact etiology of VC is yet to be clarifed. Human Papilloma Virus types 6 and 11 have been linked with the pathogenesis of this tumor, but other studies have shown that HPV infection is not a universal finding in VC.[8] In our case, the HPV serology was negative. In a study by Del Pino et al.[9] the prevalence of HPV in VC was only 18.5%. The role of repetitive strain injuries as in the case of this patient has been reported in the literature.[10]

The use of CT scan and MRI studies is to evaluate distant metastasis and other primary sources of the cancer. The patient's immunological status should be checked during the initial diagnosis.[11]

Skin or lesion biopsies are required to confirm the diagnosis as in the case of this patient. Histologically, the tumors are low-grade well-differentiated benign tumors whose degeneration can lead to a deadly local evolution because of difficulty and late diagnosis.[12] If left untreated, certain VC evolve to giant masses which may be foul-smelling, painful, and ulcerated. Inguinal lymph nodes metastasis is the single most important adverse prognosis.[13] Unfortunately, most of these tumors are diagnosed at an advanced stage. The reasons that most patients delay seeking medical treatment are due to psychological factors such as guilt, low self-esteem, fear of loss of fertility, and carcinophobia.[12] Testing for sexually transmitted infections such as HIV and syphilis is essential during the initial diagnosis. Prevention of HPV through vaccination, use of condoms, and limiting the number of sexual partners is essential in reducing the incidence and prevalence of VC.[5]

Radical surgical excision of the tumor is the treatment of choice for VC.[14] Recurrence is common, especially for tumors that have not been adequately excised. Skins defects resulting from radical excision of these tumors can be corrected using surgical reconstructions. For our case, the patient was recused from surgery and it was decided to have radiation therapy in conjunction with chemotherapy. The use of radiation therapy is controversial because of the risk of anaplastic transformation, extensive appearance of new condylomas, and lack of long-term positive results.[15] It seems yet it has been possible to treat, successfully and without recurrence at one year, by exclusive radiotherapy a patient with VC.[3] Furthermore, the use of systemic chemotherapy is not well defined in the literature for VC.[7] Local control of invasive forms of squamous cell carcinoma was achieved by chemotherapy, alone or combined with irradiation, by the association of different drugs (5 FU, mitomycin C, bleomycin, cis-platinum, methotrexate).[16] For our case, the patient has received cis-platinum chemotherapy concomitantly with radiotherapy.

The use of chemotherapy and radiotherapy in the management of squamous cell carcinoma is documented in the literature.[17] VC was radioresponsive in our case.

CONCLUSION

Radical excision with regular follow-up is essential in the management VC. In the case of an inoperable tumor, radiotherapy in concomitance with chemotherapy gives very good results, as in the case of the patient in our clinical case. For patient with tumor metastases, chemotherapy is the treatment of choice.

REFERENCES

1. Nomikos M, Barmpoutis P, Papakonstantinou E, Chousianitis Z, Ouzounoglou P, Efstathiadou P, et al. A Giant Verrucous Carcinoma of the Penis Presenting with Urinary Sepsis and Angina. Case Rep Med, 2014; 2014: 1‑3.
2. Handisurya A, Rieger A, Bago-Horvath Z, Schellenbacher C, Bankier A, Salat A, et al. Rapid progression of an anal Buschke-Lowenstein tumour into a metastasising squamous cell carcinoma in an HIV-infected patient. Sex Transm Infect. 1 août, 2009; 85(4): 261‑3.
3. Foroudi F, Turner S. VERRUCOUS SCROTAL CARCINOMA: A RADIORESPONSIVE TUMOR. J Urol, nov 1999; 162(5): 1694‑5.
4. Pomara G, Pomara S, Travaglini F, Maras L, Selli C. Verrucous scrotal carcinoma in a patient with hypospadias: is there a possible association? Urology. janv, 2003; 61(1): 224.
5. Fai EK, Bhutta HA, Ali K. A Case Report of Progression of a Buschke-Lowenstein Tumor of the Right Inguinal Region into Invasive Squamous Cell Carcinoma, 1(1): 3.
6. Philippou P, Kitsios C, Miliatou M, Poullou C, Konstantinou P. Organ-Sparing Surgery for a Giant Verrucous Carcinoma of the Penile Shaft: A Case Report and Review of the Literature. Case Rep Urol. 24 févr, 2019; 2019: 1‑4.
7. Gole G, Shekhar T, Gole S, Prabhala S. Successful treatment of buschke-löwenstein tumour by surgical excision alone. J Cutan Aesthetic Surg, 2010; 3(3): 174.
8. N. Fujimoto, G. Nakanishi, H. Ushida et al. "Penile verrucous carcinoma arising in HPV-negative condylomatous papules," European Journal of Dermatology, 2011; 21(3): 436–438.
9. Del Pino M, Bleeker MC, Quint WG, Snijders PJ, Meijer CJ, Steenbergen, RD. Comprehensive analysis of human papillomavirus prevalence and the potential role of low-risk types in verrucous carcinoma. Modern Pathology, 2012; 25: 1354-63.
10. Martin F, Dalac S, Lambert D. Carcinome verruqueux. Aspects nosologiques à propos de 4 cas. Ann Dermatol Venereol, 1995; 122: 399-403.

11. Correia E, Santos A. Buschke-Löwenstein Tumour: Successful Treatment with Minimally Invasive Techniques. Case Reports in Dermatological Medicine, 2015; Article ID 651703.
12. Lu S, Bodemer W, Ostwald C, Barten M, Zimmermann R, Seipp C,, et al. Anal Verrucous Carcinoma and Penile Condylomata acuminata. Dermatology, 2000; 200: 320-323.
13. Bezerra SM, Chaux A, Ball MW, Faraj SF, Munari E, Gonzalez-Roibon, N, et al. Human papillomavirus infection and immunohistochemical p16INK4aexpression as predictors of outcome in penile squamous cell carcinomas. Human Pathology, 2015; 46: 532-40.
14. Gholam P, Enk A, Hartschuh W. Successful Surgical Management of Giant Condyloma Acuminatum (Buschke-Löwenstein Tumor) in the Genitoanal Region: A Case Report and Evaluation of Current Therapies. Dermatology, 2008; 218: 56-9.
15. Sobrado CW, Mester M, Nadalin W, Nahas SC, Bocchini SF, Habr-Gama, A. Radiation-induced total regression of a highly recurrent giant perianal condyloma: report of case. Dis Colon Rectum, 2000; 43: 257-60.
16. Schon MP, Heisterkamp T, Ahrens C, Megahed M, Ruzicka, T. Presternal verrucous carcinoma. Hautarzt, 2000; 51: 766-9.
17. Mitra A, Agarwal P, Singh R, Verma S, Srivastava V, Chugh A, et al. Squamous cell carcinoma of the scrotum - still an occupational hazard. Indian Journal of Occupational and Environmental Medicine, 2014; 18: 150-2.