

**DISTAL END LEFT ANTERIOR DESCENDING CORONARY ARTERY DILATATION:  
CASE REPORT**A. Bakkali MD, PhD<sup>1,2</sup>, H. Bouhdadi MD<sup>2\*</sup> and M. Laaroussi MD<sup>2</sup><sup>1</sup>Faculty of Medicine and Pharmacy, Ibn Zohr University; Agadir, Morocco.<sup>2</sup>Cardiovascular Surgery Department, Avicenna University Hospital; Rabat, Morocco.**\*Corresponding Author: H. Bouhdadi MD**

Cardiovascular Surgery Department, Avicenna University Hospital; Rabat, Morocco.

Article Received on 05/10/2020

Article Revised on 25/10/2020

Article Accepted on 15/11/2020

**INTRODUCTION**

Coronary artery anomalies include anomalies of origin, termination, structure, or course. Coronary artery fistulas result from abnormalities of termination.

Coronary artery fistulas are defined as sizeable connection between a coronary artery and cardiac chamber (coronary-cameral fistula) or any part of systemic or pulmonary vasculature having bypassed the myocardial capillary bed.<sup>[1]</sup>

Coronary artery aneurysm is a rare clinical entity with an estimate incidence of 0.3–5% among patients who undergo coronary angiography.<sup>[2]</sup>

It is usually presented with myocardial ischemia due to rupture or distal embolization.<sup>[3]</sup>

Despite the low prevalence in the overall population, congenital coronary artery anomalies are frequently found as the cause of sudden death in the young, particularly in the athletic field.<sup>[4]</sup>

These anomalies are observed both in paediatric and adult patients.

**CASE REPORT**

A 21 year-old women with no significant past medical history, presented with dyspnea and recurrent bronchitis, an atrial septal defect was diagnosed and she was transferred to our department for surgery.

Physical examination revealed a regular pulse of 80 beats/min, blood pressure of 120/60 mmHg, heart sounds examination revealed a IV<sup>th</sup> degree pansystolic murmur at the left border of the sternum.

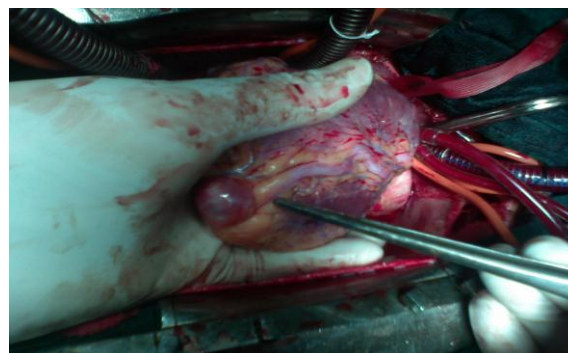
The EKG recorded sinus rhythm with hypertrophy of the right atrial and the right ventricle with right axis deviation. The chest x-ray showed right atrial and right ventricular dilatation and increased pulmonary vascular markings.

Transthoracic echocardiography revealed a large ostium secundum atrial septal defect of 3 cm with left to right shunt. It also revealed a dilated right atrium and a dilated right ventricle with moderate pulmonary hypertension (mean pulmonary artery pressure was 50mmHg) and moderate tricuspid regurgitation.

The patient underwent surgical closure of atrial septal defect with autologous pericardial patch under cardiopulmonary bypass.

During the operation we discovered a dilated distal end of the left descending artery. (Figure 1) Since the coronary dilatation was distal and the patient had no specific symptom of coronary disease, we decided to perform, first, a coronary angiography to better assess the cause of the dilatation and the detailed anatomy of the fistula.

The postoperative period was uneventful. The patient refused to undergo a cardiac catheterization. She were discharged home in good clinical condition and regularly followed up.



**Figure 1: Peroperative picture showing an incidental finding of a dilatation of the distal end of the left anterior descending artery.**

## DISCUSSION

Coronary cameral fistulas are usually a congenital communication between coronary artery and cardiac chamber and are most commonly seen with right coronary artery (approximately 55%), but it can be seen with left or both coronary arteries.<sup>[5]</sup>

In unselected patients undergoing diagnostic coronary catheterization, they are incidentally detected in approximately 0.1% cases.

The reported prevalence of aneurysmal coronary artery disease varies widely from 0.2 to 10%, with male predominance and a predilection for the right coronary artery. Atherosclerosis is the commonest cause of aneurysmal coronary artery disease in adults, while Kawasaki disease is the commonest cause in children and adolescents. Most patients are asymptomatic, but when symptoms do exist, they are usually related to myocardial ischemia.<sup>[6]</sup>

Thus, cardiac catheterization remains the modality of choice for defining the pattern of structure and flow.

## CONCLUSION

In some cases, the surgeon have to face some peroperative incidental findings, and may not have all the resources to make the good decision, this case highlights the importance of the hybrid operating rooms.

The surgeon of the future may well be a hybrid physician, maybe the merging of a surgical interventionist and an interventional surgeon.

## REFERENCES

1. D. Sagar, A. Hernandez, and T. Heimowitz, "Coronary artery-left ventricle fistula: a case report of a rare connection error!," *Cureus*, 2015; 7(4): e266.
2. Lima B, Varma SK, Lowe JE. Nonsurgical management of left main coronary artery aneurysms: report of 2 cases and review of the literature. *Tex Heart Inst J*, 2006; 33: 376–9.
3. Paz Soldan-Patino CP, Rojas-Velasco G, Arias-Mendoza MA, Enriquez-Gomez E, Meave-Gonzalez A, Alvarez-Sangabriel A et al. . Left main coronary aneurysm and antiphospholipid syndrome: survival at 12 years. A case report and literature review. *Arch Cardiol Mex*, 2012; 82: 120–4.
4. Corrado D, Basso C, Schiavon M, Thiene G, Screening for hypertrophic cardiomyopathy in young athletes, *N. Engl. J. Med.*, 1998; 339: 364–369.
5. Padfield GJ. A case of coronary cameral fistula. *Eur J Echocardiogr*, 2009; 10: 718–20.
6. GMohamed S. ElGuindy and Ahmed M. ElGuindy. Aneurysmal coronary artery disease: An overview. *Glob Cardiol Sci Pract*, 2017 Oct 31; 2017(3): e201726.