

CLINICAL SINGLE CASE STUDY OF VENOUS ULCER MANAGEMENT BY LEECH THERAPY***¹Dr. Anjali Meena, ²Dr. Vishnu Dutt Sharma M. S. Ph.D. (Ayu.) and ³Dr. Pankaj potalia**^{1,2}M.S. Scholar, Department of Shalya Ttanra, Dr. Sarvepalli Radhakrishnan Rajasthana Ayurveda University, Jodhpur.³Assistant Prof., Department of Shalya Tanra, Dr. Sarvepalli Radhakrishnan Rajasthana Ayurveda University Jodhpur.***Corresponding Author: Dr. Anjali Meena**

M.S. Scholar, Department of Shalya Ttanra, Dr. Sarvepalli Radhakrishnan Rajasthana Ayurveda University, Jodhpur.

Article Received on 26/08/2020

Article Revised on 16/09/2020

Article Accepted on 06/10/2020

ABSTRACT

A wound on the leg or ankle caused by abnormal or damaged veins .A venous ulcer is a sore on your leg that very slow to heal, because of weak blood circulation in the limb. venous ulcer develop mostly along the medial distal leg ,and painful with negative hypertension may be gravitation which is due to hydrostatic pressure by weight of blood column from the right atrium which is maximum at foot and ankle dynamic which is due to muscular contraction across the incompeletent perforator with a high pressure up to 200mm Hg.Venous ulcer commonly develop is around and above the medial malleoli because of presence of large number of perforators in ayurveda compare siragat vat janya vran, suhruta has treat jaloka one of most effective method of bloodletting useful even in infected and chronic non healing ulcer and some orally medicine.

KEYWORD: Leech therapy venous ulcer, jaloka, siragat vaat vrana.**INTRODUCTION**

1. About venous ulcer:-It is the complication of varicose vein or deep vein thrombosis. Varicose vein or DVT which are recanalised eventually causes chronic venous hypertension around ankle hemosiderin deposition in subcutaneous plan from lysed RBC then eczema –dermatitis –lipodermatosclerosis-anoxia-ulceration.

The pathogenesis starts with persistently increase intravenous pressure which damage the venous wall and result in stretching loss of elasticity confirmation of diagnosis is done by duplex Doppler ultrasound scanning of lower limb venous system.

1. About leech therapy

Leech reference of indication therapy in wound in Sushruta Chikitsa shtan chap. 12 and 16

Leech release the many protein and peptides that thin blood and prevent clotting and improve circulation and prevent tissue death.

Leech have have property anti-inflammatory anesthetic and antibiotic properties in leech saliva reduce pain and tenderness at the site of the affected joint.

Leech secrete more than 20 identified bioactive substance such as antihistamin ,eglns, hirudin, bdellins.

The technique is cheap effective easy to apply and it modes of action have been elucidated for certain disease.

Aim and objective

The evaluated and clinical efficacy of leech therapy in the patient with venous ulcer.

Single Case study

Name –Fatima

Age- 40

Gender –female

Religion –Muslim

Occupation-house wife

Diet - non veg.

Registration-47097

Date of admission- 13-11-2018

Type of study- observation single case study without control group

Chief complain:-

Pain and redness in left lower limb.

Swelling and discoloration and serous discharge from 3 month

Brief history

Patient has been suffering from above symptom since 3 year she took treatment for allopathy hospital some time relief but after some time pain and swelling lower limb complain patient .then patient come to DSRRAU Karwad she complain pain and serous discharge and discoloration lower left leg ;patient past history did not

any disease diabetes , hypertension and other no history of previous surgery in past.

General examination

Hb -11%

Blood sugar-95.74 mg %

ESR-24

CT- 4 min 17 sec

BT-2 min 3sec

HIV-negative

HBsAG - negative

Coagulation profile-normal

X-ray left leg –normal arterial & venous colour Doppler

–multiple incompetent perforators seen in the lower limb competent SF &FP valves

Local examination

Site of ulcer - Lateral aspect of left lower limb

Size of ulcer - 3-2-0.5

Discharge - mild discharge

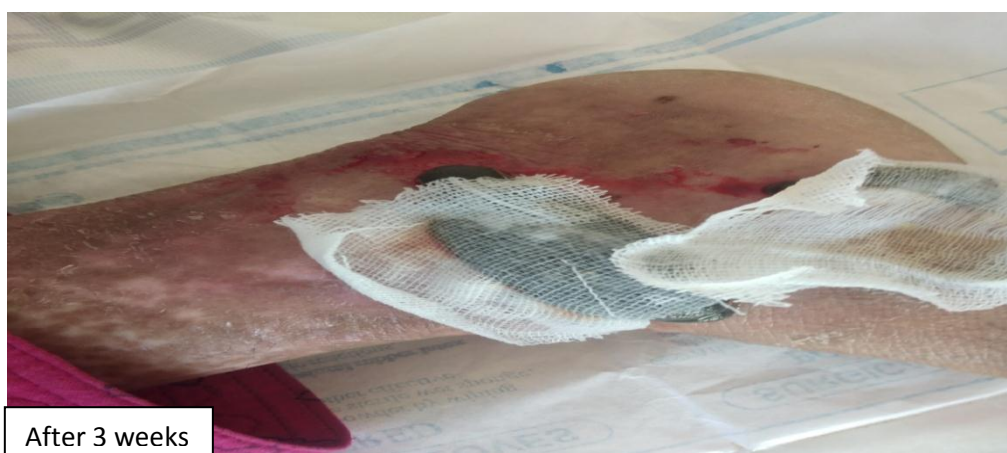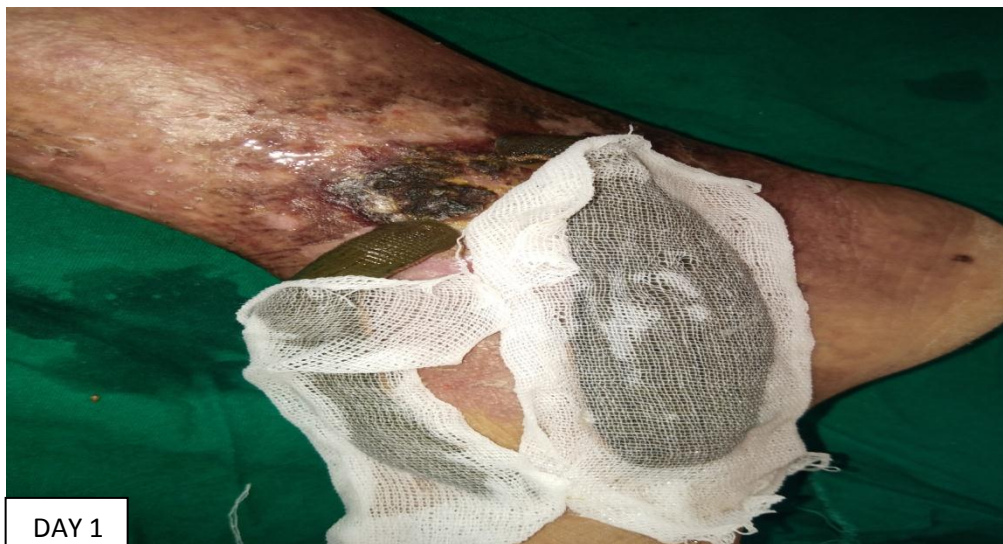
Smell - foul smell

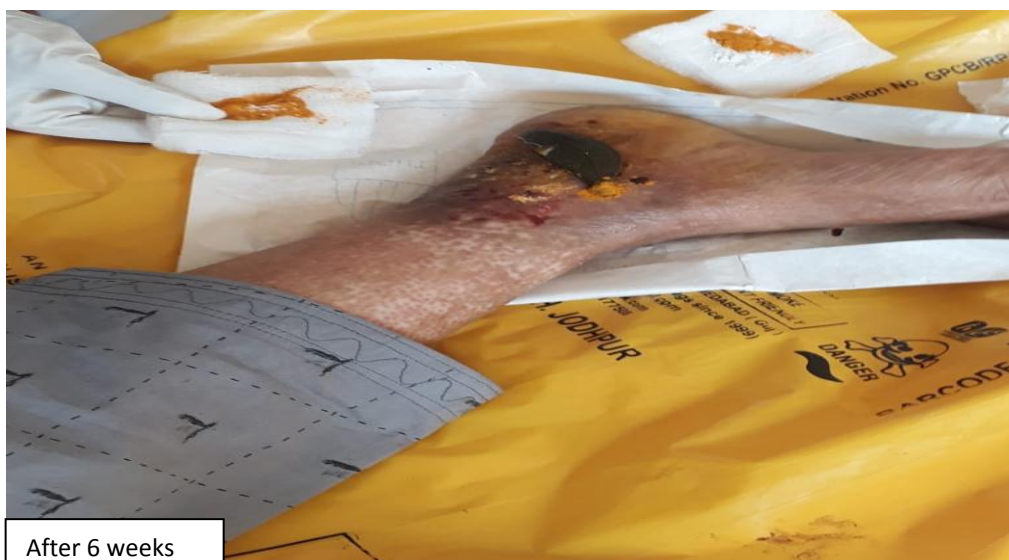Consent form:-

Treatment

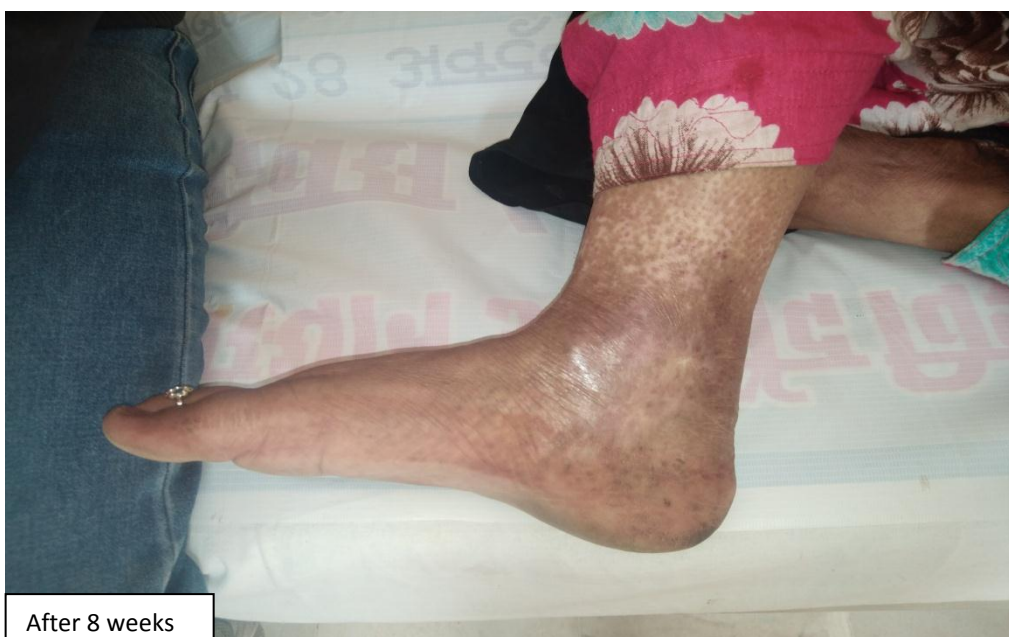After assessment wound was washed with normal water and there after 3 leech were applied all around lesion after 20 min blood suck and leech left the site and haridra dressing with guage piece. dressing was change two time clean *Triphla kwath* and leech therapy repeated 8 sitting.and some take medicine orally. Total duration 2 month and during the treatment assessment was done on day.

Observation:- Parameters of observations included Ankle flare, Peripheral hyperpigmentation, Size of ulcer, granulation tissues and relief in pain. Patient was observed on above parameters on every week for five weeks.





After 6 weeks



After 8 weeks

Parameters	1 st week	3 nd week	5 rd week	6 th week	8 th week
Ankle flare	Base line 100%	50%	25%	0%	0%
Peripheral Hyper pigmentation	Base line 100%	75%	25%	25%	50%
Size of Ulcer (cm)	Base line 100%	50%	50%	25%	0%
Pain	Base line 25%	75%	25%	25%	0%

With leech therapy and some medicine orally the wound completely healed with 2 month.

Probable mechanism of action of leech therapy

Leech application has peripheral vasodilator effect due to presence of vasodilator constituent in the saliva which improves blood circulation and anti-inflammatory and relief of pain and correct ischemia around the wound thus promote wound healing.

Triphala kwath vran shodan and anti-oxidant, anti-bacterial effect.

Orally medication

Shudha gandhak:- 250 mg

Rasmanikay:-125mg

Prvalpisti:- 250mg

Giloy stav:-250mg

All contents mix and twice a day

Acc. to ayurveda all medicine anti-inflammatory, anti-biotic and purifies blood and remove toxin.

CONCLUSION

With leech therapy the venous ulcer completely healed with 2 month on basis of this case study we can roughly conclude that ayurveda can give hope in treatment of venous ulcer and no complication like sever bleeding and wound infection. leech therapy prove to be effective time saving and acceptable.

Source of support: Nil.

Conflict of interest: None Declared.

REFERENCE

1. Medical Leech Therapy, Author: Andreas Mechallsen, Manfred Roth, Gustav Dobos. Publication Thieme, New York, USA, 2007; 11-12: 132-138.
2. Weinfeld AB et al, Clinical & Scientific consideration in Leech Therapy for the management of acute venous congestion, "An update Review. Ann Plastic Surgery, 2000; 45: 207-221.
3. Dr Anantram Sharma, "Shushru Vimarshini" commentary on Shushrut Samhitha, Chikitsa Stan – Chapter 4(Vat Vyadi Chikitsa – Shlok 07), Volume 2, published by Chaukhambha Surbharthi Prakashan, 2009; 205.
4. Illustrated Sushrut Samhita, Translated by K. R. Srikant Murthy, Second edition, 2004; 1.
5. Margolis DJ, Bilker W, Santanna J, Baumgarten M. Venous leg ulcer: incidence and prevalence in the elderly. J Am Acad Dermatol, 2002 Mar; 46: 381-386.
6. 3. Das S. Concise Textbook of Surgery, 8th ed. Kolkata: S Das Publication, 2014.