

MANAGEMENT OF FISTULA IN ANO (BHAGANDARA) THROUGH THE KSHARA
SUTRADr. Rajendra Kumar Dixit^{*1}, Dr. Shruti Dixit² and Dr. Rishi mishra³¹Assistant Professor at Rajeev Ghandhi Ayurved College Bhopal.²Assistant Professor at Rani Dullaiya Smt. Ayurved P.G. College Bhopal.³Associate Professor at Rajeev Ghandhi Ayurved College Bhopal.***Corresponding Author: Dr. Rajendra Kumar Dixit**

Assistant Professor at Rajeev Ghandhi Ayurved College Bhopal.

Article Received on 20/08/2020

Article Revised on 10/09/2020

Article Accepted on 30/09/2020

DEFINITION

The fistula is a tortuous track lined by unhealthy granulation tissue and fibrous and has one end communicating with the perianal skin and the other end with the rectum.

KEYWORDS: Fistula, Kshara, Kshara Sutra.

Etiology of fistula

1. **Non specific:** caused by - cryptoglandular infection and previous anorectal abscess, Constipation.
2. **Specific:** by different diseases.

Tuberculosis, Crohn's, Ulcerative colitis, Fissure, Carcinoma, Leukemia, etc

Signs and Symptoms

Anal fistulae can present with different symptoms:

- **Discharge:** Soiling of Undergarments with Perianal Discharge which can be either bloody or purulent.
- **Pain:** Pain is maximum when the tract is filled with discharge and minimum when it ruptures. It is usually constant, throbbing and worse when sitting down.
- **Swelling:** There is a typical history that the swelling intermittently ruptures and swells again.
- Bleeding
- Fever
- Diarrhoea
- Skin irritation around the anus including swelling, redness and tenderness
- External Opening

Mechanism of fistula formation 4 stages

- A. Stage of infection
 - B. Stage of burrowing
 - C. Stage of abscess formation
 - D. Stage of secondary opening
- A. Stage of infection

- Infection of the anal crypts which become to be distended and form primary opening.
- Later on crypts become edematous and the infection spreads.

- B. Stage of burrowing**
- It starts with burrowing

The fistulous track may proceed in any one or more than one direction.

- Subcutaneous
- Submucous
- External sphincter.
- Internal sphincter. Or between them.
- Infection may go either or inferior to levator ani muscle

C. Stage of abscess formation

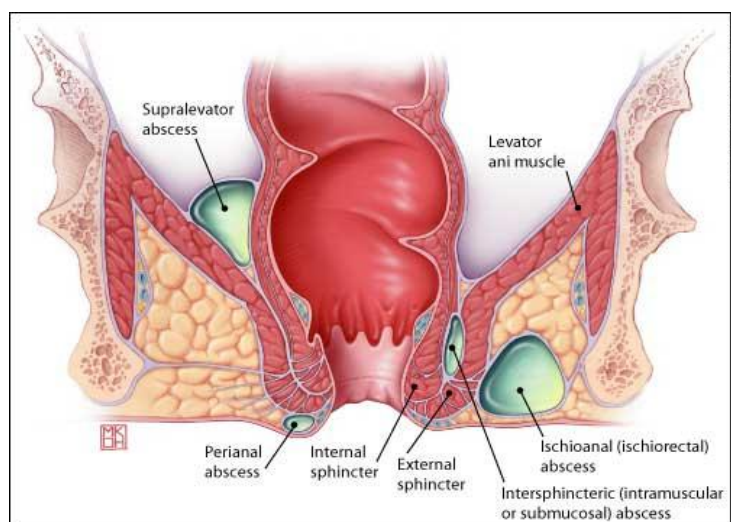
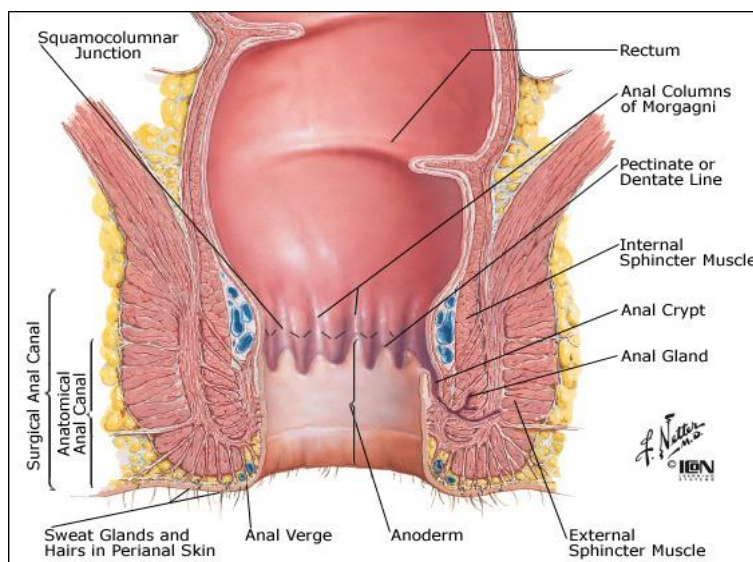
(1) In this condition, the abscess lies between the anal or rectal muscles on one hand and rectal mucosa on other hand.

- a. Sub mucous
- b. Subcutaneous

(2): In this condition, the infection penetrates the musculature and the abscess lies deeper in the tissues.

D. Stage of secondary opening-

- Abscess rupture,
- Secondary opening forms.
- This opening either inside the rectum or on the external surface of the body.



Investigations

At a proper diagnosis and investigations may be ordered to serve two specific purposes i.e., (i) to assess the general condition of patient and to diagnose the associated systematic diseases, and (ii) to find out the extent of fistula and possibly the causes of recurrence. The systematic and associated causes of recurrence should first be ruled out.

The common examinations which are required to be performed on blood and by radiology are:-

Radiological Examinations

- X-ray of chest in PA view
- Plain X-ray of abdomen for K.U.B. region
- X-ray of the spine in A.P. and lateral views
- X-ray of pelvis including both hip-joints
- Barium Enema studies
- Fistulography
- Magnetic Resonance Imaging (MRI)
- CT Scan

Blood Examinations

- Total & differential leucocytic count

- Haemoglobin estimation
- E.S.R. estimation
- Blood sugar estimation, both fasting and post-parendial
- Blood urea estimation
- Serum cholesterol

Fistulography - Is done to Visualize

1. The direction of primary and secondary tract
2. The external and internal openings and their relative positions
3. The relation of the fistulous tract with ano-rectal canal, ano-rectal ring and other structures.
4. To conform the diagnosis of fistula
5. Ramifications of the tracts

Treatment of Anal Fistula

Kshara Sutra therapy

Kshara Sutra therapy is a minimal invasive Ayurvedic Parasurgical procedure and time-tested Ayurvedic technique in the management of Anal Fistula. It is a safe, sure and cost effective method of treatment for fistula-in-ano.

Preparation of Kshara Sutra

The Standard Kshara Sutra is prepared by 11 coatings of Snuhi latex (*Euphorbia nerifolia*), 7 coatings of Snuhi latex and Apamarga Kshara (*Achyranthes aspera*) and last 3 coatings of Snuhi latex and Haridra Churna (*Curcuma longum*). The pH of Apamarga Kshara Sutra is 9.72.

Procedure

The patient is anaesthetized with local or spinal or general anesthesia, then a malleable probe is passed through the external opening of the fistula to the internal opening in the anal canal and probe is gently taken out through anal opening to outside along with a Kshara Sutra in the groove of the probe. Later both ends of the Kshara Sutra is tied together. The Kshara Sutra is replaced by a new one after an interval of one week. The Kshara Sutra gradually cuts and heals the tract. Finally the whole fistulous tract heals after cutting.

Advantages of Kshara Sutra Therapy

- Simple and safe parasurgical procedure.
- Cost-effective and ambulatory.
- Minimal recurrence rate.
- Systemic diseases are also undergoing this procedure.
- No surgical complications like incontinence, stenosis and stricture.

REFRANCES

1. S.das A manual on clinical surgery 10th edition.
2. Chaturvedi Gorakha Nath and Shastri Kasinath Charak samhita (Chikitsa sthana). Varanasi: Chaukhambha Bharati Academy, 2011; 419.
3. Shastri Kaviraja Ambikadutta Sushruta samhita (Nidana Sthaana). Varanasi: Chaukhambha Sanskrit Sansthan, 2010; 306.
4. Chaturvedi Gorakha Nath and Shastri Kasinath Charak samhita (Chikitsa sthana). Varanasi: Chaukhambha Bharati Academy, 2011.
5. Shastri Kaviraja Ambikadutta Sushrutasamhita (Sutra Sthaana). Varanasi: Chaukhambha Sanskrit Sansthan, 2010.