

ARRHYTHMIA OF RARE ETIOLOGY

Dr. Tridip Kumar Sengupta*ⁱ, Dr. Tanmay Mukhopadhyayⁱⁱ and Dr. Kanak Kumar Mitraⁱⁱⁱⁱ)Senior Medical Officer Gr. II, Emergency Medical Unit, High Court, Calcutta, West Bengal, India.ⁱⁱ)Assistant Professor, Department of Cardiology, Burdwan Medical College & Hospital, West Bengal, India.ⁱⁱⁱ)Professor & HOD, Department of Cardiology, R.G.Kar Medical College & Hospital, Kolkata, West Bengal, India.

*Corresponding Author: Dr. Tridip Kumar Sengupta

Fulia Stationpara North, Fulia Colony, Nadia.

Article Received on 05/07/2020

Article Revised on 26/07/2020

Article Accepted on 16/08/2020

ABSTRACT

Palpitation / Arrhythmia is one of the most important and common cardiological problem in any cardiology and / or Medical Out-patient Department (OPD) or Emergency Room(ER) of any hospital or clinic. Arrhythmia can cause palpitation, dizziness, syncope, chest pain or breathlessness and trigger heart failure or even sudden death.^[1] The causes of arrhythmia are: (a) Cardiac – Ischaemic heart disease, structural changes (left atrial dilatation secondary to mitral regurgitation, cardiomyopathy, pericarditis, myocarditis, aberrant conduction pathways); (b) Non-cardiac: caffeine, smoking, alcohol, pneumonia, drugs (beta-blockers, digoxin, L-dopa, tricyclics, doxorubicine) and pheochromocytoma.^[2] Fexofenadine is an anti-histamine used to relieve allergy symptoms such as watery eyes / runny nose, itching eyes / nose, sneezing etc. It works by blocking a certain natural substance (histamine) that our body makes during allergic reactions. This patient, having symptoms of allergic reactions took Fexofenadine, advised by allergy clinic. His allergic reaction subsided; but eventually he developed arrhythmia. The arrhythmia subsided after stoppage of Fexofenadine.

INTRODUCTION

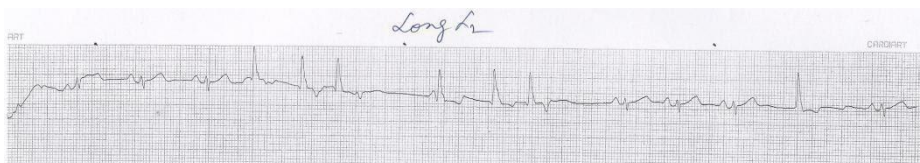
A patient with arrhythmia not associated with pre-existing cardiological ailment leads with diagnostic and treatment dilemmas. The symptoms of palpitation compelled a 23 years old young man to attend and seeking advice for complain relief. The presenting case of arrhythmia which was not a cardiac origin was initially confused. After thorough review of literature, and found a very rare similarity with the patient, the case is presented here.

Case Presentation: A 23 years old, young man presented with palpitation for 4 to 5 days. He was taking Tablet Fexofenadine 120mg. one tablet daily for preceding

seven days for his allergic rhinitis and sneezing. His initial allergic complains subsided, but eventually he noticed palpitation and came to us for advice.

Examination: On clinical examination, his pulse rate was 62 beats per minute (bpm), but the rhythm was irregular. Blood pressure was normal (110/70 mm of Hg). First and second heart sounds were audible, but irregular. Third and fourth heart sounds were inaudible.

Investigations: Immediately he was advised to do a 12 lead resting E.C.G. (Electrocardiogram) with long lead 2 (L2). In the ECG it was found that Sinus arrhythmia and frequent Ventricular Premature Complexes (VPCs).



(ECG fig: 1).

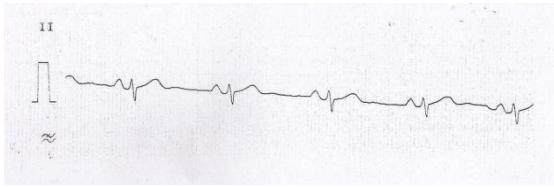
Advice / Treatment: As because he was only on Fexofenadine (a second generation antihistaminic)^[3] he was advised to stop the drug. To relieve his palpitation (the presenting complain) he was given sustained release Metoprolol 12.5 mg (It is a prototype of cardioselective Beta₁ blocker)^[4] one tablet daily for 7 days.

He was advised to review after seven days with a latest 12 lead ECG with long lead 2.

The ECG was normal sinus rhythm and he expressed his better feelings (i.e. no palpitation).

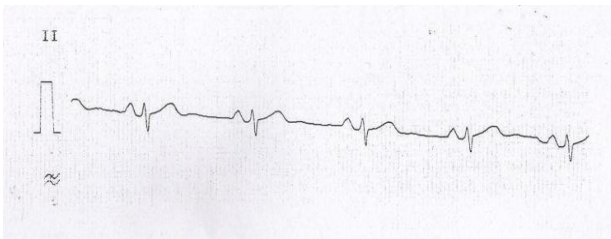
Follow-up: Then he was again advised with assurance and without any medicine stay for another seven days

and review thereafter with same, i.e. 12 lead resting ECG with long lead 2.



(ECG fig: 2).

It was found that the ECG was normal sinus rhythm and the patient is having without any complain.



(ECG fig: 3).

Final Diagnosis: Arrhythmia of Rare Etiology.

REFERENCES

1. Davidson's Essential of Medicine 22nd. Edition, 217.
2. Oxford Textbook of Clinical Medicine, 10th. Edition.
3. Essentials of Medical Pharmacology (7th. Edition), by K.D.Tripathi, 164.
4. Essentials of Medical Pharmacology (7th. Edition), by K.D.Tripathi, 148.