

## ESTHETIC MANAGEMENT OF DISCOLOURED PREVIOUSLY TREATED MAXILLARY INCISOR USING INTRACORONAL BLEACHING TECHNIQUE- A CASE REPORT

Dr. Asha Pius<sup>\*1</sup>, Dr. Jain Mathew<sup>2</sup>, Dr. Robin Theruvil<sup>3</sup> and Dr. Manju Krishna<sup>4</sup>

<sup>1</sup>Final Year MDS Department of Conservative Dentistry and Endodontics St.Gregorios Dental College, Chelad.

<sup>2</sup>Principal, HOD Department of Conservative Dentistry and Endodontics St.Gregorios Dental College, Chelad.

<sup>3</sup>Professor Dept. of Conservative Dentistry and Endodontics St.Gregorios Dental College, Chelad.

<sup>4</sup>Final Year MDS Dept. of Conservative Dentistry and Endodontics St.Gregorios Dental College, Chelad.

\*Corresponding Author: Dr. Asha Pius

Final Year MDS Department of Conservative Dentistry and Endodontics St.Gregorios Dental College, Chelad.

Article Received on 20/05/2020

Article Revised on 10/06/2020

Article Accepted on 30/06/2020

### ABSTRACT

**Introduction:** Discoloration of the anterior tooth due to trauma or endodontic treatment can cause considerable esthetic compromise to patients. The discoloured anterior teeth can cause significant esthetic concerns. The walking bleach technique is a relatively reliable, fairly simple technique for management of discoloration. **Aim:** The aim of this report is to depict the successful management of a discoloured central incisor subsequent to endodontic treatment by intracoronaral bleaching. **Method:** Management of the discoloured endodontically treated tooth was performed using sodium perborate (SP). A 30-year-old female who had undergone endodontic treatment of the central incisor reported with discoloured maxillary central incisor tooth. The case was managed with "walking bleach technique" using Sodium perborate and water. **Results:** Proper selection of bleaching agent and technique had resulted in the conservative and successful management of the case. **Conclusion:** Walking bleaching technique using Sodium perborate can be used as a treatment of choice for nonvital, discoloured endodontically treated cases.

**KEYWORDS:** Walking Bleaching, Discoloration, Nonvital teeth, Sodium Perborate.

### INTRODUCTION

Discoloration of the tooth results from trauma, loss of vitality, restorative procedures and endodontic treatment.<sup>[1]</sup> The remnants of the blood stain as a consequence to trauma or incomplete removal of pulp during endodontic treatment lead to hemolysis.<sup>[2,3]</sup> The chromogenic blood degradation products, such as hemosiderin, hemin, hematin gets deposited in the dentinal tubules.<sup>[4]</sup> The accumulated breakdown products lead to grayish- yellow to brown discoloration of the teeth. Other causes such as obturation materials, remnants of pulp tissue in the pulp horns, coronal restorations and intracanal medicaments may also cause discoloration.<sup>[5,6]</sup> The discoloured anterior teeth can cause significant esthetic concerns.<sup>[7]</sup> Over the years, a number of bleaching and restorative techniques have been proposed for managing discoloured nonvital incisors.<sup>[3,8]</sup> Walking bleach technique is based on the use of chemicals that release active oxygen species such as hydrogen peroxide (H<sub>2</sub>O<sub>2</sub>) or sodium perborate (SP). A combination of Sodium perborate and water or Hydrogen peroxide has been used in the "walking bleach" technique.<sup>[9,10]</sup> The outcome of the bleaching depends

mainly on the concentration of the bleaching agent, ability of the agent to reach the chromophore molecules, and duration and number of times the agent is in contact with chromophore molecules.<sup>[11]</sup> Although Hydrogen peroxide exhibited excellent esthetic outcome, the undesirable consequences such as cervical resorption and irreversible damage to the dentin and surrounding tissues led the clinicians to look for alternative methods. Sodium perborate has been widely used to bleach nonvital teeth with predictable results.<sup>[3]</sup> Sodium perborate is an oxidizing agent containing 95% perborate and is available in three forms: monohydrate, trihydrate, and tetrahydrate. In the presence of water, perborate will break down to form sodium metaborate, Hydrogen peroxide, and oxygen. Sodium perborate is also synergistically used with H<sub>2</sub>O<sub>2</sub> but when used with water released H<sub>2</sub>O<sub>2</sub> in a controlled manner with remarkable esthetic outcome with little or no side effects.<sup>[12]</sup> The Sodium perborate releases active oxygen radicals inside the pulp chamber and diffuses to the dentinal tubules.<sup>[13]</sup> It oxidizes and bleaches the iron sulfide and other pigments present in the dentinal tubules and the free radicals induces oxidative effects to lipids, proteins, and nucleic acids.<sup>[14]</sup> A case of successful

bleaching of discoloured nonvital, endodontically treated tooth using walking bleach technique with Sodium perborate and water is reported.

### Pictures

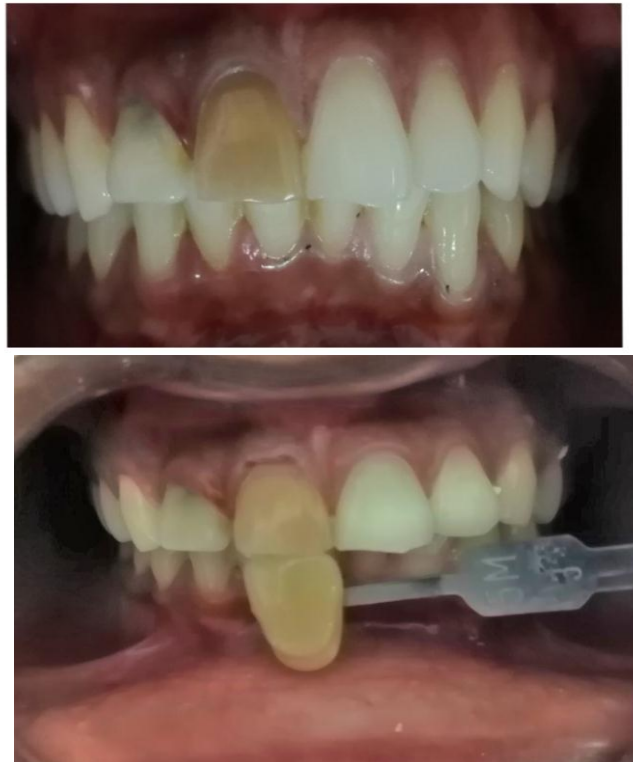

Figure 1: A Pre Operative-Discoloured 11.

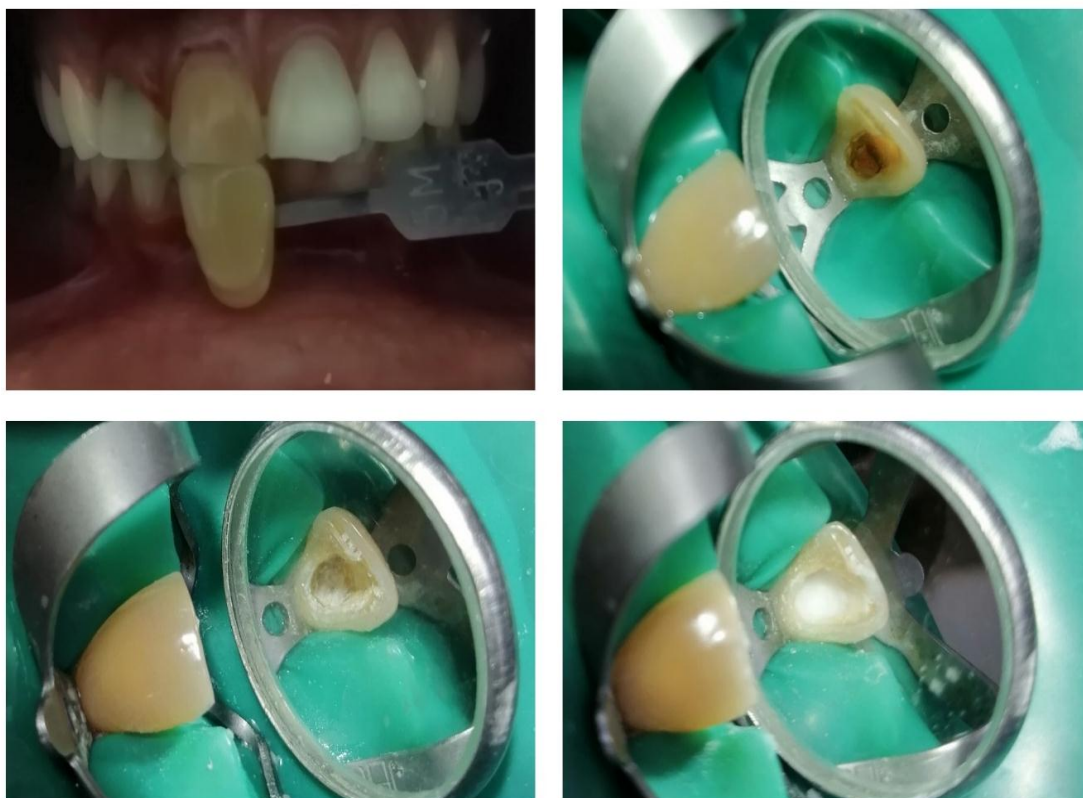


Figure 1: B

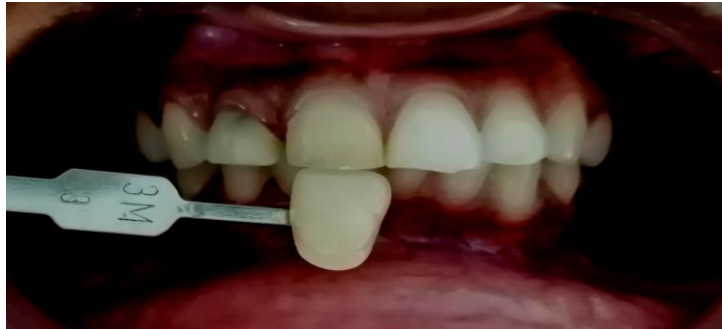

Figure 1: C

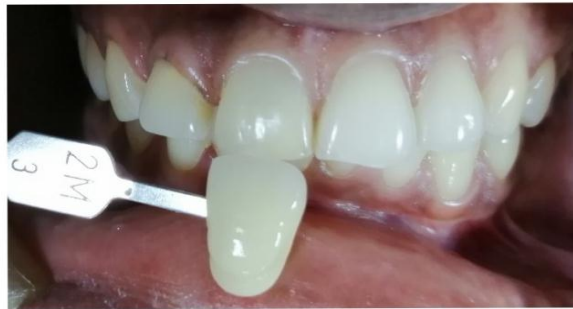
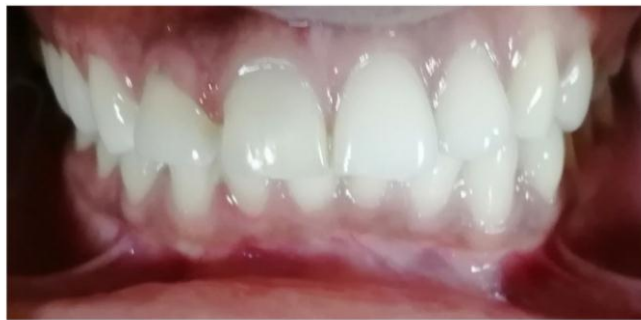
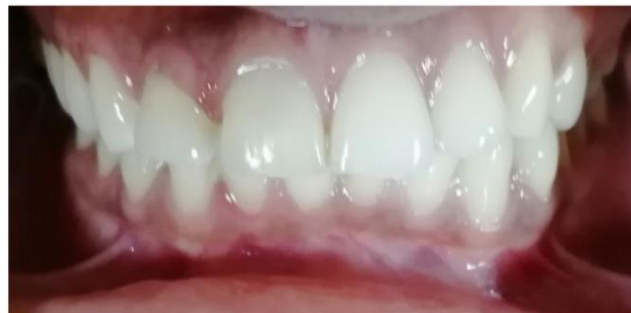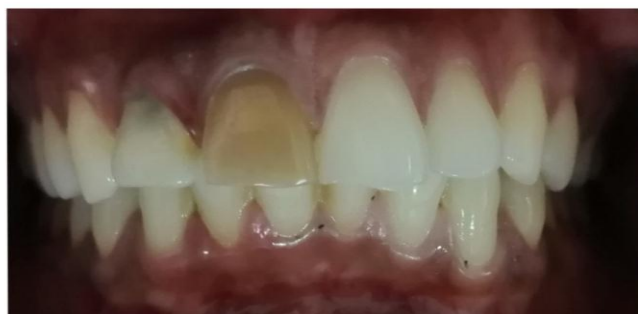Figure 1: D



Post Operative



Pre Operative and Post Operative Comparison

## CASE DESCRIPTION

A 30-year-old woman complained discoloration of her maxillary right central incisor [Figure 1a]. According to the patient's chief complaint, she experienced trauma when she was 9 years old and visited a dentist near her locality at that time. The management of the patient's tooth included root canal therapy followed by restoration. Informed consent from the patient was obtained. Clinical and radiographic examination revealed that the tooth had undergone acceptable root canal treatment and the access cavity was sealed with composite restoration. However, the restoration was not adapted to the internal wall, leaving a gap (of approximately 5 mm) between the restoration and the canal orifice. Initial shade of the tooth was 5M3 calculated by Vita classic 3D Master. The periodontal ligament was continuous with no widening, and the lamina dura appeared normal. At the patient's first visit, the tooth was isolated using a rubber dam (Hygenic®, Coltène®/Whaledent Inc., Cuyahoga Falls, OH, USA) and the prior composite restoration was removed. At the level of the cemento-enamel junction, a resin-modified glass ionomer (GC Fuji II) was placed as a sealing barrier. A mixture of Sodium perborate and distilled water was inserted in to the cavity.(FIGURE 1:B) The cavity was sealed with temporary restoration. Patient was recalled after 1 week. There was a noticeable shade change from 5M3 to 3M3 after 7 days [Figure 1:C]; The procedure was repeated again. After 1 week, shade change was noticed from 3M3 to 2M3 (FIGURE 1:D) at this time, the Sodium perborate was flushed out, and a permanent composite restoration was given. At a 1-year follow-up examination, the patient presented with no symptoms, and the patient was satisfied with the tooth's colour.

## DISCUSSION

Discoloration of the anterior tooth due to trauma or endodontic treatment can cause considerable esthetic compromise to patients. The management of post endodontic tooth discoloration includes full veneers, laminates, crowns, and non invasive technique such as bleaching.<sup>[11,15]</sup> Even though laminate veneer or a full porcelain crown is one of the most predictable methods of managing such cases, it involves the removal of tooth structure.<sup>[8,16]</sup> Nonvital bleaching has many benefits since it is a noninvasive procedure, economical, and less time-consuming. The three most popular techniques for nonvital tooth bleaching are the walking bleach technique, inside/outside bleaching, and in-office bleaching. The walking bleach technique is a relatively reliable, fairly simple technique. The walking bleach technique is performed by application of a paste consisting of SP and distilled water or H<sub>2</sub>O<sub>2</sub> in the pulp chamber.<sup>[17]</sup> The pigmentation that causes the intrinsic discoloration of necrotic pulp consists of long-chain organic molecules. Bleaching using H<sub>2</sub>O<sub>2</sub> will oxidize these long-chain molecules and transform them into

carbon while releasing water and oxygen.<sup>[18]</sup> Internal bleaching requires healthy periodontal tissues and a root canal that is properly treated to prevent the bleaching agent from leaking into periapical tissues.<sup>[19]</sup> In vitro studies have concluded that Sodium perborate in water, Sodium perborate in 3% H<sub>2</sub>O<sub>2</sub>, Sodium perborate in 30% H<sub>2</sub>O<sub>2</sub>, and 10% carbamide peroxide are efficient agents for the internal bleaching of nonvital teeth.<sup>[20,22]</sup> The use of a bleaching agent with a high concentration of H<sub>2</sub>O<sub>2</sub> in combination with heating appears to promote cervical root resorption.<sup>[19,23]</sup> This is attributed to the leakage of bleaching agent through dentinal tubules which initiate an inflammatory reaction.<sup>[24]</sup> Cervical root resorption is a potential complication of nonvital tooth bleaching. Studies have shown that the use of a mixture of Sodium perborate and water showed low potential to cause cervical resorption.<sup>[21,23]</sup> However, in the present case, the use of Sodium perborate and water as well as proper sealing technique prevented the development of resorption.<sup>[25,26]</sup> The resin-modified glass ionomer was placed as a barrier sealant in the present case to avoid leaching of bleaching agent. Sodium perborate in tetrahydrate form mixed with distilled water was used instead of H<sub>2</sub>O<sub>2</sub> to avoid any potential risk of invasive cervical resorption, as shown in prior studies.<sup>[21,23]</sup>

## CONCLUSION

The case presented highlights the effectiveness of the nonvital bleaching using Sodium perborate and water to achieve successful and predictable cosmetic outcome. The case was followed up for 1 year with no sign of relapse of the discoloration or cervical root resorption. Hence, it can be concluded that walking bleaching technique using Sodium perborate can be used as a treatment of choice for nonvital, discoloured endodontically treated cases.

## REFERENCES

1. Ranka M, Dhaliwal H, Albadri S, Brown C. Trauma to the primary dentition and its sequelae. *Dent Update*, 2013; 40: 534-6, 539-40, 542.
2. Rotstein I, Zalkind M, Mor C, Tarabeah A, Friedman S. In vitro efficacy of sodium perborate preparations used for intracoronal bleaching of discolored non-vital teeth. *Endod Dent Traumatol*, 1991; 7: 177-80.
3. Amato M, Scaravilli MS, Farella M, Riccitiello F. Bleaching teeth treated endodontically: Long-term evaluation of a case series. *J Endod*, 2006; 32: 376-8.
4. Arens D. The role of bleaching in esthetics. *Dent Clin North Am*, 1989; 33: 319-36.
5. Krastl G, Allgayer N, Lenherr P, Filippi A, Taneja P, Weiger R. Tooth discoloration induced by endodontic materials: A literature review. *Dent Traumatol*, 2013; 29: 2-7.
6. Mohebbi P, Tour Savadkouhi S. Tooth discoloration induced by calcium-silicate based materials: A

- literature review. *Minerva Stomatol*, 2016; 65: 378-84.
7. Plotino G, Buono L, Grande NM, Pameijer CH, Somma F. Nonvital tooth bleaching: A review of the literature and clinical procedures. *J Endod*, 2008; 34: 394-407.
  8. Beier US, Kapferer I, Burtscher D, Dumfahrt H. Clinical performance of porcelain laminate veneers for up to 20 years. *Int J Prosthodont*, 2012; 25: 79-85.
  9. Camps J, de Franceschi H, Idir F, Roland C, About I. Time-course diffusion of hydrogen peroxide through human dentin: Clinical significance for young tooth internal bleaching. *J Endod*, 2007; 33: 455-9.
  10. Holmstrup G, Palm AM, Lambjerg-Hansen H. Bleaching of discoloured root-filled teeth. *Endod Dent Traumatol*, 1988; 4: 197-201.
  11. Dahl JE, Pallesen U. Tooth bleaching – A critical review of the biological aspects. *Crit Rev Oral Biol Med*, 2003; 14: 292-304.
  12. Valera MC, Camargo CH, Carvalho CA, de Oliveira LD, Camargo SE, Rodrigues CM. Effectiveness of carbamide peroxide and sodium perborate in non-vital discolored teeth. *J Appl Oral Sci.*, 2009; 17: 254-61.
  13. Kawamoto K, Tsujimoto Y. Effects of the hydroxyl radical and hydrogen peroxide on tooth bleaching. *J Endod*, 2004; 30: 45-50.
  14. Attin T, Paqué F, Ajam F, Lennon AM. Review of the current status of tooth whitening with the walking bleach technique. *Int Endod J*, 2003; 36: 313-29.
  15. Fearon J. Tooth whitening: Concepts and controversies. *J Ir Dent Assoc*, 2007; 53: 132-40.
  16. Chen YW, Raigrodski AJ. A conservative approach for treating young adult patients with porcelain laminate veneers. *J Esthet Restor Dent*, 2008; 20: 223-36.
  17. Zimmerli B, Jeger F, Lussi A. Bleaching of nonvital teeth. A clinically relevant literature review. *Schweiz Monatsschr Zahnmed*, 2010; 120: 306-20.
  18. Zarow M. Nonvital tooth bleaching: A case discussion for the clinical practice. *Compend Contin Educ Dent*, 2016; 37: 268-76.
  19. Baratieri LN, Ritter AV, Monteiro S Jr., Caldeira de Andrada MA, Cardoso Vieira LC. Nonvital tooth bleaching: Guidelines for the clinician. *Quintessence Int.*, 1995; 26: 597-608.
  20. Rotstein I, Mor C, Friedman S. Prognosis of intracoronal bleaching with sodium perborate preparation in vitro: 1-year study. *J Endod*, 1993; 19: 10-2.
  21. Ari H, Ungör M. In vitro comparison of different types of sodium perborate used for intracoronal bleaching of discoloured teeth. *Int Endod J*, 2002; 35: 433-6.
  22. Vachon C, Vanek P, Friedman S. Internal bleaching with 10% carbamide peroxide in vitro. *Pract Periodontics Aesthet Dent.*, 1998; 10: 1145-8, 1150, 1152.
  23. Friedman S, Rotstein I, Libfeld H, Stabholz A, Heling I. Incidence of external root resorption and esthetic results in 58 bleached pulpless teeth. *Endod Dent Traumatol*, 1988; 4: 23-6.
  24. Cvek M, Lindvall AM. External root resorption following bleaching of pulpless teeth with oxygen peroxide. *Endod Dent Traumatol*, 1985; 1: 56-60.
  25. Dietschi D. Nonvital bleaching: General considerations and report of two failure cases. *Eur J Esthet Dent.*, 2006; 1: 52-61.
  26. De Oliveira LD, Carvalho CA, Hilgert E, Bondioli IR, de Araújo MA, Valera MC. Sealing evaluation of the cervical base in intracoronal bleaching. *Dent Traumatol*, 2003; 19: 309-13.