

DRY EYE AND ANTIPSYCHOTIC DRUG

Dr. Dimple Shakeet*¹ and Dr. Shakti Krishan Rajguru

Department of Ophthalmology, Barmer Medical College, Barmer (Rajasthan).

*Corresponding Author: Dr. Dimple Shakeet

Department of Ophthalmology, Barmer Medical College, Barmer (Rajasthan).

Article Received on 01/12/2019

Article Revised on 22/12/2019

Article Accepted on 12/01/2020

ABSTRACT

Background: Dry eye disease is a well-known side effect of antipsychotic therapy which is often neglected due to nonspecific symptoms. Therefore, this study is to analyse dry eye prevalence in patients on chronic antipsychotic therapy. **Methods:** This was hospital based cross-sectional study conducted at department of ophthalmology. 50 patients who were diagnosed of schizophrenia and have been under anti-psychotic were included. 50 healthy subjects who have statistically similar demographic features compared with the cases, were involved as a control group. Dry eye was to be diagnosed on the basis of Schirmer's test and TBUT (tearfilm breakup time) Results-16 out of 50 patients on chronic anti-psychotic therapy had dry eye disease. 4 patients were present unilateral dry eye. Maximum 12 (42.86%) eyes out of 28 eyes diagnosed with dry eye had Grade 2 dry eye disease. 50% of the patients found to have dry eye disease were on treatment with anti-psychotic agents for more than 10 years. Prevalence of dry eye was more common (12 out of 19 patients) in patients taking two drug combination. The Schirmer test showed thickness of 3.21 ± 0.68 mm and 14.20 ± 1.45 mm in groups cases and control respectively. The blink rate were observed 4-8 per minute in patients on a anti-psychotic therapy. There was a statistically significant difference in the Schirmer test and blink rate between the two groups. **Conclusion:** Anti psychotic drug may induce dry eye syndrome and thus may lead to morphological alterations in corneal parameters through its anticholinergic and antidopaminergic activities.

KEYWORDS: Dry eye, Prevalence, Antipsychotic Therapy, Combination.

INTRODUCTION

Psychotropic drugs can potentially lead to many ocular adverse effects depending upon the idiosyncrasies, dosages, and the interactions with specific mechanisms of the body organs. After liver, the eye is supposed to be the second most frequent organ to manifest drug toxicity.

The visual system consists of numerous tissues derived from different origins, and the eye has an extensive, rich blood supply although having a relatively small mass. Besides, neural tissues within the eye exhibit a very high metabolic rates. All these factors are important for the human eye becoming sensitive to psychotropic treatments.

In typical antipsychotics, phenothiazine family forms the most examined group in psychotropic agents. The group of phenothiazines has the potential of creating ocular and dermatological side effects. Chlorpromazine, especially when used in high doses, causes abnormal pigmentation in the eyelids, interpalpebral conjunctiva, cornea, and the lens.^[1] Moreover, epithelial keratopathy related to chlorpromazine is discussed by many authors in the literature. Abnormal pigment accumulations related to

chlorpromazine, especially dose of drugs used more than 2 grams daily, develops secondarily.^[2,4]

Typical antipsychotics also have effects on uveal tissues. Antipsychotics which have strong anticholinergic and/or antiadrenergic effects (such as chlorpromazine and fluphenazine) cause mydriasis and cycloplegia. Due to this effect profile, the feature of weakening accommodation by phenothiazines is identified.^[5]

MATERIAL AND METHODS

This was hospital based cross-sectional study conducted at department of ophthalmology. 50 patients who were diagnosed with Schizophrenia and have been under anti psychotic treatment were included. 50 healthy subjects who have statistically similar demographic features compared with the cases, were involved as a control group.

The inclusion criteria were patients with diagnosis of schizophrenia aged 18 to 60 years who had been taking antipsychotic drugs (typical, atypical or both) for at least two years.

The exclusion criteria were patients who had diabetes, systemic arterial hypertension, previously diagnosed ocular diseases (glaucoma, retinopathies, corneal diseases), family history of either glaucoma or blindness, and patients who had taken corticosteroids, amiodarone or had had any ocular trauma. No patients with symptoms of acute angle closure glaucoma were included. Patients who did not give consent and who were not cooperative also exclude from study.

Dry eye was to be diagnosed on the basis of Schirmer's test and TBUT (tearfilm breakup time).

Statistical analysis of the subjects was evaluated by using SPSS (for Windows version 22.0; SPSS Inc., Chicago, IL) program.

RESULTS

Table 1: Socio-demographic profile.

Variable	Case (n=50)	Control (n=50)	p-value
Mean age \pm SD (Yrs)	42.56 \pm 12.26	44.11 \pm 11.31	>0.05
Male : Female	22:28	24:26	>0.05
Rural : Urban	28:22	26:24	>0.05
Socio-economic status (B.G Prasad scale) I:II:III:IV	11:14:13:12	10:13:15:12	>0.05
Hindu : Muslim	41:9	43:7	>0.05

The socio-demographic profile of both group were comparable.

16 out of 50 patients on chronic anti-psychotic therapy had dry eye disease.

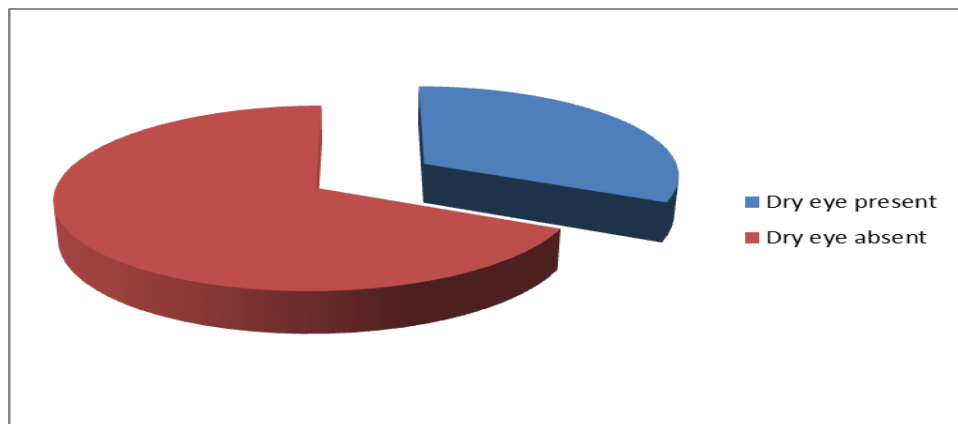


Fig.1 prevalence of dry eye

Table 2: Grading of Dry Eye Disease.

Grading of dry eye disease	Number of eye	Percentage
1	1	3.57
2	12	42.86
3	9	32.14
4	6	21.43
Total	28	100.00

4 patients were present unilateral dry eye. Maximum 12 (42.86%) eyes out of 28 eyes diagnosed with dry eye had Grade 2 dry eye disease.

Table 3: Duration of Drug Therapy.

Duration of Drug Therapy	Dry eye present	Dry eye absent
2-5 Yrs	3(18.75%)	21(61.76%)
5-10 Yrs	5(31.25%)	8(23.52%)
>10 yrs	8(50.00%)	5(14.70%)
Total	16	34

50% of the patients found to have dry eye disease were on treatment with anti-psychotic agents for more than 10 years.

Table 4. Combination drug therapy.

Drug Therapy	Dry eye present	Dry eye absent
Mono drug	4(25.00%)	27(79.41%)
Two drug combination	12(75.00%)	7(20.59%)
Total	16	34

Prevalence of dry eye was more common (12 out of 19 patients) in patients taking two drug combination.

Table 5: Ocular examination.

Variable	Case (n=50)	Control (n=50)	p-value
Blink rate per minute	7(4-8) per minute	17(16-18) per minute	<0.05
TUBT abnormal	28 eye	1 eye	<0.05
Schirmer's Test (thickness)	3.21 ± 0.68 mm	14.20 ± 1.45 mm	<0.05

The Schirmer test showed thickness of 3.21 ± 0.68 mm and 14.20 ± 1.45 mm in groups cases and control respectively. The blink rate were observed in 4-8 per minute in patients on a anti-psychotic therapy. There was a statistically significant difference in the Schirmer test and blink rate between the two groups.

DISCUSSION

16 patients out of 50 patients on anti-psychotic medications for more than 2 years had dry eye disease. Of the 100 eyes evaluated, 28 eyes were found to have dry eye disease. Patients on two drug regimen showed more prevalence of dry eye than on mono drug regimen in our study.

Dry eye disease is multifactorial disease of tear film and ocular surface that results in symptoms of discomfort, visual disturbance and tear film instability with potential damage to ocular surface.^[6] It is accompanied by increased osmolarity of tear film and inflammation of ocular surface.

Dry eye is a chronic disease becoming commoner among the people all over the world, some of whom become blind as sequelae. So, a better knowledge of the disease and better mode of treatment would aid the physician to help these patients to overcome this chronic problem and maintain a good visual acuity.

Anti-psychotic agents are very commonly used medications in a Psychiatry setup for patients suffering from Psychoses and Delusional disorder. As these patients are on medications all through their life, side effects are seen very commonly in them.

Eye is the second most commonly affected organ by Anti-psychotic medications. Ocular side effects include blurring of vision, dry eye, corneal deposition of drugs, stellate capsular deposits, oculogyric crisis etc.^[7] Of these many ocular side effects, Dry eye disease, often does not get proper attention and thus, leads to great

discomfort to the patients. Possible mechanism suggested is due to the anti-cholinergic action of these drugs, they block the muscarinic receptors present over lacrimal gland. This decreases the tear secretion leading to an unstable tear aqueous layer. And that is the reason for aqueous deficiency and dryness of eyes.^[8] According to a study by McIntosh et al, the schizophrenic patients on neuroleptics showed decreased blink rate which may be another cause of dry eye in these patients.^[9]

Antipsychotic medication, exhibits anticholinergic side effects by blocking muscarinic and nicotinic receptors, and muscarinic-3 receptors in the conjunctiva and lacrimal gland as well. This leads to decreased mucous and aqueous secretion.^[10] Persistent tear film instability can lead to morphological and biomechanical changes at the cellular level, ultimately affecting the ocular surface and vision.^[10] Prompt lubrication and use of tear rehabilitating agents as cyclosporine can prevent desiccation.^[11]

CONCLUSION

Anti psychotic drug may induce dry eye syndrome and thus may lead to morphological alterations in corneal parameters through its anticholinergic and antidopaminergic activities.

REFERENCES

1. Li J, Tripathi RC, Tripathi BJ. Drug-induced ocular disorders. *Drug Saf.*, 2008; 31: 127-41.
2. Bond WS, Yee GC. Ocular and cutaneous effects of chronic phenothiazine therapy. *Am J Hosp Pharm*, 1980; 37: 74-8.
3. Johnson AW, Buffaloe WJ. Chlorpromazine epithelial keratopathy. *Arch Ophthalmol*, 1966; 76: 664-7.
4. Edler K, Gottfries CG, Haslund J, Ravn J. Eye changes in connection with neuroleptic treatment especially concerning phenothiazines and thioxanthenes. *Acta Psychiatr Scand*, 1971; 47: 377-84.

5. Hansen TE, Casey DE, Hoffman WF. Neuroleptic intolerance. *Schizophr Bull*, 1997; 23: 567-82.
6. Malone DA, Camara EG, Krug JH. Ophthalmologic effects of psychotropic medications. *Psychosomatics*, 1992; 33(3): 271-277.
7. Sihota R, Tandon R. *Parson's diseases of the eye*. 22nd edn. Elsevier, 2015.
8. Minhas BOD. The Mind's eye: ocular complications of psychotropic medications. *Review of Optometry*, 2016.
9. Oshika T. Ocular adverse effects of neuropsychiatric agents: incidence and management. *Drug Saf*, 1995; 12(4): 256-263.
10. Mackintosh JH, Kumar R, Kitamura T. Blink rate in psychiatric illness. *The British Journal of Psychiatry*, 1983; 143(1): 55-57.
11. Pensyl CD. Preparations of dry eye and ocular surface disease. In: Bartlett JD, Jaanus SD, eds. *Clinical ocular pharmacology*. 5th edn. Butterworth-Heinemann, 2008.