

**MESENCHYMAL ORIGIN TUMORS OF PAROTID GLAND**<sup>1</sup>Dr. Hafsa Imtiaz, <sup>2</sup>\*Dr. Waqar Hassan Kulachi and <sup>3</sup>Dr. Zain UL Abdin<sup>1</sup>PMDC # 16426-D.<sup>2</sup>PMDC # 22006-D.<sup>3</sup>PMDC # 22811-D.**\*Corresponding Author: Dr. Waqar Hassan Kulachi**

PMDC # 22006-D.

Article Received on 21/10/2019

Article Revised on 11/11/2019

Article Accepted on 01/12/2019

**ABSTRACT**

Desmoid tumor is a proliferation of a mesenchymal, fibroblastic or myofibroblastic tissue. It is a non-capsulated tumor. Despite its benign nature, desmoids tumor have an aggressive behavior. Its localization in the parotid gland has rarely been reported in the literature. The particularity of this location in the head and neck is the proximity of Vascularnervous structures, the facial nerve in the parotid location and the consequence, if affected, on the facial motility especially that this tumor often occurs in young people. The clinical presentation is often about a slow-growing mass characterized by being: painless, ill-defined, firm, non-inflammatory, deeply located, and fixed to the underlying structures. Treatments strategies, always made by a multidisciplinary committee, are based on the natural biological behavior of this deep fibromatosis which is unpredictable and variable. Surgery could be undergone every time it is radical. Radiotherapy could also be played. However, the most relevant point is that actually, most authors highlighted the conservative approach by the “wait and see” policy for primary as well as for recurrence of the disease after surgical resection or radiotherapy.

**KEYWORDS:** mesenchymal, fibroblastic or myofibroblastic tissue.**1. INTRODUCTION**

The desmoid tumor also called aggressive fibromatosis, is a proliferation of a mesenchymal, fibroblastic or myofibroblastic tissue<sup>[1]</sup>, arising from deep musculoaponeurotic structures<sup>[2,3]</sup>, that could occur throughout the body.<sup>[1]</sup> It is a rare tumor that accounts for only 0, 03% of all neoplasm<sup>[4]</sup> with an annual incidence estimated at 2-4 cases /million / year.<sup>[5]</sup>

Despite its benign histology, this tumor is characterized by infiltrative growth and the absence of proper capsule which explains the high incidence of local recurrence but without showing any metastasis<sup>[6]</sup>; thus some authors classified it as a low-grade mesenchymal tumor or sarcoma.<sup>[1,2]</sup>

The localization in the head and neck was reported in 12% of cases of extra-abdominal fibromatosis<sup>[5]</sup> and seems to be more aggressive in this region due to the restricted anatomy and the recurrence rate following the surgical resection.<sup>[5]</sup>

**2. CASE REPORT**

We report a case of a woman aged 26-year-old, who underwent one year ago; in another medical center; a

superficial parotidectomy on the right side, the histopathologic analysis objective an « aggressive fibromatosis ». Currently, she consulted our Institute for recurrence of the parotid swelling growing slowly with no associated symptoms; especially there was no facial palsy.

On physical examination, we palpated a firm, painless, fixed parotid mass on the right side, measuring 5 cm in greatest diameter and with ill-defined borders, the overlying skin was normal, no facial palsy was associated neither bulging of the lateral pharyngeal wall or soft palate.

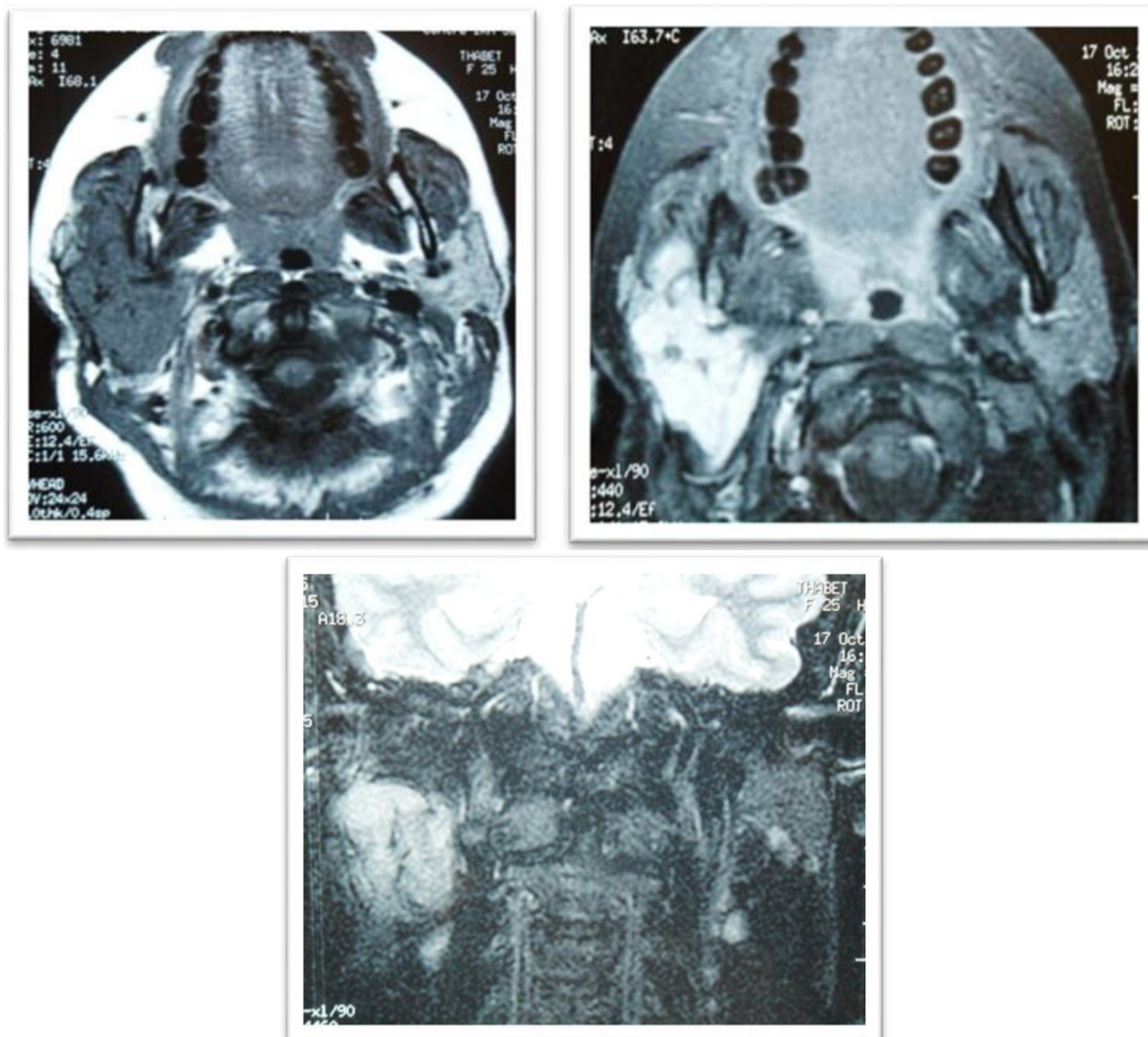
MRI was performed and showed a right parotid tumor of the 2 lobes, poly-lobulated with high enhancement after injection of contrast material; the axial T1weighted demonstrates low signal intensity. Indeed, it was a relapse of this desmoid tumor. Through the MRI we evaluated, and we judged this mass as couldn't be removed without squeal. The decision, taken in a multidisciplinary consultation meeting, recommended radiotherapy since surgery will not be radical with an increased risk of functional complications and more morbid recurrence. We also indicated tamoxifen as an

adjuvant therapy. We observed a marked interruption of tumor progression during 2 years controlled by imaging.

### 3. DISCUSSION

The desmoid tumor is a rare benign tumor arising from connective tissue, fascial sheaths and aponeurotic structures.<sup>[2]</sup> The pathogenesis of this nonencapsulated lesion is still unknown.<sup>[5]</sup> The head and neck localization is not common and is mostly sporadic.<sup>[6]</sup> During 40 years (1968-2008) only 179 cases were reported.<sup>[5]</sup> Parotid localization has been very rarely treated; they have tried to separate it from that arising from other parts of the body<sup>[10]</sup>, due to its relation to its critical anatomical position.<sup>[4]</sup> The peak incidence is situating about the third decade<sup>[5,6]</sup>, our patient was younger 24 years. The

behavior of this tumor seems to be more aggressive in younger people. Some authors report that both genders are equally affected<sup>[6]</sup>, others one reports a female predominance. No significant racial or ethnic distribution has been objectified.<sup>[5]</sup> The etiology is still unknown.<sup>[7]</sup> In our case, we do not found any particular antecedent or risk factor. In the literature, most studies have reported an association and possible implication with trauma (including surgery), pregnancy, estrogen exposure and genetic predisposition.<sup>[3,5,7]</sup> In fact, the most commonly correlated etiological factor seems to be previous musculoaponeurotic trauma; while genetic abnormalities (mainly trisomy 8 and 20) and steroid hormones are additional factors that may contribute to the genesis of these tumors.



**Fig. 1, 2 and 3: MRI in axial and coronal section showing the left parotid tissue formation in hypoT1 and enhanced after injection of PDC.**

Desmoids are one of the multiple tumors with demonstrated mutations in exon 3 of the  $\beta$ -catenin gene.<sup>[1]</sup> Thus the resultant loss of ability to degrade  $\beta$ -

catenin and elevated  $\beta$ -catenin levels promotes fibroblastic proliferation.<sup>[8]</sup> Mutations in the gene encoding  $\beta$ -catenin CTNNB1 are highly prevalent in

sporadic desmoid tumors and may predict the risk of recurrence.<sup>[9]</sup>

Clinically, in our observation, the characteristics presentation of the parotid swelling was similar to what described in the literature. Deep fibromatosis may reach a large size; it generally appears as a mass characterized by being: painless, ill-defined, firm, non-inflammatory, deeply located, fixed to the underlying structures, and which grow slowly.<sup>[2,4,6]</sup> The natural biological behavior of deep fibromatosis can be unpredictable and variable<sup>[10]</sup>; that means that a significant proportion (about 50%) of patients have tumors that remain spontaneously stable after initial progression or even regress and hence benefit from a front line non-aggressive policy (watch and wait).<sup>[10]</sup> This spontaneous regression has been observed in the menarche and menopause.<sup>[5]</sup>

Histologically, it is composed of well-differentiated fibroblasts, fibrocytes, and myofibroblasts within collagenous to myxoid stroma.<sup>[6]</sup> No atypical mitosis or anaplastic elements are found.<sup>[6]</sup> Nevertheless, its clinical, behavioral character varies from benign fibrous lesions to fibrosarcomas.<sup>[11]</sup> The histological confirmation is obtained via a core needle or surgical biopsy which is necessary for accurate diagnosis; the IHC studies have an important role.<sup>[1]</sup>

Treatment is challenging due to the wide variety of clinical findings and locations of the tumor, difficulties in estimating its progression and prognosis and alternative management methods. The major difficulties encountered are the rarity of the tumor and lack of a large patient series.<sup>[11]</sup> In all cases, the ultimate treatment goal is tumor control avoiding recurrence, since the probability of dying from aggressive fibromatosis stay relatively low.<sup>[8]</sup> Since this tumor is characterized by an unpredictable natural history, patient with this tumor should be managed by a multidisciplinary team with expertise in sarcoma treatment; hence treatment alternative should be individualized.<sup>[1]</sup>

Currently, most authors highlight the conservative approach by the “wait and see” policy for primary as well as for recurrence of the disease after surgical resection or radiotherapy. S. Bonvalot objective that the surgical strategy does not provide a benefit regarding local control over non-surgical strategies in the extra-abdominal localization.<sup>[12]</sup> The non-surgical option is interesting also in cases of large fibromatosis of the head and neck region, and for tumor localized in anatomically difficult structures that need to be preserved as much as possible<sup>[3,6]</sup>, then alternative therapy are radiotherapy and chemotherapy.<sup>[5,6]</sup> Previously, the main treatment modality is surgical excision responding to tumor-free margins with function preserving approach<sup>[3,8]</sup>; and the recommended margins are 2 and 4 cm respectively in the transverse plane and along the longitudinal axis and less than 3 cm<sup>[6]</sup>; however, in the head and neck region, the

preservation of vital structures, their function, and the aesthetics need may impede this objective.<sup>[2]</sup> Therefore, a multimodality management strategy is usually employed to control residual tumor.<sup>[2]</sup>

Alternatively, some authors prefer a radical neck dissection for all neck fibromatosis in order to reduce recurrence rates by 33% through aggressive surgery<sup>[5]</sup>; but since it does not metastasize, and the recurrence rate is higher, the indication for a radical neck dissection should be careful and reasonable.<sup>[5]</sup> In order to control residual disease and to prevent recurrence, surgery is usually combined with radiation therapy<sup>[2,8]</sup>. Some authors considered that the adjuvant postoperative radiotherapy is a must in the treatment of aggressive fibromatosis<sup>[8]</sup>, appearing to be a rational approach instead of sacrificing function and avoiding disfigurement to reach tumor-free margins, so with a combined treatment only modest surgical interventions may be needed along with a significant improvement in local control<sup>[3,8,11]</sup>; Zelefsky and all reported good results with brachytherapy for recurrent fibromatosis after surgical resection and achieved local control in 70% of patients.<sup>[6]</sup>

Besides, studies have shown that radiation therapy can also be effectively employed independently, with total dose recommended 55 to 60 Gy<sup>[3]</sup>, leading to a complete response in 20%, a partial response in 20% and stable disease in 53% of cases, supporting evidence that radiation therapy may decrease indications for surgery<sup>[2]</sup>, because surgery as a trauma can provide an impetus for tumor development, therefore avoidance of surgery with the only radiotherapy could lead to local improvement.<sup>[3]</sup> In addition, radiotherapy itself could change the tumor behavior.<sup>[3]</sup>

However, radiation therapy is associated with a high risk of complications, especially in the head and neck region, what should be only used in cases of residual disease or where surgery may significantly impair the functional capabilities of the patient.<sup>[2,6]</sup>

Concerning advanced disease with a gross tumor, radiotherapy alone can also be used and leads to tumor control in 70% to 80% of cases, despite the reduction in tumor size may not occur.<sup>[3,10]</sup> If radiotherapy is contraindicated, chemotherapy is a valid alternative.<sup>[6]</sup> Systemic therapy can be interesting for unresectable disease, or in cases where surgical and radiation therapy may lead to significant morbidity<sup>[2,9]</sup>, or If the margins are positive after surgery because there is an advantage for patients who received adjuvant chemotherapy compared with who did not receive adjuvant treatment.<sup>[3]</sup> An experimental protocol based on a combination of three drugs (vincristine, actinomycin D, and cyclophosphamide) can be used and must be combined with continuous follow up with MRI.<sup>[6]</sup>



The use of chemotherapeutic and other systemic agents may be a reasonable alternative to avoid radiotherapy in the growing child.<sup>[3]</sup> Sarcoma alliance for research through collaboration (SARC) initiated a multicenter phase II trial on the efficacy of Imatinib (tyrosine kinase inhibitor) in aggressive fibromatosis, and estimated progression-free survival was 94% and 88%, for 2 and 4 months respectively, whereas one-year progression-free survival was 66%.<sup>[9]</sup>

There were other pharmacologic therapies that were analyzed and tried. As known, growth tumor was influenced by hormonal factors; estrogen was more implicated than progesterone. Then, In order to avoid surgery; that may be mutilating or at risk of local recurrence especially when it is marginal; some centers tried tamoxifen and concluded an inhibition of growth tumor.<sup>[13]</sup>

Raymond.P et al. demonstrated that COX-2 is expressed in the majority of aggressive fibromatoses, and so he concluded through his data that COX blockade could have the role of slowing growth tumor.<sup>[14]</sup> This data is in agreement with our finding. Indeed, we recommended this treatment as an adjuvant to the radiotherapy, and we have succeeded to obtain tumor growth interruption and stabilization of the disease without any functional or cosmetic deterioration nor radiation complications, and this was during 2 years.

The problem concerning all these therapy options seems to be the lack of experience in using them in head and neck region fibromatosis.<sup>[5]</sup>

Local control of aggressive fibromatosis remains a significant problem with an average recurrence of 24 to 77% no matter what therapeutic modality have been used.<sup>[15]</sup> It often occurs in a delay of 18 months what was also observed in our patient.

Astrid L and al. in his review of the literature over 40 years (1968-2008) doesn't observe clear prognostic factors of recurrence.<sup>[5]</sup>

In cases of patients undergoing multimodality treatment, including surgical resection and radiation therapy, the recurrence-free survival rate is 83, 6% at five years (2) with figures going up to 88, 5% for 10year recurrence-free survival.<sup>[2]</sup>

Kruse and al in their review of the literature found no indicators for potential recurrence in relation to age, sex, or localization<sup>[5]</sup> but the depth of invasion was shown to affect disease-free survival(2) significantly. In a consecutive series, surgery for tumor diameter > 10 mm were the most significant prognostic factors associated.<sup>[15]</sup>

The risk of local recurrence after non-wide resection is 8-70%<sup>[7]</sup> and it is de 20-46% in case of radiotherapy; there

is a wide variation in the natural history of aggressive fibromatosis, ranging from the spontaneous regression, stability to morbid progression, and this regardless the modality of treatment used.<sup>[7]</sup> In fact, some authors report the absence of recurrence or progressive disease even in cases with residual disease or microscopically positive margins after surgery removal; this implies that the persistence of tumor cells does not necessarily equate with evolutive disease.<sup>[7]</sup>

Some authors noticed that radiotherapy prevents recurrence especially in patients with microscopically residual tumors.<sup>[11]</sup>

Our patient had had a recurrence of parotid demoids in a delay of one year, and the major factor was probably the age and so the hormonal status. Radiotherapy associated with an anti COX-2 offer to her the chance of local control and none facial dysfunction or esthetic problem especially for young women.

#### 4. CONCLUSION

Aggressive fibromatosis is a rare benign tumor, characterized by an unpredictable biologic behavior. Thus there is a lack of a therapeutic consensus. Consequently, treatment has to be individualized for each patient while keeping in mind that surgery resection, whenever it will be non-marginal, and followed by adjuvant radiotherapy, seems to be the best protocol available. The "wait and see policy" is an interesting option for asymptomatic and slow growing tumor which progression will not be harmful. Concerning advanced disease, chemotherapy and Imatinib could be an effective alternative.

#### REFERENCES

1. Kotiligam D., Lazar A.J.F., Pollock R.E. and Lev D. Desmoid tumor: a disease opportune for molecular insights. *Histol Histopathol*, 2008; 23: 117-126.
2. Sobani Z., Junaid M. and Khan M. Successful management of aggressive fibromatosis of the neck using wide surgical excision: a case report. *Journal of Medical Case Reports*, 2011; 5: 244.
3. Ghazipour A., Ghavami Lahiji S., Bradd B. and Saleheh F. Huge Facial Desmoid Tumors with Neck Extension. *Iranian Journal of Otorhinolaryngology*, Jul 2014; 26(3): Serial No.76.
4. Nagar Milesh, Kaushal Manish, Shukla A and coll "an interesting case of fibromatosis of neck with review of literature"; *Pakistani J Surg Oncol*, December 2013; 4(4): 378-381.
5. L. Kruse A., T. Luebbers H., W. Gratz K. and A. Obwegeser J. Aggressive fibromatosis of the head and neck: a new classification based on a literature review over 40 years (1968-2008). Springer-Verlag 2010.
6. Angiero F., Benedecenti S., and Stefani M. Fibromatosis of the Head and Neck: Morphological,

- Immunohistochemical and Clinical Features. *Anticancer Research*, 2008; 28: 1725-1732.
7. Mitchell G., Thomas J., and L. Harmer C. Aggressive fibromatosis: evidence for a stable phase. *Sarcoma*, 1998; 2: 149-154.
  8. G Baumert B., O Spahr M., Von Hochstetter A., and Coll. The impact of radiotherapy in the treatment of desmoids tumors. An international survey of 110 patients. A study of the Rare Cancer Network. *Radiation Oncology*, 2007; 2: 12.
  9. T. Mullen J., F. Delaney T., E. Rosenberg A., and Coll. Catenin Mutation Status and Outcomes in Sporadic Desmoid. *The Oncologist*, 2013; 18: 1043-1049.
  10. Kesus R.B., Nout R.A., Blay J.-Y. and Coll. Results of a phase II pilot study of moderate dose radiotherapy for inoperable desmoidstype fibromatosis-an EORTC STBSG and ROG study (EORTC 62991-22998). *Annals of Oncology*, 2013; 24: 2672-2676.
  11. Levent K., Burçin K., Dundar S. and Coll. Aggressive fibromatosis: evaluation of prognostic factors and outcomes of surgical treatment. *Acta Orthop Traumatol Turc.*, 2014; 48(1): 55-60.
  12. Bonvalot.S, Eldweny.H, Haddad.V and coll "fibromatoses extra-abdominales primitives: certains patients peuvent-ils éviter la chirurgie?"; e-mémoires de l'académie nationale de chirurgie, 2007; 6(2): 72-80.
  13. Hansmann AN, Adolph Claudia, Vogel TI, and coll "High-dose Tamoxifen and sulindac as first-line treatment for desmoids tumors", *American cancer society, Cancer*, February 1, 2004; /volume 100/Number 3: 612-620.
  14. Raymond P, Ron S, Catherine Li., « cyclooxygenase-two (COX2) modulates proliferation in aggressive fibromatosis (desmoid tumor), *Oncogene*, 2001; 20: 451-460.
  15. Bertani E., Testori A., Chiappa A. and Coll. Recurrence and prognostic factors in patients with aggressive fibromatosis. The role of radical surgery and its limitations. *World Journal of Surgical Oncology*, 2012; 10: 184.