

**COMPARATIVE STUDY BETWEEN ASPIRATION FOLLOWED BY INTRA-LESIONAL STEROID INJECTION AND SURGICAL EXCISION FOR THE MANAGEMENT OF DORSAL WRIST GANGLION IN A TERTIARY CARE HOSPITAL****Dr. Ajaz Ahmad Shah<sup>1</sup>, Dr. Ashiq Hussain Raina<sup>2</sup>, Dr. Mudasir Ahmad Ganie<sup>3</sup> and Dr. Irshad Ahmad Kumar<sup>4</sup>**<sup>1</sup>Senior Resident, Department of General Surgery, GMC Srinagar, Jammu and Kashmir, 190010, India.<sup>2,4</sup>Resident, Department of General Surgery, GMC Srinagar, Jammu and Kashmir, 190010, India.<sup>3</sup>Resident, Department of General Medicine, GMC Srinagar, Jammu and Kashmir, 190010, India**\*Corresponding Author: Dr. Ajaz Ahmad Shah**

Senior Resident, Department of General Surgery, GMC Srinagar, Jammu and Kashmir, 190010, India.

Article Received on 21/04/2019

Article Revised on 11/05/2019

Article Accepted on 31/05/2019

**ABSTRACT**

**Objective-** To compare aspiration followed by intra-lesional steroid (triamcinolone acetate) injection and surgical excision in the management of dorsal wrist ganglion. **Method** – This was a prospective study conducted from Aug 2016 to Aug 2018 in department of general surgery Government Medical college Srinagar, a total number of 86 Patients with dorsal wrist ganglions were offered treatment in two groups: A- aspiration with Intralesional Triamcinolone Acetonide Injection into the cyst in 68 patients, B-surgical excision in 18 patients. Follow up was done at 1, 3, 6 and 12 months. **Result-** Successful treatment in group A was seen in 59 patients (86.76%), and in group B in 15 patients (83.33%). **Conclusion-** Aspiration followed by intra-lesional steroid (triamcinolone acetate) injection is a better mode of management than surgical excision.

**KEYWORDS:** Dorsal wrist ganglion, aspiration, triamcinolone acetate, intra-lesional steroid, excision.**INTRODUCTION**

<sup>[1,2]</sup> Carpal ganglion cyst is the most common benign soft tissue tumor, approximately 50- 70% of the tumors of the hand and wrist area.<sup>[1]</sup> They may subside with rest, enlarge with activity, and rupture or disappear spontaneously.<sup>[3]</sup> Ganglions are generally seen between the second and fourth decades of life and are more prevalent in women. Patients usually seek medical attention because of the pain, mass, weakness or fear of a malignancy. They are the most common tumor like conditions in the hand and wrist which usually arise from a pedicle in tendon sheath or joint capsule and located over scapholunate ligament. About 60% - 70% of ganglion cysts are found in dorsal aspect of the wrist.<sup>[4]</sup> There are a number of treatment modalities for ganglion such as observation, aspiration, intralesional steroid injection, sclerotherapy and surgical excision, but none of these modalities has been the standard or best treatment.<sup>[5,6,7]</sup> Surgical measures like transfixation, aspiration with seton transfixation, surgical excision and more recently by arthroscopy, but no one of these has been the standard or best treatment. At present aspiration is the mainstay of non operative management and most studies demonstrate a success rate of around 70%. To improve the results of treatment aspiration is combined with steroid injection into the ganglion wall. We did this study to compare the effectiveness of the two traditional

methods aspiration followed by intralesional steroid (triamcinolone acetate) injection and surgical excision.

**MATERIALS AND METHODS**

This was a prospective study conducted from Aug 2016 to Aug 2018 in department of general surgery Government Medical college Srinagar, Patients with clinical diagnosis of dorsal wrist ganglion of atleast 1cm in size, and more than 15 years of age, history of trauma and previous treatment was ruled out and willing for follow-up, were included in the study. Diagnosis of ganglion was based on history and clinical examination. In some patients radiological investigations like X-ray and ultrasonography was done to rule out other lesions. All patients were informed and explained about the lesion and their treatment plan. A total of 86 patients were divided according to their treatment option into two groups:

- A. Aspiration followed by intralesional steroid (triamcinolone acetate) injection.
- B. Surgical excision.

In group A, under standard aseptic precautions, the ganglion was first infiltrated with 2% xylocaine using 26 G needle and then aspiration was done using 18 G needle and then 40mg triamcinolone acetate was injected using the same needle port and pre-filled syringe containing

the diluted triamcinolone. Crepe bandage was applied and wrist immobilized for 2 days.

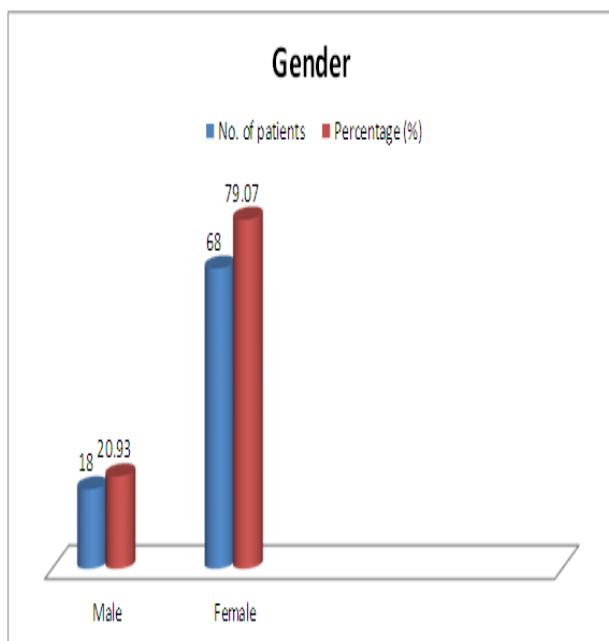
In group B the surgical excision was done using similar standard aseptic precautions and after local infiltration of 10 cc of 2% xylocaine. In surgical procedure entire cyst complex including cyst, pedicle and a cuff of adjacent joint capsule was excised. Follow-up was done at 1, 3, 6 and 12 months after treatment. Successful treatment was defined as disappearance of the cyst on final visit. In case of recurrence treatment was defined as failure.

## RESULTS

A total of 86 patients were included in the study. There were 68 (79.06%) females and 18 (20.93%) males. The mean age was 24.8 years (Range-16-48ys).

### Gender wise distribution of the patients.

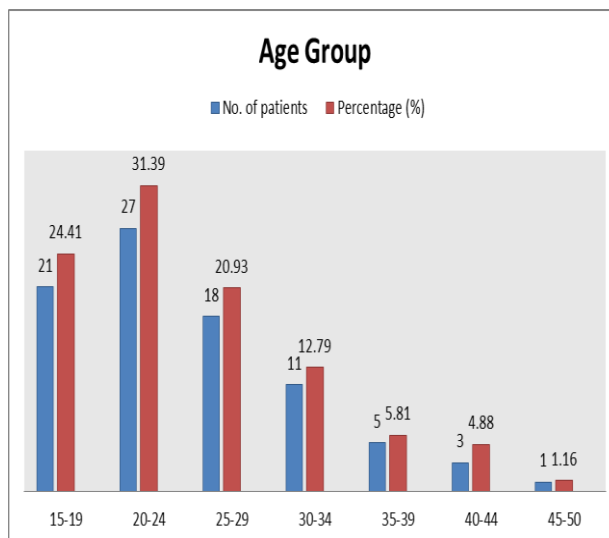
S. No.	Gender	No. of patients	Percentage (%)
1	Male	18	20.93
2	Female	68	79.07
	Total	86	100.00



### Age wise distribution of the patients.

S. No.	Age group (in years)	No. of patients	Percentage (%)
1	15-19	21	24.41
2	20-24	27	31.39
3	25-29	18	20.93
4	30-34	11	12.79
5	35-39	5	5.81
6	40-44	3	4.88
7	45-50	1	1.16
	Total	86	100

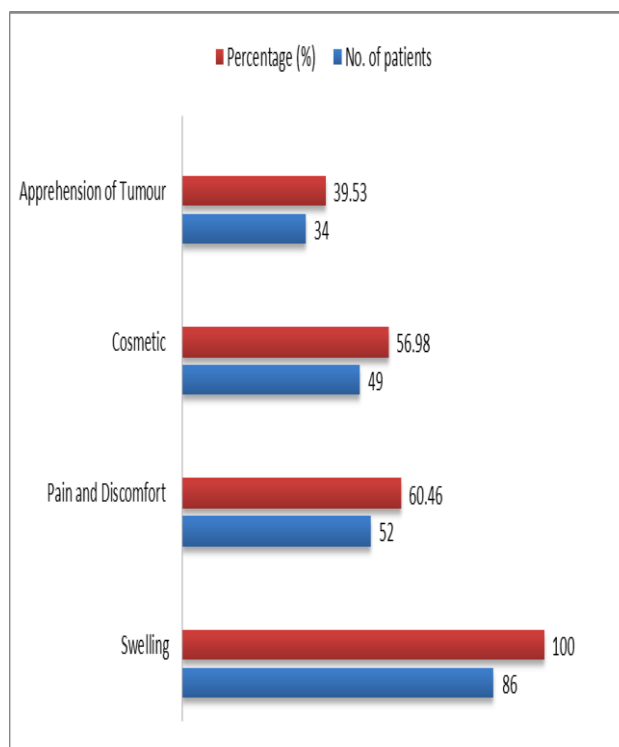
Age mean $\pm$ sd value is 24.8 $\pm$ 7.69 and range 16-48.



Swelling was a common presentation in all the subjects, while allied complaints synchronous with the swelling were pain and discomfort 52(60.46%), cosmetic 49 (56.98%) and apprehension of tumor 34(39.53%).

### Symptoms of the diseases in patients.

S. No.	Symptoms of the diseases	No. of patients	Percentage (%)
1	Swelling	86	100
2	Pain and Discomfort	52	60.46
3	Cosmetic	49	56.98
4	Apprehension of Tumor	34	39.53



Out of 86 patients, 68(79.07%) were treated in group A with success rate of 86.76% and recurrence rate of 13.23%, In group B 18 (20.93%) were treated with

success rate of 83.33% and recurrence rate of 16.66%, as shown in Table.

GROUP	SEX	%	SUCCESS RATE	Recurrence rate
A-Aspiration With Intralesional Triamcinolone Acetonide Injection	MALE-13 FEMALE-55 TOTAL-68	19.12 80.88	59 (86.76%)	9(13.23%)
B- Surgical Excision	MALE-5 FEMALE-13 TOTAL-18	27.78 72.22	15 (83.33%)	3(16.66%)

## DISCUSSION

<sup>[1]</sup> Carpal ganglion cyst is the most common benign soft tissue tumor, approximately 50- 70% of the tumors of the hand and wrist area.<sup>[4]</sup> There are a number of treatment modalities for ganglion such as observation, aspiration, intralesional steroid injection, sclerotherapy and surgical excision, but none of these modalities has been the standard or best treatment.

The mean age at the time of presentation was 24.7 years, our results are comparable with the findings of Singhal R et al<sup>[8]</sup> were mean age of presentation was 25.3 years, as compared to 40.25 years in the study by <sup>9</sup>Paul and Sochart.

Our study involved 86 patients with a male/female ratio of 1/3.78, Similar results are obtained in<sup>[10]</sup> western studies with a ratio of 1/3.1. Other studies from the<sup>[11]</sup> British and<sup>[12]</sup> African population groups report a ratio of 1/1.4 and 1/1.5 respectively.

Recurrence is the most common complication of treatment of ganglions.<sup>[13]</sup> Paramhans et al compared two methods aspiration followed by triamcinolone injection and surgical excision for treatment of wrist ganglions. They found a recurrence rate of 8.4% and 21.5% respectively and their conclusion was that intracystic steroid injection was a safe mode of treatment.<sup>[14]</sup> Humail SM et al reported that the recurrence rate was 43% in aspiration and steroid injection and 24% in surgical excision for treatment of dorsal wrist ganglions. In a report by,<sup>[15]</sup> Gerhard et al conducted a study on 38 wrist ganglions and found that aspiration was a better choice than hyaluronidase injection or surgery. In our study, we found 13.23% recurrence with aspiration followed by steroid injection & 16.66% recurrence was found after surgical excision. The maximum follow-up time was 1 year.<sup>[16]</sup> Janson reported that most of the ganglia recurred in first 6 months period.

## CONCLUSION

Aspiration followed by intralesional steroid (triamcinolone acetate) injection is a better mode of management than surgical excision.

## REFERENCES

1. Memon F, Abbas R, Khan MA, Quraishy, MS.

- Aspiration combined with seton insertion for treatment of wrist ganglions. J Surg Pak, 2007; 3(3): 205-7.
- Afridi SP. Use of setonin ganglions of the wrist. J Surg Pak, 2006 July-Sept; 11(3): 121-3.
- Edward A. Athanasian. Bone and soft tissue tumors in: Scott W Wolf, Robert N Hotchkiss, William C Pederson, Scott H Kozin, Green's Operative Hand Surgery. Vol. 2, Elsevier Churchill Livingstone, 2011; 2150-2156.
- Gude W, Morelli V. Ganglion cysts of the wrist: pathophysiology, clinical picture, and management. Curr Rev Musculoskeletal Med, 2008; 1(3-4): 205-211.
- Rathod CM, Nemade AS, Badole CM. Treatment of dorsal wrist ganglia by transfixation technique. Niger J Clin Pract, 2011; 14: 445-8.
- Memon F, Abbas R, Khan MA, Quraishy MS. Aspiration combined with seton insertion for treatment of wrist ganglions. J Surg Pak, 2007; 3: 121-3.
- Khan PS, Hayat H. Surgical excision versus aspiration combined with intralesional triamcinolone acetate injection plus wrist immobilization therapy in the treatment of dorsal wrist ganglion; a randomized controlled trial. J Hand Microsurg, 2011; 3: 55-7.
- Singhal R, Angmo N, Gupta S, Kumar V, Mehtani A. Ganglion cysts of the wrist : A prospective study of a simple outpatient management.. Acta Orthop. Belg, 2005; 71: 528-534.
- Paul AS, Sochart DH. Improving the results of ganglion aspiration by the use of hyaluronidase. J Hand Surg, 1997; 22-B: 219-221.
- Stephen AB, Lyons AR, Davis TRC. A prospective study of two conservative treatments for ganglion of the wrist. J Hand Surg, 1999; 24-B: 104-105.
- Nield DV, Evans DM. Aspiration of ganglia. J Hand Surg, 1986; 11B: 264.
- Gang RK, Makhoulouf S. Treatment of ganglia by a thread technique. J Hand Surg, 1988; 13-B: 184-186.
- Paramhans D, Nayak D, Mathur RK, Kushwah K. Double dart technique of instillation of triamcinolone in ganglion over the wrist. J Cutan Aesthet Surg, 2010; 3(1): 29-31.
- Humail SM, Amidi AR, Naeem-Ul-Haq S, Mustafa KG. Comparative study of two methods for

- treatment dorsal wrist ganglion. J Pak Orthopaedic Assoc, 2010; 22(1): 53-56.
15. Hajer GF, Scheltinga MRM, Bakker XR, Wijburg ER. Hyaluronidase aspiration vs surgical excision of ganglion cysts: a randomized controlled trial. Eur J Plast Surg, 2005; 28: 337-339.
  16. Janson L, Niechajev IA Wrist ganglion. Scand J Plast Reconstr Surg, 1981; 15: 53-6.