

CAVERNOUS HEMANGIOMA OF SCROTUM: A CASE REPORTDr. S. Berrada*¹, S. Amouzoune¹, A. Aarab¹, M. Oulad sayad², A. Fakhri and H. Rais¹Department of Pathology FMPM-UCA – CHU Mohamed VI 40000 Marrakech Maroc.²Department of Pediatric Surgery FMPM-UCA – CHU Mohamed VI 40000 Marrakech Maroc.***Corresponding Author: Dr. S. Berrada**

Department of Pathology FMPM-UCA – CHU Mohamed VI 40000 Marrakech Maroc.

Article Received on 16/02/2019

Article Revised on 06/03/2019

Article Accepted on 27/03/2019

ABSTRACT

Scrotal hemangioma is a rare benign vascular tumour mostly occurring in child and young adults. We report a case of cavernous hemangioma of the scrotum of an 14-month-old infant who consulted for a scrotal mass that had been present since birth. He was diagnosed with right scrotal tumor based on the physical examination and ultrasound findings. Serum tumour markers including Beta- human chorionic gonadotropin and Alpha- fetoprotein, were normal. The child underwent exision of the tumour in view of a suspicious lesion in the scrotum. On histology, the tumour was diagnosed as cavernous hemangioma. To date, only a small number of cases and retrospective series have been described. We report this observation in view of its rarity and the necessity to know this unusual location, mainly by surgeons and pathologists.

KEYWORDS: Cavernous hemangioma; Scrotal mass, Histology.**INTRODUCTION**

Hemangioma is a benign tumour of vascular origin according to the fourth edition of the WHO classification of tumours of Soft Tissue and Bone, published in 2013.^[1] Hemangiomas are classified based on the predominant vascular channel type: capillary, cavernous, epithelioid, and anastomosing. Cavernous hemangioma constitute a specific subtype of hemangiomas. It is the most common tumour of infancy.^[2] Location in the scrotum is extremely rare and only a few cases have been published in the literature. We report a new case of a cavernous hemangioma of the scrotum of an 14-month-old infant with emphasis on their behavior clinical, histological and immunostaining features, and compare them with literature data. Histologically, hemangiomas are classified based on the predominant.

Vascular channel type: capillary, cavernous, arteriovenous, and venous.^[4,5] Cavernous hemangiomas are found in the skin as well as in the liver, kidneys, breast, brain, bone, and skeletal muscle. It is morphologically characterized by cavern-shaped vascular spaces that are much wider than those of capillary hemangioma and are lined with bland endothelial cells.

CASE REPORT

We report a case of an 14-month-old infant with no specific pathological history. He was born at term without particular abnormalities in antenatal ultrasound

scan. He was consulted for a scrotal mass that had been present since birth, gradually increasing in volume. The initial physical examination revealed the presence of dure and indolore right scrotal mass. This mass was intimately related to right testis and was not associated with a hydrocele. The left testis was normal. Serum tumour markers including Beta- human chorionic gonadotropin and Alpha- fetoprotein, were normal. Ultrasonography with color Doppler flow revealed the presence of a right scrotal mass, measuring 6,14 in size. The mass was well defined, round and hypoechoic with poor blood flow. There were no signs of expansion to the lateral structures, that why we did not ask for further radiological study such MRI. After discussion with the parents, a decision for exision was reached. A histological examination revealed a benign vascular proliferation. Architecturally, it was lobulated and composed of a large number of vascular spaces lined by a monolayer of non atypical endothelial cells and contained numerous red blood cells [Fig A,B].

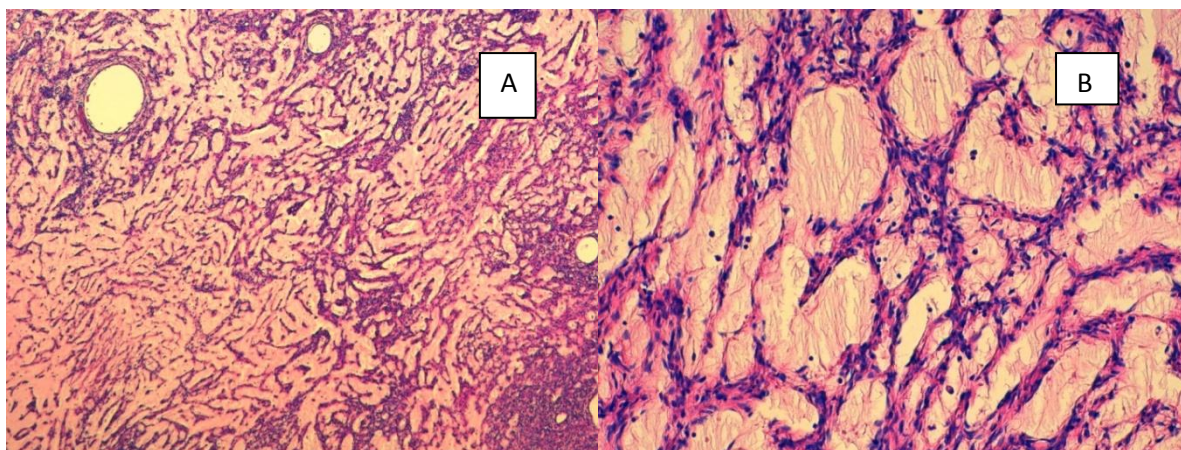


Fig A: Vascular proliferation with large number of vascular spaces x 10.

Fig B: Vascular spaces lined by a monolayer of non atypical endothelial cells x 20.

The vascular spaces were separated by connective tissue septa of varied thickness. Immunohistochemical staining showed a positivity for the vascular markers (CD34,

CD31) [Fig C,D]. Cytokeratin, D2-40 and PS100 were negative.

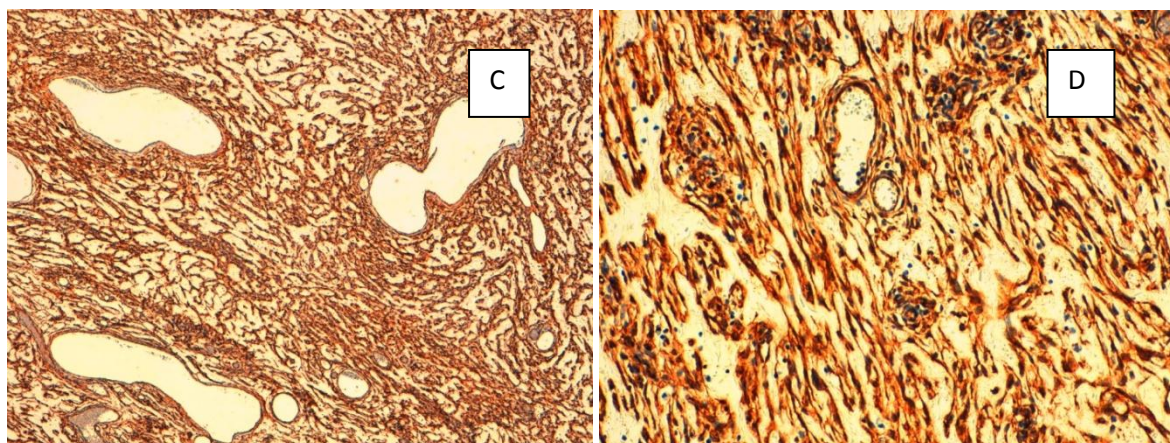


Fig C: Endothelial cells showing proeminent immunostaining for CD34.

Fig D: Endothelial cells showing proeminent immunostaining for CD31.

The nature of tumor was confirmed and the diagnosis of cavernous hemangioma of scrotum was retained. Actually, there was no local recurrence after one year following surgical excision.

DISCUSSION

The International Society for the Study of Vascular Anomalies (ISSVA) classified vascular anomalies into vascular tumours with proliferative endothelium and vascular malformations with structural anomalies. The aim of this classification is to standardized the terminologies and to further the knowledge of pathogenesis, diagnosis and treatment of these vascular lesion. We distinguished several types of hemangiomas among them cavernous hemangioma that usually occur on the skin and mucosal surfaces of the body but it can also found in many other tissues such as the liver, pancreas, spleen, urinary bladder and gastrointestinal tract,^[3] Location in the external genitalia represents 1-3% of all cutaneous hemangiomas.^[4] Cavernous hemangioma of the scrotum is extremely rare and a very

few cases have been reported in the literature. The tumor was first described by Robert in 1851^[5] and since then, many cases and retrospective series have been published. It is mainly seen in child but may appear at any age.^[6] Clinically, these tumours are asymptomatic, but a scrotal mass with local pain can be seen. Generally, the lesion is unilateral and creates discomfort for child and parents due to their location and potential complication including ulceration or hemorrhage. It has been demonstrated that scrotal hemangiomas do not affect potency and fertility.^[7] Doppler ultrasonography is useful for diagnosis that demonstrates the nature of the mass. Hemangiomas in sonographs vary from hypoechoic to hyperechoic, or they may be heterogeneous. The absence of flow on a Doppler study, like our case does not exclude the diagnosis. The presence of a variably sized calcifications is highly suggestive of cavernous hemangioma. Compared with ultrasound, MRI is able to provide more information of use in diagnosis.^[8] Macroscopically, Tumours range from < 1 cm to > 4 cm, and are circumscribed and reddish brown. Occasional

fibrous areas may be present.^[9] Histologically, the tumor consists in large (cavernous) spaces, lined by tumor endothelial cells which appear very similar to normal cells. These interconnected spaces are filled with blood and separated by a fibrous tissue. Necrosis and mitotic activity are absent. Immunohistochemistry demonstrates that the cells lining the vascular channels are positive for endothelial markers (CD31, CD34) and negative for epithelial markers such as cytokeratin and lymphatic markers such as D2-40. Cavernous hemangioma in this location can mimic a varicocele or an inguinal hernia, thus presenting a diagnostic and therapeutic challenge. Once a diagnosis has been suspected, eradication of the lesion should be recommended either by surgery or laser therapy.^[10]

CONCLUSION

In summary, the case described here, confirms that scrotal hemangiomas are rare benign lesions. It is necessary to consider hemangioma in the differential diagnosis of scrotal masses. Positive diagnosis can be established only after histopathological examination. Detailed investigations are necessary to clarify the pathogenesis of tumor development and growth of hemangioma in the scrotum

REFERENCES

1. Pathology and Genetics of Tumours of Soft Tissue and Bone (4th edition). World Health Organization classification of tumours. Edited by CDM Fletcher, JA Bridge, PCW Hogendoorn, F Mertens, IARC Press, Lyon, 2013.
2. Munden, R. Butschek, W. L. Tom et al., "Prospective study of infantile haemangiomas: incidence, clinical characteristics and association with placental anomalies," *British Journal of Dermatology*, 2014; 170(4): 907–913.
3. Ray, B., Grabstald, H., Exelby, P. R., and Whitmore, W. F., JR.: Bladder tumors in children, *Urology*, 2: 426.
4. Gulienetti, R: Haemangiomata of the external genitalia, *Br. J. Plast. Surg.*, 1959; 12: 228.
5. Robert, in Boullay: *Bull. Sot. Anat. de Paris*, 1851; 26: 194.
6. Gibson, T. E.: Hemangioma of scrotum, *Urol. Cutan. Rev.*, 1937; 41: 843.
7. Eastridge RR, Carrion HM, Politano VA Hemangioma of scrotum, perineum and buttocks. *Urology*, 1979; 14: 61±63.
8. Aizenstein RI, Wilbur AC, O'Neil HK, Gerber B MRI of scrotal hemangioma. *J Comput Assist Tomogr*, 1996; 20: 888±889.
9. WHO Classification of Tumours of the Urinary System and Male Genital Organs. Fourth edition. Moch, H., Humphrey, P.A., Ulbright, T.M., Reuter, V.E. Volume 8. IARC WHO Classification of tumours.
10. Sarig, S Kimel, A Orenstein. Laser treatment of venous malformations. *Ann Plast Surg.*, 2006; 57(1): 20–24.