

ASSESSMENT OF RING ENHANCING LESIONS OF BRAIN USING MAGNETIC RESONANCE IMAGING AND MAGNETIC RESONANCE SPECTROSCOPY¹Dr. Sheikh Shahnawaz, ²Dr. Iqbal Hussain Dar*, ³Dr Asif Majid Wani and ⁴Dr. Vineet Wadhwa¹Consultant Department of Radiology GMC Srinagar.²III Year Post-Graduate Department of Radiology GMC Srinagar.³Senior Resident Department of Radiology GMC Srinagar.⁴Consultant Radiologist.***Corresponding Author: Dr. Iqbal Hussain Dar**

III Year Post-Graduate Department of Radiology GMC Srinagar.

Article Received on 01/12/2018

Article Revised on 22/12/2018

Article Accepted on 13/01/2019

ABSTRACT

Background: Most common lesions found in brain on neuroimaging are ring-enhancing lesions. These can be caused by a variety of infectious, neoplastic, inflammatory or vascular diseases. Distinguishing imaging characteristics of non-neoplastic causes from neoplastic lesions is extremely important because a misdiagnosis can lead to unwarranted neurosurgery and exposure to toxic chemotherapy or potentially harmful brain irradiation. Advanced diagnostic techniques, such as Magnetic resonance imaging, diffusion-weighted magnetic resonance imaging (MRI), magnetic resonance spectroscopy, may help in establishing the etiology. The basic intention of this study is to describe the characteristic Magnetic resonance imaging findings in various ring enhancing lesions which will help in their characterization. **Objectives:** To study the characteristic MR imaging and MR spectroscopic findings of various ring enhancing lesions and their differential diagnosis on MRI brain. **Methods:** 40 patients (males=22; females=18) were evaluated in this study conducted at Govt medical college (GMC SRINAGAR), from JULY to DEC 2018 over a period of 6 months. MRI along with MRS was performed using 3T siemens Magnetom skyra in patients ranging from ages of 10-70 years. **Results:** 40 patients were evaluated out of those 18 cases were tuberculomas, 10 abscesses, 6 metastasis, 4 cases of primary brain tumor 1 case of NCC and 1 case of demyelinating lesions. Seizures are the commonest presenting complaint seen in 25 cases. **Interpretation & Conclusion:** On the basis of this study we conclude that Magnetic resonance imaging coupled with Magnetic resonance spectroscopy provides the fairly accurate diagnosis in differentiating various ring enhancing lesions of brain and helps to narrow the long list of differential diagnosis of ring enhancing lesions in brain.

KEYWORDS: Neuroimaging, Magnetom skyra, tuberculomas.**INTRODUCTION**

Ring enhancing lesions are one of the most common neuroimaging abnormalities encountered by the radiologists. Various imaging modalities, like computed tomography (CT) and magnetic resonance imaging (MRI) are used to detect these lesions. A variety of infective and noninfective processes display a pattern of ring enhancement on neuroimaging, which often prohibits a reliable diagnosis and their clinical correlation is essential. In developing countries often it is not possible to perform brain biopsies because of limited neurosurgical and neuropathological facilities. Diseases causing multiple ring-enhancing lesions of the brain are infectious, neoplastic, inflammatory or vascular in origin. Several types of primary and secondary brain neoplasms, such as glioblastomas, low-grade gliomas, lymphomas and brain metastases can also present as multiple ring-enhancing lesions. Many non-neoplastic neurological disorders can mimic brain neoplasms on neuroimaging.

These diseases include tuberculosis, cysticercosis, demyelinating disorders, pyogenic abscess, toxoplasmosis, fungal infections, neurosyphilis, sarcoidosis, Behcet disease, radiation encephalopathy, cerebral venous thrombosis and several other vasculitic disorders. A variety of free-living amebas *Naegleria*, *Balamuthia mandrillaris* and *Acanthamoeba* are unusual causes of central nervous system (CNS) infections presenting as multiple ring-enhancing lesions of the brain. All these parasites are known to produce multiple ring-enhancing lesions of the brain. MR spectroscopy is a potential tool for differential diagnosis between brain abscesses and non-infectious lesions such as primary brain tumor, lymphoma, brain metastasis and tuberculoma. Proton MRS obtains information about brain tissue metabolism, which cannot be performed by conventional MRI scans^[1] (MRS) provides information about the possible extent and nature of changes on a routine MRI scan by analyzing the presence and/or ratio

of tissue metabolites such as NAA, creatine, choline, and lactate etc.

Tuberculoma

CNS tuberculosis may take a variety of forms, including tubercular meningitis, abscess, focal cerebritis and tuberculoma. Tuberculomas may be single or multiple, and can be seen anywhere in the brain parenchyma. The number of identified lesions per patient may range from one to 12 (or more), with the size varying from 1 mm to 8 cm. Depending on its stage of maturation, a tuberculoma's appearance varies on MRI, i.e., whether noncaseating, caseating with a solid center, or caseating with a liquid center.^[2,3] A noncaseating tuberculoma usually appears hyperintense on T2W and slightly hypointense on T1W images.^[2] Quantitative MT imaging and in vivo proton MRS may help in the differential diagnosis of tuberculomas. In vivo spectroscopy shows only lipid in T2 hypointense tuberculomas, whereas lesions with a heterogeneous appearance show Cho at 3.22 ppm along with lipid. These lesions show a large amount of cellularity and minimal solid caseation, the cellular regions appearing brighter on MT imaging and showing Cho resonance on spectroscopy.^[4]

Metastatic Disease

80% to 85% of metastases are located in the supratentorial compartment. These lesions may be the direct result of microscopic foci of neoplastic cells transported into the brain via the hematogenous route with subsequent growth in situ, or the metastatic deposit may be primarily to the surrounding secondarily. Calvarium or dural membranes and impinge on the brain. Intraparenchymal metastases are the most common type of metastatic disease to affect the intracranial space. Most common, in decreasing incidence, are lung cancer, breast cancer, melanoma, gastrointestinal cancers, renal cell carcinoma, and tumors of unknown primary.^[5]

Primary Brain Tumour

There is long list of primary brain tumours but among the primary brain tumours commonly presenting as ring/peripheral contrast enhancement are Glioblastoma also known as glioblastoma multiforme in adults and pilocytic astrocytoma among children.

Demyelinating Disorders

Multiple enhancing ring lesions are encountered in several acute demyelinating disorders. Enhancing demyelinating lesions differ in size, shape or pattern. Most of them demonstrate a nodular pattern. Some of them demonstrate a ring-enhancing pattern and few have other patterns. Demyelinating lesions, including both classic multiple sclerosis and tumefactive demyelination, may also create an open ring or incomplete ring sign. Patients with atypical ring-enhancing lesions and mass effect usually undergo brain biopsy to establish the diagnosis. Otherwise, biopsy of these lesions is not indicated because conservative medical treatment with

corticosteroids results in a favourable outcome in most of the cases.^[6,7]

Abscess

A brain abscess, also known as a cerebral abscess or CNS abscess, is an abscess within the brain tissue caused by inflammation and collection of immune cells and infected material originating from local or remote infection sources. Abscesses tend to demonstrate high signal intensity on DWI, with a corresponding reduction in the apparent diffusion coefficient values.^[8,9] This is directly related to the cellularity and viscosity of the pus contained within an abscess cavity.^[8]

2. MATERIAL AND METHODS

- 1) **Study Design:** Prospective, Observational study.
- 2) **Study Location:** Govt medical college Srinagar Kashmir.
- 3) **Study Population:** The study was conducted on patients with clinical suspicion of ring enhancing lesions who were referred to the department of Radiodiagnosis govt medical college Srinagar Kashmir.
- 4) **Sample Size:** A sample of 40 patients was selected for the undergoing study who were meeting the inclusion criteria.
- 5) **Study Period:** July 2018 to dec 2018.
- 6) **Study Definitions**
 - **Ring enhancing lesion:** Lesions showing peripheral contrast enhancement in a ring like manner and no enhancement in center.
 - **Hypointense:** Lesion appears less brighter on MRI than surrounding tissues.
 - **Hyperintense:** Lesion appear more brighter than surrounding tissues.
 - **Isointense:** Lesion appear in similar brightness as of its surroundings.
 - **Mass effect:** Compression of surrounding structures like ventricles, CSF spaces etc.

Inclusion Criteria

The study includes

- A. All Patients with suspicion of cerebral ring enhancing lesions like tuberculoma, metastasis, brain abscess etc.
- B. All patients with incidentally detected ring enhancing lesions on MRI brain.
- C. All patients with ring enhancing lesion detected by CT.
- D. Patients of all ages including children and adults and both genders.

Exclusion Criteria

The study will exclude

- 1) Patients with non ring enhancing lesions of brain.
- 2) Patient having history of claustrophobia.
- 3) Patient having history of metallic implants insertion, cardiac pacemakers and metallic foreign body insitu.

- 4) Patents with contrast allergy and medical renal disease.
- 5) Unwillingness of persons to participate in this study or give informed consent.

Study Protocol

1). Screening of patients and inclusion in this study

All patients referred to the Department of Radiology, Govt medical college Srinagar were screened by the primary investigator of the study. Those patients meeting the study inclusion criteria were eligible for inclusion in this study. Each eligible patient was then informed by the primary investigator of this study, and explained the reason and purpose of the study and informed consent was obtained.

The study proforma was completed for each included patient including basic demographic information such as age, sex and symptom history.

Each patient was then proceed for MR imaging as follows:

2). Study MR Imaging Procedure

MRI examinations was done on siemens Magnetom skyra 3T machine using phase array brain coil at Gmc Srinagar jammu and kashmir.

Sequences

Conventional spin echo sequences, axial T1, T2 and FLAIR: Coronal T2; Sagittal T1; Post contrast axial, coronal and sagittal; DWI; T2 GRE MR spectroscopy was performed at TE of 144. The voxel is placed on the lesion so that it covers the maximum area of the lesion in a single voxel. We used PRESS and T1 post contrast sequence as localization sequence with 5 mm thickness. Post contrast T1W spin echo imaging was done using gadolinium DTPA contrast in every positive case.

RESULTS

In our study of 40 patients 22 (55%) were males and 18(45%) were females. Our study include patients between 10 to 70years of age. The highest incidence was found in 30-40 years of age group accounting for 30% of cases and least was seen in age group of 60-70 years constituting 5% as shown in table 1. Out of the 40 patients who were evaluated, tuberculomas (40%) is the most common pathology followed by abscesses (25 %), metastasis (15%), primary brain tumor (10%), demyelinating lesions (2.5%) and NCC (2.5%) as defined in table 2. Among the 40 patients with RELs noted 10 (25%) were noted on the Right side, 10 (25%) were noted on the left side, 17 (42.5%) were seen

bilaterally and 3(7.5%) in the midline. 10 (25%) out of 40 patients presented with a single lesion, 22 (55%) patients presented with 2-4 lesions and > 4 ring enhancing lesions (REL) were seen in 8 (20%) of cases. Out of the 40 patients, Choline peak was observed in 24 cases, Lipid in 22 cases, Lactate in 20 cases, reduced NAA peak in 18 cases and amino acids in 5cases (Table 4). Majority of lesions were associated with irregular contrast enhancement (62.5%) and smooth enhancement was seen in (30%). Only 7.5% cases shows solid component.(Table 5).

Table 1: Age wise distribution.

Age in years	No cases	%
10-20	5	12.5%
20-30	8	20%
30-40	12	30%
40-50	10	25%
50-60	3	7.5%
60-70	2	5%
Total	40	100

Table 2: Incidence of ring enhancing lesions according to etiology.

Lesions	No. of cases	Percentage (%)
Tubercloma	18	40(%)
Neurocysticercosis	1	2.5(%)
Metastasis	6	15(%)
Abscesses	10	25(%)
Primary brain tumor	4	10(%)
Demyelinating lesions	1	2.5(%)
Total	40	100(%)

Table 3: Male – Female incidence of Ring enhancing lesions.

Pathology	Male	Female	Total
Tubercloma	12(66.6%)	6(33.33%)	18
NCC	1(100%)	0	1
Metastasis	4(66.66%)	2(33.33%)	6
Abscess	5(50%)	5(50%)	10
Primary brain tumour	3(75%)	1(25%)	4
Demyelinating lesions	1(100%)	0	1

Table 4: List of various metabolite peaks noted in ring enhancing lesions.

Metabolite Peak	No. of cases	Percentage (%)
Choline	24	60(%)
Lactate	20	50(%)
Lipid	22	55(%)
Reduced NAA	18	45(%)
Amino acids	5	12.5(%)

Table 5: Type of ring enhancement.

Type of ring enhancement	No. of cases	Percentage (%)
Smooth	12	30(%)

Irregular	25	62.5(%)
Associated with solid components	3	7.5(%)
	40	100(%)

Table 6: Degree of mass effect.

Type of mass effect	No of lesions	Percentage (%)
Mild	25	62.5(%)
Moderate	11	27.5(%)
Severe	4	10(%)
Total	40	100(%)

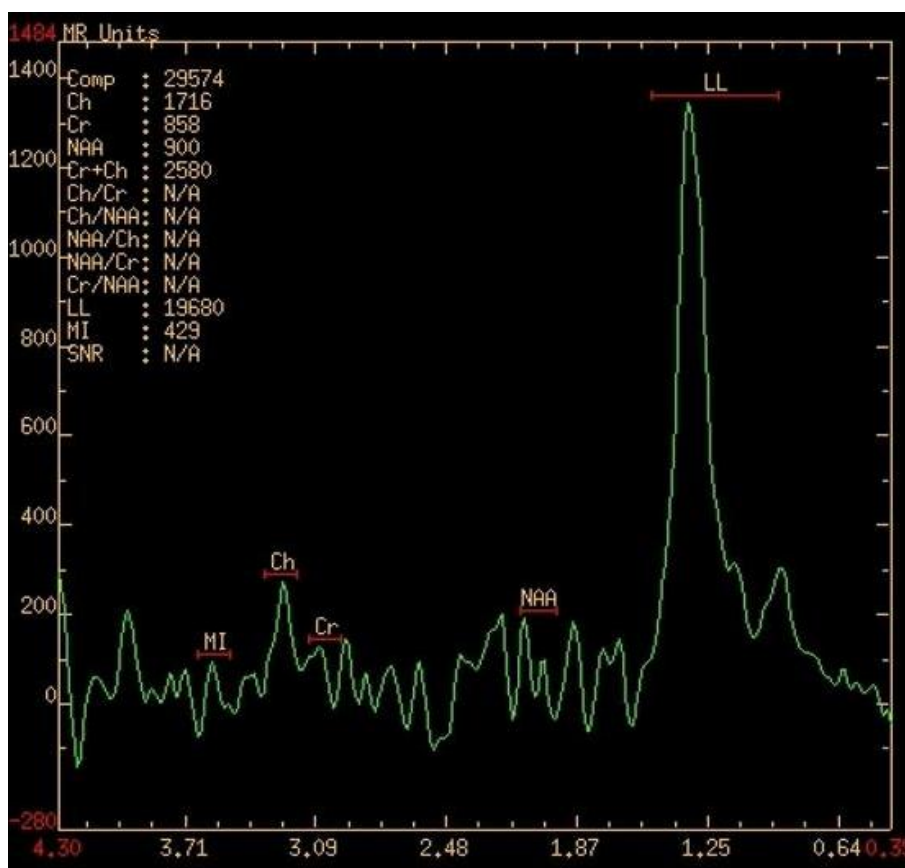
Mild: mass effect which efface regional sulci.

Moderate: which efface ipsilateral ventricle.

Severe: which is associated with midline shift.

Table 7: MRS Findings of individual lesions.

Pathology	No. of cases	Choline	Lactate	Lipid	Reduced NAA	Amino Acids
Tubercloma	18	12	10	14	8	2
NCC	1	1	1	1	0	1
Metastasis	6	6	2	0	6	0
Abscess	10	0	10	2	6	3
Brain Tumour	4	4	0	0	4	0
Demylinating Disease	1	1	0	0	1	0

**Fig 1: MRS showing lactate peak in abscess.****DISCUSSION**

Magnetic resonance imaging is a noninvasive, multi planar and fairly accurate method with better inherent contrast that demonstrates the lesion accurately. MRI provides an accurate assessment of the brain changes in

various ring enhancing lesions, for accurate diagnosis and introduction of immediate treatment. This is a prospective, observation study done in the Department of Radiology in Govt medical college Srinagar Kashmir

aimed at studying the MR appearances in various ring enhancing lesions of the brain.

Tuberculoma

Out of 40 patients evaluated tuberculomas were seen in 18 (45%) of cases. Among the 18 cases (males = 12; females = 6). Single lesions were noted in 5 cases (27.77%) and multiple in 13 cases (72.22 %). They are seen as conglomerate lesions which are hypointense on both T1 and T2. On T1 weighted images they show iso to hyperintense ring which was seen in 12 cases in our study. The lesions may show a nodular or irregular ring like enhancement. All our cases presented ring like enhancement.

MRS showed a Lipid peak in 14 (77.7%) cases and it plays an important role in identification of tuberculomas from other infective granulomas. The stage of the tuberculoma whether it is caseous or non caseous can also be identified on MRI with the help of T2 weighted images. Tae Kyoung Kim, Kee Hyun Chang, Chong Jai Kim, Jin Mo Goo, Myeong Cheri Kook, and Moon Hee Han (1995) showed that on T1-weighted images, the granulomas showed a slightly hyperintense rim. On T2-weighted images, the entire portion of the granuloma showed slightly heterogeneous isointensity or hypointensity with small markedly hypointense foci. On post contrast T1-weighted images, there were single or multiple conglomerate ring enhancements within a tuberculoma in all six patients.^[10] Jayasundar R, Singh VP, Raghunathan P, Jain K, Banerji AK (1999). concluded that presence of lipid can be used for differentiating tuberculomas from both non-specific IG and NCC.^[11]

Abscess

Out of the 40 patients, abscess were found in 10 cases 25 % (males=5; females =5). Single abscess was found in 6 cases (60%) whereas the other 4 cases(40%) had multiple abscesses. All were hypointense on T1 weighted images with a hyperintense rim noted in 6 patients and were hyperintense on T2 weighted images with a surrounding hypointense rim (4 cases). They showed complete diffusion restriction and MRS showed Lactate peak in all 10 cases suggesting anaerobic glycolysis with amino acids like glutamine seen in 3 cases. Halmes et al described the appearance of abscesses on MR. We correlated our findings with those described and distinguished the peripheral oedema, central necrosis and the characteristic pattern of peripheral enhancement of the abscess capsule.^[12] Our findings were similar to the study conducted by, Shukla-Dave A et al^[13] and Leuthardt EC et al.^[14] Halmes et al described the appearance of abscesses on MR. We correlated our findings with those described and distinguished the peripheral oedema, central necrosis and the characteristic pattern of peripheral enhancement of the abscess capsule.^[12]

Metastasis

Out of the 40 patients, 6 cases were metastasis (males = 4; females =2). Multiple lesions were identified in 5 cases and 1 showing solitary lesion. All the cases showed high Cho / Cr and Cho / NAA levels. All 6 cases were hyperintense on T2 with 2 cases showing inversion on FLAIR suggestive of cystic metastasis. Primary was identified in four cases in breast, lung and prostate and ovary. Thick, irregular type of ring enhancement was noted after contrast administration. Our findings were similar to the study conducted by Vieth RG et al.^[15]

Primary Brain Tumours

Out of 40 patients, 4 cases were primary brain tumors (males= 3 and females= 1). Among primary brain tumors 3 cases were Glioblastoma multiforme (GBM) and 1 was pilocytic astrocytoma. The type of enhancement was irregular and nodular in GBM and pilocytic astrocytoma shows associated mural nodule (solid component). In all the 4 cases lesions were surrounded by vasogenic perilesional oedema and GBMs were associated with severe mass effect (midline shift). Internal haemorrhagic and necrotic changes were seen in all 3 cases of the GBMs. These tumors were hypo to isointense on T1 and hyperintense on T2 /FLAIR. On MRS GBM shows increased choline, and decreased NAA. MR spectroscopic study in pilocytic astrocytoma showed the high Cho/NAA and Cho/Cr ratios, relative low concentration of creatine with increased NAA/Cr ratio (2.32 ± 1.1). Lactate doublet was detected. On diffusion imaging none of the tumor shows diffusion restriction.

CONCLUSION

MRI along with MRS has been the most sensitive modality in the characterization of intracranial ring enhancing lesions. MRI being non invasive and non-radiating is an ideal imaging modality. Multiplanar capability of MRI was helpful in identifying precise anatomical location and the exact extent of lesions. Based on the various metabolites MRS is useful in differentiating and characterizing various ring enhancement lesions.

REFERENCES

1. Wilson, M., Davies, NP., Grundy, RG., & Peet, AC., A quantitative comparison of metabolite signals as detected by in vivo MRS with ex vivo ¹H HR-MAS for childhood brain tumors, NMR Biomed, 2009; 22(2): 213-9, ISSN 0952-3480.
2. Gupta RK, Husain N, Kathuria MK, Datta S, Rathore RK, Husain M. Magnetization transfer MR imaging correlation with histopathology in intracranial tuberculomas. Clin Radiol, 2001; 56: 656-63.
3. Gupta RK, Lufkin RB. In Tuberculosis and other non-tuberculous bacterial granulomatous infection. New York: Kluwer Academic/Plenum Publishers.

- MR imaging and spectroscopy of central nervous system infection, 2001; 95–145.
4. Poptani H, Gupta RK, Roy R, Pandey R, Jain VK, Chhabra DK. Characterization of intracranial mass lesions with in vivo proton MR spectroscopy. *AJNR Am J Neuroradiol*, 1995; 16: 1593–603.
 5. Potts DG, Abbott GF, von Sneidern JV. National Cancer Institute study: evaluation of computed tomography in the diagnosis of intracranial neoplasms. III. Metastatic tumors. *Radiology*, 1980; 136: 657–664.
 6. Maarouf M, Kuchta J, Miletic H, Ebel H, Hesselmann V, Hilker R, et al. Acute demyelination: diagnostic difficulties and the need for brain biopsy. *Acta Neurochir (Wien)*, 2003; 145: 961-69.
 7. Masdeu JC, Quinto C, Olivera C, Tenner M, Leslie D, Visintainer P. Open-ring sign: highly specific for atypical brain demyelination. *Neurology*, 2000; 54: 1427-33.
 8. Desprechins B, Stadnik T, Koerts G, et al. Use of diffusion-weighted MR imaging in differential diagnosis between intracranial necrotic tumors and cerebral abscesses. *AJNR Am J Neuroradiol*, 1999; 20: 1252-1257.
 9. Kim YJ, Chang KH, Song IC, et al. Brain abscess and necrotic or cystic brain tumor: discrimination with signal intensity on diffusion-weighted MR imaging. *AJR Am J Roentgenol*, 1998; 171: 1487–1490.
 10. Tae Kyoung Kim et al Intracranial Tuberculoma: Comparison of MR with Pathologic Findings *AJNR*, 16: 1903–1908.
 11. Jayasundar R, Singh VP, Raghunathan P, Jain K, Banerji AK Inflammatory granulomas: evaluation with proton MRS *NMR Biomed*, 1999 May; 12(3): 139-44.
 12. Halmes AB, Zimmerman RD, Morgello S, Weingarten K, Becker RD, Jennis R, Deck MD. MR Imaging of brain abscesses. *AJR*, 1989; 152(5): 1073-85.
 13. Shukla-Dave A, Gupta RK, Roy R, Husain N, Paul L, Venkatesh SK, Rashid MR, Chhabra DK, Husain M Prospective evaluation of in vivo proton MR spectroscopy in differentiation of similar appearing intracranial cystic lesions. *Magn Reson Imaging*, 2001 Jan; 19(1): 103-10.
 14. Leuthardt EC, Wippold FJ 2nd, Oswood MC, Rich KM. Diffusionweighted MR imaging in the preoperative assessment of brain abscesses. *Surg Neurol*, 2002 Dec; 58(6): 395-402.
 15. Vieth RG, Odom GL. Intracranial metastases and their neurosurgical treatment. *J Neurosurg*, 1965; 23: 375–383.