

## ANKLE FLEXURE LICHENIFICATION IN THIRTEEN PATIENTS

\*Dr. Abdullah Mancy and Khalid M. Awad

FICMS(D&amp;V), Specialist Supervisor in Dermatology and Venereology, Al-Ramadi Teaching Hospital, Ramadi, Iraq.

\*Corresponding Author: Dr. Abdullah Mancy

FICMS(D&amp;V), Specialist Supervisor in Dermatology and Venereology, Al-Ramadi Teaching Hospital, Ramadi, Iraq.

Article Received on 30/09/2018

Article Revised on 21/10/2018

Article Accepted on 11/11/2018

## ABSTRACT

Lichenification is characterized clinically by thickening of areas of skin in association with exaggerated normal skin markings and hyperpigmentation, it may originates on seemingly normal skin or may develops at the site of another cutaneous disease, such as atopic or allergic contact dermatitis, or as a result of chronic pruritus of systemic diseases as renal insufficiency, hypothyroidism and hyperthyroidism, liver failure and underlying malignancy. Thickening of certain areas of the skin sometimes not associated with the presence of skin or systemic diseases but may be related to a prolonged minimal trauma or pressure subjected to those areas leading to a changing in their texture and color.

**KEYWORDS:** Hyperpigmentation, Ankle joint, Lichenification.

## INTRODUCTION

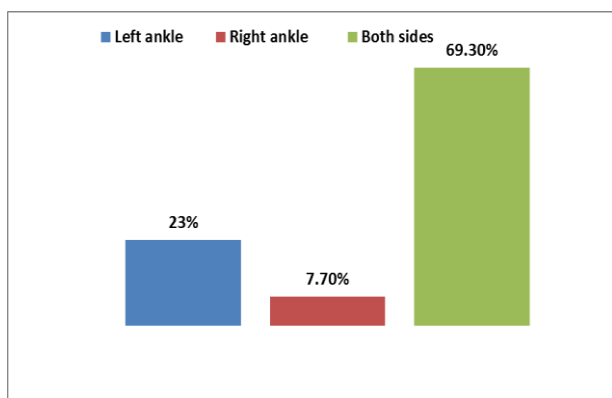
Long-term chronic rubbing and scratching of the skin will result in a thickened and leathery texture in association with exaggerated normal skin markings, This known as lichenification, it may originates on seemingly normal skin or may develops on skin that is the site of another disease, such as atopic or allergic contact dermatitis or ringworm infection.<sup>[1]</sup> The lichenified plaque may become hyperpigmented or hypopigmented with chronicity, usually only one plaque is present, however more than one site and any part of the body may be involved such as the back and sides of the neck, the wrist and ankle flexure.<sup>[2]</sup> Lichenification is usually coexist with atopic dermatitis, adult-onset atopic dermatitis usually manifested as inflammatory eczema with lichenification of the flexures, also may presents with non-typical morphology and localization,<sup>[3]</sup> but in non-atopic patients, chronic pruritus in association with systemic diseases like renal insufficiency, hypothyroidism and hyperthyroidism, liver failure, hepatitis B and C, HIV disease, parasitic infestation and underlying malignancy may lead to thickening of the skin also.<sup>[1,4]</sup>

Environmental factors have been implicated in inducing itching such as heat, sweat, friction and abrasion, low ambient humidity and cold temperature decrease the water content of the stratum corneum making it more permeable to irritant.<sup>[2]</sup> Irritation from clothing as in textile contact dermatitis, presents as erythematous patches usually at the sites where the garments fit tightly to the skin, such as inner and posterior thighs and popliteal fossae, textile dermatitis can also assumes other

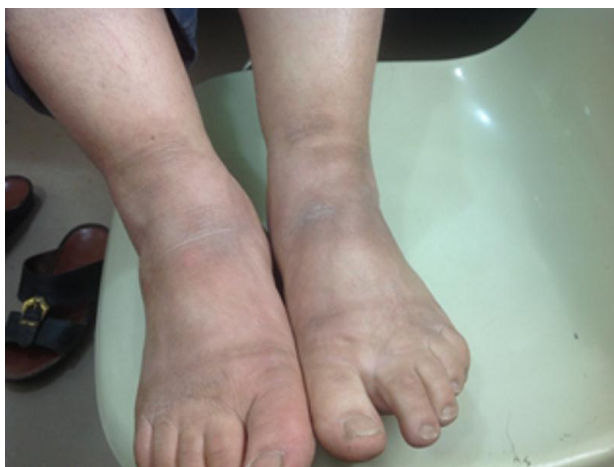clinical appearances that are atypical as in pigmented contact dermatitis which has been related to hypersensitivity to disperse dyes and to an azo dye coupling component agents, it presents with spotted hyperpigmentation on the exposed areas but without pruritus, this hyperpigmentation is most pronounced in individuals with dark complexions.<sup>[5]</sup> Presence of emotional or psychological disturbances such as in anxiety, depression or obsessive-compulsive disorders may play key role in inducing a pruritic sensation leading to chronic itching and subsequent lichenification as in lichen simplex chronicus and neurodermatitis.<sup>[6]</sup>

## CASE REPORT

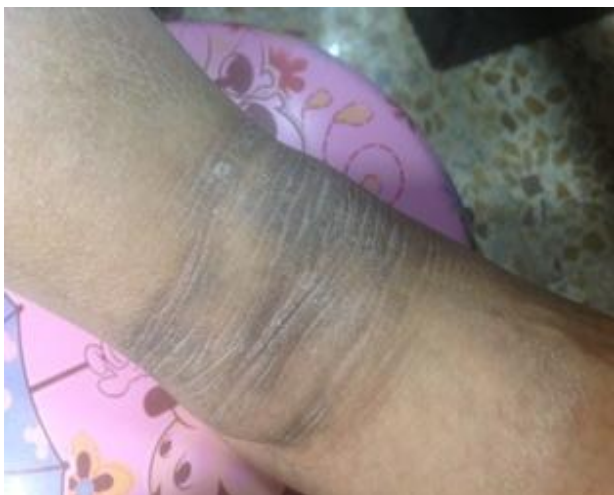Thirteen patients, four females and nine males presented with lichenification of the anterior surface of ankle region were studied in Al-Ramadi Teaching Hospital after obtaining a clearance from the institutional ethics committee and an informed consent was taken from all patients, their ages ranged from 9 years to 76 years with mean age of 57 years and male to female ratio around 2.25 :1. The anterior surface of the left ankle region affected in 23%, the right ankle in 7.7% while both side affected in 69.3%. "Fig. 1" and "Fig. 2 (A, B&C)"



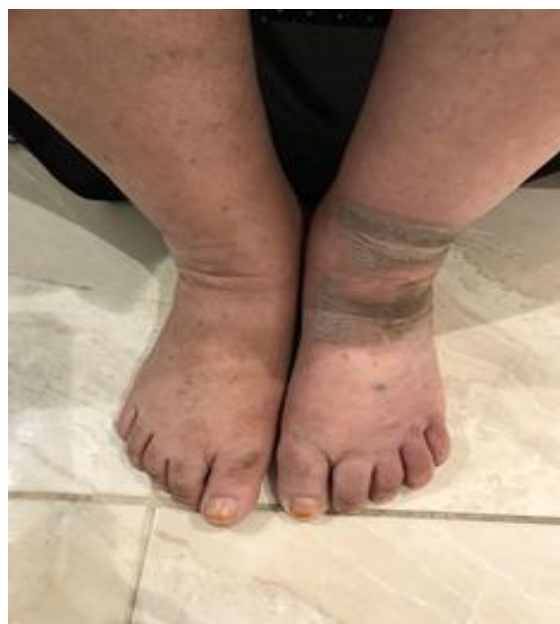**Figure 1: Lichenification of the anterior surface of ankle region.**



[A]



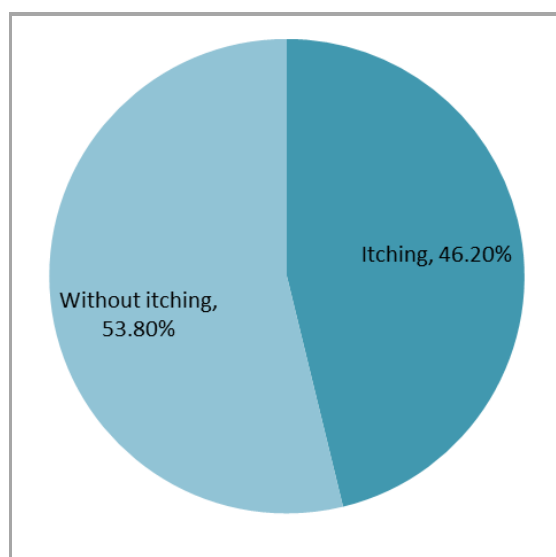
[B]



[C]

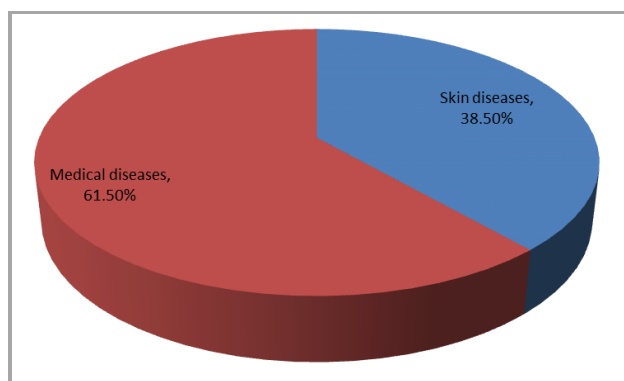
**Figure 2 [A, B & C]: Bilateral lichenification of the anterior surfaces of ankle regions in patient [A] while unilateral involvement of the patients [B & C].**

Regarding complaints of the patients were itching, found in 46. 2%, those without itching and for cosmetic appearance only in 53. 8%. "Fig. 3"



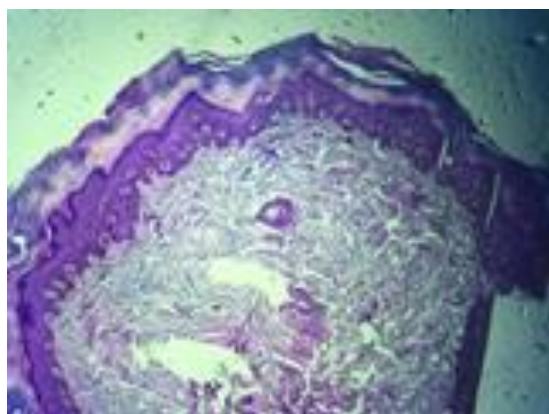
**Figure 3: The main complaints of the patients presented with lichenification of the anterior surface of the ankle region.**

Associated skin diseases present in 38. 5% which include xanthasma, vitiligo, atopic dermatitis and xerosis, while associated medical diseases account 61. 5%, these include obesity, hypertension, diabetes mellitus hepatitis B virus positive, renal disease and stone, Hodgkin's lymphoma. "Fig. 4"

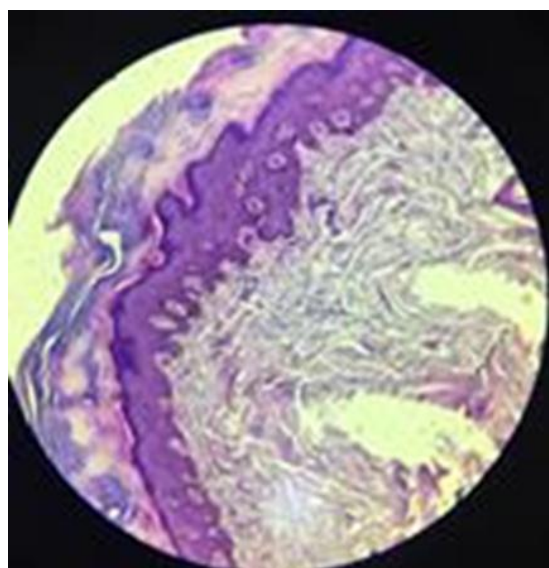


**Figure 4: Associated cutaneous and medical diseases in patients presenting with anterior surface of ankle lichenification.**

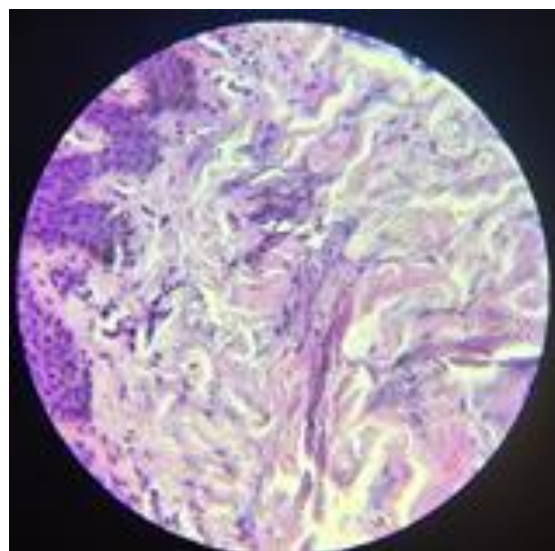
Histopathological examination of lichenified lesions was done and reveals hyperkeratosis with preservation of the stratum granulosum, irregular acanthosis, increased pigmentation of the basal layer and dermal fibrosis. "Fig. 5"



**(A)**



**(B)**



**(C)**

**Figure 5: Histological examination of a skin of patient with anterior surface of ankle lichenification, with Hematoxylin and Eosin stain(A X4), (BX20) and (C X40).**

There is no seasonal variation apart from one patient in whom the condition aggravated during winter months and no family history of the same complaint, medications were taken for associated medical diseases.

## DISCUSSION

The hallmarks of dry skin(xerosis) are scaliness and loss of elasticity, decreased hydration and a disturbed lipid contents of the stratum corneum are also well-known factor, the frequency of dry skin increases with age,<sup>[7]</sup> xerotic skin can induces itching and with chronicity, rubbing and scratching can lead to lichenification, as 46. 2% of the patients complain of itching which may be due to dry skin as an aging process or could be an adult-onset atopic dermatitis which is a common, chronic, relapsing, severely pruritic eczematous skin disease and can presents with non-typical morphology and localization.<sup>[3,8]</sup>

Males are more affected because they are more intended with outdoor work than females, so more exposure to environmental factors. Friction from wearing garments that fit tightly at the ankle joint region, these garments especially designed to be wear in this locality may play a role in initiation of the lesion or could induce a textile dermatitis at that site. In most patients bilateral lichenification of the anterior surface of ankle joint was the usual presentation, occasional unilateral affection is present, this may be related to the sitting position during praying in Islamic religion, so in 23% of patients, the left side was used to sitting on while the right side in 7. 7 % and both side alternatively used in 69. 3% of patients.

The morphological diagnosis of lichenification is not usually difficult, lichen planus, lichen amyloidosis and psoriasis have to be excluded, and typical lesions should

be sought in other sites, also secondary lichenification complicates persistent skin lesions such as venous insufficiency on lower leg and some chronic infection with *Trichophyton rubrum*.<sup>[9]</sup>

Histologically, the hallmark of all eczematous eruptions is spongiosis with an underlying dermal perivascular lymphoid infiltrate and exocytosis, this is very prominent in the acute stage, subacute stage demonstrates epidermal spongiosis with acanthosis and hyperkeratosis while chronic lesions may have minimal accompanying spongiosis in addition to compact hyperkeratosis, irregular acanthosis, and thickening of the collagen bundles in the papillary dermis, the dermal infiltrate at all stages is predominantly lymphoid.<sup>[10]</sup>

In mechanically induced keratoses, such as corns and calluses, they exhibit changes within the epidermis, dermis, and adipose layer, corns demonstrate a parakeratotic plug within the stratum corneum, with a pressure-related loss of the stratum granulosum as well as atrophy of the stratum malpighii, the dermis displays significant fibrosis, dilated eccrine ducts and blood vessels, hypertrophied nerves, and scar tissue replacement of subcutaneous fat, Overall, the histologic changes in calluses are less pronounced, and include a thickened stratum corneum but intact stratum granulosum.<sup>[11]</sup> So most of the patients who presented with lichenification, histopathologically they resemble mechanically- induced keratosis and thickening of the skin secondary to minimal but frequent trauma over long period of time, also there are many associated skin and medical diseases in the patients but it is uncertain whether these diseases are actively involved in the disease pathogenesis or merely coincidental bystanders.

## CONCLUSION

In conclusion, thickening of the anterior surface of the ankle joint was mainly due to pressure –induced trauma to that site and it could be considered as prayer mark for that religion.

## REFERENCES

1. James WD, Berger TG and Elstone DM. Pruritus and neurocutaneous dermatoses in: Andrews diseases of the skin: Clinical dermatology. 12th ed. Philadelphia, WB Saunders Company, 2016; 57-75.
2. Suzan B. Nummular eczema, lichen simplex chronicus, and prurigo nodularis. In: Fitzpatrick Dermatology in General Medicine 8th ed. New-York. Mcgraw-Hil, 2012; 182-87.
3. Thapa DM and Malathi M. Is there something called adult atopic dermatitis in India? IJDVL, 2013; 97(2): 145-47.
4. Arseculeratne G, Altman P, Millard PR, Todd P and Wonjnarowska F. Giant lichenification of the scalp. Clinical and Exp Dermatol, 2003; 28(3): 257-9.
5. Aneta L, Mario C, Natalia P and David A. Atypical and unusual clinical manifestations of contact dermatitis to clothing (textile contact dermatitis) - case presentation and review of the literature. Dermatol Online J, 2003; 9(3): 1.
6. Liao YH, Lin CC, Tsai PP, Shen WC and Kao CH. Increased risk of lichen simplex chronicus in people with anxiety disorder: a nationwide population-based ratiospectrum cohort study. Br J Dermatol, 2014; 170(4): 890 [Medline].
7. Engeke M, Jensen J-M, Ekanayake-Mudiyanselage S and Proksch E. Effect of xerosis and ageing on epidermal proliferation and deferenciation. Br J Dermatol, 2003; 137(2).
8. Takeshi N, Tetsuya K, Shuji F, Hiroshi U, Masutaka F. Intermittent topical corticosteroid/tacrolimus sequential therapy improves lichenification and chronic papules more efficiently than intermittent topical corticosteroid/ emollient sequential therapy in patients with atopic dermatitis. J Dermatol, 2004 Jul; 31(7): 524-8.
9. Irvine AD and Mellerio JE. Genetics and Genodermatoses. In: Rook's Textbook of Dermatology, 8th ed., London, Blackwell Science, 2010; 1: 445-543.
10. James WD, Berger TG and Elstone DM. Atopic dermatitis, eczema, and noninfectious immunodeficiency disorders in: Andrews Diseases of the Skin: Clinical Dermatology. 12th ed. Philadelphia, WB Saunders Company, 2016; 76-106.
11. DeLauro TM and DeLauro NM. Corns and calluses. In: Fitzpatrick Dermatology in General Medicine 8th ed. New-York. Mcgraw-Hil, 2012; 1111-15.