

**CARCINOSARCOMA OF THE LARYNX: A RARE SITE ENTITY**

**\*Dr. Sfaoua H., Allam A., Aarab J., Moukasse Y., Lahlali F. Z., Elmajjaoui S., Kebdani T., Elkacemi H., Benjaafar N.**

Department of Radiotherapy-Oncology, National Institute of Oncology, University Mohammed 5 Rabat.

**\*Corresponding Author: Dr. Sfaoua H.**

Department of Radiotherapy-Oncology, National Institute of Oncology, University Mohammed 5 Rabat.

Article Received on 22/05/2018

Article Revised on 12/06/2018

Article Accepted on 03/07/2018

**ABSTRACT**

**Introduction:** Carcinosarcoma of the larynx has been occasionally described in the literature, it represents less than 1% of all malignant laryngeal tumors. True carcinosarcoma is defined by mixed malignant epithelial and mesenchymal elements. The diagnosis is difficult due to such variety histopathological features and there is no consensus on the treatment strategy of this rare entity. **Case report:** In this paper, we report a case of 70 years old male, who presented a persistent hoarseness of voice evolving since six months and was diagnosed by histopathological and immunohistochemical studies to be a case of carcinosarcoma of a left vocal cord, the general physical examination of the patient and workup for extension carried out were normal. He underwent exclusive external beam radiotherapy for 66 Gy in 33 Fractions with 2 Gy per fraction for five days per week, by opposed lateral fields to the larynx. Our patient had an uneventful post-radiation phase, after 3 months, he is asymptomatic and having complete clinical and radiological response. Furthermore, he delivered good results after 12 months of following up. **Conclusion:** The prognosis of carcinosarcoma of larynx is largely controversial and seems to be poor with high recurrence rate. By contrast, our patient remained in good control after 12 months of following up.

**KEYWORDS:** Carcinosarcoma, larynx, radiotherapy.

**INTRODUCTION**

Carcinosarcoma of the larynx has been occasionally described in the literature, it represents less than 1% of all malignant laryngeal tumors.<sup>[1]</sup> True carcinosarcoma is defined by mixed malignant epithelial and mesenchymal elements. This pathological entity is widely controversial due to its heterogenous terminology, rarity and disputed histogenesis.<sup>[2]</sup> It is also known as "sarcomatoid carcinoma" "spindle cell carcinoma," "pseudosarcoma," "spindle squamous cell carcinoma."

The following is a case report of a patient who presented to our institution with carcinosarcoma of left vocal cord.

**CASE REPORT**

70 years old-male. Presented to the department of radiotherapy-oncology, national institute of oncology, Rabat with a persistent hoarseness of voice of six months duration which had been increasing gradually.

A History of smoking and alcoholism were present since 33 years duration and there is no history of any medical co-morbidities.

A radiograph of chest did not reveal any metastatic nodules. Ultrasonography of the abdomen region of the

patient was normal. General physical examination of the patient was normal.

Contrast enhanced computed tomography scan of head and neck showed irregular enhancing lesion of the left vocal cord. Paraglottic space appears normal. No evidence of infiltration of the adjacent structures or cervical lymphadenopathy.

Direct laryngoscopy revealed growth on anterior third of left vocal cord without anterior commissure involvement and bilateral vocal cords were mobile. Biopsy was taken and sent for histopathological examination.

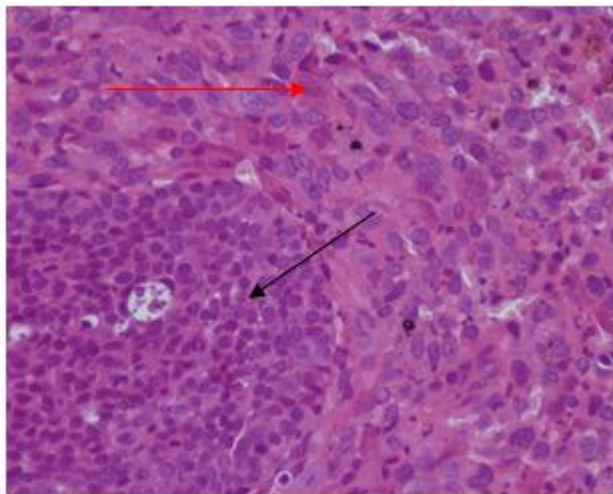
Histopathology report shows fragments totally tumorous made by a double contingents: the first made by Compact basaloid cells and cytonuclear atypia, the second proliferation, more abundant, characterized by a diffuse cellular slick made of elements showing strong anisocaryosis with hypertrophic, irregular, hyperchromatic and inconstantly nucleated nuclei. Mitotic activity is important.

Immunohistochemical study revealed intense immunoreactivity to vimentine (V9-BiosB) in the sarcomatous areas and to cytokeratin (AE1/AE3-DAKO) in the carcinomatous areas. On the basis of morphological and immunohistochemical elements;

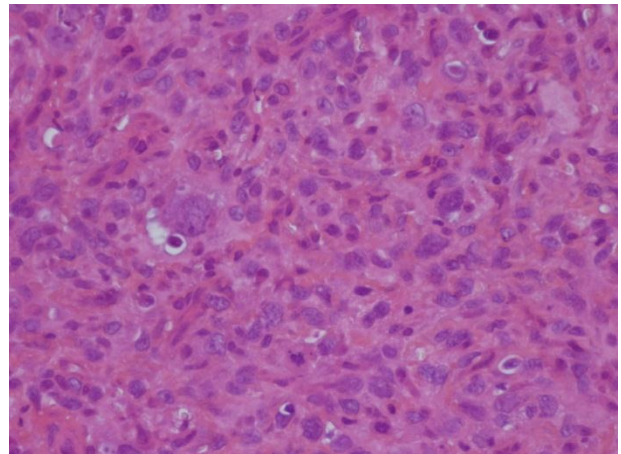
histopathological findings are in favor of a carcinosarcoma (fig.1,2,3).

Patient was clinically diagnosed as T1N0M0, stage I. He underwent exclusive external beam radiotherapy for 66 Gy in 33 Fractions in 6.6 weeks with 2 Gy per fraction for five days per week, in supine position by opposed lateral fields to the larynx (fig.4). Radiotherapy was tolerated well and patient had an uneventful post-radiation phase. Patient is asymptomatic and having complete response.

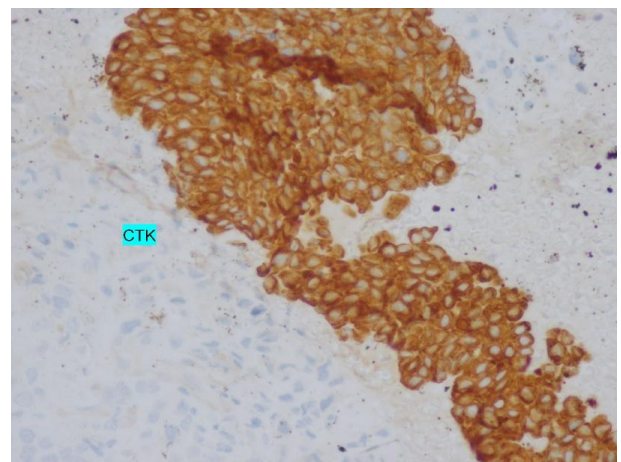
Patient is without any evidence of tumor recurrence after 12 months of follow-up.



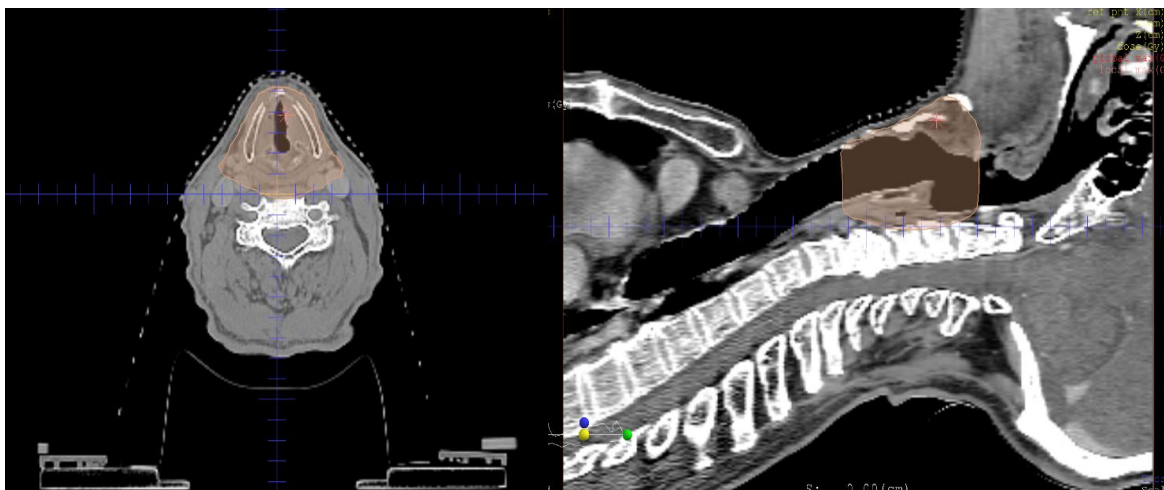
**Figure 1:** Tumoral proliferation with double components: epithelial component (black arrow) made by carcinomatous cluster and sarcomatous component (red arrow). (H&E 200x).



**Figure 2:** The mesenchymal component with manifest atypia. (H&E x400).



**Figure 3:** Positive labeling of the anti-CK AE1-AE3 antibody at the level of the carcinomatous cells and no labeling at the level of the tumor cells of the sarcomatous component (IHC x200).



**Figure 4:** (a-b) Dosimetry images showing coverage of the 95% dose in (a) axial and (b) sagittal view.

## DISCUSSION

Squamous cell carcinoma (SCC) is considered to be the most common type of malignant laryngeal tumor. Carcinosarcoma of the larynx is an uncommon variant of

SCC; it represents less than 1% of all malignant laryngeal tumors.<sup>[1]</sup> It is also known as “sarcomatoid carcinoma” “spindle cell carcinoma,” “pseudosarcoma,” “spindle squamous cell carcinoma. Despite several electron microscopic, immunohistochemical and genetic

studies, precise histogenesis of carcinosarcoma is quite controversial.<sup>[3]</sup>

Exact etiology of a laryngeal carcinosarcoma remains unknown, whereas, Many etiological hypotheses have been proposed. It has similar clinical presentation like other laryngeal carcinomas;<sup>[4]</sup> in their report of their large series of 'spindle cell (sarcomatoid) carcinomas of the larynx', Thompson et al. described the following characteristics of these tumours: male preponderance (93.0 per cent); history of heavy tobacco (87 per cent) and alcohol (48 per cent) use; hoarseness as the most frequent symptom (88 per cent); the glottis as the most common site (71 per cent); and a polypoid appearance (99 per cent) with surface ulceration.<sup>[5]</sup>

As presented in our case, hoarseness is the most frequent symptom. Other symptoms are change of voice, breathlessness, airway obstruction, difficulty in swallowing, sore throat, cough or stridor.

Spindle cell carcinoma is mainly diagnosed pathologically in which both squamous cell and a spindle cell stromal reaction (sarcomatous) histology is demonstrated.<sup>[6]</sup> Microscopic features of squamous cell carcinoma show tissue with sheets of pleomorphic squamous epithelial cells infiltrating the stroma. The tumour cells have round to oval nuclei with prominent nucleoli and with abundant eosinophilic cytoplasm. Keratin pearls can also be seen.<sup>[7]</sup> The microscopic features of carcinosarcoma show malignant epithelial and stromal components. Both components are admixed. On immunohistochemistry, epithelial component is positive to cytokeratin and mesenchymal component is positive to vimentine, while the positivity for other markers like S-100, actin, desmin etc. depends on tumour cell origin.

In our case, immunohistochemistry was strongly positive for Cytokeratin in the epithelial component and positive for Vimentine in the mesenchymal component leading to a diagnosis of carcinosarcoma.

There is no consensus on what constitutes reasonable therapy for patients with laryngeal carcinosarcoma. The specific treatment approach should be based on the tumour stage, location and size, just as if these patients had conventional squamous cell carcinoma. Then, Standard treatment is surgery alone or surgery followed by adjuvant radiation therapy.<sup>[5]</sup> In most centers, RT is the initial treatment prescribed for T1 and T2 lesions, with surgery reserved for salvage after RT failure.<sup>[8,9,10]</sup> Although hemilaryngectomy or cordectomy produces comparable cure rates for selected T1 and T2 vocal cord lesions, RT is generally preferred.<sup>[9,11]</sup>

The major advantage of irradiation compared with partial laryngectomy is organ preservation and better quality of life.<sup>[5,12,13]</sup>

Prognosis of carcinosarcoma of the larynx is controversial.<sup>[14,15]</sup> The 5-year actuarial local control rates are 94% and 54% for patients with T1 and T2 lesions respectively. The 10-year actuarial disease-specific and overall survival rates are 92% and 63%, respectively. Five year overall survival rate is 58.8%. Recurrence rate is 45%, and it may occur from within 2 months to 9 years post treatment. More favourable prognosis is associated with glottis tumors. Local control in early T1 or T2 glottic tumors is 70-96% with radiation alone and 63-100% with surgery alone.<sup>[5]</sup>

In the present case, patient underwent exclusive radiation therapy. After completing radiation therapy successfully, patient is having complete response and without any evidence of tumor recurrence even after twelve months of follow up.

## REFERENCES

1. Brodsky G. Carcino (pseudo) sarcoma of the larynx: the controversy continues. *Otolaryngol Clin North Am*, 1984; 17: 185-97.
2. Klijanienko J, Vielh P, Duvillard P, Lubinski B. True carcinosarcoma of the larynx. *J Laryngol Otol*, 1992; 106: 58-60.
3. Oktay M, Kokenek-Unal TD, Ocal B, Saylam G, Korkmaz MH, Alper M. Spindle cell carcinoma of the tongue: a rare tumor in an unusual location. *Pathology research international*, 2011; 1: 1-6.
4. Ianniello F, Ferri E, Armato E, Longo L, Zambenedetti P. Carcinosarcoma of larynx: immune histochemical study, clinical considerations, therapeutic strategies. *Acta otorhinolaryngologica Italica*, 2001; 21(3): 192-9.
5. Thompson LD, Wieneke JA, Miettinen M, Heffner DK. Spindle cell (sarcomatoid) carcinomas of the larynx: a clinicopathologic study of 187 cases. *Am J Surg Pathol*, 2002; 26: 153-70.
6. Katase N, Tamamura R, Gunduz M, Murakami J, Asaumi J, Tsukamoto G, et al. A spindle cell carcinoma presenting with osseous metaplasia in the gingiva: A case report with immunohistochemical analysis. *Head Face Med*, 2008; 4: 28.
7. Wiernik G, Millard PR, Haybittle JL. The predictive value of histological classification in to degree of differentiation of squamous cell carcinoma of the larynx and hypopharynx compared with the survival of patients. *Histopathology*, 1991; 19: 411-17.
8. Mendenhall WM, Amdur RJ, Morris CG, et al. T1-T2N0 squamous cell carcinoma of the glottic larynx treated with radiation therapy. *J Clin Oncol*, 2001; 19(20): 4029-4036.
9. Mendenhall WM, Werning JW, Hinerman RW, et al. Management of T1-T2 glottic carcinomas. *Cancer*, 2004; 100(9): 1786-1792.
10. Chera BS, Amdur RJ, Morris CG, et al. T1N0 to T2N0 squamous cell carcinoma of the glottic larynx treated with definitive radiotherapy. *Int J Radiat Oncol Biol Phys*, 2010; 78(2): 461-466.

11. O'Sullivan B, Mackillop W, Gilbert R, et al. Controversies in the management of laryngeal cancer: results of an international survey of patterns of care. *Radiother Oncol*, 1994; 31(1): 23–32.
12. Mendenhall WM, Hinerman RW, Amdur RJ, Mancuso AA, Villaret DB, Werning JW. Larynx. In: Halperin EC, Perez CA, editors. Principles and Practice of Radiation Oncology. 5th ed. Philadelphia PA: Lippincott Williams & Wilkins., 2008; 975-1034.
13. Liu CY, Wang MC, Li WY, Chang SY, Chu PY. Sarcoma of the larynx: Treatment results and literature review. *Chin Med Assoc.*, 2006; 69(3): 120-24.
14. Nistal M, Yébenes-Gregorio L, Esteban-Rodríguez I, Bernáldez R, Regadera J. Malignant mixed tumour of the larynx. *Head Neck*, 2005; 27: 166–70.
15. Stomeo F, Rocca PC, Bozzo C, Bianchini C, Meloni F, Pastore A. Laryngeal true malignant mixed tumour. *Head Neck*, 2009; 31: 556–60.