

MANAGEMENT OF FISTULA-IN-ANO WITH KSHARASUTRA: A CASE STUDY**Dr. Sanghamitra Samantaray*, Dr. Vinayak S Kinnal**Associate Professor, Dept of Shalya Tantra, Sri Babu Singh Dadduji Ayurveda Medical College and Hospital,
Fatehgarh.

Assistant Professor; Shri Babu Singh Dadduji Ayurvedic Medical College. Fatehgarh.

***Corresponding Author: Dr. Sanghamitra Samantaray**

Associate Professor, Dept of Shalya Tantra, Sri Babu Singh Dadduji Ayurveda Medical College and Hospital, Fatehgarh.

Article Received on 01/05/2018

Article Revised on 22/05/2018

Article Accepted on 12/06/2018

ABSTRACT

Fistula in Ano is a chronic inflammatory condition having a tubular structure with opening in the Anorectal canal at one end and surface of perineum or perianal skin on the other end. Any opening in perianal area with chronic pus discharge indicates fistulous tract. Prolong sitting, unhygienic condition, obesity, repeated irritation due to hair may increase the risk of occurrence. In Ayurveda it is correlated with Bhagandar and Acharya Sushruta mentioned five types of Bhagandar. He had explained Shastra karma along with Kshara karma and Bhesaja chikitsa for treatment. Here a case of fistula in Ano in a 30 year male patient was examined in Shalya OPD and treated with Ksharasutra, considering it as an ideal procedure in treatment of Bhagandar as it cuts and cures the unhealthy tissue present inside the fistulous tract.

KEYWORDS: Bhagandar, kshara sutra, fistula in ano.**INTRODUCTION**

In Ayurveda it is mentioned that certain clinical condition requires surgical intervention for better cure. Charaka mainly a Kayachikitsa treatise also stated that the diseases like Gulma, Arsha, Bhagandar, Ashmari may require surgical intervention. Sushruta has discussed in the detail about various Shastra karma along with Anushastra karma which includes Agnikarma, Jalaukavcharana and Ksharakarma. Kshara is considered as one of the most important parasurgical procedure as it can produce excision, incision, scrapping and can pacify all three Doshas.

Kshara application in the form of Ksharasutra, in anorectal diseases has become more popular due to its easy approach and low rate of recurrence. Ksharasutra induces both mechanical and chemical cutting and healing. Direct reference of Ksharasutra is found in Sushruta for treatment of Nadivrana. Chakradatta has referred to a medicated thread coated with Snuhi and Haridra powder in treatment of Arsha and Bhagandar. But the modified ksharasutra available now a day is re-established by the Dept. of Shalya Tantra Banaras Hindu University. The standard Ksharasutra is prepared by 11 coatings of Snuhi Ksheera then 7 coatings of Snuhi Ksheera and Apamarga Kshara and then again 3 coatings of Snuhi Ksheera and Haridra Churna. This Kshara Sutra is used in treatment of fistula in ano due to its cutting, curetting and healing effect as well as it controls the infection.

In this study a case report of Fistula in Ano treated by Ksharasutra which was cured and no further complaints were found in the patient during follow up period.

Ayurvedic view of bhagandar and kshara sutra

Acharya Sushruta described Fistula in Ano under the heading Bhagandar along with its symptoms, types and its management. The disease which creates Darana (tear) like yoni in the area of pelvis, rectum & urinary bladder is called as Bhagandar and when these are not opened it's called as Bhagandar Pidaka. An abnormal passage between a hollow or tubular organ (bhaga, guda, or basti) and the body surface or between two hollow or tubular organs is called fistula.

Kshara destroys the vitiated tissue and make them fall off. It is the most important among Shastra and Anushastra because it does functions like excision, cutting and scrapping, also mitigates all the three doshas. Acharya Sushruta described that nadivrana (sinus) should be cut open by Kshara Sutra and also he said the same procedure should be adopted for Bhagandar.

CASE REPORT

Patient Name- XYZ

Age- 30 year

Gender- male

Occupation- tailor

Date of admission- 20/4/2018

Date of recovery-25/5/2018

Chief complaints and duration

Patient complains of pus discharge with mild pain at the right side of perianal region since 4 month.

H/o present illness

Patient was apparently normal before 4 month. Then he had developed boil with intermittent discharge in perianal region since last 4 months. He also complained of mild pain and discomfort while sitting and continuous pus discharge since 2-3 months. He had taken analgesics for it, but didn't get any relief. Therefore for further treatment he came to OPD of Shalyatanra, SBSDAMC & H, Fatehgarh.

Family history

No H/O HTN, DM or any other major illness

General examination

G.C-moderate
Afebrile
CVS- S1 S2 Normal.
Pulse- 86/min, BP- 130/90 mm Hg,
RS- Chest clears on both sides.
Digestive System- Appetite- normal, Bowel- constipated.
Uro-genital System- NAD

Local examination

In lithotomy position of patient, the findings observed were: patient had hairy perineal region with a small opening in right side of perianal region with seropurulent pus discharge through that opening, tenderness on touch with indurations was felt around external opening. Probing was done from external opening to access the internal opening but internally it was fibrosed. About 5 cm tract was found during probing.

On proctoscopic examination no any anal pathology was seen. After complete examination the diagnosis was confirmed as Fisula in Ano i.e. Bhagandar.

In this patient perianal skin was normal with no dermatitis.

Ksharsutra application**Pre-operative preparation**

Local part preparation i.e. shaving was not done as patient didn't allow due to some ritual believe. 5gm panchasakar churna with luke warm water was given to the patient at night before operation. Proctoglycerin enema was given at early morning on day of operation. After proper bowel passed patient was taken to recovery room and injection T.T. 0.5ml IM was given and plain xylocaine 2% was given subcutaneously for sensitivity test.

Operative procedure

Patient was taken in lithotomy position on operation theatre table.

After proper painting and drapping, local anaesthesia with 2% xylocaine was infiltrated nearby opening and around anal verge.

Reassessment of extension of tract was done by probing. Probe was removed through anal opening via internal opening after feeding of ksharasutra and ksharasutra ligated appropriately. Complete haemostasis was maintained and T bandaging was done.

Postoperative procedure

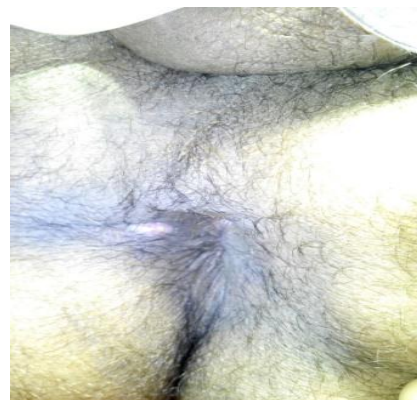
Broad spectrum antibiotics, analgesic along with ayurvedic medicine and sitz bath was given. Patient was admitted to the Hospital for 7 days till next ksharasutra was changed.

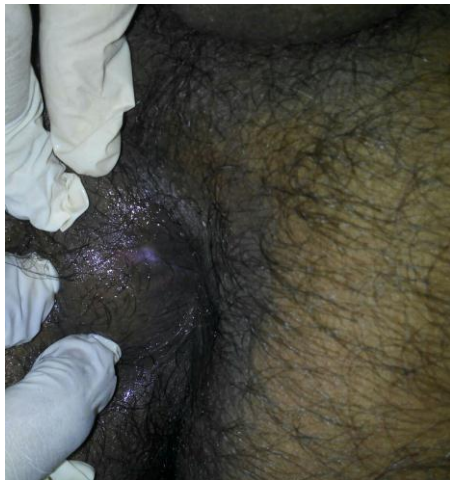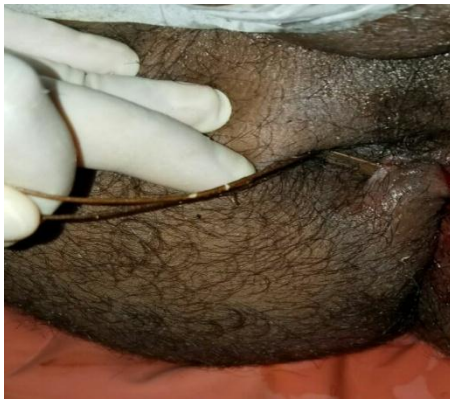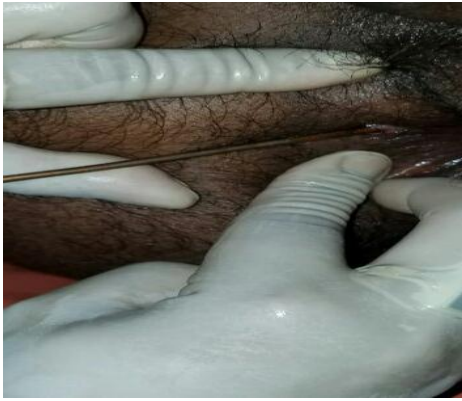Oral medications

Mox-cv 625 bd
Zerodol sp bd
Triphala guggulu tid
Gandhak rasayan tid
Panchasakar churna 3grams hs
Sitz bath with triphala kwath.
Patient was advised to take khichdi and daliya during hospital stay. He was also advised to resume his normal day to day activities.

Follow up

Patient was discharged from hospital after 1st ksharasutra change and then asked for changing ksharasutra every 7th day till cutting of the tract. Hot sitz bath and jatyadi taila local application was done during this period. Patient was allowed to do his routine job after discharged from hospital. After 6 sitting the tract was totally cut and healing was achieved simultaneously. Jatyadi taila application on scar mark was advised.





mainly occurs due to local action of kshara, snuhi and the mechanical pressure of ksharasutra knot. Haridra powder having antiseptic action helps in healing of the tract.

CONCLUSION

The incidence of fistula in ano is increasing now a day due to improper job style where a person sits for long time on hard surfaces. The management of anorectal diseases need a complete knowledge of anorectal anatomy and pathophysiology. Also it needs to be diagnosed early so that appropriate treatment can be given without delay. Ksharasutra helps in removal of debridement and also prevent from bacterial infections. Ksharasutra at a time provides both cutting and healing so we can use it in any type of fistula tract. So we conclude that in fistula in ano ksharasutra treatment is a better option due minimum complication and patient can resume normal activities earlier.

REFERENCES

1. Sushruta Samhita, Nidan Sthan, Vaidya Yadavji Trikamji Acharya, Chaukhamba Publications.
2. Sushruta Samhita, Chikitsa Sthan, Vaidya Yadavji Trikamji Acharya, Chaukhamba Publications.
3. Sushruta Samhita, Nidan Sthan, Kaviraj Ambika Dutta Shastri, Chaukhamba Sanskrit Samsthan.
4. Sushruta Samhita, Chikitsa Sthan, Kaviraj Ambika Dutta Shastri, Chaukhamba Sanskrit Samsthan.
5. Despande P.J, Pathak S.N, The Treatment of Fistula in Ano with Kshara Sutra Treatment.

DISCUSSION

Sushruta described the treatment of fistula in ano as bhashaj, ksharakarma, agnikarma and Shastra karma. In modern medicine treatment like fistulotomy, fistulectomy, seton ligation are indicated. These treatments have more recurrence rate and post operative complications like haemorrhage, pain, delayed healing etc. In comparison to Modern Treatment Ksharasutra ligation is better due to its minimal complications and less recurrence. Even fecal incontinence and anal stricture are not seen in this case.

The application of Ksharasutra is having anti-inflammatory and anti-microbial property and due to its alkaline property helps in cutting and healing. Cutting