

**PREVALENCE OF ORAL MUCOSAL LESIONS AMONG PAEDIATRIC PATIENTS
ATTENDING PATNA DENTAL COLLEGE AND HOSPITAL PATNA BIHAR: A CROSS
SECTIONAL STUDY****Anju Singh, BDS (H), MDS¹ and Dr. Konark, BDS (H), MDS^{2*}**¹Senior Resident, Department of Pedodontics and Preventive Dentistry, Government Patna Dental College and Hospital, Patna, Bihar, India.²Senior Lecturer, Department of Conservative Dentistry and Endodontics, Government Patna Dental College and Hospital, Patna, Bihar, India.***Corresponding Author: Dr. Konark, BDS (H), MDS**

Senior Lecturer, Department of Conservative Dentistry and Endodontics, Government Patna Dental College and Hospital, Patna, Bihar, India.

Article Received on 06/05/2018

Article Revised on 27/05/2018

Article Accepted on 17/06/2018

ABSTRACT

Aim: The aim of this study was to evaluate the prevalence of oral lesions in Bihar Population. **Methods:** A cross-sectional study was carried out on total of 210 paediatric patients with age 6 years to 12 years were included. Patients with systemic disease were not included in this study. **Results:** Out of 210 patients 59 (28.09%) patients were diagnosed with oral mucosal lesions. Out of 59 patients 15 (25.42%) patients were diagnosed with Minor Aphthous Ulcer and 1 (1.69%) patients with oral candidiasis, pyogenic granuloma, ranula. **Conclusions:** There is a need for more good quality epidemiological studies in this area.

KEYWORDS: Oral mucosal lesions; paediatric population; epidemiology.**INTRODUCTION**

Oral mucosal lesions are a broad group of alterations located in the soft tissues of the oral cavity. These lesions are recognizable by their etiology, clinical characteristic features, prognosis, and dissimilar treatments. The oral mucosal lesions can present as vesicles, ulcers, macules, changes in color, size alterations, and configuration of the oral anatomy in paediatric patients. The clinical exam to obtain a diagnosis of oral conditions and lesions is fundamental, which is why, it must be correct, thorough, and systematic. The exam of soft tissues in paediatric patients involves knowledge of normal size, shape, color, and texture of the structures that comprise it. The correct exploration of the oral mucosa can provide important tools in diagnosing developmental, neoplastic, infectious, or inflammatory alterations.^[1]

The frequency of children with oral mucosal lesions and the prevalence of each lesion show a wide range of literature and this may be a result of the difference of geographic areas, sociodemographic characteristics of the population studied, and the clinical diagnostic criteria. Although examined studies have provided helpful information in this field, the lack of uniformity in the criteria adopted by the researchers makes it difficult to draw coherent conclusions. Therefore, an appropriate protocol should be created in order to exactly evaluate the prevalence of the most common oral mucosal lesions in

children and their association with a particular condition (age, gender, systemic disease, socioeconomic level).^[2]

MATERIAL AND METHODS

An observational, descriptive study was conducted after obtaining the ethical clearance from Institutional Ethical committee before the commencement of the study. Non-probability sampling was used for convenience depending on scheduling and availability of the patients from the Paediatric Dentistry Department. 210 patients were examined. Patients with age group between 6 to 12 years were included in this study. Patients with systemic disease were excluded from the study. The oral mucosal lesion was captured using a photograph. The results obtained were processed using Microsoft Office Excel 2010® worksheet and a descriptive statistical analysis was done.

RESULTS

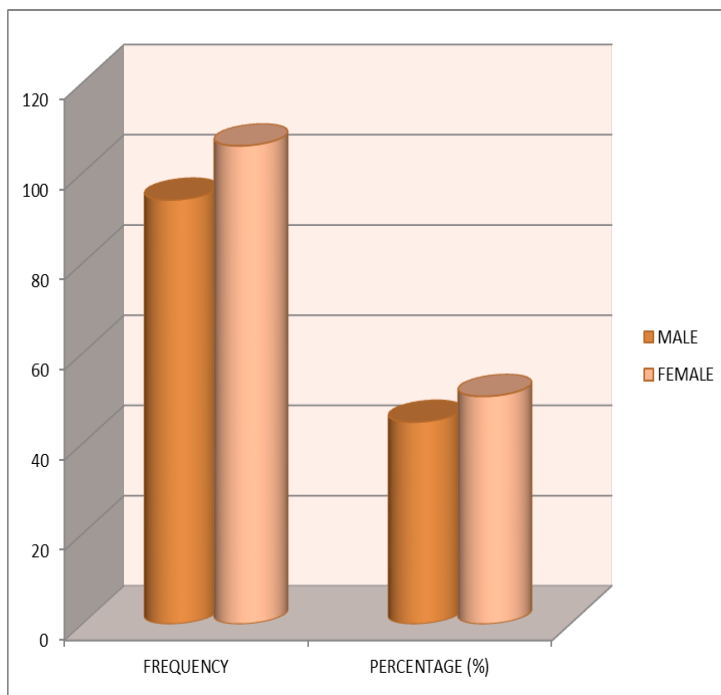
210 paediatric patients were examined in the department of paediatric dentistry in which 94 (44.76%) % were male and 106 (50.47%) were female (Table 1, Graph 1). The age group of the patients was from 6 to 12 years of age. Among 210 patients 59 (28.09%) patients were diagnosed with one oral mucosal lesion and 151 (71.9%) patients without oral mucosal lesion (Table 2, Graph 2). Out of 59 patients with oral mucosal lesions there were 25 (42.37%) male patients and 34 (57.62%) female

patients with oral mucosal lesions (Table 3, Graph 3). Out of 210 patients 59 patients were diagnosed with oral mucosal lesions. Out of 59 patients 15 (25.42%) patients were diagnosed with Minor Aphthous Ulcer followed by 13 (22.03%) patients with traumatic ulcers followed by 10 (16.96%) patients with traumatic fibroma, 5 (8.47%) patients with herpetic stomatitis, 4 (6.78%) patients with mucocele, 3 (5.08%) patients with recurrent herpes, pigmented lesions, geographic tongue and 1 (1.69%)

patients with oral candidiasis, pyogenic granuloma, ranula (Table 4, Graph 4).

Table 1: Gender Wise Distribution of Patients.

Gender	Frequency	Percentage (%)
Male	94	44.76
Female	106	50.47

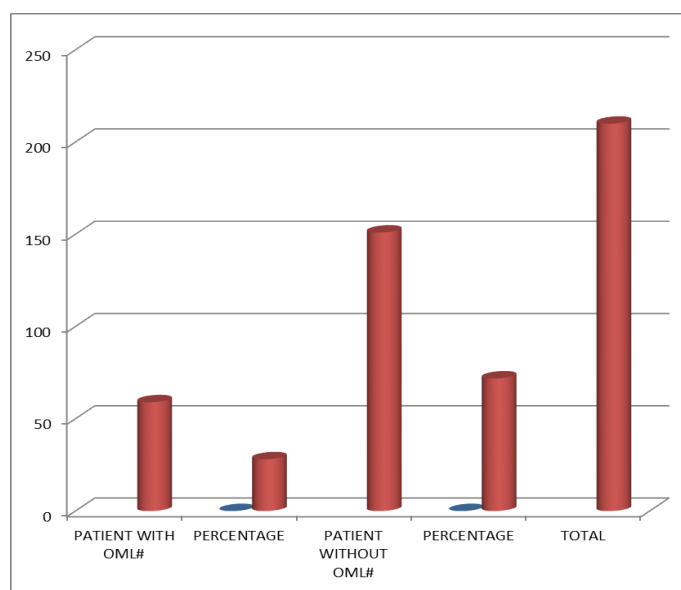


Graph 1: Gender Wise Distribution of Patients.

Table 2: Patient With OML# and Without OML#.

Patient With OML#	Percentage (%)	Patient Without OML#	Percentage (%)	Total
59	28.09	151	71.90	210

OML# Oral Mucosal Lesions

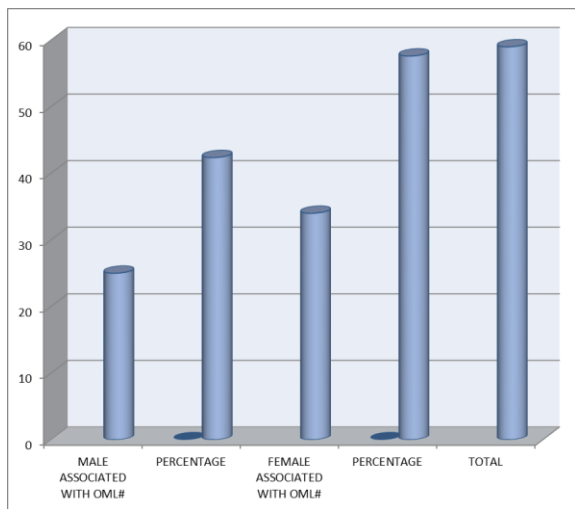


Graph 2: Patient with OML# and Without OML#.

Table 3: Gender Wise Distribution of OML#

Male Associated With OML#	Percentage (%)	Female Associated With OML#	Percentage (%)	Total
25	42.37	34	57.62	59

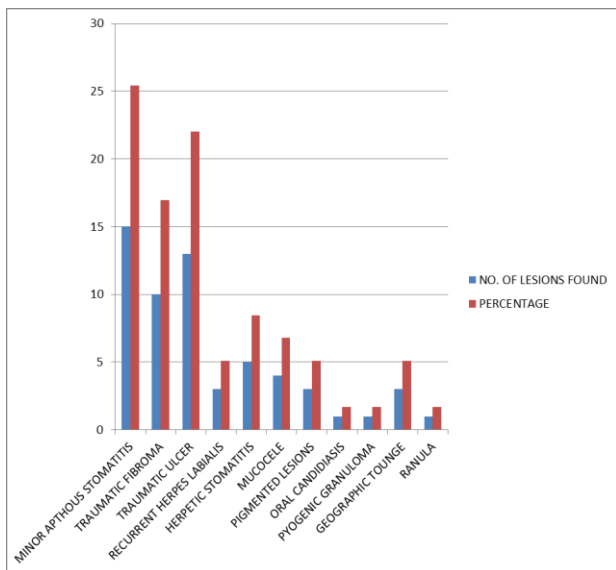
OML# oral Mucosal Lesions



Graph 3: Gender wise Distribution of OML#

Table 4: Prevalence of OML#

Type of Lesions	No. of Lesions Found	Percentage (%)
Minor Aphthous Stomatitis	15	25.42
Traumatic fibroma	10	16.95
Traumatic ulcer	13	22.03
Recurrent Herpes Labialis	3	5.08
Herpetic stomatitis	5	8.47
Mucocele	4	6.78
Pigmented Lesions	3	5.08
Oral Candidiasis	1	1.69
Pyogenic Granuloma	1	1.69
Geographic Tounge	3	5.08
Ranula	1	1.69



Graph 4: Prevalence of OML#

DISCUSSION

The prevalence of oral mucosal lesions in this study was of 28.09 % of the studied paediatric population. In the revised studies, this percentage varies from a 4.1 %^[3] to a 78.4 %.^[4] The most prevalent lesions were Minor Aphthous Ulcer 15 (25.42%) followed by 13 (22.03%) patients with traumatic ulcers followed by 10 (16.96%) patients with traumatic fibroma, 5 (8.47%) patients with herpetic stomatitis, 4 (6.78%) patients with mucocele, 3 (5.08%) patients with recurrent herpes, pigmented lesions, geographic tongue and 1 (1.69%) patients with oral candidiasis, pyogenic granuloma, ranula. No malignant lesions were found in the present study, which confirms the rarity of these lesions in the oral cavity. Even though it is rare, the oral and maxillofacial health care professional should remain alert for any suspicious lesion. Non-traumatic white patches, white patches with red areas, chronic non-healing ulcers, and indurated lesions are some of the features which would make a lesion suspicious and should be investigated further. Opportunistic screening of high risk individuals will go a long way in detecting oral cancer and precancer at a relatively early stage. For the dentists to fully contribute to improvement of early detection, they must perform thorough examinations. Repeatedly training one to scrutinize the entire oral mucosa in a systematic fashion reduces the chance of missing any lesion.^[5]

CONCLUSION

The information furnished in this present study adds to our understanding of the common oral mucosal lesions occurring in the general population. The most common oral mucosal lesion was found to be minor aphthous ulcer followed by traumatic fibroma and traumatic ulcers. Further study is required with larger sample size.

ACKNOWLEDGEMENT

Authors acknowledge the immense help received from the scholars whose articles are cited and included in reference of this manuscript. The authors are grateful to authors / editors / publishers of all those articles, journal and books from where the literature for this article has been reviewed and discussed.

REFERENCES

1. Espinoza, I.; Rojas, R.; Aranda, W. & Gamonal, J. Prevalence of oral mucosal lesions in elderly people in Santiago, Chile. *J. Oral Pathol. Med.*, 2003; 32(10): 571-5.
2. Colaci R, Sfasciotti G. Most common oral mucosal lesions in children: Prevalence and differential diagnosis. *Webmed Central Dentistry*, 2013; 4(12): WMC004483.

3. Arendorf, T. M. & van der Ross, R. Oral soft tissue lesions in a black pre-school South African population. *Community Dent. Oral Epidemiol*, 1996; 24(4): 296-7.
4. Espinosa-Zapata, M.; Loza-Hernandez, G. & Mondragón-Ballesteros, R. Prevalencia de lesiones de la mucosa bucal en pacientes pediátricos. Informe preliminar. *Cir. Cir.*, 2006; 74(3): 153-7.
5. Ali M., Sundaram D. Biopsied oral soft tissue lesions in Kuwait: a six-year retrospective analysis. *Med. Princ. Pract*, 2012; 21: 569–575.