

**DIAGNOSTIC STUDY OF CLINICAL, LABORATORY AND RADIOLOGICAL FINDINGS IN ACUTE APPENDICITIS**Naniwadekar R.G.<sup>1</sup>, Bhagat Abhishek\*<sup>2</sup> and Kesarwani Abhinav<sup>3</sup><sup>1</sup>Professor, Department of General Surgery, Krishna Institute of Medical Sciences, Karad.<sup>2,3</sup>Resident, Department of General Surgery, Krishna Institute of Medical Sciences, Karad.**\*Corresponding Author: Dr. Abhishek Bhagat**

Professor, Department of General Surgery, Krishna Institute of Medical Sciences, Karad.

Article Received on 02/04/2018

Article Revised on 23/04/2018

Article Accepted on 14/05/2018

**ABSTRACT**

**Background:** Appendicitis is the inflammation of the appendix. It is a disease of the young, with 40% of cases occurring between the ages of 10 and 29 yrs. The present study involves diagnostic study of clinical, laboratory and radiological findings in acute appendicitis. **Materials and methods:** It was a prospective analytical study carried out at department of surgery, Krishna Institute of Medical Sciences to study diagnostic accuracy and value of clinical, laboratory and radiological findings in acute appendicitis, conducted during the period from October 2015 to October 2017. **Results:** It was observed that majority of patients belonged to age group 21-30 years (34%) followed by 31-40 years (26%). The proportion of male cases was 58% while that of female cases was 42%. all patients presented with pain in abdomen and tenderness in right iliac fossa (100%), followed by vomiting (82%). **Conclusions:** Acute appendicitis is more a clinical diagnosis rather than radiological. It is better to use radiological investigations only to confirm the diagnosis of acute appendicitis rather to diagnose it primarily because it is clear from the present study that a significant number of positive cases had been missed radiologically.

**KEYWORDS:** Acute abdomen, Acute appendicitis, Appendix, Clinical diagnosis.**INTRODUCTION**

Appendicitis is the inflammation of the appendix. It is a disease of the young, with 40% of cases occurring between the ages of 10 and 29 yrs. In 1886, Fitz reported the associated mortality rate of appendicitis to be at least 67% without surgical therapy.<sup>[1]</sup> Sir Heneage Ogilvie says "Acute appendicitis is one of the common condition which the surgeon is called upon to treat as an emergency". It requires utmost skill and care of the attending doctor, besides good clinical judgement. Acute appendicitis is the most common surgical cause of acute abdomen. There is no doubt that early diagnosis with prompt surgical intervention is the goal.

In a general hospital most common abdominal operation is appendectomy. This constitutes about 25% of emergency abdominal surgeries in many hospitals, Meloney and his associates estimated that 1 in 100 of population may be expected to get appendicitis every year. There is no known method of prevention of acute appendicitis. The diagnosis of acute appendicitis is predominantly a clinical one, many patients present with a typical history and examination findings. The cause of acute appendicitis is unknown but is probably multifactorial- luminal obstruction, dietary and familial factors have all been suggested. Appendectomy is the treatment of choice.<sup>[2]</sup> Despite technologic advances, the

diagnosis of appendicitis is still based primarily on patients history and the physical examination. Prompt diagnosis and surgical referral may reduce the risk of perforation and prevent complications. The mortality rate in non-perforated appendicitis is <1% but may be as high as 5% or more in young and elderly patients. The present study involves diagnostic study of clinical, laboratory and radiological findings in acute appendicitis.

**MATERIALS AND METHODS**

It was a prospective analytical study carried out at department of surgery, Krishna Institute of Medical Sciences to study diagnostic accuracy and value of clinical, laboratory and radiological findings in acute appendicitis, conducted during the period from October 2015 to October 2017. In the present study 150 patients admitted to wards with history of pain abdomen (especially with pain in right iliac fossa suggestive of acute appendicitis) within 24-48 hours in the department of General Surgery were included.

We excluded patients with history of pain abdomen of >48 hours duration with clinical symptoms and signs suggestive of appendicular mass or appendicular abscess or diagnosed to be having other pathological conditions like PID, ruptured ectopic, right ureteric calculus, perforated duodenal ulcer, acute cholecystitis, torsion of

omentum, enterocolitis, nonspecific mesenteric lymphadenitis, regional ileitis, obstructed carcinoma of the caecum, Meckel's diverticulum etc.

After admission to the hospital a detailed proforma was filled including clinical history and physical findings, preoperative investigations. On the basis of clinical history and the physical signs a diagnosis of acute appendicitis was made and differentiated from other acute abdomen conditions. After taking the history, patient was examined for general physical examination, and systemic examination and few specific examinations particular for the appendicitis are done. Preliminary haematological investigations and ultrasonography of abdomen and pelvis was done. All the patients were assessed according to modified Alvarado scoring system as below:

Patients with a score of 1 - 4 were not considered likely to have acute appendicitis. Those patients with score of 5 - 6 were considered likely to have acute appendicitis. But not convincing enough to warrant immediate surgery. Those with a score more than 7 were considered to have definitive acute appendicitis.<sup>[3]</sup> Score Prediction: 1-4 : Unlikely, 5-6 : Possible, More than: 7 Definitive. Appendix was removed during appendicectomies and was inspected for macroscopic abnormalities and microscopic findings evaluated by histopathological findings.

The data was recorded using standard case record proformas and entered using Microsoft Excel software. The statistical analyses performed using the Statistical Package for Social Science (SPSS) version 21 for Windows. Data were expressed as mean values  $\pm$  standard deviations (SD) for continuous variables. Frequency and proportions were reported for categorical variables. The p-value of  $< 0.05$  was considered statistically significant.

## RESULTS

The present study was conducted among 150 cases admitted under department of surgery with history of pain in right iliac fossa suggestive of acute appendicitis within 24-48 hours. We recorded and analyzed various demographic variables of the study cases. It was observed that majority of patients belonged to age group 21-30 years (34%) followed by 31-40 years (26%). The proportion of male cases was 58% while that of female cases was 42% (Figure 1) (Figure 2).

We analyzed modes of presentation of cases and observed that all patients presented with pain in abdomen and tenderness in right iliac fossa (100%), followed by vomiting (82%).

The cases of acute abdomen were further subjected to various haematological investigations, It was observed that majority of patients presented with leucocytosis (82%) followed by increased neutrophil count 74%, 62% cases had increased C-reactive proteins (Table 1). Study cases were further subjected to ultrasonographic examinations. Among various USG features, it was observed that majority of patients were having congested oedematous appendix (80%) and in 3 cases perforated appendix was observed.

The findings were also confirmed using histological examinations, it was observed that majority of patients were having inflamed appendix finding (92%), followed by appendicular perforation (4%) (Table 3).

After comparative analysis of clinical, radiological and histological findings. The histological findings showed that findings from 144 (96%) patients, were in favour of conditions related to appendicitis as compared to just clinical (92%) or radiological (82%). In the present study the clinical accuracy was more as (sensitivity=92%) compared to radiological accuracy (sensitivity=82%) (Table 4).

**Table 1: Distribution of cases according to their various clinical parameters.**

Clinical parameters		Number of cases	Percentage
Clinical presentation	Pain in abdomen	150	100
	Vomiting	123	82
	Fever	120	80
	Tenderness in right iliac fossa	150	100
	Rebound tenderness	43	28.67
Investigation findings	Leucocytosis	123	82
	Increase Neutrophils	111	74
	Increase C-reactive Proteins	93	62
Modified Alvarado Score	$<4$	00	00
	5-6	03	02
	7-8	18	12
	$>8$	129	86
Operative as well as histopathological findings	Inflamed Appendix	144	96
	Appendicular perforation	06	04

**Table 2: Distribution of cases according to their Ultrasonography findings.**

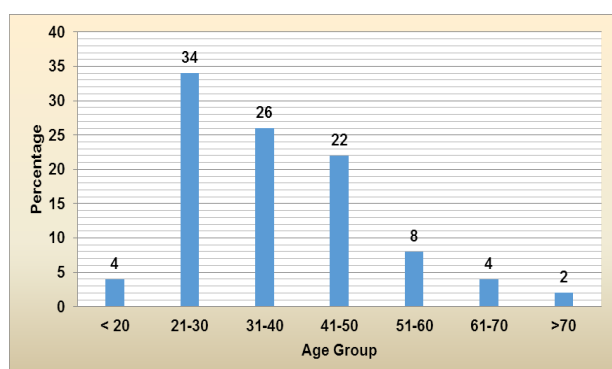
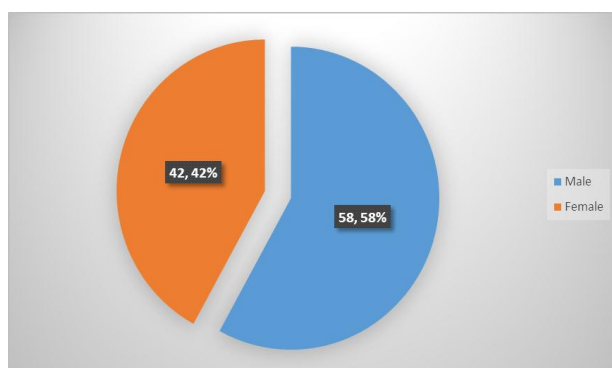
USG Features	Number of Patients	Percentage
Congested Oedematous	120	80
Not visualized	27	18
Perforated	03	02
Thickened fibrotic	00	00
Gangrenous	00	00
Total	150	100

**Table 3: Comparison of Clinical, Radiological and Histological Findings.**

Diagnosis	Positive (%)	Negative (%)	Total (%)
Clinical	138 (92)	12 (08)	150 (100)
Radiological	123 (82)	27 (18)	150 (100)
Histological	144 (96)	06 (04)	150 (100)

**Table 4: Diagnostic accuracy of Clinical, Radiological and Histological Findings.**

Diagnosis	Sensitivity	Specificity	Positive Predictive Value	Negative Predictive Value
Clinical	92%	50%	97.97%	25%
Radiological	82%	63%	91%	52%
Histological	96%	94%	98.73%	16%

**Figure 1: Distribution of cases according to their age groups.****Figure 2: Distribution of cases according to their gender.**

## DISCUSSION

The accurate clinical diagnosis of acute right iliac fossa pain remains a difficult clinical problem as the differential diagnosis of such pain is not always straightforward. Acute appendicitis is the most common non traumatic surgical emergency and in spite of all diagnostic modalities it is confusing for the clinician.

The diagnosis is made purely based on history, clinical examination and some laboratory investigations. New diagnostic techniques such as estimation of C-reactive protein, peritoneal aspiration cytology, scoring and computer analysis, graded compression ultra sonography, computed tomography, non-contrast helical computed tomography and laparoscopy have been introduced in recent years.<sup>[6]</sup> The drawback with these techniques is involvement of additional costs and lack of free availability. Due to these factors these modalities have not gained wide acceptance as routine diagnostic investigations of acute appendicitis. Imaging techniques have been shown to add very little. A certain diagnosis can only be obtained at surgery and after pathological examination of surgical specimen.<sup>[4,5]</sup>

Difficulty in diagnosis arise in very young, elderly patients and females of reproductive age because they usually have atypical presentation and many other conditions also present like appendicitis and literature shows that 2-7% of adults on exploration have diseases other than appendicitis. Against this, it is generally accepted that unnecessary surgery should be avoided, and this aspect of care is usually measured by the proportion of appendixes that are normal on histology, A negative appendectomy rate of 20-40% has been reported in literature and many surgeons would accept rate of 30% as inevitable. Removing normal appendix is an economic burden both on patients and health resources.

In the present study, we emphasized on the importance of clinical examination and utilization of modified Alvarado score in making a confident diagnosis of acute appendicitis and thereby decreasing the negative appendectomy rate. The present cross-sectional study was conducted to study diagnostic accuracy and value of

clinical, laboratory and radiological findings in acute appendicitis among total 150 patients admitted under department of surgery with history of pain in abdomen within 24-48 hours especially with pain in right iliac fossa suggestive of acute appendicitis during the study period of October 2015 to October 2017.

The present study has shown that modified Alvarado scoring system (MASS) provides high degree of sensitivity, specificity, PPV and accuracy in the diagnosis of acute appendicitis by showing lower negative appendicectomy rate and high positive predictive value. It is therefore recommended that modified Alvarado score should be used to improve the diagnostic accuracy of acute appendicitis and subsequently reduce negative appendicectomy and complication rates. A modified Alvarado score above 7 should indicate appendectomy without the need for further imaging studies. This study proves that modified Alvarado scoring system is very useful scoring system for diagnosis of acute appendicitis. It may help making early diagnosis and prevent further complications, reduce numbers of negative appendicectomies, it is better than other scoring systems because it includes wide spectrum of symptoms and signs and laboratory investigations and finally it helps in reducing necessity of ultrasonography and CT scan which has become now-a-days gold standard for diagnosis of acute appendicitis.

Clinical accuracy was more in the study as compared to radiological methods. There is no advantage of ultrasound over the other methods for the diagnosis of acute appendicitis. Ultrasound is unnecessary when one's degree of clinical suspicion is high. However, the additional information provided by ultrasound does improve diagnostic accuracy in the case of a negative clinical diagnosis. Acute appendicitis is more a clinical diagnosis rather than radiological. It is better to use radiological investigations only to confirm the diagnosis of acute appendicitis rather to diagnose it primarily because it is clear from the present study that a significant number of positive cases had been missed radiologically.

In the present study, it was observed that majority of patients were in age group 21-30 years (34%) followed by 31-40 years (26%) The majority of patients were males (58%) and females were 42%. The findings were compared with studies done by Nshuti R,<sup>[7]</sup> Kapoor S et al,<sup>[8]</sup> and A. Gligorievski et al<sup>[9]</sup> were mean age was 26  $\pm$ 12, 28  $\pm$ 11 and 31  $\pm$ 10 years respectively. A. Gligorievski et al<sup>[9]</sup> (2010) demonstrated the value of the ultrasound (US) as an excellent diagnostic modality in evaluation of the appendix in 124 cases with history and physical examination of acute appendicitis observed with aged 15-57, with peak incidence in second decade of life with mean age of 31  $\pm$ 10 years. Kapoor S et al<sup>[8]</sup> (2016) evaluated the efficiency of clinical examination, radiological investigations, intraoperative and histopathological examination in diagnosis of acute

appendicitis among fifty consecutive patients suspected of acute appendicitis observed mean age of 28  $\pm$ 11 years.

In this study it was observed that all patients presented with pain in abdomen and tenderness in right iliac fossa (100%), followed by vomiting (82%). Majority of patients presented with leucocytosis (82%) followed by increased neutrophil count 74%. The modified Alvarado Score showed that majority of patients were having score  $>8$  (86%). Nshuti R<sup>[7]</sup> in their study found pain as a major symptom among 90% whereas Kapoor S et al<sup>[8]</sup> (2016) observed pain as a most common symptom among 92%.

In this study it was observed that majority of patients were having congested oedematous appendix (80%). It was observed that majority of patients were having congested finding (96%), followed by perforated appendix (4%). The majority of patients were having inflamed appendix finding (92%), followed by appendicular perforation (4%). The histological findings showed 144 (96%) patients positive finding related to appendicitis as compared to radiological (82%).

The clinical accuracy was observed to be more as (sensitivity=92%) compared to radiological accuracy (sensitivity=82%) in the present study. In this study it was observed that positive predictive value is 97.97% and negative predictive value is 25%. The findings related to clinical presentation were compared with studies done by Richard Nshuti, they found sensitivity of clinical findings as 93%, Specificity (86%), PPV (93.3%) and NPV (66.7%).

## CONCLUSIONS

Acute appendicitis is the most common reason for emergency abdominal surgery and must be distinguished from other causes of abdominal pain. Atypical presentations are not uncommon as many inflammatory and noninflammatory conditions may mimic the presentation of acute appendicitis. This is especially seen in females and in the extremes of age. These and other factors resulted in the relatively high rate (15-30%) of negative explorations for acute appendicitis.

Family physicians play a valuable role in the early diagnosis and management of this condition, However, the overall diagnostic accuracy achieved by traditional history, physical examination, and laboratory tests has been approximately 80 percent. The ease and accuracy of diagnosis varies by the patient's sex and age, and is more difficult in women of childbearing age, children, and elderly persons. If the diagnosis of acute appendicitis is clear from the history and physical examination, prompt surgical referral is warranted. In atypical cases, ultrasonography and computed tomography (CT) may help lower the rate of false-negative appendicitis diagnoses, reduce morbidity from perforation, and lower hospital expenses. Ultrasonography is safe and readily available, with accuracy rates between 71 and 97

percent, although it is highly operator dependent and difficult in patients with a large body habitus. While there is controversy regarding the use of contrast media and which CT technique is best, the accuracy rate of CT scanning is between 93 and 98 percent. Disadvantages of CT include radiation exposure, cost, and possible complications from contrast media. Acute appendicitis is the most common surgical abdominal emergency with a lifetime prevalence of approximately one in seven.

The main stay of diagnosis is by through clinical evaluation by eliciting the different tests. Blood investigations like total WBC count, differential count and applying the latest system of Alvarado scoring were helpful in making an early diagnosis. This scoring system is a dynamic one, allowing observation and critical reevaluation of the evolution of the clinical picture. Its application improves diagnostic accuracy and consequently reduces negative exploration and complication rates.

When migration or shifting to right iliac fossa is present, appendicitis is likely, while absence of migration does not indicate a normal appendix. Anorexia, seems a reliable symptom and one should deeply inquire about this symptom. The severity and frequency of the vomiting indicates the degree of distension of the appendix and consequently the risk of perforation. Vomiting is earlier and continuous in the obstructive variety of appendicitis.

According to this study it has been proved that modified Alvarado scoring system is very useful scoring system for diagnosis of acute appendicitis. It can help in making early diagnosis and prevent further complications, reduce numbers of negative appendicectomies, it is better than other scoring systems because it includes wide spectrum of symptoms and signs and laboratory investigations and it will help in reducing necessity of ultrasonography and CT scan which has become nowadays gold standard for diagnosis of acute appendicitis.

Clinical accuracy was more in the study as compared to radiological methods. There is no advantage of ultrasound over the other methods for the diagnosis of acute appendicitis. Ultrasound is unnecessary when one's degree of clinical suspicion is high. However, the additional information provided by ultrasound does improve diagnostic accuracy in the case of a negative clinical diagnosis. Ultrasonography and plain X-ray of the erect abdomen were helpful in some of the doubtful cases but it doesn't replace the clinical skills of General Surgeons. The ultrasonography has made its dent in the confirming the diagnosis of an acute appendicitis. Acute appendicitis is more a clinical diagnosis rather than radiological. It is better to use radiological investigations only to confirm the diagnosis of acute appendicitis rather to diagnose it primarily because it is clear from the present study that a significant number of positive cases had been missed radiologically.

**CONFLICT OF INTEREST:** None to declare.

## REFERENCES

1. Fitz RH: Perforating inflammation of the vermiform appendix with special reference to its early diagnosis and treatment. *Trans. Assoc. Am. Physicians*, 1:107, 1886.
2. Humes and Simpson. Acute Appendicitis. –*BMJ*, 2006; 333(7567): 530.
3. Kanumba ES, Mabula JB, Rambau P, Chalya PL. Modified Alvarado Scoring System as a diagnostic tool for Acute Appendicitis at Bugando Medical Centre, Mwanza, Tanzania. *BMC Surgery*, 2011; 11: 4.
4. Hoffmann J, Rasmussen OO. Aids in the diagnosis of acute appendicitis. *Br J Surg*, 1989; 76(8): 774-9.
5. Beets GL, Beets-Tan RG. Mandatory imaging cuts costs and reduces the rate of unnecessary surgeries in the diagnostic work-up of patients suspected of having appendicitis. *Eur Radiol*, 2015; 25(5): 1464-70.
6. Xharra S, Gashi-LuciL, Xharra K, Veselaj F, Bicaj B, Sada F, Krasniqi A. Correlation of serum C-reactive protein, white blood count and neutrophil percentage with histopathology findings in acute appendicitis. *World J Emerg Surg*, 2012; 7(1): 27.
7. Richard Nshuti, Deirdré Kruger, and Thifheli E Luvhengo Clinical presentation of acute appendicitis in adults at the Chris Hani Baragwanath academic hospital. *Int J Emerg Med.*, 2014; 7: 12.
8. Dr. Sudershan Kapoor, Dr. Punit Kumar Dr. Ashish Kumar Sharma Acute Appendicitis: A Comparative Study of Clinical, Radiological and Operative Findings. *IOSR Journal of Dental and Medical Sciences*, 2016; 15(7): 36-42.
9. A. Gligorievski; Skopje/MK University Clinic of Radiology, Department of Abdominal Radiology. US diagnosis of acute appendicitis. Congress: ECR 2010.