wjpmr, 2018,4(5), 122-131

SJIF Impact Factor: 4.639

WORLD JOURNAL OF PHARMACEUTICAL AND MEDICAL RESEARCH

www.wjpmr.com

Research Article

ISSN 2455-3301

WJPMR

IS ATTENTION DEFICIT /HYPERACTIVITY DISORDER (ADHD) A DIAGNOSIS OR A SYMPTOM COMPLEX? EXPERIENCE FROM PEDIATRIC ORTHOPEDIC PRACTICE

Ali Al Kaissi*[1,2], Farid Ben Chehida[3], Vladimir Kenis[4], Wolfgang Brozek[1], Franz Grill[2], Rudolf Ganger[2], Susanne Gerit Kircher[5]

[1]Ludwig Boltzmann Institute of Osteology at the Hanusch Hospital of WGKK and AUVA Trauma Centre Meidling, First Medical Department, Hanusch Hospital, Vienna, Austria.
[2]Orthopaedic Hospital of Speising, Paediatric Department, Speisinger Str. 109, Vienna-1130, Austria.
[3]Ibn-Zohr center of Radiology and Imagings, Tunis, Tunisia.
[4]Pediatric Orthopedic Institute N.A. H. Turner, Department of Foot and Ankle Surgery, Neuroorthopaedics and Systemic Disorders, Parkovaya Str., 64-68, Pushkin, Saint-Petersburg, Russia.
[5]Institute of Medical Chemistry, Medical University of Vienna, Austria.

***Corresponding Author: Ali Al Kaissi**
Ludwig Boltzmann Institute of Osteology at the Hanusch Hospital of WGKK and AUVA Trauma Centre Meidling, First Medical Department, Hanusch Hospital, Vienna, Austria.

Article Received on 15/03/2018 **Article Revised on 05/04/2018** **Article Accepted on 26/04/2018**

ABSTRACT

Objective: Attention deficit hyperactivity disorder (ADHD) is a group of behavioral symptoms that include hyperactivity and impulsiveness. The etiological understanding is somehow controversial. We aimed to study the etiological understanding in a remarkable number of children and adults with various orthopedic problems in which (ADHD) was the earliest feature and was considered as a diagnosis. **Material and Methods:** 47 children and adolescent (5females and 42 males) of age range of (7-17 years) were sought in our departments from the period of 1998-2012. Prior to the development of variable forms of bone disorders, ADHD was the earliest feature. Clinical examination of parents and multigenerational family tree analyses was fundamental. Eventually phenotypic and genotypic correlation was the baseline tool of documentation. **Results:** ADHD was a symptom complex rather than a diagnosis in all patients we sought and a number of serious heritable disorders such as; hamartoneoplastic disorders (neurofibromatosis type I, NF-I) in 34 patients(72.3%), syndromic craniosynostosis (3MC, hypophosphataemic rickets) in 3 patients (6.4%) , mucopolysaccharidosis type II (Hunter syndrome) and type III (Sanfilippo syndrome) in one patient (2.1%) and 2 patients (4,3 %) respectively, and in 7 adult patients with XXY syndrome (14,9 %) were diagnosed accordingly. **Conclusion:** The term ADHD is classically used as a diagnostic entity in accordance and as defined by DSM-5. We wish to underline that these children were not referred to our departments on the premise that they were ADHD patients. The referral was because they starting to develop a diversity of skeletal deformities. Our task was to categorize these children in accordance with their phenotypic and genotypic correlation. Therefore, the usage of stimulant drugs should not be issued, unless a complete clinical documentation is established and the etiological understanding is reached. Our findings confirm the continuity of ADHD beyond the adolescent as a symptom complex rather than a diagnosis.

KEYWORDS: Attention deficit /hyperactivity disorder, Neurofibromatosis Type 1, Syndromic craniosynostosis, Mucopolysaccharidosis type II and III, XXY Syndrome.

INTRODUCTION

Attention-deficit/hyperactivity disorder (ADHD) describes a child who has a high level of physical activity because of a short attention span and persists over time leading to notable impairments. ADHD is thought to result from complex interactions between genetic and environmental factors.[1,2,3]

Symptoms of ADHD are continuously distributed throughout the population. The disorder is diagnosed by the severity and persistence of symptoms, which are associated with high levels of impairment and risk for developing co-occurring disorders.[2,3,4]

ADHD prevalence estimates are in the range of 2-12% in children.[5]

Evidence from family, twin, and adoption data suggested that ADHD is familial and heritable (75-91%).[3,4] At least 20 potential susceptibility genes have so far been studied in relation to ADHD (3-5).[3-5]

We usually receive full reports from the referral physicians which confirmed the diagnosis of ADHD and some of them were in fact have been prescribed brain stimulants. According to our knowledge, these physicians followed the guidelines for the diagnosis of ADHD (DSM-5). The DSM–5's classification involves a shift from the traditional categorical approach to a dimensional approach. The changes involving the removal of the legal problems criterion and the addition of a craving criterion were retained in the final revision of the diagnostic criteria.[6]

In skeletal deformities (especially those linked with syndromic entities) the age of presentation matters little, since these deformities can occur between the age of 0-70 years. These syndromic entities can be described as highly unpredictable and the guidelines shown in DSM-5 have limited role/ significance when it came to serious heritable disorders. Even, children whom showed similar presentation (e.g ADHD), the phenotype and the genotype are diverse and the spectrum is diverse. Thereby, ADHD symptoms can be connected to a wide spectrum of syndromic associations which have adverse impact on the development of the axial and the appendicular skeletal systems. From our experience, we roughly estimated, that more than 60% of pediatric admissions in our hospitals are strongly related to genetically-determined disorders. We consider children with frequent admissions to our departments as syndromic until proven otherwise.

The etiology and the pathogenesis of ADHD are controversial and simultaneously unclear. But, nevertheless, we believe that the clinical phenotype and the correlation with genotypic confirmation of these patients´ are a potential linkage with neurobehavioral functioning.

MATERIALS AND METHODS

The sum of 47 patients' of different ethnic origins (5 females and 42 males) of age range of (7-17 years) were sought and examined via phenotypic characterization followed by genotyping.

The study protocol was approved by Ethics Committee of the Turner Scientific Research Institute, No.3/2016, Saint-Petersburg, Russia) approved the study.

Informed consents were obtained from the patient's Guardians to publish. We analyzed these patients via the clinical and radiographic phenotypic characterization at the osteogenetic department of the osteogenetic department, Pediatric orthopedics (Speising Hospital, Vienna, Austria) and international collaboration with clinicians and scientists from Pediatric orthopedic Surgery, Children Hospital, Tunis. The sum of 47 patients' of different ethnic origins (5 females and 42 males) of age range of (7-17 years) were sought and examined via phenotypic characterization followed by genotyping.

The diagnosis of ADHD was based primarily on information and reports provided by the referring pediatricians and clinicians who supposedly reviewed and assessed every case according to the guidelines based on the criteria applied by the variable committees. Mostly these patients were assessed via the DSM-5, but no clinical phenotypic evaluation and or clinical documentation was considered in their assessment. Factors such as concentration, attention, and interest were the main guideliness and were given the priority in classifying these patients within the category of ADHD.Sadly speaking, the clinical phenotypes were completely ignored and the inter-family differences in disease severity were omitted as well.

The Diagnostic and Statistical Manual of Mental Disorders, (DSM-5), was the only tool applied in accordance with the referral reports from clinicians. These reports stated that six and in some more than six symptoms were present. The children group of patients have been discribed as, often fidgets with hands or feet or squirms in seat, and leaves seat in classroom or in other situations in which remaining seated and they often runs about or climbs excessively in situations in which it is inappropriate. Difficulty in sustaining attention, easily distracted, careless mistakes, extreme difficulties to follow instructions, massive disorganization, avoid tasks, and forgetfull in daily activities. The above mentioned criteria have been considered by (DSM-5) as the baseline tool to establish the diagnosis of ADHD. In addition, the reports we received from the clincians , all were describing hyperactive/impulsive, difficulties in remaing seated, extreme restlessness, difficulties in being engaged in daily activities, blurt out answers before questions have been completed. All these patients (children and adults) were bound to be disadvantaged in learning situation. In addition to slow language development and this was explained by the clinicians as directely related to bahavioural problems. In adolescents/ adult group of patients, this has been described as subjective to feelings of restlessness in conjunction with the above criteria in their childhood period.

In accordance to the guidelines listed by DSM-5, these patients were given the diagnosis of ADHD. Like any other orthopaedic hospitals, diverse forms of orthopaedic problems were the incentive of these families to seek advice. But, nevertheless, children with frequent hospital admissions were given high priority for a comprehensive studies and phenotypic characterization. We subdivided our patients in accordance with the clinical presentation at the departments of orthopaedics

RESULTS

In the light of our methodology which is based on individualistic assessment via clinical and radiographic phenotypic characterizations. We subsequently, subdivided our patients into two main groups in connection with the form of the heritable disorder. The categorization was based up on the definite clinical and

radiographic phenotype /genotype correlation and two groups were established. Group 1 included children and adults with a history of ADHD. But; nevertheless, Neurofibromatosis (NF-1) type- I was diagnosed (phenotype/genotype) confirmation and 34 patients have been diagnosed (72.3%), age range of 7-16 years presented with variable of skeletal deformities which require long-term hospital management have been diagnosed. Limb length discrepancy, unilateral incurvation of the right lower limb (particularly of the tibia and fibula) associated with unilateral macrodactyly in a-13-years-old-boy with (NF-1) **(figure 1).** Interestingly, the family histories of patients with (NF-1) revealed; primary unexplained sterility, multiple spontaneous abortions, stillbirths, sudden infant death syndrome, migraine (abdominal in paediatric group and cephalic in the adult group), sleep disturbance, cerebral aneurysm, mental handicap, epilepsy, diabetes mellitus type 2, and astrocytoma). Neurofibromatosis type I was conformed as a diagnostic entity and genetic counselling was arranged accordingly (table 1). Group 2 included 13 children and adults with a history of ADHD (age range of 7-17 years). Included syndromic craniosynostosis (3MC) (fig 2,3,4) ; a-10-years-old- girl presented with Legg-Calve-Perthes disease (figure 5); hypophosphataemic rickets) in 3 patients (6.4%) (figure 6), mucopolysaccharidosis type II (Hunter syndrome) and type III (Sanfilippo syndrome) in one patient (figure 7,8) (2.1%) and 2 patients (4.3%) respectively, and in 7 adult patients with XXY syndrome (figure 9,10) (14.9%) . Other orthopedic presentations such as fractures, and chronic osteomyelitis of the calcaneus, carpal tunnel syndrome, hip pain, scoliosis and early onset osteoarthritis have been recorded. All these deformities underwent clinical, radiographic documentations. The latter was followed by comprehensive genotypic confirmation. A list of variable syndromic entities were thereby diagnosed and listed in (table 2)

Table 1: 34 patients (age range of 7-16 years), all with a history of ADHD, diagnosed with NFI through the phenotype /genotype correlation of NF-1 (74.3%).

Age and sex	First presentation and family history	Orthopaedic problems	Phenotypic and genotypic correlation
Five boys (age range 8-12-years)	Poor concentration and behavioral disorders- maternal history of still-births and sudden infant death syndromes was observed in four families.	Genu varum(bow-legs)	NF-1 (mutation in the neurofibromin gene (NF1 on chromosome 17q11.2)
Two boys of 7 and 9 years -old	Hyperactivity and poor concentration – Migraine was observed in two families. One grandfather with cerebral aneurysm	Pseudo-arthrosis of the clavicle	NF-1 (mutation in the neurofibromin gene (NF1 on chromosome 17q11.2)
Seven boys (age range 8-10) and two girls of 7 and 10 years	Hyperactivity and impulsive behavior- In three families sibling with severe mental handicap and epilepsy	Frequent fractures of the elbows	NF-1 (mutation in the neurofibromin gene (NF1 on chromosome 17q11.2)
Nine boys (age range of 12-16-years)	Hyperactivity and cognitive disorders-3 Mothers had a history of diabetes mellitus type 2 and learning disabilities, and manifested the full clinical criteria of NF-I	Pre-adolescent and adolescent scoliosis	NF-1 (mutation in the neurofibromin gene (NF1 on chromosome 17q11.2)
Seven boys (age range of 7-12 years)	Learning disabilities and impulsive disorder-One parent operated for astrocytoma (no associated café-au-lait spots) but grandfather manifested the full picture of NF1	Limb-length discrepancy	NF-1 (mutation in the neurofibromin gene (NF1 on chromosome 17q11.2)
Two boys of 9 and 13 years old	Hyperactivity, and sleep disturbance, three families still births, and sudden infant death syndrome were registered.	Macrodactyly	NF-1 (mutation in the neurofibromin gene (NF1 on chromosome 17q11.2)

Abbreviations: NF1=Neurofibromatosis type I

Table 2: Diverse forms of syndromic associations in 13 children (age range 7-17) in correlation with ADHD: Syndromic craniosynostosis (3MC, hypophosphataemic rickets) in 3 patients (6.4%) , mucopolysaccharidosis

type II (Hunter syndrome) and type III (San-Filipo syndrome) in one patient (2.1%) and 2 patients (4.3%) respectively, and in 7 adult patients with XXY syndrome (14.9%).

Age and sex	First presentation and family history	Orthopaedic problems	Final diagnosis
7-years-old boy	Hyperactivity and learning disabilities-parents are first degree related with a history of perinatal mortalities	Radio-ulnar synostosis	3MC syndrome-mutated genes, COLEC11 resp. MASP1 (fig 2)
10-years-old girl	sleep disturbance and poor concentration- parents are first degree related with a history of perinatal mortalities	Legg-Calve-Perthes disease-like	3MC syndrome-mutated genes, COLEC11 resp. MASP1 (fig 3)
7 years-old-boy	Hyperactivity- family history of bowing of the long bones	Blount's disease (skeletal survey and laboratory tests revealed hypophosphataemic rickets	Early onset-Craniosynostosis in connection with PHEX-gene mutation
12-years-old girl	Progressive intellectual decline resulting in severe dementia, sleep disturbance and progressive motor disease (parents are first cousins)	Frequent wrist fractures because of excessive motor hyperactivity	Mucopolysaccharidosis type III A with deficiency of heparan sulfatase
15-years-old-girl	Behavioral aberrations started at the age of 4 years, sleep disturbance and poor social contacts (parents are first cousins)	Chronic osteomyelitis of the calcaneus	Mucopolysaccharidosis type III B (mutation of *the NAGLU gene*) with deficiency of alpha-N-acetylglucosaminidase.
17-years-old-boy	Progressive poor concentration, hyperactivity and progressive mixed hearing loss	Carpal tunnel syndrome	Mucopolysacharidosis type II-Hunter syndrome (Increased excretion of dermatan sulfate and heparan sulfate) –low activity of iduronate-2-sulfatase in serum
Seven boys age range of 12-16 years	Tall stature (above 97 the percentile), poor concentration, inattentiveness and impulsiveness , hyperactivity and aggressiveness	Frequent fractures of the elbows, wrists, hip pain, scoliosis in two subjects, subluxation of the hip, early onset osteoarthritis in two subjects	47 XXY syndrome

Abbreviations: MPS type IIIB (mucopolysaccharidosis- Sanfilippo syndrome), 3MC syndrome= Unifying Carnevale, Mingarelli, Malpuech and Michels syndromes, DSM-5=The Diagnostic and Statistical Manual of Mental Disorders, NICE guidelines= National Institute for health and Care Excellence (NICE) guidelines, COLEC11 and MASP1= encode components of the lectin complement pathway, PHEX = Phosphate-regulating neutral endopeptidase

Figure 1: A-11-year-old boy with a history of ADHD presented with unilateral incurvation of the right lower limb (tibia and fibula), limb length discrepancy, and unilateral macrodactyly. The diagnosis of *NF1* (on chromosome 17q11.2) has been confirmed accordingly.

Figure 2: A-10-year-old-boy with a history of ADHD, the child presented to our department because of unilateral radio-ulnar synostosis.

Figure 3: 3D –CT scan based phenotype showed abnormal cranio-facial contour because of synostosis of the lamdoid sutures (b). Phenotype-genotype was consistent with the diagnosis of 3MC syndrome (3MC syndrome-mutated genes, *COLEC11 and MASP1*).

Figure 4: 3D –CT scan based phenotype showed abnormal cranio-facial contour because of synostosis of the lamdoid sutures. The phenotype-genotype was consistent with the diagnosis of 3MC syndrome (3MC syndrome-mutated genes, *COLEC11 and MASP1*).

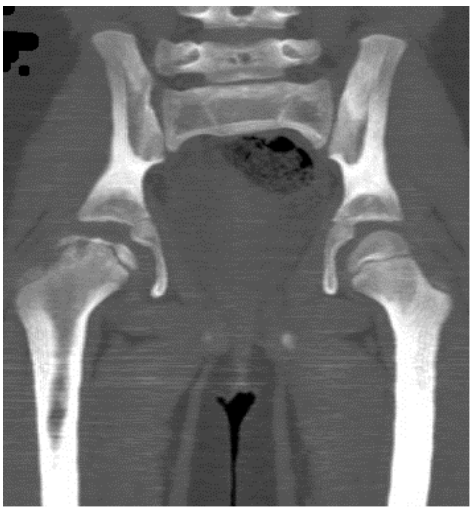

Figure 5: A 10-years-old-girl with a history of sleep disturbance, poor concentration, presented in our department because of antalgic gait secondary to Legg-Calve-Perthes disease-like was evident. 3D CT scan showed unilateral fragmentation of the right capital femoral epiphysis.

Figure 6: A-9-year-old-boy with a history of poor schooling achievement and ADHD, anteroposterior skull radiograph showed progressive sclerosis of the calvaria involving the sutures. His clinical/radiological phenotype and genotype were consistent with the diagnosis of X-linked hypophosphataemic rickets (early onset-Craniosynostosis in connection with *PHEX-gene* mutation).

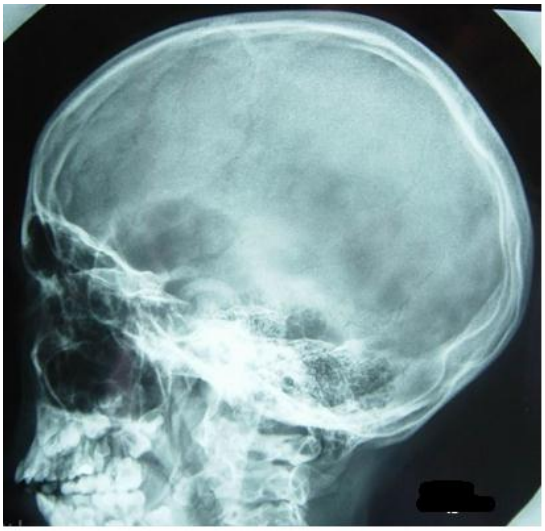

Figure 7: A-13-years-old-girl with was diagnosed with ADHD, presented with osteomyelitis of the calcaneus. Clinical and radiographic phenotypic characterizations and genotype were consistent with the diagnosis of MPS-type III-B (Sanfilipo syndrome)- mutation of *the NAGLU gene located on chromosome 17q21.1*) with deficiency of alpha-N-acetylglucosaminidase).

Figure 8: Lateral skull radiograph of the same girl with MPS type III showed sclerosis of the Calvaria and hyperostosis of the skull base with a large sella turcica.

Figure 9: XXY syndrome in a-17-year-old-boy presented with early osteoarthritis (and has been treated for ADHD since the age of 9-years). His head circumference was at the 25 th percentile and his height was above the 97 th percentile. Lateral skull radiograph showed that the facial bones are almost equal to the size of his cranium. The cervical vertebrae are large and compatible with his tall stature *(47 XXY)*.

Figure 10: XXY syndrome in a-17-year-old-boy presented with early osteoarthritis and has been treated for ADHD since the age of 9-years. AP pelvis radiograph showed coxa vulga and progressive narrowing of the hip joints. Antalgic gait was the reason for his consultation (*47 XXY)*.

DISCUSSION

ADHD is one of the most common neurodevelopmental disorders in children, affecting both boys and girls, and continuing into adulthood in many patients.[1] Hyperactivity or hyperkinetic syndrome can affect children of varying intellectual levels, and if it is due to a failure of normal development, it does have similarities to specific learning disorders. It is often found among children with other learning disabilities, such as multiple handicaps resulting from a common etiology. Hyperkinesia refers to a psychiatric syndrome of children with hyperactive and inattentive behaviour. It implies that the condition is not just a feature of the child´s reactions to situations but is severe and pervasive. The behaviour occurs in all situations regardless who is present. The behaviour is handicapping to the child both socially and academically. These children also frequently show delays in intellectual development with clumsiness and speech delay.[2,3]

Some overactive children may be under-stimulated, but probably only if they are also anxious. Experimental evidence has shown a diminished response of the autonomic nervous system in these children compared with controls, but it is possible that these findings are the result of the emotional complications rather than primary cause of the over-activity.[6,7,8]

To compare our findings with what has been published, we firstly have to explore the depth of the previous studies and to what extent it expresses genuine results and how far it could help to elicit the underlying

pathologies in these children.[1,5,6,13] The most practiced guidelines by vast majority of psychiatrists and physicians for the diagnosis of ADHD, is what has been emerged from UK´s National Institute for health and Care Excellence (NICE) guidelines. It considered, symptoms of hyperactivity/impulsivity and /or inattention should meet the diagnostic criteria in the Diagnostic and Statistical Manual of Mental Disorders, Fourth Edition(DSM-IV) or the international statistical classification of diseases and related health problems (10th Revision-ICD-10) (hyperkinetic disorders). The guidelines described ADHD as a diagnostic entity which should be associated with at least moderate psychological, social and /or occupational impairment and occur in two or more important settings including social, familial, educational and /or occupational settings. NICE guidelines and the recently published Diagnostic and Statistical Manual of Mental Disorders, Fifth Edition (DSM-5).[6] The DSM-5 differs from its predecessor in requiring several inattentive or hyperactive symptoms to be present before 12 years of age, compared with the presence of symptoms that cause impairment prior to the age of 7 years in DSM-IV (American Psychiatric Association2013) (5-12). None of the above mentioned guidelines provide compelling data in favor of patient´s clinical phenotype, syndromic associations and or the role of heritable disorders.

The spectrum of learning deficits includes abnormalities in visual-motor integration, visual –spatial judgment and visual-perceptual skills, such that children with NFI perform worse than control children on the judgment of line orientation test, the Beery Visual-Motor Integration Test and the Recognition-Discrimination test.[14,15]

Brown et al,[16] established a new GEM model of NF1-associated attention deficits and have identified the neurochemical defect underlying this abnormality. The discovery of reduced dopaminergic pathway integrity and resulting decreased DA levels provides a mechanistic explanation for the observed attention system abnormalities in mice, and supports the clinical utility of MPH and related drugs for the treatment of attention system dysfunction in children with NF1.

Craniosynostosis refers to the premature fusion of one or more of the sutures that normally separate the bony plates of the infant's skull. Multiple-suture fusions are associated with several well-described genetic syndromes—including Apert, Crouzon, Pfeiffer, Saethre Chotzen, and Carpenter syndromes—which have been associated with elevated rates of mental retardation and learning disabilities.[17] Speltz et al.[18] reviewed 17 studies of the hypothesized association between isolated craniosynostosis and neurodevelopment. They found that isolated craniosynostosis is associated with three-to fivefold increase in risk of cognitive deficits or learning/language disabilities. We encountered two siblings with syndromic craniosynostosis of 3MC syndrome which was proposed as a unifying term to integrate the overlapping Carnevale, Mingarelli, Malpuech and Michels syndromes. These rare autosomal Recessive disorders comprise a spectrum of developmental features including characteristic facial dysmorphism, cleft lip and/or palate, craniosynostosis, learning disability, and genital, limb and vesicorenal anomalies. The identification of two genes, mutations in which cause the above mentioned disorders, namely COLEC11 and MASP1, encode components of the lectin complement pathway thus implicating this diverse inflammation/chemotaxis cascade in the aetiology of human developmental disorders. Two siblings presented with radioulnar synostosis and Legg-Calve-Perthes disease-like. Both had a history of learning difficulties and ADHD.[19,20]

Similarly, other two siblings with craniosynostosis, learning difficulties, and ADHD have been diagnosed with hypophsophataemic rickets. Blount´s disease and frequent wrist fractures were the prime orthopedic problems. Skeletal survey revealed craniosynostosis of the sagittal suture causing effectively the development of scaphocephaly. Metabolic parameters were in favor of hypophosphataemic rickets. Genetic tests showed a loss-of-function mutation in PHEX gene disrupts this interaction leading to hypophosphatemic rickets.[21]

Mucopolysaccharidosis type III (MPS III, Sanfilippo syndrome) is an autosomal recessive disorder, caused by a deficiency in one of the four enzymes involved in the lysosomal degradation of the glycosaminoglycan heparan sulfate. Based on the enzyme deficiency, four different subtypes, MPS IIIA, B, C, and D, are recognized. The basic clinical features are a combination of severe and progressive mental retardation with relatively mild somatic features and without corneal clouding. All types of MPS III are characterized by progressive mental deterioration and behavioral problems with mild dysmorphic facial features and mild somatic signs. Based on the relevant enzyme deficiency, four types have been recognized: heparan N-sulphatase is deficient in type A, α–N- acetylglucosaminidase in type B, acetyl-CoA α-glucosamide acetyltransferase in type C, and N- acetyl glucosamine 6-sulphatase in type D. This group of disorders primarily affect the central nervous system.[22]

All types of MPS III are characterized by progressive mental deterioration and behavioural problems with more or less prominent dysmorphic facial features and mild somatic signs.[21]

In the early psychomotor development of patients with MPS IIIA, B, and C, the acquisition of sitting and unassisted walking were within normal parameters, as previously described. At 18 months of mean age, mild speech delay, without any new words was evident in most patients, corresponding to the onset of the first phase of the disease.[23]

Two unrelated patients presented the different orthopedic abnormalities of wrist fractures (type III A) and chronic osteomyelitis in type (IIIB). Both had a history of progressive mental deterioration, sleep disturbances and behavior al problems and were labeled as ADHD.

The recent development of BMN 250, is a novel fusion of alpha-N-acetyglucosaminidase (NAGLU) which is a peptide derived from insulin-like growth factor 2 (IGF2). Is an enzyme replacement therapy for the treatment of Mucopolysaccharidosis IIIB (Sanfilippo Syndrome Type B). BMN 250 is delivered directly to the brain using BioMarin's patented technology. The animal studies showed that the intracellular storage was cleared with NAGLU-IGF2 treatment which is a promising medication to translate well in clinical practice.[23-25]

Mucopolysaccharidosis type II (MPS II, Hunter syndrome) is an X-linked multisystemic disorder characterized by glycosaminoglycans (GAG) accumulation. The vast majority of affected individuals are male. Age of onset, disease severity, and rate of progression vary significantly. In those with severe disease, CNS involvement (manifest primarily by progressive cognitive deterioration), progressive airway disease, and cardiac disease usually result in death in the first or second decade of life. In those with attenuated disease, the CNS is not (or is minimally) affected, although the effect of GAG accumulation on other organ systems may be just as severe as in those who have progressive cognitive decline. One boy presented with carpal tunnel syndrome associated with characteristic dysmorphic facial features and mild skeletal pathology. Investigations showed increased excretion of dermatan sulfate and heparan sulfate and low activity of iduronate-2-sulfatase in serum which were compatible with the diagnosis of MPS II-Hunter syndrome.[25,26]

47 XXY syndrome is characterized by an extra copy of the Y chromosome in each of a male's cells. Although males with this condition may be taller than average, this chromosomal change typically causes no unusual physical features. The cognitive phenotype of XXY including language-based learning difficulties and mild deficits in general cognitive ability as measured by full-scale IQ and the behavioural features described in XXY include increased risk of impulsivity and difficulties related to behavioural dysregulation.[27-29]

CONCLUSION

Attention-deficit/hyperactivity disorder is highly prevalent in children worldwide, and the prevalence of this disorder in children and adults is increasingly recognized. The early diagnosis of ADHD in children is done in primary care clinics. Nevertheless, the etiological background of ADHD is diverse and there is no unique phenotype-genotype correlation. Comprehensive clinical assessment of ADHD is not just observational; it represents a real challenge and requires appropriate knowledge in clinical phenotypic characterization. Knowledge stem from appropriate understanding of the clinical phenotype of every given case, since it can provide novel insights to assess ADHD and to reformulate the current methodology of management. Researchers need to perceive the diverse and the broad spectrum of clinical presentations in ADHD patients, and therefore the necessity to keep a firm hold on the impact of clinical aspects and to anticipate the far-reaching conceptual consequences. We believe that the accuracy of clinical diagnosis is a baseline tool to predict outcomes and it is the only route to guide the geneticists, and consequently to determine prognosis and designing treatment in every given case. Also the hypotheses emerged from research studies in children with ADHD assumed that the application of molecular diagnostics might be the solution. We consider such hypotheses as a short-sighted strategy, simply because the diversity of the underlying pathologies of ADHD is enormous. We wish to underline that these children were not referred to us based on the premise that they were ADHD patients. Our specialty does not allow us to debate or question the validity of their diagnosis of ADHD. These children were referred to us, because they were starting to develop different skeletal deformities. Psychiatrists and neurologists and other clinicians have limited knowledge as far as phenotypic characterization is concerned, therefore it is common that we encounter an important number of patients referred to our department with partial diagnosis.

This paper departs from the assumption that the ADHD diagnosis of these children is valid. The main purpose of this paper is to stress that ADHD is a symptom complex, and is not an isolated diagnosis. Our clinical documentation started in 1998, until the end of 2012. Each case was clinically documented via phenotypic characterization, followed by genetic testing to confirm our findings. My position as a consultant and specialized in bone disorders in two departments (Depatment of paediatric orthopaedic surgery, Children Hospital, Tunis and simultaneously consultant at the Paediatric orthopaedic surgery-orthopaedic hospital of Speising, Vienna, Austria) gave full access to all sorts of congenital orthopaedic abnormalities regardless the age. In general, we document hundreds of patients every year (Tunisia, Austria, Saint-Petersburg Russia and others). The necessity of establishing the phenotype/genotype correlation is the cornerstone in the management of the deformities in our department. Neuro-Cutaneous disorders (NF1), Craniosynostosis, MPS, and chromosomal abnormalities (XXY) which have all been confirmed by genetic and cytological studies, have all proven to be linked to ADHD. Patients with Fragile X syndrome for instance who were treated as ADHD patients were not included in our study (because of logistical reasons their genetic tests were not conducted).

ACKNOWLEDGMENT

We wish to thank Mr. Hamza Al Kaissi student at the Slovak Medical University, Bratislava for his help in translating the German literature.

CONFLICTS OF INTEREST

The authors declare that there are no conflicts of interest related to the subject matter or materials discussed in this article.

Contribution: All authors participated in writing and data analysis of the MS.

Abbreviations: ADHD=Attention deficit hyperactivity disorder, NF1=Neurofibromatosis type 1, MPS type III (mucopolysaccharidosis III – Sanfilippo syndrome), 3MC syndrome= Unifying Carnevale, Mingarelli, Malpuech and Michels syndromes, DSM-5=The Diagnostic and Statistical Manual of Mental Disorders, NICE guidelines= National Institute for health and Care Excellence (NICE) guidelines, COLEC11 and MASP1= encode components of the lectin complement pathway, PHEX = Phosphate-regulating neutral endopeptidase

Ethics Committee: The study protocol was approved by Ethics Committee of the Turner Scientific Research Institute, No.3/2010, Saint-Petersburg, Russia) approved the study. Informed consents were obtained from the patient's Guardians to publish. We analysed these patients via the clinical and radiographic phenotypic characterization at the osteogenetic department of the Orthopaedic Hospital of Speising, Vienna, Austria and at the department of Foot and Ankle Surgery, Neuroorthopaedics and Systemic Disorders, Parkovaya str., 64-68, Pushkin, Saint-Petersburg, Russia.

International collaboration was with clinicians and scientists from Paediatric Orthopaedic surgery department, Children Hospital, Tunis (Medical Committee Chairman-Prof. Maher Ben Ghachem 1998-2007) in addition informed consents were obtained from the patient's guardians.

REFERENCES

1. American Psychiatric Association. *Diagnostic and Statistical Manual of Mental Disorders*, 4th edn, revised. *American Psychiatric Press: Washington*, DC, 2000.
2. Didoni A, Sequi M, Panei P, Negri M, Bonati M. One-year prospective follow-up of pharmacological treatment in children with attention-deficit/hyperactivity disorder. Eur J Clin Pharm, 2011; 67(10): 1061-67.
3. Taylor E A. The overactive child. Clinics in Developmental Medicine no. 97, 1986.
4. Thapar A, Langley K, Asherson P, Gill M. Gene-environment interplay in attention-deficit hyperactivity disorder and the importance of a developmental perspective. *Br J Psychiatry*, 2007; 190: 1-3.
5. Chen W, Zhou K, Sham P, Franke B, Kuntsi J, Campbell D, et al. DSM-IV combined type ADHD shows familial association with sibling trait scores: a sampling strategy for QTL linkage. *Am J Med Genet B Neuropsychiatr Genet*, 2008; 147B: 1450-60.
6. The Diagnostic and Statistical Manual of Mental Disorders. 5th ed.; *DSM–5*, American Psychiatric Association, 2013.
7. Shapiro BK, Palmer FB, Capute AJ. The early detection of mental retardation. *Clinical Pediatrics*, 1987; 26: 215–220.
8. Conners CK. Learning disabilities and stimulant drugs in children, theoritical implications. In: Knight RM, Baker DJ (eds). The neurophysiology of learning disorders. University Park Press, London, 1976.
9. Kendall T, Taylor E, Perez A, Taylor C, on behalf of the Guideline Development Group. Diagnosis and management of attention-deficit/hyperactivity disorder in children, young people, and adults: summary of NICE guidance. BMJ, 2008; 337: 1239.
10. Burt SA. Rethinking environmental contributions to child and adolescent psychopathology: a meta-analysis of shared environmental influences. *Psychol Bull*, 2009; 135: 608–637.
11. Swanson JM, Hinshaw SP, Arnold LE, Vitiello B, Abikoff HB and et al. Secondary evaluations of MTA 36-month outcomes: propensity score and growth mixture model analyses. *J Am Acad Child Adolesc Psychiat*, 2007; 46: 1003-14.
12. van den Berg SM, Willemsen G, de Geus EJ, Boomsma DI. Genetic etiology of stability of attention problems in young adulthood. *Am J Med Genet B.*, 2006; 141B: 55–60.
13. Santosh P, Taylor E, Swanson J, Wigal T. Refining the diagnoses of inattention and overactivity syndromes. A reanalysis of the multimodal Treatment study of attention deficit hyperactivity disorder (ADHD) based on ICD-10 criteria for hyperkinetic disorder. *Clin Neurosci Res*., 2005; 5: 307-14.
14. Dawei Li1, Pak C. Sham, Michael J. Owen and Lin He. Meta-analysis shows significant associationbetween dopamine system genes and attention deficit hyperactivity disorder (ADHD). *Human Molecular Genetics*, 2006; 15(14): 2276–84.
15. Chen CK, Chen SL, Mill J Huang YS, Lin SK, Curran S, Purcell S, Sham P. and Asherson P. The dopamine transporter gene is associated with attention deficit hyperactivity disorder in a Taiwanese sample. *Mol. Psychiat*, 2003; 8: 393–96.
16. Brown A J, Emnett J R, White R C, Yuede M C, Conyers B S, O'Malley L K et al. Reduced striatal dopamine underlies the attention system dysfunction in neurofibromatosis-1 mutant mice. Human Molecular Genetics, 2010; 19(22): 4515–28.
17. Cohen MM, Jr. Syndromes with craniosynostosis. In: Cohen MM Jr, editor. Craniosynostosis:

Diagnosis, Evaluation and Management. New York: Raven Press., 1986: 413-590.
18. Speltz L M, Kapp-Simon A K, Cunningham M, Marsh J, Dawson G.Single-Suture Craniosynostosis: A Review of Neurobehavioral Research and Theory. *J Pediatr Psychol*., 2004; 29(8): 651-68.
19. Al Kaissi A, et al. Asymmetrical skull, ptosis, hypertelorism, high nasal bridge, clefting, umbilical anomalies, and skeletal anomalies in sibs: is Carnevale syndrome a separate entity? Am J Med Genet A., 2007; 143: 349–54.
20. Rooryck C, Diaz-Font A, Osborn DP, Chabchoub E, Hernandez-Hernandez V, Shamseldin H, et al. Mutations in lectin complement pathway genes COLEC11 and MASP1 cause 3MC syndrome. *Nat Genet*, 2011; 43(3): 197-203.
21. Carlsen NL, Krasilnikoff PA, Eiken M. Premature cranial synostosis in X-linked hypophosphatemic rickets: possible precipitation by 1-alpha-OH-cholecalciferol intoxication. Acta Paediatr Scand, 1984; 73: 149-54.
22. Neufeld EF, Muenzer J: The mucopolysaccharidoses. In The metabolic and molecular basis of inherited disease. 8th edition. Edited by Scriver CR, Beaudet AL, Sly WS, Valle D. New York: McGraw-Hill, 2001: 3421–52.
23. Wijburg F, Wezgrzyn G, Burton KB, Tylki-Szymanska A, Mucopolysaccharidosis type III (Sanfilippo syndrome) and misdiagnosis of idiopathic developmental delay, attention deficit/hyperactivity disorder or autism spectrum disorder. *Acta Paediatr*, 2013; 102(5): 462–70.
24. White KK, Karol LA, Ehite DR, Ehite DR, Hale S: Musculoskeletal manifestations of Sanfilippo syndrome (mucopolysaccharidosis type III). *J Pediatr Orthop*, 2011; 31(5): 594–98.
25. Mika Aoyagi-Scharber, et al. BioMarin Pharmaceutical Inc.; Department of Pediatrics, Los Angeles Biomedical Research Institute at Harbor-UCLA Medical Center. *Engineering of a* recombinant NAGLU fusion protein with insulin-like growth factor 2 leads to improved cellular uptake via glycosylation-independent lysosomal targeting pathway. Poster presentation by BioMarin on February 11, 2014.
26. Muenzer J, Beck M, Eng CM, Escolar ML, Giugliani R, Guffon NH, et al. Multidisciplinary management of Hunter syndrome. Pediatrics, 2009; 124: e1228–39.
27. Ratcliffe SG. Speech and learning disorders in children with sex chromosome abnormalities. Dev Med Child Neurol, 1982; 24(1): 80–4.
28. Netley CT. Summary overview of behavioural development in individuals with neonatally identified X and Y aneuploidy. Birth Defects. Orig Artic Ser., 1986; 22(3): 293–306.
29. Fryns JP, Kleczkowska A, Kubie_n E, Van den Berghe H. XXY syndrome and other Y chromosome polysomies. Mental status and psychosocial functioning. Genet Couns, 1995; 6(3): 197–206.