

## HISTOCHEMICAL STUDIES ON GILLS OF THE FRESHWATER MURREL FISHES *CHANNA STRIATUS* AND *CHANNA PUNCTATUS* (BLOCH) INFECTED WITH BACTERIAL AND FUNGAL STRESS INDUCED EPIZOOTIC ULCERATIVE SYNDROME (EUS)

Dr. Koteswar Rao Podeti\* and Benarjee G.

Fisheries Research Laboratory, Department of Zoology, Kakatiya University – 506 009.

\*Corresponding Author: Dr. Koteswar Rao Podeti

Fisheries Research Laboratory, Department of Zoology, Kakatiya University – 506 009.

Article Received on 13/03/2018

Article Revised on 03/04/2018

Article Accepted on 24/04/2018

### ABSTRACT

Histochemistry has contributed a great deal not only to the understanding of biological phenomenon but also to clinical medicine. Histochemical techniques help to analyze not only the localization of protein, lipid and glycogen etc, but also molecular changes at cellular level. The main advantage of histochemistry lies in the analysis of biological phenomena in the "particular cells". The present investigation deals with the histochemical nature of the gills of *Channa striatus* and *Channa punctatus* infected with bacteria *Aeromonas hydrophila*, *Pseudomonas aeruginosa* and fungi like *Aspergillus flavus*, *Fusarium solani*, *Rhizopus stolonifer* and *Penicillium chrysogenum* in order to discuss, the comparison between the control and infected gills. In the freshwater fishes of gills are the important organs for respiration and osmoregulation. The gills in a number of fishes show considerable modification with changes in oxygen environment and function in combination with other respiratory structures in the exchange of gases. The indiscriminate use of insecticides in agriculture on variety of crops, pollutants the surrounding water resources, such as lakes and rivers seriously damage of the aquatic fauna. The intake of pollutants variously affect the fish, the gills become more exposed because of their location and constant intimate contact with the water and are liable to damage by any irritant material.

**KEYWORDS:** Histochemistry, Gills, *Aeromonas hydrophila*, *Penicillium chrysogenum*.

### INTRODUCTION

The gills are the chief respiratory organs in fish gills exchange oxygen and carbon dioxide by diffusion method between blood and water. Gill slits or gill clefts are formed by the perforation on the lateral wall of the pharynx. The anterior and posterior walls of each gill cleft are raised in the form of vascular filamentous outgrowths to form the gills, where exchange of dissolved oxygen and carbon dioxide takes place, besides the gills, other accessory organs also function as respiratory structures in *C. striatus* and *C. punctatus*. The histological structure of the gills in *C. gachua* shows that gills are covered externally by an operculum. They are holobranch type, comprising reduced interbranchial septum supported by a cartilage. Gills are four pairs and two rows of primary gill lamellae are born by the ceratobranchial and epibranchial segments of each gill arch. The interbranchial septum between the two rows of lamellae is short, so that the lamellae of the two rows are free at their distal ends.

The gill lamellae are supported by gill rays which are partially bony and are connected to the gill arch and with each other by fibrous ligaments. Each gill ray is

bifurcated at its proximal end provides a passage for the efferent branchial vessel. Each hole-branch carries two hemi branches or half gills. Each hemi branch comprises a row of long thin filaments or primary gill lamellae. Each primary lamella bears a large number of secondary lamellae on both sides. The secondary lamellae are free from each other but fused at the distal ends of the primary lamellae. Each secondary lamella consists of a central vascular layer surrounded by a thin layer of connective tissue and epithelium. The vascular layer consists of a network of capillaries supported by the so-called pilaster cells. The flat leaf-like structures are the main seat of gaseous exchange. The gill head is covered over by a thin epithelium in which a large number of mucous glands are present. Thus, the structure of the gill in fish is such that water is brought in close contact with the secondary lamellae. In *C. striatus* and *C. punctatus* the pharynx develops a sac-like diverticulum to store air for some time for gaseous exchange. The epibranchium of the first gill arch is covered by a thin vascular respiratory membrane. It also bears a folded and highly inched respiratory labyrinthine organ for the purpose of accessory respiration.

## MATERIAL AND METHODS

The freshwater fish's material for the present study was collected from different lakes of Hasanparthy, Dharmasagar and Bandham resources in Warangal district, Telangana, India. The *Channa striatus* and *Channa punctatus* control and EUS infected fish samples were collected and the specimens were obtained alive by using fishing net, and they were brought immediately to the laboratory, in plastic containers with oxygen filled water. The specimens were deeply anaesthetized by immersion into 5 ml/L aqueous solution of ethylene glycol monophony ether. (Figure. 1. *C. striatus* and Figure. 2. *C. punctatus*). To study the gross anatomy of different regions of the dissected tissue parts of gills were carefully removed and small pieces were taken to obtain proper fixations. For the histochemical studies the required tissues were removed and the blood vessels and mucous attached to them were scrapped off smoothly without damaging the original structure. The tissues collected for the present study. The procedure followed for preparation of histological sections and for histochemical analysis of different substances is similar to all the tissues. The tissues collected from control and infected fishes were immediately fixed and processed. The fixatives used in the present study were Alcoholic Bouin's, Susa, Carnoy and Zenker. Muco polysaccharides. Susa and Carnoy for muco polysaccharides modified (Bouin's Harris *et al.*, 1973) and cetyl pyridinium chloride (1% cetylpyridinium chloride in formalin) was used specially. Bouin's and Susa comparatively gave good results. After fixation in Bouin's for 18-24 hours material was washed in scots tap water. Susa fixed material has been treated with iodine

alcohol. Experience proved that Susa formed the choicest fixative for most histological and histochemical reactions with the exception of lipids, nucleic acids and mucopolysaccharides. After fixation and post treatment the material was washed and then dehydrated in graded series of alcohols. Cleared in xylene and embedded in paraffin wax. Depending upon the parts of the systems the infiltration time varied from (1- 4) hours was minimized and then serial transverse or sagittal sections were cut 3-6 $\mu$  thickness for all the tissues. Excellent staining results for histological studies could be obtained by using Dalafields haematoxylin counter stained with eosin (Gurr 1962 and Heidenhain's Azan Gurr, 1885). For the EUS infected fishes collected and the procedures for determination of infected and control fishes. The tissues from control and infected groups were collected separately and processed individually for histochemical investigations.

The following various histochemical methods have been employed to elucidating the chemical nature of viz., the presence of carbohydrates, in different tissue of gills in *Channa striatus* and *Channa punctatus*. The procedure as out lined in (Pearse, 1968) for the different histochemical tests was adopted in the present study. However, the techniques mentioned in the following books were also referred (Gomori, 1952; McManus and Mowry 1960; Lillie 1965; Humason 1967; Bancroft 1975; Carleton and Drury 1957; Barka and Anderson 1963; Chayen *et al.*, 1973; Culling 1974; Bancroft and Steyans 1977; Kiernan, 1999; Shyamasundari and Hanumantha Rao, 2007).




Figure 1.

Figure 2.

Figure. 1. *C. striatus* and Figure. 2. *C. punctatus* infected with Bacterial and Fungal infection.

- a) Ulcers.
- b) Frayed Tail.
- c) Haemorrhage at the base of fins.

### Identification of Carbohydrates

For the testing carbohydrates, material fixed in Bouin's and Susa fixatives was used. Periodic acid/ Schiff (PAS) technique (Pearse, 1968) has been employed to detect the presence of carbohydrates and other groups. Periodic acid brings about oxidative cleavage of carbon to carbon bond in 1, 2 glycols to form dialdehydes, which are subsequently coloured by Schiff's reagent. This oxidant does not further oxidize the resulting aldehydes. As a

number compounds give PAS positive reaction, the different Pas positive groups that may be present were further characterized by subjecting the sections to various procedures.

### Polysaccharides

The conventional method for detecting polysaccharides by the periodic acid Schiff (PAS) method. As varieties of substances were known to give a positive reaction with PAS technique, suitable controls were employed to determine the actual compound responsible for the positive reaction. It was performed without prior oxidations with periodic acid to know whether the

reaction was due to performed aldehydes to detect glycogen, sections were subjected to PAS light green technique in conjunction with diastase digestion. Best's caramine method was also used to determine the presence of glycogen.

The PAS reaction was conducted after acetylation (24 hours at room temperature in 16 ml of acetic acid and 24 ml of pyridine) and subsequent deacetylation (45 minutes in 0.1 N potassium hydroxide at room temperature or with 20% ammonia in 70% alcohol for 24 hours) to establish the presence of 1: 2 glycol groups. To determine whether the reactivity is due to lipid, sections were treated with various lipid solvents such as pyridine or methyl alcohol chloroform mixture prior to the application of PAS technique of the substance gives a positive PAS reaction not extractable by diastase or lipid solvents and when it also gives positive reaction for protein tests, then it was considered as either a mucoprotein or glycoprotein. Finally identification was confirmed by employing methylene blue extinction technique which involves the staining of sections in methylene blue at different pH levels.

#### Mucus substances

Tissue was fixed in either new Comer's fluid dioxane or 1% acetyl pyridinium chloride in 10% formaldehyde containing 2% calcium acetate are modified Bouin's Harris *et al.*, (1973). Of all these acetyl pyridinium chloride formalin was the best as judged by the integrity of cells and by the intensity of staining of especially for mucopolysaccharides. A variety of histochemical tests were employed to demonstrate different types of mucous cells and to characterize the mucosubstances elaborated by them in turn of their vicinal hydroxyl groups their carboxyl or sulfate acid groups or both.

To differentiate mucosubstances, sections were subjected to the following testes PAS technique of McManus (1946). PAS technique with prior acetylation, McManus and Cason (1950) acetylation deacetylation, PAS McManus and Cason (1950), PAS after diastase digestion. PAS after phenyl hydrazine treatment (5% phenyl hydrazine for 1 hour at 25°C). (Spicer *et al.*, 1967). These are all to demonstrate mucosubstances with vicinal hydroxyls.

Acid mucosubstances were detected by using following techniques; Alcian blue (AB) at pH 2.5 (1% AB 8GX in 3% acetic acid) for 30 minutes AB at pH 1.0 (1% AB in 0.1N HCl) for 30 minutes Mowry (1956); Lev and Spicer (1964); Mowry's (1963) modifications of Male's colloidal iron solution for 2 hours.

Acid mucosubstances were distinguished from the neutral mucosubstances by following tests, the combined technique with PAS and AB at pH 2.5 Mowry and Winkler (1956) at pH 1.0 (Spicer *et al.*, 1967).

The following procedures were adopted to distinguish sialomutins and sulfomucins. Aldehyde fuchsin (AF) of Halmi and Davis (1953), AF / AB (pH 2.5) (Spicer and Mayer 1960).

Most of the above techniques were done concomitantly with supplementary procedures and specific tests involving chemical blockage or enzymate removal of certain reactive groups in the mucosubstances. These include mild methylation (0.40 cc of concentrated HCl in 50 cc of absolute alcohol for 4 hours at 37°C) followed by Alcian blue staining at pH 2.5 and active methylation (4 Hours at 60°C) followed by AB at pH 2.5 (Fisher and Lillie 1954; Spicer 1960). Mild methylation saponification (1% KOH in 70% alcohol for 20 minutes) followed by AB (pH.2.5) staining, active methylation saponification AB (Spicer and Lillie 1959). These methylation and demethylation treatments were performed in conjunction with Azure A, AB/PAS and AF/AB.

## RESULTS

### Histochemistry of Control Gills

The present study of histochemical tests reveals the control freshwater fishes of *C. striatus* and *C. punctatus* have four pairs of gills. Each gill filament or primary gill lamellae bears a series of alternately arranged respiratory (secondary) lamellae on its either side. Secondary lamellae are made up of alternately arranged blood channels and supporting pillar cells, which give them a ladder like configuration. A thin barrier layer of respiratory epithelium covers the pillar cells and blood channels are the components of the secondary lamellae. Usually one or two RBCs can pass through each blood channels. The mucous cells are mostly present in the primary lamellae (Singh *et al.*, 2014). The periphery of these mucous cells stained moderately with PAS and moderately too strongly with AB 2.5 and AB 1.0 taking bluish violet coloration with AB 2.5/PAS. The thin mucous layer when present on the primary lamellae and secondary lamellae stains weakly too moderately with AB 2.5 and AB 2.5/PAS negatively with AB 1.0 and PAS.

### Histochemistry of Infected Gills

The bacteria and fungi like *Aeromonas hydrophila*, *Pseudomonas aeruginosa* and *Aspergillus flavus*, *Fusarium solani*, *Rhizopus stolonifer* and *Penicillium chrysogenum* infected gill blood cells of secondary lamellae showed extensive congestion. Increased weight of these RBCs caused stretching out of the respiratory epithelium that resulted in wear and tear often leading to extensive hemorrhage. Due to congestion of the blood cells, the pillar cells got vertically compressed. Hemorrhage from the blood cells of secondary lamellae ceased with bacterial and fungal infection. The gill filaments became compactly formed due to extensive hyperplasia of the epithelial cells of primary lamellae and secondary lamellae when the individual entity of the secondary lamellae was lost at certain places. The ladder

like arrangement of the blood cells and pillar cells started losing their shape the space with blood cells decreased. This is followed by partial regaining of the ladder like appearance of the secondary lamellae even though the volume of blood cells remained distinctly shrunken and the pillar cells came very closer to each other.

The damaged secondary lamellae showed lifting from the vascular components causing hemorrhages'. However due to subsequent hyperplasia, the secondary lamellae got completely embedded into the primary lamellae which appeared solid. After the seasonal infectious conditions the mucous cells also showed hyperplasia followed by hypertrophy, when a layer of mucous covered the respiratory surface. The subsequent hyperplasia of the epithelial cells caused fusion of neighboring primary lamellae during later stages. Although the chloride cells continued to exhibit periodic hyperplasia, they frequently got degenerated. The density and dimension, secretory activity and staining properties of the mucous cells fluctuated independently of one another at several stages of infection. The fusion of adjacent primary lamellae continued even after seasonal recovery. The distorted histo-morphology of the primary lamellae along with disintegrated blood cells and pillar cells components of the secondary lamellae also persisted at several places. RBCs were invariably present within the scattered blood cells in the presence of infection, marked repair of the gill filaments were observed. The ladder like vascular component of the secondary lamellae re-established with greatly decreased thickness of the epithelial lining. The regeneration of the gills continued during the subsequent stages. However at the inner layers these cells appear loosely woven. At certain later stages the small sized mucous cells confined mostly to the outer lining of the epithelial layer, showing more affinities for Alcian Blue (AB) staining. Some of the unidentified cell mass/cells or de-generated mucous cells staining strongly with Aldehyde fuchsine (AF) were also noticed in the deeper layer of the primary lamellae primary lamellae.

#### **Histochemical Analysis**

##### **Glycogen Content**

##### **Periodic Acid/Schiff (PAS) Reaction**

This stain moderately too strongly with PAS positive in control gills in mucous cells was noticed in primary lamellae or secondary lamellae. Blood cells of the secondary lamellae became considerably engorged with red blood cells which stained positively with PAS method.

In the EUS infected gills extensive inter-cellular vacuolization with wide spread hyperplasia of cells of the epithelial linings of primary lamellae and secondary lamellae resulted in their increased thickness when presence of the infection. Lifting of the epithelial lining both from the primary lamellae as well as secondary lamellae was very commonly observed in infection. And in the density of the mucous cells are both in the primary

lamellae and secondary lamellae increased deeply. These cells were stained negatively with PAS.

##### **Alcian Blue (AB) pH 2.5**

The AB 2.5 stain moderately too strongly with control gills at this stage a good number of rounds, large vacuoles of uniform size began appearing in the primary lamellae, as well as secondary lamellae. A small amount of basophilic slimy substance stained positively with AB 2.5. And in the bacterial and fungal infected gills showed the density of the mucous cells decreased slightly and basophilic fuzzy substance regularly sloughed from the mucus coated surface of the primary lamellae and secondary lamellae is negative with AB 2.5.

##### **Alcian Blue (AB) pH 1.0**

In the control gills the vacuolization aggravated with this stage a good number of rounds, large vacuoles of uniform size began appearing in the primary lamellae as well as secondary lamellae. A small amount of basophilic slimy substance stained positively with AB 1.0 was frequently observed, especially in the inner lining of these vacuoles. The size and density of these vacuoles in the hyperplastic primary lamellae in general and secondary lamellae in particular increased in the subsequent stages. Even though mild wear and tear of the epithelial linings of the primary lamellae and secondary lamellae was noticed at this stage, no hemorrhage or rupture of the blood cells was detected.

The bacterial and fungal infected gills shows the blood cells of the primary lamellae, however, became greatly dilated and engorged with red blood cells after the infection. The densities of the mucous cells are decreased. A slightly basophilic fuzzy substance regularly sloughed from the surface of the secondary lamellae. However, a thin layer of mucus coated the surface of the secondary lamellae AB 1.0 negative with this several sites the typical ladder-like arrangement of the pillar cells and blood cells are collapsed. However, the gills regenerated partially and regained some of their lost staining properties at several other sites. The blood capillaries running through the gill filament showed extensive congestion and engorgement with a large number of red blood cells. (Plate: I. Figure 1 to 12).

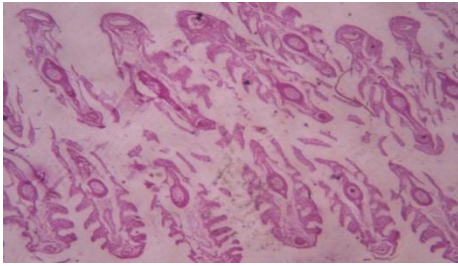


Figure 1.

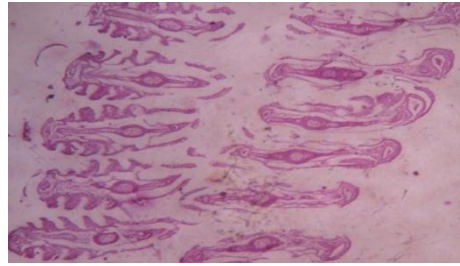


Figure 2.

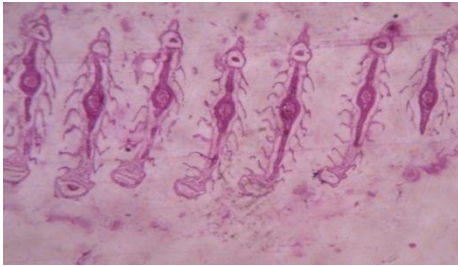


Figure 3.

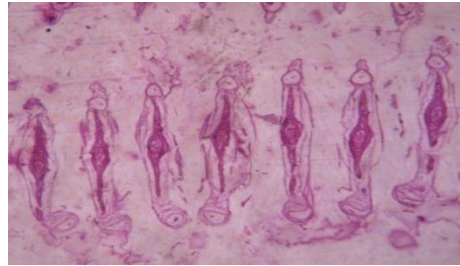


Figure 4.

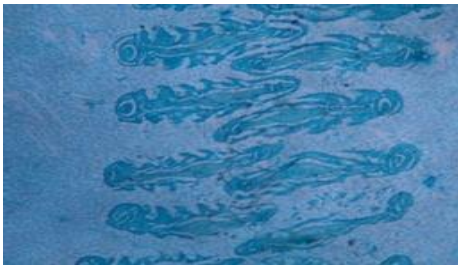


Figure 5.

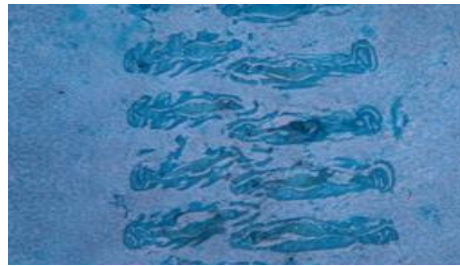


Figure 6.

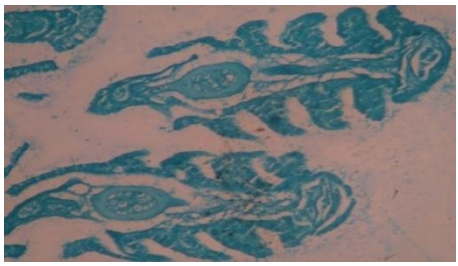


Figure 7.

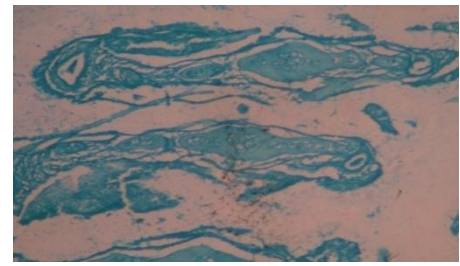


Figure 8.

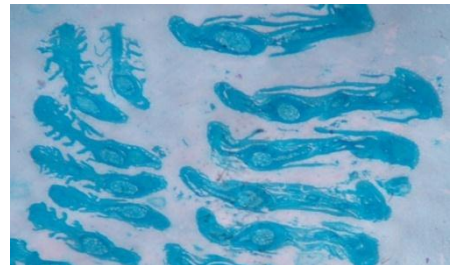


Figure 9.

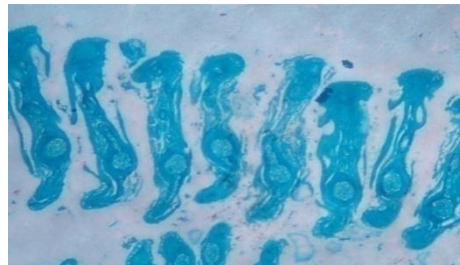


Figure 10.

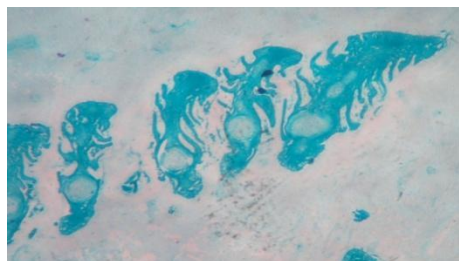


Figure 11.

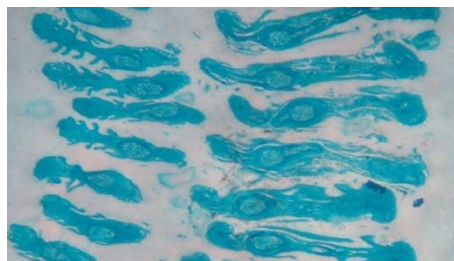


Figure 12.

**PLATE: I.** Figure. 1: T.S of *C. striatus* Control gill shows moderately the presence of glycogen (PAS). Figure. 2: T.S of *C. striatus* Infected gill shows strongly the presence of glycogen substances (PAS). Figure. 3: T. S of *C. striatus* Control gill showing pale blue presence of acid mucin (AB2.5pH). Figure. 4: T.S of *C. striatus* Infected gill shows light and dark blue presence of sulphated mucins (AB 2.5 pH). Figure. 5: T.S of *C. striatus* Control gill shows presence of mucin (AB 1.0 pH). Figure. 6:T.S of *C. striatus* Infected gill showing presence of sulfated mucosubstances (AB1.0 pH). Figure. 7: T.S of *C. punctatus* Control gill showing moderately the presence of glycogen (PAS). Figure. 8: T.S of *C. punctatus* Infected gill showing strongly the presence of glycogen substances (PAS). Figure. 9: T.S of *C. punctatus* Control gill showing pale blue presence of acid mucin (AB2.5pH). Figure. 10:T.S of *C. punctatus* Infected gill showing light and dark blue presence of sulphated mucins (AB 2.5 pH). Figure. 11: T.S of *C. punctatus* Control gill showing presence of mucin (AB 1.0 pH) Figure. 12:T.S of *C. punctatus* Infected gill showing presence of sulfated mucosubstances (AB1.0 pH).

#### Alcian Blue (AB) pH 2.5/ PAS

The control gill shows vascular components of the secondary lamellae are made up of alternately arranged pillar cells, blood channels that remained covered by a thin respiratory epithelium. The mucous cells are mostly observed in the epithelium of the gill filaments or primary lamellae. A few saucer-shaped mucous cells are also present in the secondary lamellae. The mucous cells take on a dark greenish-black colour with AB 2.5/PAS. The mucous cells on the primary lamellae stain

light greenish-blue, with their periphery taking on a dark blackish green colour with AB 2.5/PAS.

EUS infected *C. striatus* and *C. punctatus* gills extensive inter-cellular vacuolization with wide spread hyperplasia of cells of the epithelial linings of primary and secondary lamellae resulted in their increased thickness density of the mucous cells both in primary lamellae and secondary lamellae increased greatly to greenish-blue with AB 2.5/PAS techniques. (Plate: II. Figure 1 to 4).

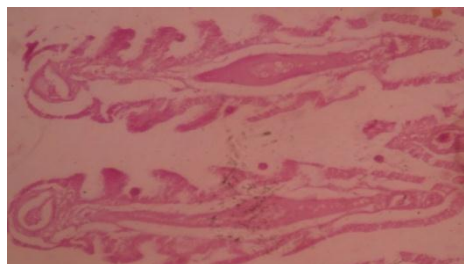


Figure 1.

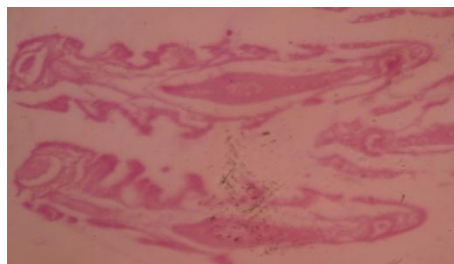

Figure 2.

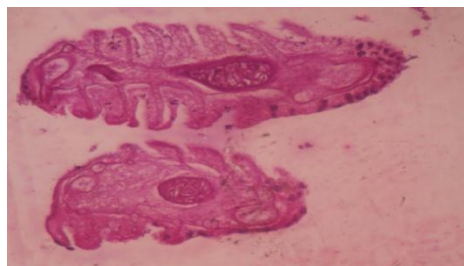


Figure 3.

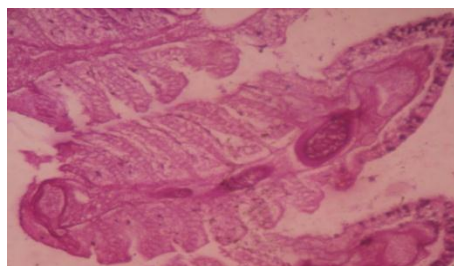


Figure 4.

**PLATE: II.** Figure.1: T.S of *C. striatus* Control gill, displaying presence of glycogen predominately (pink), less amount of mucin (blue) (AB25pH/PAS). Figure. 2: T.S of *C. striatus* Infected gill displaying the presence of mucin predominately (AB 2.5 pH /PAS). Figure. 3: T.S of *C. striatus* Control gill presented elastic fibers purple and collagen stained with light yellow (Aldehyde fuchsine). Figure. 4: T.S of *C. striatus* Infected gill shown elastin decreased (Aldehyde fuchsine).

### Aldehyde Fuchsin

With this aldehyde fuchsin of normal gills have shown vascular components of the secondary lamellae purple and blood channels that remained covered by a thin respiratory epithelium stained with light yellow, the pillar cells show negative reaction. Gills epithelial cells appear in intense purple colour. The mucous cells were

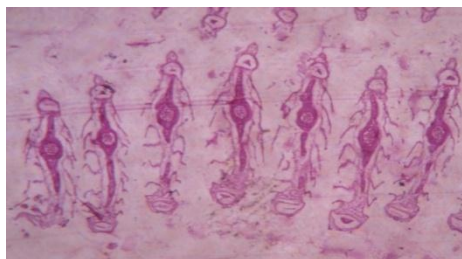

Figure 5.

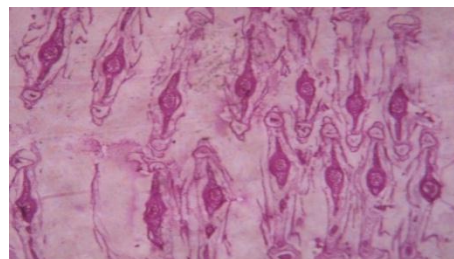


Figure 6.

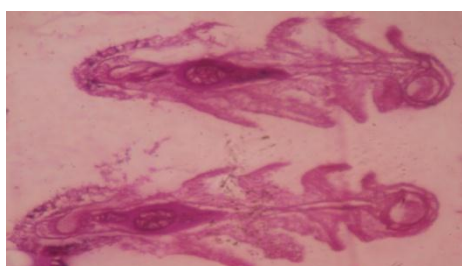


Figure 7.

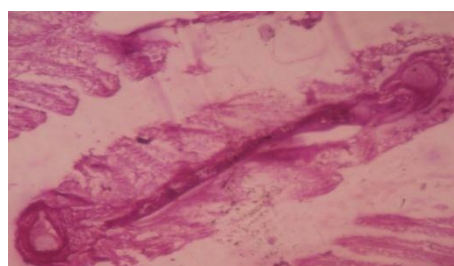


Figure 8.

**PLATE: III. Figure. 5: T.S of *C. punctatus* Control gill, displaying presence of glycogen predominately (pink), less amount of mucin (blue) (AB25 pH/PAS). Figure. 6: T.S of *C. punctatus* Infected gill displaying the presence of mucin predominately (AB 2.5 pH /PAS). Figure. 7: T.S of *C. punctatus* Control gill presented elastic fibers purple and collagen stained with light yellow (Aldehyde fuchsin). Figure. 8: T.S of *C. punctatus* Infected gill shown elastin decreased (Aldehyde fuchsin).**

### DISCUSSION

The histochemical studies were in the present microscopic investigations of the gills. Histochemical tests carried out on the gills, revealed alcianophilia of the mucus glands when stained with alcian blue at 1.0 pH and 2.5 pH. The alcian blue at 1.0 pH the staining intensity is inconspicuous as compared to alcian blue at 2.5 pH. This clearly indicated the presence of sulphated mucosubstances, hyaluronic acid and sialic acid in the gills. Alcian blue (1.0 pH)/PAS demonstrated the traces of acid muco polysaccharides sulphated muco substances, hyaluronic acid and sialomucins. When alcian blue (2.5 pH)/PAS stain was employed, the neutral mucopolysaccharides and strongly acidic muco polysaccharides revealed their presence. The most remarkable toxic affect of the arsenic salt on the gills of *C. striatus* and *C. punctatus* is periodic fluctuation in their density, percentage of area occupancy and staining properties of the mucous cells. The extensive secretion of sulphated mucosubstances by the mucous cells. A survey of the literature indicates that after severe stages of infection increases, the density and percentage of area occupancy of the mucous cells of the gills decreased significantly in the seasonal condition. However the density remained above the normal level up to end of the

seasonal period even though it shows periodic fluctuations. This indicates regeneration of large number of small sized mucous cells. Later on both the parameters fluctuate at different stages of exposure and remain subnormal especially at later stages of EUS infection. Bacteria and fungi have permanently altered the monogenic activity of mucous cells of the gills as evidenced by subnormal density/area occupancy of the mucous cells. Although excessive mucus coagulation on the respiratory surfaces might cause disturbances in several important physiological processes such as gas exchange, nitrogen excretion, salt balance and circulation of blood (Laurent and Dunel, 1978). It is also prevents the penetration of the ambient arsenic salt temporally.

The gill structure in case in the case of teleost fishes is likely to be markedly altered resulting into pathological conditions in various ways if subjected to any environmental and chemical pollutants like heavy metals, pesticides and insecticides (Benarjee, 1986). These conditional changes are visible especially at the base of the secondary gill lamellae, respiratory epithelium of primary and secondary gill lamellae, with necrosis of lamellar epithelium causing respiratory and osmoregulatory distress. (Skidmore and Tovell 1972;

Lamke and Mount 1963). The present observations point out to the similar conditions as a result of bacterial and fungal factors are infected to *C. striatus* and *C. punctatus*. However the severity of damage caused was more with the increased in the period of seasonal infection. The major changes were necrosis, rupture of capillaries and atrophy of respiratory gill filaments. These findings of the present investigations thus show a similarity with the observations made (Rao *et al.*, 1989).

## CONCLUSION

The damage of gills in fishes infectious to *Aeromonas hydrophila*, *Pseudomonas aeruginosa* and *Aspergillus flavus*, *Fusarium solani*, *Rhizopus stolonifer* and *Penicillium chrysogenum* the high level of disease was severe. Shortened and clubbing of ends of the secondary gill lamellae, fusion of adjacent secondary gill lamellae and necrosis in the primary lamellae were well marked. Hyperplasia and hypertrophy of nuclei were also seen. The histochemical reactions were determined that the control gill tissues of these fishes contained glycogen, weakly acidic sulfated mucosubstances, hyaluronic acid, sialomucins, carboxylated mucosubstances, In the EUS infected fishes gill the tissue had shown some variation with the control. The damaged secondary lamellae showed lifting from the vascular components causing haemorrhages. However due to subsequent hyperplasia, the secondary lamellae got completely embedded in the primary lamellae which appeared solid. After the infection the mucous cells also showed hyperplasia followed by hypertrophy, with a layer of mucus covering the respiratory surface.

## ACKNOWLEDGEMENT

Authors thanks to Head, Department of Zoology, Kakatiya University, Warangal, Telangana. India, for providing necessary facilities.

## REFERENCES

1. A.K. Singh and T. K. Banerjee. Histopathological and histochemical study on gills of the freshwater walking catfish *clarias batrachus* (linn.) Following exposure and withdrawal of arsenic stress. *International journal of integrative sciences, innovation and technology*, 2014; 3(4): 12-19.
2. Bancroft, J. D. and Stevenson, J. M. Theory and practical histochemical technique. Edinburg Churchill, 1977.
3. Barka, T. and Anderson, P. J. Histochemistry theory, practical and bibliography. Hoeber Medical Division. Harper and Row Publishers Inc., New York, Boston and London, 1963.
4. Banerjee, G. Toxicological effects of organophosphorus insecticide on the Histopathological changes in certain tissues of the Catfish, *Clarias batrachus* (Linnaeus) Ph. D. thesis, Kakatiya University, Warangal, 1986.
5. Carleton, M. and Drury, R.A.B. 1957. Histochemical technique for normal and pathological tissues and the identification of parasites. *Oxford University Press, London*.
6. Chayen, T., Bitensky, L. and Butches, R.G. Practical Histochemistry. John Wiley and Sons, London, 1973.
7. Culling, C. F. A. Handbook of histopathological and histochemical technique. Butter Worths, 1974.
8. Fisher, E. R. and Lillie, R.D. The effect of methylation on basophilia. *J. Histochem. Cytochem*, 1954; 2: 81-87.
9. Gomori, G. Microscopic histochemistry: Principles and Practice. Univ. of Chicago Press, Chicago, III, 1952.
10. Gurr, E. 'Staining animal tissues: practical and theoretical'. Leonard Hill (Books) Ltd., London, 1962; 631.
11. Heidenhain R. Eine neue Verwendung des haematoxylin. *Arch. Mikr. Anat*, 1885; 24: 468-470.
12. Halmi, N.S. and Davies, J. Comparison of aldehyde fuchsin staining, metachromasia and periodic acid/Schiff reactivity of various tissues. *J. Histochem. Cytochem*, 1953; 1: 447-459.
13. Harris J.E. Watson A and Hunt S. Histochemical analysis of mucous cells in the epidermis of brown trout *Salmo trutta L.J. Fish Biol.*, 1973; 5: 345-351.
14. Humason, G. L. Animal tissue techniques. W.H. Freeman and Co. San Fransisco and London, 1967.
15. Kiernan, J.A. Histological and histochemical methods: theory and practice. Butterworth Heinemann Linacre House, Jordan Hill, Oxford OX28DP, 1999.
16. Laurent P. and Dunel.L.S. Relations anatomiques des ionocytes (Cellules a chlorure) avec le compartiment veineux branchial: Definition de deux types d' epithelium de la branchie des poissons. *C. R. Hebd. Seances Academy of Sciences, Ser. D.*, 1978; 286: 1447-1450.
17. Lekme, E. and Mount, L. Some effects of alkyl benzene sulfonate on the blue gills, *Lepomis machrochirus*. *Trans. Amer. Fish. Soc.*, 1963; 92: 372- 378.
18. Lev, R. and Spicer, S.S. Specific staining of sulphate group with Alcian blue at low pH. *J. Histochem. Cytochem.*, 1964; 12: 309.
19. McManus, J.F.A. The histological demonstration of mucin after periodic acid. *Nature*, 1946; 158: 202.
20. McManus, J.F.A. and Cason, J.E. Carbohydrate histochemistry studied by acetylation technique. *J. Exp. Med.*, 1950; 91: 651-654.
21. Mowry, R.W. The special value of methods that colour with both acidic and vicinal hydroxyl groups in histochemical study of musims with revised direction for colloidal iron stain the use of Alcian blue 8GX and their combinations with the periodic acid Schiff reaction. *Ann. N.Y. Acad. ScL*, 1963; 106: 402-423.
22. Mowry, R.W. and Winkler, C.H. The colouration of acidic carbohydrates of bacteria and fungi in tissue sections with a special reference to capsules of



- Cryptococcus*, *Pneumococcus* and *Staphylococcus*. *Amer. J. Path.*, 1956; 32: 628-629.
23. Pearse, A.G.E. *Histochemistry: Theoretical and Applied*. 2nd Edition, Little, Brown and Company, Boston, Mass, 1968.
  24. Rao, K. R. S., Bhaskar, B. R., Rao, D. P. and Durga prasad, Y. V. K. Hemograms of six marine teleosts from visakhapatnam coast [India]. *Proc Indiannatl Sc Acad Part B Biol Sci.*, 1989; 55(2): 103-106.
  25. Shyamasundari, K. and Hanumantha Rao, K. *Histochemistry in focus*. *M.J.P Publishers, Chennai, India*, 2007.
  26. Skidmore, J.F., Towel, P.W.A. Toxic effect of zinc sulphate on the gills of Rainbow trout. *W. Res.*, 1972; 6: 230-271.
  27. Spicer, S. S. and Lillie, R. D. Saponification as a means of selectively reversing the methylation blockade of tissue basophilia. *J. Histochem. Cytochem.*, 1959; 7(2): 123-125.
  28. Spicer, S.S. and Mayer, D.B. Histochemical differentiation of mucopolysaccharides by means of combined aldehyde fuchsin alcian blue staining. *Amer. J. Clin. Pathol.*, 1960; 33: 453-460.
  29. Spicer, S.S. Horn, R.G. and Leppi, T.J. Histochemistry of connective tissue mucopolysaccharides. Symposium on Connective tissue research methods. Ch. 17. *The Williams and Welkins Co.*, Baltimore, 1967; 251-302.