

IMAGING STUDY FOR LIVER SEGMENT 9 PORTOBILIARY ANATOMY IN ADULTS

Dr. Dragica Jurkovikj*

Institute of Anatomy, Medical Faculty, University "Ss. Cyril and Methodius", Skopje, Republic of Macedonia.

*Corresponding Author: Dr. Dragica Jurkovikj

Institute of Anatomy, Medical Faculty, University "Ss. Cyril and Methodius", Skopje, Republic of Macedonia.

Article Received on 13/03/2018

Article Revised on 03/04/2018

Article Accepted on 24/04/2018

ABSTRACT

Background: The main goal of this research was to clarify the existence of a paracaval area as the most common location for liver malignancies. **Material and Methods:** On 30 cadaveric human liver specimens of adults the injection-corrosive method was used. Portal vein segmentation, and then types of segment 9 subdivision were determined in 27 portobiliary casts of proper quality with the help of a magnifying lens. **Results:** The results confirmed four different types: type I only with 9d portal branches in 3.71%; type II with 9c and 9d portal branches and biliary ducts in 14.81%; type III with 9b, 9c, and 9d portal branches and only 9b and 9c biliary ducts also in 14.81%; and type IV with portal branches and biliary ducts of all subsegments in 66.67% of cases. **Conclusion:** This investigation confirms the complete presence of all three subsegments in 66.67% and partially in the remaining 33.33% of cases.

KEYWORDS: Liver segments, paracaval portion, portal vein, biliary duct, corrosion liver casts.

INTRODUCTION

The worldwide used numbering system for liver segments is the Couinaud's (1954)^[1] classification into I-VIII segments. Previously its application was reported during sonography, CT and MR imaging-Gerald DD III (1993),^[2] as well as during anatomical basic investigation Arora et al. (2003)^[3] and Rajput et al. (2014).^[4] But, regarding segment I we propose the new Couinaud's consideration on liver anatomy with special accent on the dorsal sector (1989, 1999).^[5,6]

Despite this, other investigators and clinicians have accepted the Kumon's (1985)^[7] caudate lobe subdivision into three parts -the Spieghele lobe, the paracaval portion and the caudate process. Derived from the report done by hepatopancreatobiliary surgeons-Feng et al. (2015)^[8] about resection of caudate lobe hemangioma, it may be concluded that Spieghele lobe is equal to the Couinaud's segment I, and the paracaval portion is equal to the Couinaud's segment IX.

Since the question on the existence or nonexistence of the liver segment 9 i.e. paracaval portion is still open, we found it necessary to continue with investigation of this paracaval area.

MATERIAL AND METHODS

On the 30 cadaveric human liver specimens of adults the injection-corrosive method was applied. Uncolored odontolitic acrylate into the portal trunk and yellow

colored one into the common hepatic duct was injected and then injected elements were ligated. After polymerization the specimen underwent to corrosion with concentrated HCl acid. Also, on a few specimens, due to a previously study, the proper hepatic artery with red colored odontolitic acrylate was injected. A total of 27 acrylate casts were of proper quality whereas the 3 remaining had incomplete filling. With the help of magnifying lens were analyzed:

1. Intrahepatic portal vein branching pattern.
2. Intrahepatic biliary ducts confluence.

Based on the Couinaud's (1999)^[6] concept of liver segmentation nine portal vein segments were determined and then a schematic drawing was made. As to segment 9 on the basis of presence of its portal and biliary elements the constituent subsegments-b, c, and d and types of subdivision were determined.

In accordance with the proposed terminology of liver anatomy and resections-Brisbane 2000 by Terminology Committee of the IHPBA and their suggestion^[9] in the Couinaud's numbering system the Roman numerals are replaced with Arabic ones. So, the segments were numbered from 1 to 9 and to segment 1 the shortcuts 1RP for right portion, 1LP for left portion, cp for caudate process, pp for papillary process, s for superficial branch and p for profound branch were used. Also, shortcuts 9b, 9c, and 9d were used for segment 9 subsegments.

As a descriptive statistics the percentage of obtained frequencies was determined.

RESULTS

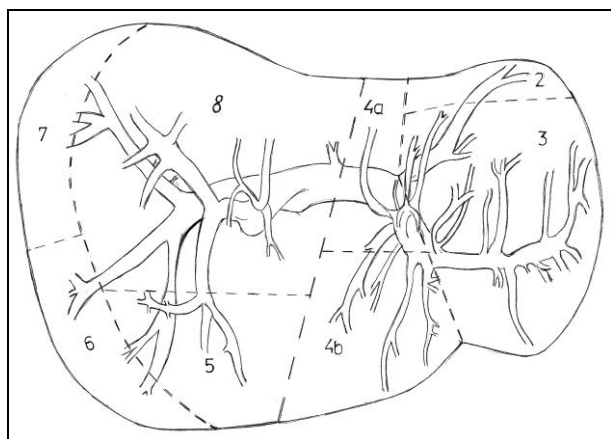
According to the determined intrahepatic portal vein and biliary duct ramification for each specimen the liver segmental division into 1-9 segments was established. Then, on the basis of presence of segment 9 subsegments (b, c, and d) four types of subdivision were noticed.

Type I: presence only of subsegment 9d portal branches in one case-3.71% (see Fig. 1).

Type II: presence of subsegment 9c and 9d portal branches and biliary ducts in four cases-14.81% (see Fig. 2).

Type III: presence of subsegment 9b, 9c and 9d portal branches and only of subsegment 9b and 9c biliary ducts in another four cases-14.81% (see Fig. 3).

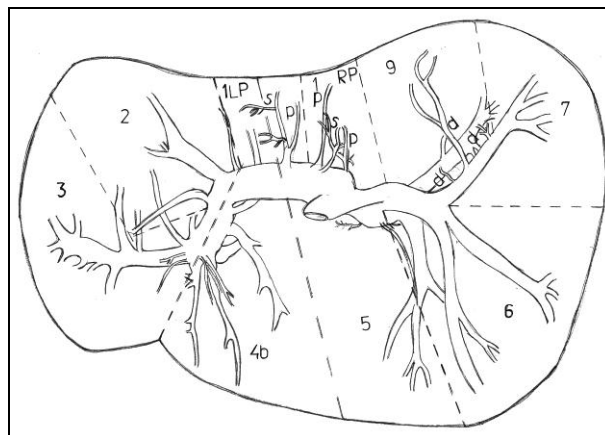
Type IV: presence of all subsegment 9b, 9c and 9d portal branches and biliary ducts in 18 cases-66.67% (see Fig. 4).



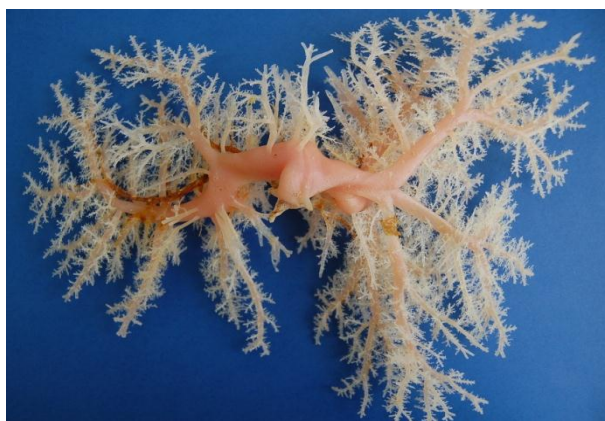A



B

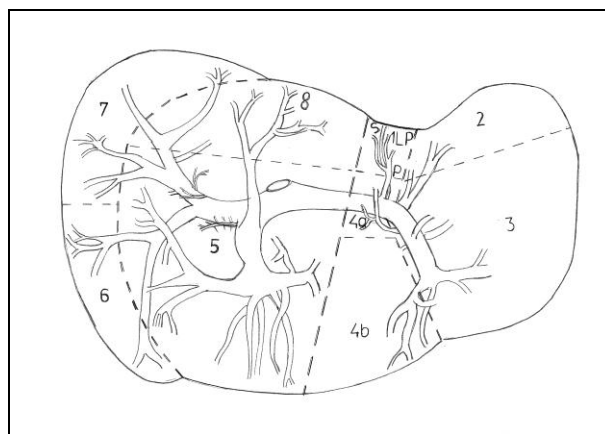


C

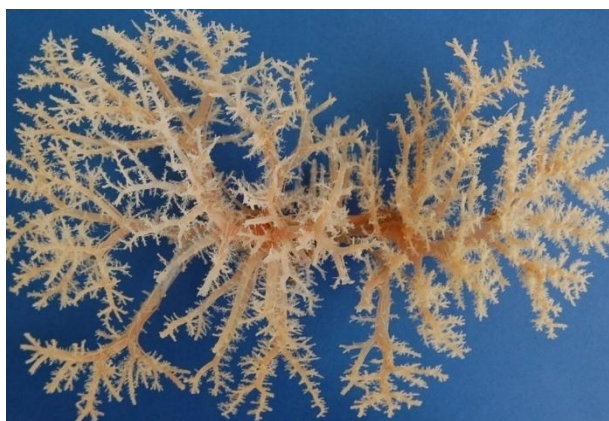

D

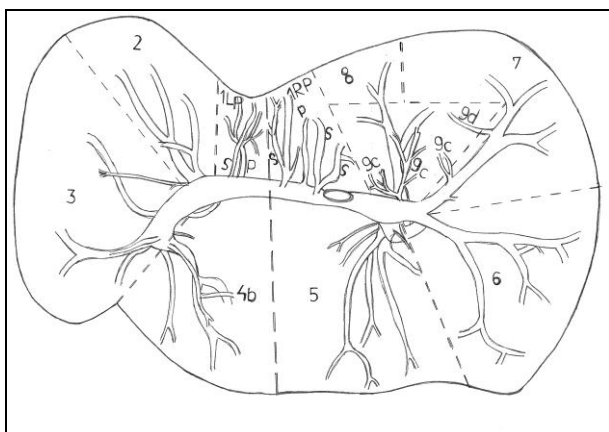
Figure 1: Case no. VIII with type I of segment 9 subdivision; A. Scheme of a portal segmentation outlining on the diaphragmatic surface; B. Diaphragmatic view of the portobiliary cast; C. Scheme of a portal segmentation outlining on the visceral surface; D. Visceral view of the portobiliary cast.



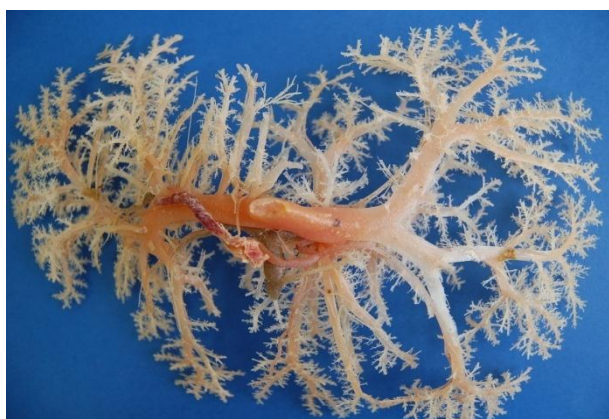A



B

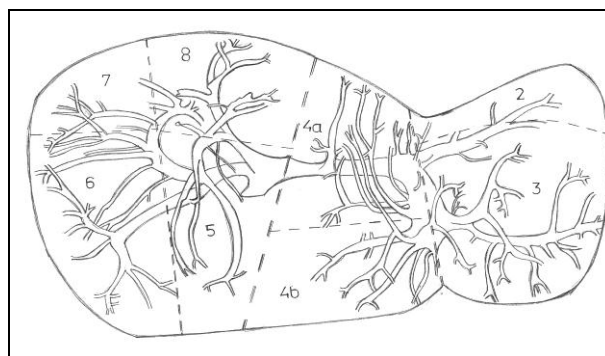


C

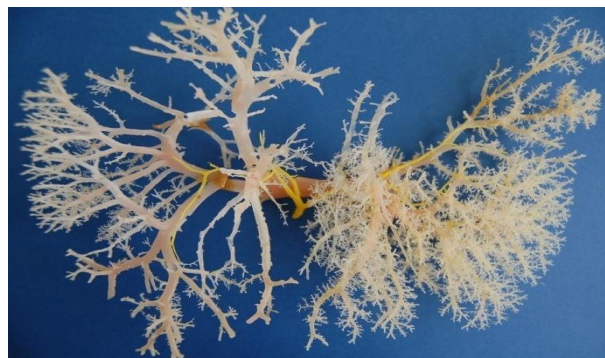

D

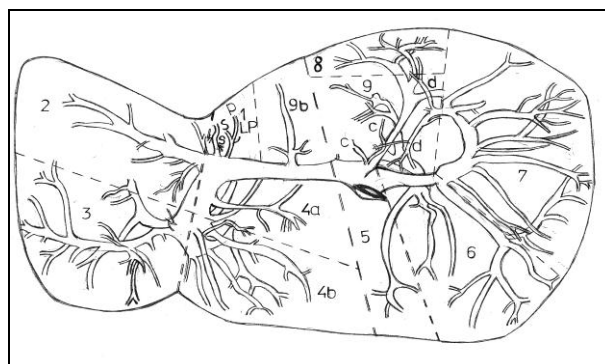
Figure 2: Case no. I with type II of segment 9 subdivision; A. Scheme of a portal segmentation outlining on the diaphragmatic surface; B. Diaphragmatic view of the portobiliary cast; C. Scheme of a portal segmentation outlining on the visceral surface; D. Visceral view of the portobiliary cast.



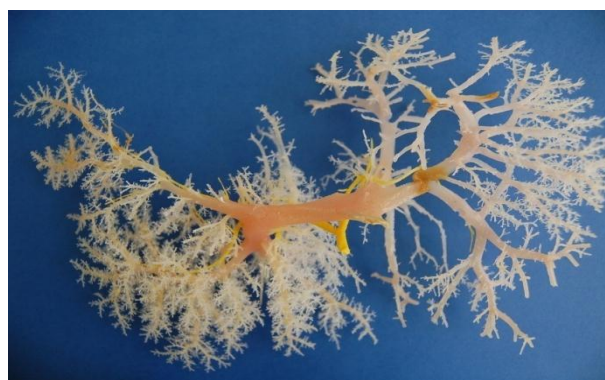A



B

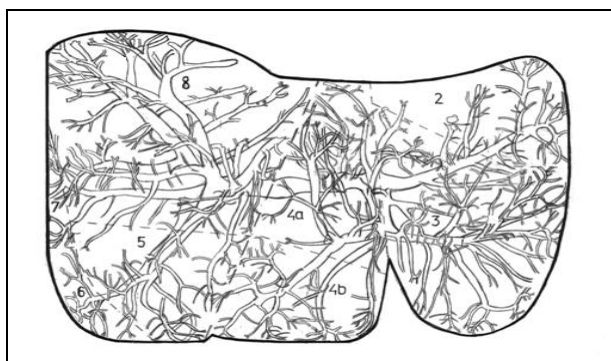


C



D

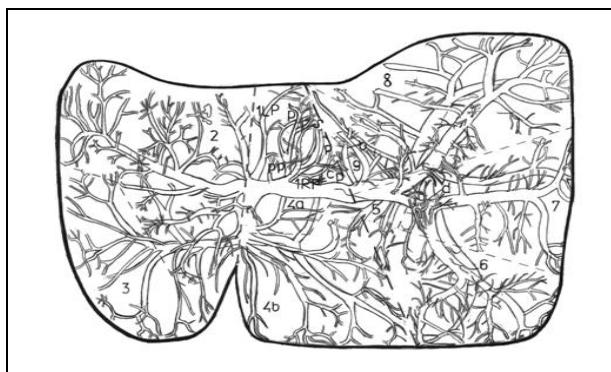
Figure 3: Case no. X with type III of segment 9 subdivision; A. Scheme of a portal segmentation outlining on the diaphragmatic surface; B. Diaphragmatic view of the portobiliary cast; C. Scheme of a portal segmentation outlining on the visceral surface; D. Visceral view of the portobiliary cast.



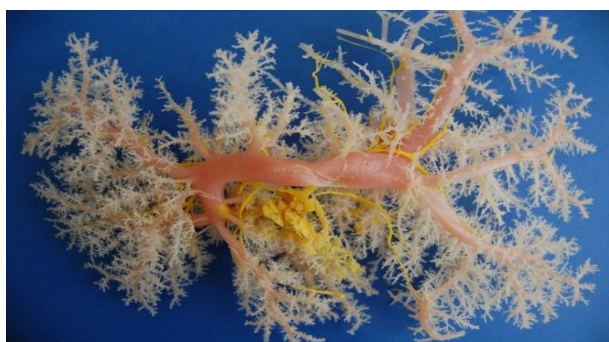A



B



C



D

Figure 4: Case no. XV with type IV of segment 9 subdivision; A. Scheme of a portal segmentation outlining on the diaphragmatic surface; B. Diaphragmatic view of the portobiliary cast; C. Scheme of a portal segmentation outlining on the visceral surface; D. Visceral view of the portobiliary cast.

DISCUSSION

From the anatomical point of view, existence of short or small hepatic veins and their openings directly into the retrohepatic inferior vena cava (RHIVC) was mainly reported. In our previous investigations, despite 2 or 3 large openings into the upper part of RHIVC, openings of medium or small-sized hepatic vein on the medium and lower thirds of RHIVC were confirmed.^[10]

From the surgical point of view, in the retrohepatic tunnel of inferior vena cava avascular zone did not exist because of the presence of relatively small vessels, which was reported by the acknowledged Chinese surgeons-Zheng et al. (2017).^[11] They consider disadvantage of the Liver Hanging Maneuver i.e. anterior approach for liver resection that it may cause bleeding due to injury to the short hepatic vein or the inferior vena cava in front of the RHIVC.

In contribution to the anatomy of this paracaval area is the anatomical knowledge of two eminent surgeons, Masamitsu Kumon from Japan^[12] and Claude Couinaud from France.^[6]

The aim of Kumon's study published in the end of the last century^[7] and now translated into English^[12] was to give definition and to determine the extent and clinical significance of the caudate lobe. In this study the caudate lobe was defined as an independent part of liver composed by Spiegelhe lobe, paracaval portion and caudate process portion. To determine the extent of area supplied by the paracaval branch 19/23 livers were classified into 3 categories: (1) the paracaval branch reaching the liver surface beneath the diaphragm; (2) the paracaval branch distributed on the anterior aspect of the inferior vena cava and the dorsal aspect of the root of the major hepatic veins, but not reaching the liver surface; or (3) the paracaval branch supplying a small region. These study findings showed that the paracaval portion of the liver was most important for clarifying the extent of the caudate lobe and that complete resection of the paracaval portion branches seemed limited because these branches may supply a large area.

Couinaud (1999)^[6] proposed the term "dorsal sector" to the area including the caudate lobe and a prolongation in the posterior surface of the right liver. The author described two portions: a left dorsal sector i.e. caudate lobe formally named segment I, and a right dorsal sector formerly named segment IX. Right dorsal sector was completely incorporated in the posterior surface of the right liver. This portion was subdivided into three subsegments which were in contact with the vena cava: RDSb under the interval between the middle and right superior hepatic veins, RDSc under the large right superior hepatic vein, and RDSd posterior to a vertical plane passing through the right superior hepatic vein. Anteriorly the right dorsal sector was fused with segments VIII (RDSb and RDSc) and VII (RDSd). The limit between left and right portions was variable, and

followed a sagittal plane passing by the left margin of the vena cava.

The present study results confirm Couinaud's^[6] concept about the existence of left and right dorsal sectors. Also, the determined types of segment 9 liver subdivision, pointing at the variable extent of this segment, are in agreement with his findings that several segments may be missing.

Regarding the surgical importance of dorsal sector Couinaud's^[6] conclusion was that approach of the anterior aspect of vena cava, and section of the dorsal overlapping pedicles not controlled by interruption of the right or left portal pedicles may lead to blood oozing or biliary leak.

According to Chaib et al. (2009)^[13] anterior hepatic transection was recommended for tumor located in the paracaval portion of the caudate lobe (segment IX).

As presented in the study of Feng et al. (2015)^[8], during liver resection anterior approach to the paracaval portion, left approach to the Spiegel's lobe, and right approach to the caudate process were recommended.

CONCLUSION

This study confirms the existence of liver segment 9 i.e. the caudate lobe paracaval portion. Being a part of the neighboring segments, mainly the complete presence of all three subsegments (9b, 9c, and 9d) in 66.67% and partially in the remaining 33.33% of cases was found.

REFERENCES

1. Couinaud C. Lobes et segments hépatiques. Notes sur l'architecture anatomique et chirurgicale du foie. Presse Med, 1954; 62: 709-712.
2. Gerald DD III. An American's Guide to Couinaud's Numbering System. Commentary. In: AJR, 1993; 161: 574-575.
3. Arora J, Kapur V, Kakkar A, Dixit PC. Ramification Pattern of Portal Vein in Right Lobe of Liver _ A Corrosion Cast Study. J Anat Soc India, 2003; 52(1): 12-14.
4. Rajput AS, Kumari S, Mishra GP. A corrosion cast study of ramification pattern of portal vein in right lobe of human liver. Original Article. In: Int J Anat Res, 2014; 2(4): 791-796. DOI: 10.16965/ijar.2014.551. www.ijmhr.org/ijar.htm.
5. Couinaud C. Surgical anatomy of the liver revisited.. Pers. Ed. Paris; 15, rue Spontini, F 75116, 1989.
6. Couinaud C. Tell me more about liver anatomy, 1st edition. Paris; Karger, 1999.
7. Kumon M. Anatomy of the caudate lobe with special reference to portal vein and bile duct. Acta Hepatol Jpn, 1985; 26: 1193-1199.
8. Feng X, Hu Y, Peng J, Liu A, Tian L, Zhang H. A Left-Sided Approach for Resection of Hepatic Caudate Lobe Hemangioma. Two Case Reports and a Literature Review. Int Surg, 2015; 100(6): 1054-1059. DOI: 10.9738/INTSURG-D-14-00317.1 PMID: PMC4587506.
9. Terminology Committee of the IHPBA (authors). Terminology of liver anatomy and resections. HPB Surg, 2000; 2: 333-339.
10. Jurkovikj D. Main and accessory retrohepatic inferior vena cava openings-case reports. Case Report. In: WJPMR, 2017; 3(6): 52-57. www.wjpmr.com.
11. Zheng W, Zi-hai D, Jie Z, Shi-zhen Z, Jian-hua L, Yi-xiong L. Anatomy of the retrohepatic tunnel in a Chinese population and its clinical application in liver surgery. Sci. Rep., 2017; 7: 44977; DOI: 10.1038/srep44977.
12. Kumon M. Anatomical Study of the Caudate Lobe with Special Reference to Portal Venous and Biliary Branches Using Corrosion Liver Casts and Clinical Application. Liver Cancer, 2017; 6(2): 161-170. DOI: 10.1159/000454682 PMID: PMC5340219.
13. Chaib E, Ribeiro Jr MAF, D'Albuquerque LAC. Anterior Hepatic Transection for Caudate Lobectomy. Clinics (Sao Paulo), 2009; 64(11): 1121-1125.