

**RADIATION-INDUCED BRACHIAL PLEXOPATHY A CASE REPORT AND REVIEW  
OF THE LITERATURE****Emilia Burada\*<sup>1</sup>, Adrian Tudor Balseanu<sup>1</sup>, Smaranda Mitran<sup>1</sup>, Veronica Sfredel<sup>1</sup>, Florin Burada<sup>2</sup> and Bogdan Catalin<sup>1</sup>**<sup>1</sup>Department of Physiology, University of Medicine and Pharmacy of Craiova, Romania Petru Rares 2, 200349, Craiova, Romania.<sup>2</sup>Human Genomics Laboratory, University of Medicine and Pharmacy of Craiova, Romania Emilia Burada and Adrian Tudor Balseanu contributed equally to this study.**\*Corresponding Author: Emilia Burada**

Department of Physiology, University of Medicine and Pharmacy of Craiova, Romania Petru Rares 2, 200349, Craiova, Romania.

Article Received on 18/02/2018

Article Revised on 11/03/2018

Article Accepted on 01/04/2018

**ABSTRACT**

**Introduction:** Delayed radiation-induced brachial plexopathy (RIBP) is a rare condition that occurs as a late side effect of radiation therapy for cancer treatment. Only few data are available about RIBP in patients that received radiotherapy for nasopharyngeal cancer. **Case Presentation:** We present a 72 years old woman patient with a slowly progressive bilateral brachial plexopathy and carotid arterial disease after radiotherapy for nasopharyngeal carcinoma. RIBP diagnosis was based on history of radiotherapy after cancer, clinical features, neurological and electrophysiological exams. The patient was diagnosed thirty two years ago with nasopharyngeal cancer and treated with radiation therapy. She developed paraesthesia on the left and right lateral side of the arm, forearm, hand and thumb. Also, skin pigmentation and enured area on the anterior part of the neck were noted from the moment of radiotherapy. Motor examination revealed right and left loss of shoulder flexion, internal rotation and abduction worse on the left part, tendon jerks depressed on biceps and brachioradialis tendon, atrophy of bilateral deltoid, biceps, supraspinatus and infraspinatus accentuated on left with fasciculation at this level. Nerve conduction study showed a reduced nerve conduction velocity, prolonged latency, and decreased amplitude in motor axilar nerves, antebrachial cutaneous nerves, sensory radial nerves, and right sensory and motor median nerve. Needle electromyographic examination revealed myokymic discharges, fibrillation and positive sharp waves on bilateral medial deltoid and biceps brachii muscles, motor unit potential varying in morphology and decreased recruitment. **Conclusion:** RIBP is a rare complication of radiotherapy in nasopharyngeal carcinoma patients. Electromyography plays an essential role in the differential and positive diagnosis of delayed radiation-induced brachial plexopathy, showing typical changes - myokymic discharges.

**KEYWORDS:** radiation-induced brachial plexopathy, nasopharyngeal cancer, electromyography, myokymic discharges, carotidian arterial disease.

**INTRODUCTION**

Delayed radiation-induced brachial plexopathy (RIBP) is a rare condition that occurs as a late side effect of radiation therapy for cancer treatment. The incidence of RIBP is less than 1–2% for those who have undergone radiotherapy total doses <55 Gy in the region of the brachial plexus,<sup>[1,2]</sup> the risk being influenced in a dose-dependent manner.<sup>[3]</sup> The RIBP was reported as a treatment complication mainly in patients with breast cancer,<sup>[4,5]</sup> and only few data are available about RIBP in patients that received radiotherapy for nasopharyngeal cancer.<sup>[6,7]</sup>

The pathophysiology of RIBP is not fully understood, the damage can results by direct effect of radiation on nerve cell, ischemic changes on vascular endothelial cells and

radiation-induced capillary network disruption. Further, these injuries lead to ischemia-hypoxia and subsequent axonal damage and demyelination.<sup>[1]</sup> Clinically, RIBP is characterized by progressive decline in muscle strength in the upper limbs, numbness and tingling that can appear months or years before diagnosis.

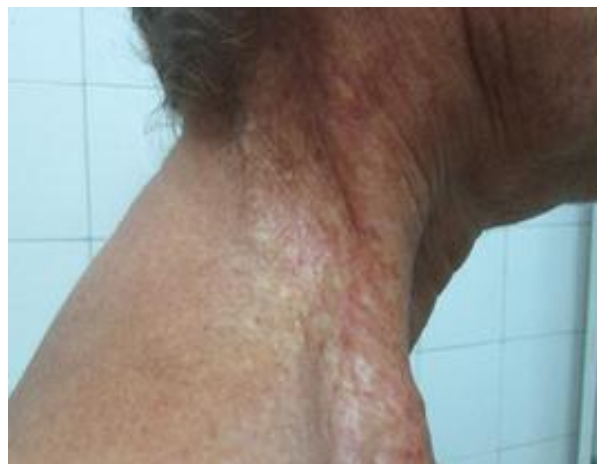**CASE PRESENTATION**

We present a 72 years old woman patient with a slowly progressive bilateral brachial plexopathy and carotid arterial disease after radiotherapy for nasopharyngeal carcinoma. RIBP diagnosis was based on history of radiotherapy after cancer, clinical features, neurological and electrophysiological exams.

**Clinical assessment**

The patient was diagnosed thirty two years ago with nasopharyngeal cancer and she was treated with radiation therapy. For the last fifteen years she developed paraesthesia on the left and right lateral side of the arms, forearms, hands and thumbs. Also pain, weakness, fasciculations and muscle atrophy in the upper arms were recorded. She has presented skin pigmentation and endured area on the anterior part of the neck from the moment of radiotherapy (Fig. 1).

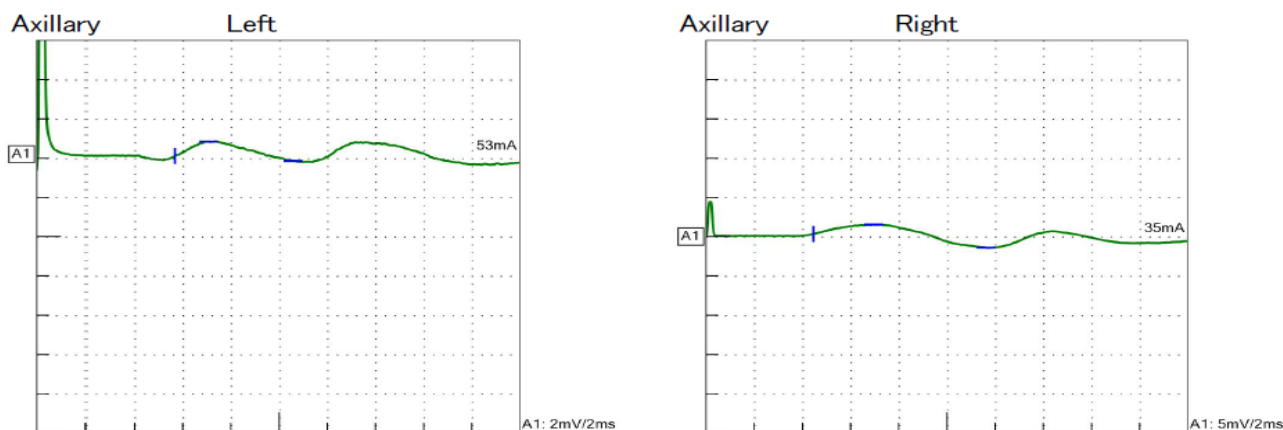
Neurological examination showed facial simetry, decreased visual acuity of both eyes with normal visual field, normal oculomotricity, and no olfactory or sensory abnormalities on face, no nistagmus, but positive Romberg test, without deglutition problems for liquid or solid foods. Motor examination revealed right and left loss of shoulder flexion, internal rotation and abduction worsen on the left part, tendon jerks depressed on biceps and brachioradialis, atrophy of bilateral deltoid, biceps, supraspinatus and infraspinatus accentuated and with fasciculation on the left side. Sensory loss on left and right lateral side of the arm, forearm, hand and thumb were also recorded.



**Figure 1: Skin pigmentation and endured area on the anterior part of the neck.**

**Electrophysiological study**

Nerve conduction study showed a reduced nerve conduction velocity, prolonged latency, and decreased amplitude in motor axillar nerves, antebrachial cutaneus nerves, sensory radial nerves, and right sensory and motor median nerve (Fig. 2).



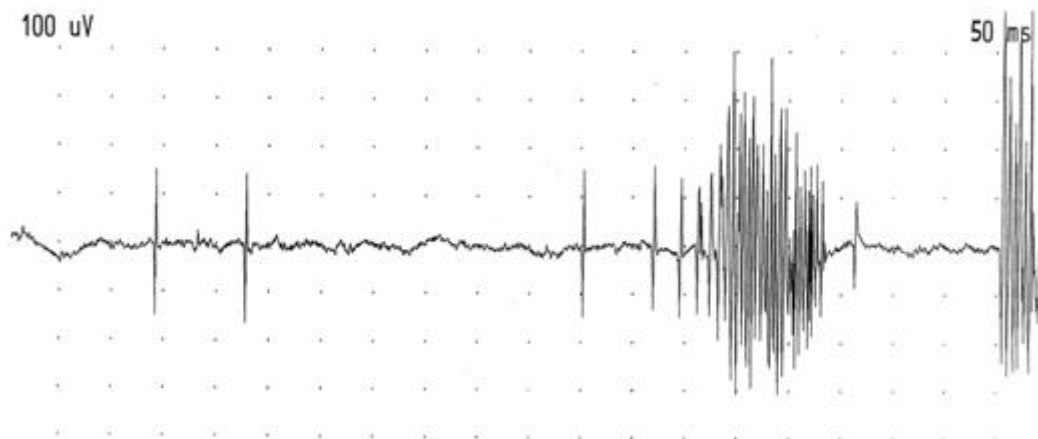
**Figure 2: Nerve conduction study – motor response axillary nerve.**

Needle electromyographic examination revealed myokymic discharges, fibrillation and positive sharp waves on bilateral medial deltoid and biceps brachii

muscles, motor unit potential varying in morphology and decreased recruitment. All these findings suggested a neurogenic pattern (Table 1 and Fig. 3).

**Table 1: Electromyography findings summary (Nihon Kohden).**

Muscle	Side	Insertional Activity	Fibs and Pos.wave	Fasc	Myokymic discharges	Normal MUP	Low Amp	High Amp	Durate	Recruitment
Biceps brachii	Right	Increased	+3	+3	+1	+1	0	+3	Long	Reduce
Biceps brachii	Left	Increased	+3	+3	+1	+1	0	+3	Long	Reduce
Deltoideus	Right	Increased	+3	+3	+1	+2	0	+2	Long	Reduce
Deltoideus	Left	Increased	+3	+2	+1	+1	0	+3	Long	Reduce



**Figure 3: Electromyography - myokymic discharges on biceps brachii.**

### Cerebrovascular ultrasonography

Doppler echography of cervical vessels showed bilateral carotid stenosis (98% right internal carotid and 50% left internal carotid arteries). This results were confirmed using cerebral angiography.

### DISCUSSIONS

We presented a case of 72 years old women who developed RIBP and carotid arterial disease following a nasopharyngeal cancer treated with big doses of radiation. At moment of examination, she presented bilateral brachial plexopathy, skin enduration and hyperpigmentation of the neck caused by radiation, critical right carotidian stenosis and 75 % stenosis on the left carotid. Previous studies showed that the mean latency at the onset of RIBP was 4.26 years,<sup>[6]</sup> with a large variation spanning from 1 to 17 years.<sup>[7]</sup> In our case, the onset of clinical features was later, with progressive and irreversible symptoms. The most common clinical features are paraesthesia, various types of pain in the shoulder and upper arms and weakness.<sup>[6,7]</sup> In this type of plexopathy no successful treatment is available, therefore the prevention is very important.<sup>[8]</sup>

RIBP is a slow and gradual process with still unknown pathophysiology. Among the hypothesis of the pathogenesis of the RIBP are inflammation, followed by vascular lesions and fibrosis around the brachial plexus that can determine ischemia and nerve demyelination.<sup>[9]</sup>

Electromyography plays an important role in diagnosis and monitoring of patients with disorders of the peripheral nervous system and it was used to differentiate between a neurogenic and a myogenic process. Electromyography reveals essential data about the motor unit function and the extension of the lesions. Electrophysiological study in our case showed a chronic and bilateral brachial plexus lesions affecting the upper trunk and partially the middle trunk. Myokymic discharges are involuntary grouped repetitive discharges of the same motor unit, with a firing frequency within burst between 5 to 60 Hz. They are determined by spontaneous depolarization in demyelinated segment of

the nerves. Myokymic discharges are associated with radiation plexopathy and not with tumor infiltration or motor neuron disease. These findings of myokymic discharges in deltoid, biceps brachii muscle as recorded in our patient, are most characteristically seen in radiation plexopathy and help us make the differential diagnosis with a motor neuron disease or with cancer invasion of the brachial plexus.<sup>[10]</sup>

Carotid arterial disease can be determine or worsen in patients with radiation therapy in cervical region.<sup>[11]</sup> Studies showed that the carotidian intima-media thickness was significantly increased in nasopharyngeal carcinoma patients treated with radiation.<sup>[12]</sup> The atherosclerotic process starts with a dysfunction of the endothelial cells because of the radiation exposure.<sup>[13]</sup> Second nuclear disruption, platelet aggregation and fibrin deposition are produced.<sup>[14]</sup> and in this way the endothelium becomes thicker. In our case, the radiation exposures determine important bilateral stenosis demonstrated through Doppler ultrasonography and also cerebral angiography.

Radiation-induced arteritis of large vessels and brachial plexus neuropathy are rare delayed complications of local radiation therapy.<sup>[15]</sup> Therefore, the particularity of our case is the association between carotid arterial disease and bilateral brachial plexopathy caused by radiation therapy.

In conclusion, RIBP is a rare complication of radiotherapy in nasopharyngeal carcinoma patients. Electromyography plays an essential role in the differential and positive diagnosis of delayed radiation-induced brachial plexopathy, showing typical changes - myokymic discharges.

### REFERENCES

1. Delanian S, Lefaix JL, Pradat PF. Radiation-induced neuropathy in cancer survivors. *Radiother Oncol*, 2012; 105(3): 273-82.
2. Powell S, Cooke J, Parsons C. Radiation-induced brachial plexus injury: follow-up of two different

- fractionation schedules. *Radiother Oncol*, 1990; 18(3): 213-20.
3. Wittenberg KH, Adkins MC. MR imaging of nontraumatic brachial plexopathies: frequency and spectrum of findings. *Radiographics*, 2000; 20(4): 1023-32.
  4. Rubin DI, Schomberg PJ, Shepherd RF, Panneton JM. Arteritis and brachial plexus neuropathy as delayed complications of radiation therapy. *Mayo Clin Proc*, 2001; 76(8): 849-52.
  5. Galecki J, Hicer-Grzenkiewicz J, Grudzien-Kowalska M, Michalska T, Zalucki W. Radiation-induced brachial plexopathy and hypofractionated regimens in adjuvant irradiation of patients with breast cancer--a review. *Acta Oncol*, 2006; 45(3): 280-4.
  6. Cai Z, Li Y, Hu Z, Fu R, Rong X, Wu R, Cheng J, Huang X, Luo J, Tang Y. Radiation-induced brachial plexopathy in patients with nasopharyngeal carcinoma: a retrospective study. *Oncotarget*, 2016; 7(14): 18887-95.
  7. Gu B, Yang Z, Huang S, Xiao S, Zhang B, Yang L, Zhao J, Zhao Z, Shen J, Liu J. Radiation-induced brachial plexus injury after radiotherapy for nasopharyngeal carcinoma. *Jpn J Clin Oncol*, 2014; 44(8): 736-42.
  8. Johansson S. Radiation induced brachial plexopathies. *Acta Oncol*, 2006; 45(3): 253-7.
  9. Gosk J, Rutowski R, Reichert P, Rabczyński J. Radiation-induced brachial plexus neuropathy - aetiopathogenesis, risk factors, differential diagnostics, symptoms and treatment. *Folia Neuropathol*, 2007; 45(1): 26-30.
  10. Preston DC, Shapiro BE. Basic electromyography: Analysis of spontaneous activity. In: D.C. Preston, B.E. Shapiro, eds. *Electromyography and neuromuscular disorders*. 2nd edition. Philadelphia: Elsevier, 2005; 199-213.
  11. Xu J, Cao Y. Radiation-induced carotid artery stenosis: a comprehensive review of the literature. *Interv Neurol*, 2014; 2(4): 183-92.
  12. Huang TL, Hsu HC, Chen HC, Lin HC, Chien CY, Fang FM, Huang CC, Chang HW, Chang WN, Huang CR, Tsai NW, Kung CT, Wang HC, Lin WC, Cheng BC, Su YJ, Chang YT, Chang CR, Tan TY, Lu CH. Long-term effects on carotid intima-media thickness after radiotherapy in patients with nasopharyngeal carcinoma. *Radiat Oncol*, 2013; 8: 261.
  13. Murros KE, Toole JF. The effect of radiation on carotid arteries. A review article. *Arch Neurol*, 1989; 46(4): 449-55.
  14. Fonkalsrud EW, Sanchez M, Zerubavel R, Mahoney A. Serial changes in arterial structure following radiation therapy. *Surg Gynecol Obstet*, 1977; 145(3): 395-400.
  15. Rubin DI, Schomberg PJ, Shepherd RF, Panneton JM. Arteritis and brachial plexus neuropathy as delayed complications of radiation therapy. *Mayo Clin Proc*, 2001; 76(8): 849-52.