

ORAL LICHEN PLANUS: THREE CASE REPORTS IN CHILDREN***Dr. Sonam C. Kapse, Dr. Vaibhav Ladke, Dr. Garima D. Yadav, Parag Juvele, Dr. Sharmeen F. Shaikh,**

MDS.

***Corresponding Author: Dr. Sonam C. Kapse**

MDS.

Article Received on 26/12/2017

Article Revised on 16/01/2018

Article Accepted on 06/01/2018

ABSTRACT

Lichen planus (LP) is an autoimmune cell-mediated mucocutaneous condition which is mostly chronic and inflammatory in nature. It is commonly affecting adults but rarely can be seen in children. The purpose of this study is to report a case series of Oral Lichen Planus in three paediatric patients with age range of 10 to 12 years involving the tongue and buccal mucosa. On clinical evaluation, typical white reticular striated lesions in tongue and buccal mucosa were observed with or without cutaneous lesions. Diagnosis was made based on clinical examination and histopathological features. Active treatment was started. The patients were evaluated on regular periodic basis. Although L.P. is rarely reported in childhood, it should be considered in a differential diagnosis of hyperkeratotic and/or erosive lesions of the oral mucosa in children.

KEYWORDS: Lichen Planus; Lichenoid reaction; childhood.**1. INTRODUCTION**

Lichen planus (LP) is a chronic inflammatory mucocutaneous condition, which was first described in 1869 by Erasmus Wilson. The oral lesions are more diverse than those of their skin counterparts and have been categorized as reticular, papular, plaque-like, atrophic, erosive, and bullous. These different clinical presentations represent variations of duration and intensity of the disease. The diagnostic criteria of oral lichen planus (OLP) must include both clinical and histopathological features. Bilateral and more or less symmetrical lesions with striations are important and mandatory.^[1] The histopathology of the lesion must present a well-defined band like area of cellular infiltration confined to the superficial part of the connective tissue, liquefaction degeneration of the basal cell layer and absence of epithelial dysplasia to call it as a lichen planus.^[1]

Oral lichen planus is considered relatively common in adults and rarely affecting childhood with few reports available in the literature.^[2-5] The exact etiology of the LP is obscured, but many factors have been implicated like graft-versus-host disease, active hepatitis, hepatitis B immunization and autoimmune diseases are frequently mentioned in the literature.^[3,4,6,7] It has been also observed that OLP in children is more common in the tropical countries.^[8] According to study of 420 Iranian patients with histopathologically -confirmed OLP, less than 1% had developed OLP before the age of 13^[9]. Here we are presenting case series of oral lichen planus rarely affecting children and discusses the importance of

clinicopathological correlation and considering OLP in the differential diagnosis of hyperkeratotic lesions or erosive lesions of the oral cavity in children.

2. CASE SERIES

Here we present a case series of three male paediatric clinically diagnosed and histologically confirmed patients of oral lichen planus with age range from 10 to 12 years. These patients were reported to the OPD of Department of oral pathology M. A. Rangoonwala Dental College, Pune for evaluation of oral lesions with chief complaints of burning sensation while having food.

CASE NO 1

A 12 year old male patient had presented with chief complaint of burning sensation while having spicy food in the cheek region since 3 months. Intraoral examination revealed an ulcerated lesion with black borders and interspersed with white striations which are flat and tender on palpation present in the commissure regions spreading to labial and buccal mucosa [figure 1a]. An incidental finding of mesiodens and buccally placed upper canine were also present. The patient's oral hygiene was excellent and was not having any dental restorations. Skin lesions were also present in the neck and below the navel regions [figure 1b].

An incisional biopsy from the representative area of the lesion was performed. Histopathological examination showed hyperparakeratosis of stratified squamous epithelium. Basal cell degeneration with dense band of

lymphocytic infiltration at subepithelial area was noticed. [figure 1c]. Both clinical and histopathological features were suggestive of oral lichen planus. Patient was given 0.05% Tretinoin cream and the skin lesions were

managed with topical corticosteroids under the guidance of dermatologist. The patient was followed periodically for the total time of 1 year 16 months during the course of treatment.

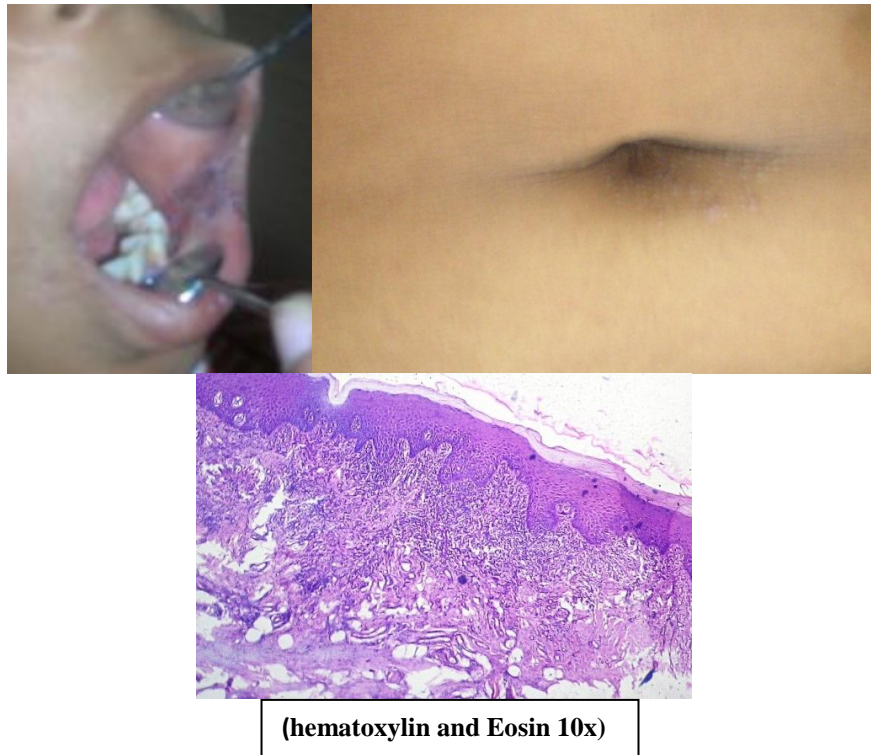


Figure 1: A-intraoral lesion, b-around umbilical area, c-histopathological features.

CASE NO 2

An eleven year old male patient was reported with chief complaint of burning sensation in cheek and tongue region during meals since 3 months. On clinical examination grayish white striated patches along with slight erythematous areas were present on the dorsum of the tongue [figure 2a]. Detailed history of any drug intake or any drug allergy along with history of any dental restoration was investigated from the patient and his parents and there was no positive history for the same. The lesion was present for the last three to four months and there were no associated skin lesions.

Incisional biopsy was performed and histopathological features revealed hyperparakeratotic stratified squamous epithelium and basal cell degeneration at places, with subepithelial band of dense lymphocytic infiltration, suggestive of oral lichen planus [figure 2b]. Active treatment of OLP with corticosteroids and multivitamins were started and topical anesthetics were given for burning sensation. Patient was observed with regular and periodic follow up. The patient reported relief from the symptoms during the course of treatment.

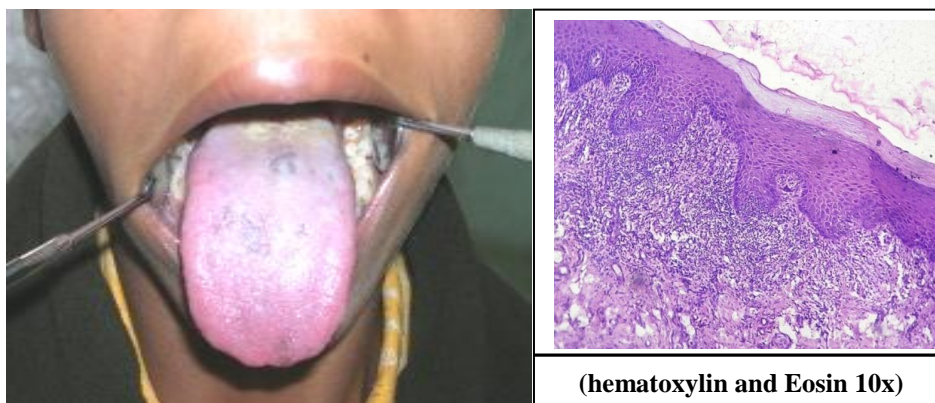
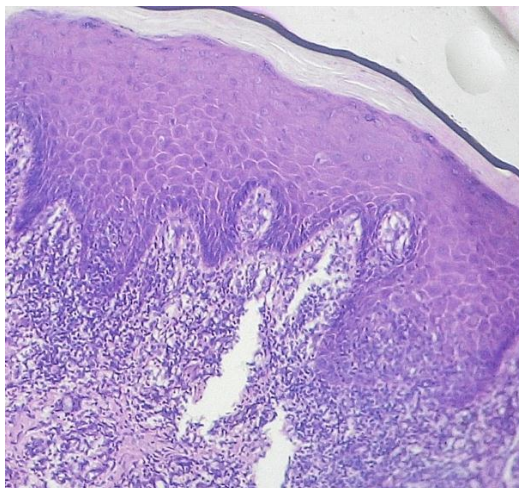
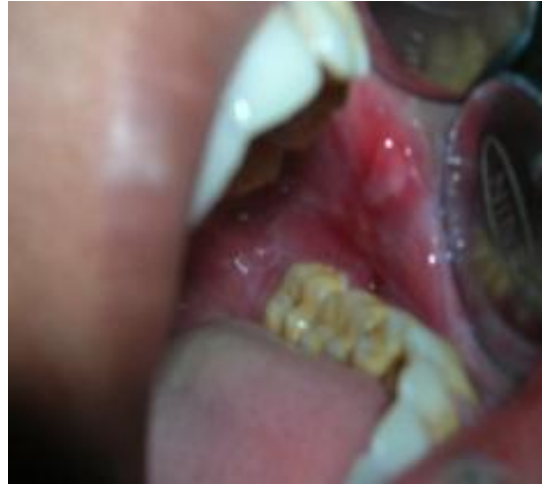

Figure 2: A-intraoral lesion on the tongue, b-histopathological features.

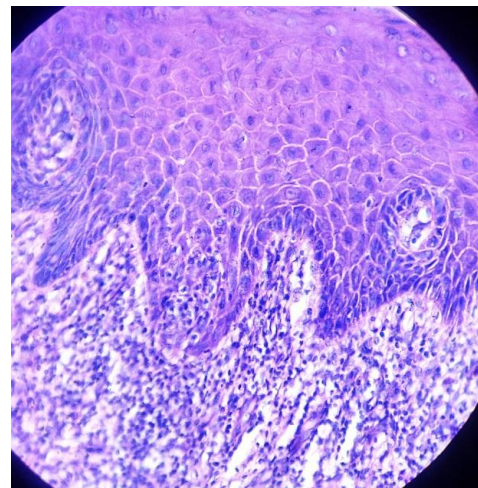
CASE NO 3

A ten year old male patient was reported with chief complaints of burning sensation during eating food for the last three months. On clinical examination bilaterally on the buccal mucosa grayish white striations with an erythematous base was noted [figure 3a,3b]. Calculus was present on the left mandibular and maxillary posterior teeth area. No associated skin lesions were present. No positive history of any drug intake or any drug allergy along with history of any dental restoration was given by the patient and his parents.

Incisional biopsy was performed and on histopathological examination typical features of oral lichen planus were found like hyperparakeratotic stratified squamous epithelium and subepithelial band of dense lymphocytic infiltration [figure 3c]. Patient was given topical anesthetics as a palliative treatment along with other supplementary medicines followed by regular and periodic follow. In next visit patient reported gradual relief of burning sensation during the course of treatment.



(hematoxylin and Eosin 10x)



(hematoxylin and Eosin 40x)

Figure 3: a-intraoral lesion on the tongue, b-histopathological features**3. DISCUSSION AND REVIEW OF LITERATURE**

Lichen planus (LP) is predominately considered to be a chronic inflammatory mucocutaneous disease of the middle aged or older patients which was first reported and named in 1869 by British physician Erasmus Wilson.^[17,18]

Although the exact etiology of OLP is not well understood it is considered as a multifactorial lesion. However, OLP occurrence is related to a T-cell mediated

immune response. Activation of the inflammatory mediator nuclear factor kappaB (NFκβ),^[21] and the inhibition of the transforming growth factor(TGF), control signaling pathway which may result in the hyperproliferation of keratinocytes, thereby causing the white lesions in OLP.^[22] Recent studies suggest that OLP is a T-cell mediated autoimmune disease in which autotoxic CD8+ T-cells trigger the apoptosis of oral epithelial cells, leading to basal cell degeneration and chronic inflammation.^[23,24] In our case series for all 3

cases etiology is unknown as there was absence of any clinically appearing contributing factor or other relevant positive drug or dental treatment history.

Occurrence of OLP is very rare approximately 0.5-2% of population having peak incidence of 30-60 years^[19] with female predominance of 2:1.^[20] The reported prevalence of OLP in childhood is 0.03 percent, which is significantly lower than that seen in adults. This difference in prevalence rates has been partially attributed to the age factor where low number of associated systemic diseases, autoimmune phenomena, drugs, and dental restorations in childhood are seen.^[25,26] In adults, LP occurs more commonly in females, but reports of LP in children showed discrepancies. According to some studies there is no consistent gender predilection for LP in children.^[14] In contrast, Walton *et al.*^[7] (2010) reported a female predominance (female to male ratio 2:1) in 36 patients. However, in large series of OLP conducted by many different investigators,^[11-13] boys are affected more common than girls. Similar results related to gender predilection were seen in a study done by Alam and Hamburger (2001),^[3] where all 6 reported cases were boys.

Approximately 15% of patients with OLP exhibit absence or presence of cutaneous involvement and associated lesions.^[27] This finding was in accordance with our case series where out of 3 only 1 case exhibited cutaneous lesions. Handa and Sahoo^[28] had reported that seven out of 87 cases of childhood lichen planus presented with concomitant involvement of the oral mucosa and that only one child had isolated OLP. They suggested that oral mucosa involvement in children with lichen planus was less when compared with adults. However, Sharma and Maheshwari^[29] reported concomitant oral lesions in 15 cases out of the total 50 children affected with LP..

An Arabian study revealed that in paediatric cases occurrence of LP was 7.5%.^[10] However, this is not the case with an Indian or Asian population. In addition, the largest reported series of lichen planus in childhood reported, originates from India.^[11,12]

Some studies have demonstrated that oral involvement of LP is extremely uncommon in children. Walton *et al.* (2010)^[7] showed that 8 out of 36 children presented oral lesions. Moreover, the largest series of paediatric LP, which evaluated 100 children, 17 of them presented OLP.^[12] The familial occurrence of oral lichen planus is also very rare with few cases reported in the literature so far. Milligan^[33] have reported a case series of 6 lichen planus patients in childhood where three patients showed familial tendency of lichen planus. It was observed that childhood familial lichen planus shows more severity of symptoms and has an early onset in terms of age.^[33]

The clinical features of OLP seen in children are essentially the same as those seen in adults, and

commonly affected sites are buccal mucosa, lateral part of the tongue, and the gingiva.^[2-4] There is a wide range of oral lichenoid lesions that can be considered as a differential diagnosis of OLP. It consists of several clinical presentations.^[16]

- 1) Oral lichenoid contact lesions: this is a result of allergic contact stomatitis, where the lesions are seen in close contact with dental restorative materials, like amalgam, or other contacted agents/materials.
- 2) Oral lichenoid drug reaction: In this oral and/or skin lesions are seen in association with certain medications, such as oral hypoglycemic agents, angiotensin-converting enzyme inhibitors, and non-steroidal anti-inflammatory agents.
- 3) Oral lichenoid lesions of graft-versus-host disease: This is a common complication of allogeneic hematopoietic stem-cell or bone marrow transplantation.^[16]

Therefore identification and elimination of such factors that may precipitate or provoke oral lesions is an important initial step in diagnosis and treatment of oral OLP. Our patients had no relevant medical or family history, nor presented any deleterious oral habits and their oral hygiene was excellent, with no dental restorations.

The differential diagnosis of OLP in children may be quite extensive and, depends on many factors like the age of the patient, the clinical variant, and the severity and the persistence of the lesions which includes leukoplakia, recurrent aphthous stomatitis, candidiasis, lupus erythematosus, auto-immune bullous diseases, several viral infections (herpes simplex, Epstein-Barr, Coxsackie, HIV), erythema multiforme, and very rarely Crohn and Behçet diseases, dyskeratosis follicularis, pachyonychia congenita, dyskeratosis congenita.^[15]

Clinically and histopathologically, lichenoid reactions may be indistinguishable from OLP. However, the distinguishing features of oral lichenoid contact lesions are the lesion's direct contact with the suspected causative agent, (e.g. amalgam restorations, composites, cinnamon etc). Removal of these suspected causative factors should result in resolution of the lesion, which helps in distinguishing Lichenoid contact lesions from OLP thereby establishing the diagnosis.^[16]

Children affected with OLP are often asymptomatic or minimally symptomatic.^[28] The recommended treatment for most cases of lichen planus is controlling the severity of symptoms.^[30] The most widely accepted treatment for lesions of OLP includes topical or systemic corticosteroids. Treatment of choice for mild to moderate symptomatic OLP is topical corticosteroids because they have fewer side effects. However, in case of widespread, symptomatic lesions systemic drugs are given.^[31,32] Topical treatment options for OLP includes corticosteroids like topical Cloben-G, isotretinoin gel, multi vitamins and minerals, tacrolimus.^[4,11,12] In our

case series patients were prescribed topical anesthetics and corticosteroids with multivitamins. As OLP is an inflammatory condition where local irritants, such as plaque and calculus, consistently trigger exacerbations hence plaque control and maintenance of oral hygiene is crucial part of treatment.

The prognosis and the effect of treatment in OLP in children seem to be more favorable and effective than in adults. Oral lesions in adults usually persists for many years in spite of intensive treatment and thorough investigation of associated factors.^[3,5] Malignant transformation of OLP in adults, especially the erosive variety, has been documented, with about 0.07% to 5%.^[5,9]

Many of the aspects of OLP in children like treatment modalities, prognosis, age of preference, and the boy-to-girl ratio, have to be studied in detail because of less occurrence of OLP in children and very few cases have been reported in the literature. Nevertheless, the schedule of follow-up of OLP in children and also the removal of local irritant factors should be done at regular intervals like once or twice a year, as long as OLP persists and even more frequently in symptomatic cases. Although oral lichen planus in childhood is rare, this diagnosis should be considered in children presenting with oral white lesion.

SUMMARY AND CONCLUSION

Oral lichen planus is a cell-mediated autoimmune condition which is rarely documented in children with an overall prevalence of around 0.03 percent in childhood. Reports of oral lichen planus affecting children are very few in the literature. Oral lesions like grayish white striations with erythematous base and associated symptoms of burning sensation during eating suggest OLP which when treated with topical corticosteroid, multivitamins with maintenance of good oral hygiene resulted in favorable results. Although OLP in childhood is rare, careful clinical examination, proper diagnosis, and management should be done.

Our case series suggest that OLP in children may present same classical lichen Planus features without having any positive medical history or any other relevant history of drug allergy or dental restoration. Regular and periodic follow-up visits should be emphasized to evaluate possible malignant transformation which is not reported in the literature till date.

REFERENCES

1. Van der Meij, E.H. and Van der Waal, I. Lack of clinicopathologic correlation in the diagnosis of oral lichen planus based on the presently available diagnostic criteria and suggestions for modifications. *Journal of Oral Pathology and Medicine*, 2003; 32: 507-512.

2. Scully, C., de Almeida, O.P. and Wellbury, R. Oral lichen planus in childhood. *British Journal of Dermatology*, 1994; 134: 131-133.
3. Alam, F. and Hamburger, J. Oral mucosal lichen planus in children. *International Journal of Paediatric Dentistry*, 2001; 11: 209-214.
4. Laeijendecker, R., Joost, T.V., Tank, B., *et al.* Oral lichen planus in childhood. *Pediatric Dermatology*, 2005; 22: 299-304.
5. Eisen, D. The clinical features, malignant potential, and systemic associations of oral lichen planus: A study of 723 patients. *Journal of the American Academy of Dermatology*, 2002; 46: 207-214.
6. Cottoni, F., Ena, P., Tedde, G., *et al.* Lichen planus in children: A case report. *Pediatric Dermatology*, 1993; 10: 132-135.
7. Walton, K.E., Bowers, E.V., Drolet, B.A., *et al.* Childhood lichen planus: Demographics of US population. *Pediatric Dermatology*, 2010; 27: 34-38.
8. Ramsay, D.L. and Hurley, H.J. Papulosquamous eruptions and exfoliative dermatitis. In: Moschella, S.L. and Hurley, H.J., Eds., *Dermatology*, Vol. 1, 2nd Edition, W.B. Saunders, Philadelphia, 1985; 529-535.
9. Pakfetrat, A., Javadzadeh-Bolouri, A., Basir-Shabestari, S., *et al.* Oral lichen planus: A retrospective study of 420 Iranian patients. *Medicina Oral Patologia Oral y Cirurgia Bucal*, 2009; 14: E315-E318.
10. Kanwar, A.J. and Belhaj, M.S. Lichen planus among Arabs—A study from Libya. *The Journal of Dermatology*, 1984; 11: 93-96.
11. Sharma, R. and Maheshwari, V. Childhood lichen planus: A report of fifty cases. *Pediatric Dermatology*, 1999; 16: 345-348.
12. Kanwar, A.J. and D. De Lichen planus in childhood: Report of 100 cases. *Clinical and Experimental Dermatology*, 2010; 35: 257-262.
13. Balamasubramanian, P., Ogboli, M. and Moss, C. Lichen planus in children: Review of 126 cases. *Clinical and Experimental Dermatology*, 2008; 33: 457-459.
14. Handa, S. and Sahho, B. Childhood lichen planus: A study of 87 cases. *International Journal of Dermatology*, 2002; 41: 423-427.
15. Yiannias, J.A., El-Azhary, R.A., Hand, J.H., *et al.* Relevant contact sensitivities in patients with the diagnosis of oral lichen planus. *Journal of the American Academy of Dermatology*, 2000; 42: 177-182.
16. Al-Hashimi, I., Schifter, M., Lockhart, P.B., *et al.* Oral lichen planus and oral lichenoid lesions: Diagnostic and therapeutic considerations. *Oral Surgery, Oral Medicine, Oral Pathology, Oral Radiology, and Endodontology*, 2007; 103: e1-e12.
17. Neville domm, Oral and maxillofacial pathology 3rd edition page: 782- 788 publisher Elsevier, 2009.
18. Nelson L. Rhodes, Sandra Myers, Shanti Kaimal Diagnosis and management of Oral Lichen

- Planus.Northwest Dentistry. Journal of Minnestra. Dentalassociation, March-April 2003; 82(2).
19. Marzich Boorghni, Narges Gholizadeh, Ali TaghaviZenoyz, Mehdi Vatankhak, Mansoumeh, Mehdipan. Orallichen planus: clinical features, etiology, treatment andmanagement. A review of literature Journal of DentalResearch, Dental Clinics, Dental Prospects, winter 2010; 4(1).
 20. Farzane Aghahosseini, Fateme Arbadi kalati, Leila AbaieFashtami, Mohsen Fatch, Gholam reza Esmaeeli Djauid.Treatment of oral lichen planus with photodynamictherapy mediated methylene blue. A case report MedOral Pato| Oral Cir Buccal, 2006; 11: E126-9.
 21. Santoro A, Majorana A, Bardellini E, Festa S, Sapelli P, Facchetti F. NF-kappaB expression in oral and cutaneous lichen planus. J Pathol, 2003; 201: 466-72.
 22. Karatsaidis A, Schreurs O, Axell T, Helgeland K, Schenck K. Inhibition of the transforming growth factor-beta/Smad signaling pathway in the epithelium of oral lichen. J Invest Dermatol, 2003; 121: 1283-90.
 23. Kim SG, Chae CH, Cho BO, Kim HN, Kim HJ, Kim IS et al. Apoptosis of oral epithelial cells in oral lichen planus caused by upregulation of BMP-4. J Oral Pathol Med, 2006; 35: 37-45.
 24. Ismail SB, Kumar SK, Zain RB. Oral lichen planus and lichenoid reactions: etiopathogenesis, diagnosis, management and malignant transformation. J Oral Sci, 2007; 49: 89-106.
 25. Eisen D. The clinical features, malignant potential, and systemic associations of oral lichen planus: a study of 723 patients. J Am Acad Dermatol, 2002; 46: 207-14.
 26. Alam F, Hamburger J. Oral mucosal lichen planus in children. Int J Paediatr Dent, 2001; 11: 209-14.
 27. Eisen D. The evaluation of cutaneous, genital scalp, nail, esophageal, and ocular involvement in patients with oral lichen planus. Oral Surg Oral Med Oral Pathol Oral Radiol Endod, 1999; 88: 431-6.
 28. Handa S, Sahoo B. Childhood lichen planus: a study of 87 cases. Int J Dermatol, 2002; 41: 423-27.
 29. Sharma R, Maheshwari V. Childhood lichen planus: a report of 50 cases. Pediatr dermatol, 1999; 16: 345-8.
 30. Chainani-Wu N, Silverman S Jr, Lozada-Nur F, Mayer P, Watson JJ. Oral lichen planus: Patient profile, disease progression and treatment responses. J Am Dent Assoc, 2001; 132: 901-9.
 31. Scully C, Carrozzo M. Oral mucosal disease: Lichen planus. Br J Oral Maxillofac Surg, 2008; 46: 15-21.
 32. Edwards PC, Kelsch R. Oral lichen planus: Clinical presentation and management. J Can Dent Assoc, 2002; 68: 494-9.
 33. Milligan A, Graham-Brown RA. Lichen planus in children--a review of six cases.Clin Exp Dermatol, 1990 Sep; 15(5): 340-2.