

## A PROSPECTIVE STUDY OF EPIDEMIOLOGICAL FACTORS & CLINICAL PROFILES OF INTRA-CEREBRAL HEMORRHAGE CASES IN TERTIARY HEALTH CENTER IN SOUTHERN MAHARASHTRA AND HENCE EVALUATING COMPUTED TOMOGRAPHY AS ITS DIAGNOSTIC MODALITY

Dr. Nitin Jadhav<sup>1</sup> and Dr. Vikram Rode<sup>2\*</sup>

<sup>1</sup>Associate Profesor, Department of Medicine, Krishna Institute of Medical Sciences, Deemed University, Karad.

<sup>2</sup>Junior Resident, Department of Medicine, Krishna Institute of Medical Sciences, Deemed University, Karad.

\*Corresponding Author: Dr. Vikram Rode

Junior Resident, Department of Medicine, Krishna Institute of Medical Sciences, Deemed University, Karad.

Article Received on 09/10/2017

Article Revised on 30/10/2017

Article Accepted on 20/11/2017

### ABSTRACT

**Introduction:** Intracerebral hemorrhage (ICH) is a common devastating neurologic event that causes high morbidity and mortality with profound economic implication. Mortality depends on the size of the hematoma and on the location of the brain. The present study was carried out to study clinical presentations of cerebral hemorrhage and hence to correlate the clinical findings with neuroimaging techniques. **Methods:** It was a prospective study carried out among suspected cases of cerebral hemorrhage. Every patient was interviewed personally and detailed history was taken followed by clinical, systemic and neurological examination. Results were analyzed comparing clinical diagnosis, sites of lesions, nature of lesions and CT scan findings. **Results:** Out of 36 patients of cerebral hemorrhage, 26 (72%) were males and 10 (28%) were females. 58% cases presented with headache, 16.6% with convulsions and 27.7% with vomiting (Table 3). When we assessed cases according to their systolic blood pressure (SBP), we found that significantly larger number of cases presented with systolic blood pressure above 140 mmHg. **Conclusions:** In intracerebral hemorrhage CT scan may help to plan a surgical therapy for hematomas in a rapidly deteriorating patient.

**Keywords:** Intra-cerebral hemorrhage, CT scan, Stroke, hypertension.

### INTRODUCTION

An intracerebral hemorrhage (ICH) account for only 15% of all strokes but it is one of the most disabling forms of stroke.<sup>[1]</sup> Greater than one third of patients with intracerebral hemorrhage (ICH) will not survive and only twenty percent of patients will regain functional independence.<sup>[2]</sup> Intracerebral hemorrhage (ICH) is a common devastating neurologic event that causes high morbidity and mortality with profound economic implication. ICH will seem to continue to be an important problem in both India and other developed countries. Nontraumatic ICH occurs due to bleeding from a vascular source directly into the brain substance. It is a major public health problem with an annual incidence of 10–30/100,000 population, accounting for 2 million (10–15%) of about 15 million strokes worldwide each year.<sup>[3]</sup> Approximately, 35–50% of patients with ICH die within the 1 month after bleeding. Data from the Asian Stroke Advisory Panel revealed an incidence of ICH ranging from 17% to 33% of all strokes, twice as high as in Western countries.<sup>[4]</sup> Mortality depends on the size of the hematoma and on the location of the brain. The most important risk factors for ICH include

hypertension (HTN) and cerebral amyloid angiopathy (CAA) tends to occur in association with advanced age, and CAA-related ICH tends to occur in lobar regions. Other risk factors for ICH include.<sup>[5]</sup>

- Alcohol intake: This risk appears to be dose-dependent, with a higher risk of ICH among those with a higher daily alcohol intake. Acute changes in blood pressure during ingestion and withdrawal, effects on platelet function and coagulation, and dysfunction of the vascular endothelium may account for this risk.
- Cholesterol: Low levels of total serum cholesterol are risk factors for ICH (in contrast to ischemic stroke, for which high cholesterol levels are a risk).<sup>[6]</sup>
- Genetics: The gene most strongly associated with ICH is the Apolipoprotein E (APOE) gene and its  $\epsilon 2$  and  $\epsilon 4$  alleles. The presence of the  $\epsilon 2$  allele was recently also linked to hematoma expansion.
- Anticoagulation: Oral anticoagulants are widely used as prophylaxis in patients with atrial fibrillation and other cardiovascular and prothrombotic states. The annual risk of ICH in patients taking warfarin

ranges from 0.3 to 1.0% per patient-year with a significantly increased risk when the INR is  $>3.5$ .<sup>[7]</sup>

- e) Drug abuse: Sympathomimetic drugs, such as cocaine, are risk factors for ICH, and patients actively using cocaine at the time of their ICH have significantly more severe presentations and worse outcomes.<sup>[8]</sup>

The present study was carried out to study clinical presentations of cerebral hemorrhage and hence to correlate the clinical findings with neuroimaging techniques available (CT scan).

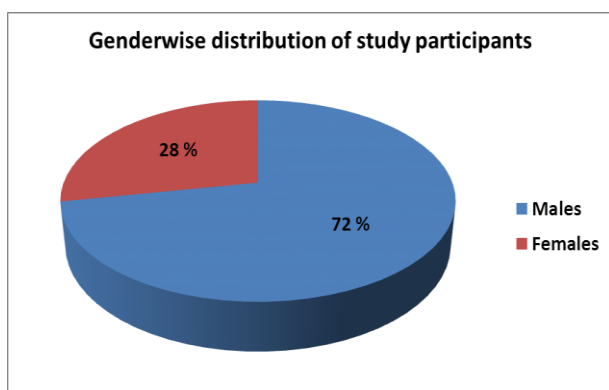
## METHODOLOGY

It was a prospective study carried out among suspected cases of cerebral hemorrhage, admitted under department of general medicine in Krishna Institute of Medical Sciences, Karad during the period of Feb 2017 to August 2017.

Cases of transient ischemic accidents were excluded. Every patient was interviewed personally and detailed history was taken followed by clinical, systemic and neurological examination. Results were analyzed comparing clinical diagnosis, sites of lesions, nature of lesions and CT scan findings.

**Table 1: Distribution of Cerebral hemorrhage cases according to age and sex.**

Age group	Male cases (%)	Female cases (%)	Total cases
Less than 40 years	1 (3.8%)	1 (10%)	2 (5.5%)
41-50	6 (23.07%)	1 (10%)	7 (19.44%)
51-60	2 (7.69%)	5 (50%)	7 (19.44%)
61-70	10 (38.46%)	2 (20%)	12 (33.33%)
More than 70	7 (26.92%)	1 (10%)	8 (22.22%)
<b>Total</b>	<b>26 (100%)</b>	<b>10 (100%)</b>	<b>36 (100%)</b>



**Figure 1: Distribution of Cerebral hemorrhage cases according to their gender.**

When we tried to assess modes of presentation of cerebral hemorrhage, we found that 19.4% cases were conscious, 25% cases presented in drowsy state whereas majority of cases i.e. 55.55 % cases presented in unconscious state (Table 2).

Patients presenting with sudden onset of neuro-deficit, with raised intracranial pressure including deterioration of consciousness were considered as:

1. Intra cerebral hemorrhage
2. Subarachnoid hemorrhage

All the patients were followed up till they were either discharged or operated upon. The data was entered to prepare a master chart, to study all the findings using Microsoft Excel software and all the clinical findings, CT scan findings were compared and the data was analyzed with the help of appropriate statistical method using Microsoft Excel software.

## RESULTS

The prospective study was done among 36 confirmed cases of cerebrovascular accidents with probable diagnosis of cerebral hemorrhage, in a tertiary healthcare center in southern Maharashtra. Out of 36 patients of cerebral hemorrhage, 26 (72%) were males and 10 (28%) were females (Table 1, Figure 1). Table-1 shows age-wise and gender-wise distribution of cases, showing more than 70% cases were presented after the age of 50 years.

**Table 2: Distribution of Cerebral hemorrhage cases according to levels of consciousness.**

Levels of consciousness	Number of cases	Percentage
Conscious	7	19.44 %
Drowsy	9	25 %
Unconscious	20	55.55 %
<b>Total</b>	<b>36</b>	<b>100 %</b>

**Table 3: Distribution of Cerebral hemorrhage cases according to various modes of presentations.**

Modes of presentations	Number of cases	Percentage
Headache	21	58.33 %
Vomiting	10	27.77 %
Convulsions	6	16.66 %
<b>Total</b>	<b>36</b>	<b>100 %</b>

58% cases presented with headache, 16.6% with convulsions and 27.7% with vomiting (Table 3). When we assessed cases according to their systolic blood

pressure (SBP), we found that significantly larger number of cases presented with systolic blood pressure above 140 mmHg (Table 4). We also found that significantly larger number of cases presented with diastolic blood pressure (DBP) less than 110 (Table 5).

**Table 4: Distribution of Cerebral hemorrhage cases according to their systolic blood pressure (SBP) at the time of admission.**

Systolic blood pressure (SBP) range	Number of cases	Percentage
Less than 140	6	16.6 %
141-160	10	27.7 %
161-180	8	22.22 %
181-200	4	11.11 %
More than 201	8	22.22 %
<b>Total</b>	<b>36</b>	<b>100 %</b>

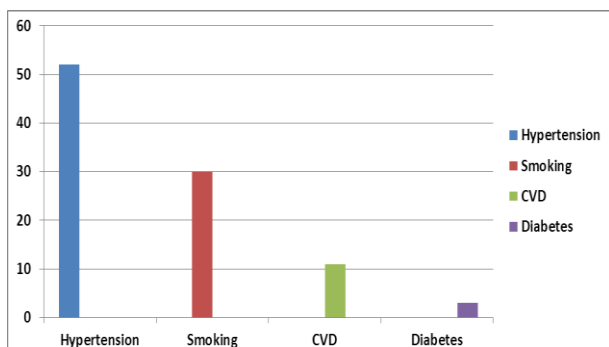
**Table 5: Distribution of Cerebral hemorrhage cases according to their diastolic blood pressure (DBP) at the time of admission.**

Diastolic blood pressure (DBP) range	Number of cases	Percentage
Less than 100	10	27.77 %
100-110	10	27.77 %
110-120	3	8.33 %
120-130	9	25 %
More than 130	4	11.11 %
<b>Total</b>	<b>36</b>	<b>100 %</b>

When we tried to assess cases of cerebral hemorrhage with various examinations, we found that 33.33% of cases presented with grade III-IV fundal changes in ocular examination, 66.66% with bilateral extensor plantar, 22.22% cases with anisocoria whereas 41.6% cases presented with neck rigidity (Table 6).

**Table 6: Distribution of Cerebral hemorrhage cases according to their various examination findings.**

Examinations	Findings	Number of cases	Percentage
Fundal changes	Grade I-II	8	22.22 %
	Grade III-IV	12	33.33 %
Pupils	Anisocoria	8	22.22 %
	Absent light reflex	4	11.11 %
Plantar reflex	Bilateral Plantar extensor	24	66.66 %
Signs of meningeal irritation	Neck rigidity	15	41.66 %



**Figure 2: Distribution of Cerebral hemorrhage cases according to their past history.**

Upon eliciting past history of cases, we found that 53% were known cases of hypertension, 11% were having past history of cerebrovascular episodes, 30.55% cases were smokers and tobacco chewers whereas 2.77% were known cases of diabetes mellitus (Figure 2).

**DISCUSSION**

The present prospective study was conducted among 36 cases of cerebral hemorrhage admitted under department of general medicine in Krishna Institute of Medical sciences, Karad.

When we assessed demographic characteristics of the study participants, we found more percentage of cases among males above the age of 50 years. We found male preponderance in cerebral hemorrhage cases, which

suggests that men have more risk factors for CVA such as hypertension and diabetes mellitus than women.

In support of the thought that men are more involved in high-risk habits such as smoking and alcoholism, and probably work harder under stressful conditions, we found 30% prevalence of smokers in our cases. These factors are closely associated with hypertension and other cardiac diseases. 53% of cerebral hemorrhage cases were also found as known cases of hypertension, which may further aggravate CVA. When patient presents with neurodeficit, headache, vomiting and altered sensorium, it is important to know the nature and site of the lesion.

*Massaro et al.*, in their study observed that 51% cases of ICH presented with headache, 34% vomiting, 60% with altered consciousness, 21.7% cases presented with coma.<sup>[9]</sup>

It is also equally important to exclude patients who are on anti-coagulants or the one who is considered for endarterectomy. If infarct is hemorrhagic, anti-coagulants are unsafe.

In non-hemorrhagic infarcts anti-coagulants are indicated but risk of converting it into hemorrhagic infarcts exists, which may be over weighed against consequent risk of embolization.

The CT scan has traditionally been used in the diagnostic workup of ICH. There is a linear relationship between CT attenuation (hyperdensity) and hematocrit values. new ICH in a patient with normal hematocrit can be easily demonstrated on CT scan.<sup>[10]</sup>

The CT scan is a rapid, relatively easy, noncumbersome imaging modality that is accurate in most regions of the brain in non-anemic patients. The differential diagnosis of hemorrhagic infarction versus hemorrhagic tumor can be difficult & an enhancing ring in an uncomplicated ICH may appear from approximately 6 days to 6 weeks after the initial event and can be diagnostically challenging as the differential diagnosis of a ring-enhancing lesion may include tumor, abscess, infarction, and multiple sclerosis.<sup>[10]</sup>

*Suthar N et al.*, in their study also found similar results, they reported 41% cases with headache, 34% cases with vomiting and 17% cases with seizures.<sup>[3]</sup>

In our study, we found that out of 36 confirmed cases of cerebral hemorrhage, computed tomography could be able to pick 32 cases (88.88%), which identifies CT scan as a trustworthy diagnostic modality in cases with CVA where accurate diagnosis, location of lesion, finding nature of lesion is of utmost importance in order to initiate management protocol. We have also found majority of cases were related with particular pattern of blood pressure (SBP above 140 mmHg and DBP below 110 mmHg), so our study suggests that hypertensive emergencies are more likely to be associated with cerebral infarction. Study conducted by *Suthar et al* also observed that intracerebral hemorrhage cases were associated with diastolic blood pressure more than 100 mmHg and 92% cases were known cases of hypertension.<sup>[3]</sup>

*Gyeong O Go et al* also reported 53% known smokers and 23% cases of hypotension among ICH cases. 66% cases presented with SBP >160 mmHg whereas 54% cases presented with DBP > 90 mmHg.<sup>[11]</sup> *Massaro et al* also found that ICH cases were associated with mean SBP of 182 mmHg and DBP of 105 mmHg.<sup>[9]</sup>

## CONCLUSIONS

- A) Following findings from the present study favours the diagnosis of cerebral hemorrhage:
1. Sudden onset with severe headache, vomiting, neck stiffness and loss of consciousness.
  2. Oculomotor signs
  3. Bilateral extensor plantars
  4. Persistently high systolic and diastolic blood pressures.
- B) Detection of early CT findings in acute hemorrhagic stroke has proved to be of prognostic value in the evaluation of these patients. In intracerebral hemorrhage CT scan may help to plan a surgical therapy for hematomas in a rapidly deteriorating

patient, or may diagnose a hydrocephalous which can be shunted. In short the use of CT coupled with clinical guidelines has been shown to improve outcome in acute stroke patients.

## ACKNOWLEDGEMENTS

The authors acknowledge the participants regarding the truthfulness in their clinical history, personal habits and compliance with clinical and systemic examination

## DECLARATIONS

*Funding: none*

*Conflict of interest: none*

*Ethical approval: not applicable*

## REFERENCES

1. Jeremy J. Heit, Michael Iv MWS. Imaging of Intracranial Hemorrhage in Adults. J stroke [Internet], 2017; 19(1): 11–27.
2. Thabet AM, Kottapally M, Hemphill JC. Management of intracerebral hemorrhage. Handb Clin Neurol, 2017; 140(5): 177–94.
3. Suthar NN, Patel K, Saparia C, Parikh A. Study of clinical and radiological profile and outcome in patients of intracranial hemorrhage. Ann Afr Med [Internet], 2016; 15(2): 69.
4. Asian acute stroke advisory panel (AASAP). Stroke epidemiological data of nine Asian countries. J Med Assoc Thai, 2000; 83: 1–7.
5. Caceres J, Goldstein J. Intracranial hemorrhage. Emerg Med Clin North Am, 2012; 30(3): 771–94.
6. Al WR et. Serum Lipid Levels and the Risk of Intracerebral Hemorrhage: The Rotterdam Study. Arterioscler Thromb Vasc Biol, 2011; 31(12): 2982–2989.
7. Flaherty ML. Anticoagulant-Associated Intracerebral Hemorrhage. Semin Neurol, 2010; 30(5): 565, 572.
8. Martin-Schild S. Intracerebral Hemorrhage in Cocaine Users. Stroke, 2010; 41(4): 680–684.
9. Massaro AR, Sacco RL, Scaff M, Mohr JP. Clinical discriminators between acute brain hemorrhage and infarction: A practical score for early patient identification. Arq Neuropsiquiatr, 2002; 60(2 A): 185–91.
10. Siddiqui FM, Bekker S V., Qureshi AI. Neuroimaging of Hemorrhage and Vascular Defects. Neurotherapeutics, 2011; 8(1): 28–38.
11. GO G, Park H, CH L, SH H, JW H, IS P. The outcomes of spontaneous intracerebral hemorrhage in young adults - a clinical study. J Cerebrovasc Endovasc Neurosurg [Internet], 2013; 15(January 2001): 214–20.