

**CALCIFYING ODONTOGENIC CYST ASSOCIATED WITH COMPLEX ODONTOMA:  
UNCOMMON CASE REPORT**

Mounir Omami\*, Sameh Sioud, Radhia Ben Ali, Abdellatif Chokri, Habib Hamdi and Jamil Selmi

Oral Surgery Department, University Dental Clinic, Monastir, Tunisia.

**\*Corresponding Author: Mounir Omami**

Oral Surgery Department, University Dental Clinic, Monastir, Tunisia.

Article Received on 11/10/2017

Article Revised on 01/11/2017

Article Accepted on 22/11/2017

**ABSTRACT**

Calcifying odontogenic cyst (COC), first described as a separate entity by Gorlin et al. in 1962, is a cystic lesion lined by an ameloblastoma-like epithelium containing ghost cells and calcifications. It is an uncommon benign lesion that can occur in association with various types of odontogenic tumors, such as odontomas. This variable histology and clinical behavior of COC has raised the question of whether or not it is a cyst or a true neoplasm. In this paper, we present a rare case of COC associated with complex odontoma in the left anterior maxilla treated by enucleation with no sign of recurrence after a 3-year follow-up.

**KEYWORDS:** Calcifying odontogenic cyst, Ghost cell, Odontoma, developmental odontogenic cysts; odontogenic tumors.

**INTRODUCTION**

Calcifying odontogenic cyst (COC) is an uncommon benign odontogenic lesion that was first distinguished as a separate entity by Gorlin et al. in 1962.<sup>[1]</sup> It is characterized by an ameloblastoma-like epithelium with ghost cells that may calcify.<sup>[2]</sup> COC may present as an intraosseous or extraosseous process.<sup>[2]</sup> Although named and defined as a cyst, there is no agreement in the literature regarding its classification as a cyst or a neoplasm, as some examples of COC show areas suggestive of neoplasia.<sup>[3]</sup> The age range varies from 5-92 years without gender predilection.<sup>[2]</sup> COC shows an equal site distribution for maxilla and mandible with more recurrence in the dentated zones, and greater incidence in relation to the first molar.<sup>[2,4]</sup> Clinically, the most frequent sign is a painless swelling of variable consistency with buccal and lingual cortical expansion.<sup>[4]</sup> Radiographically, COCs are generally seen as unilocular and, occasionally, multilocular radiolucencies with a well circumscribed border.<sup>[2,4]</sup> In about 50%, a variable amount of radiopaque material is seen and root resorption is common, as is root divergence.<sup>[2]</sup>

Enucleation is the appropriate treatment for most COC and a few recurrences have been reported for the intraosseous type.<sup>[2,4]</sup>

The purpose of this article is to present a rare case of COC associated with complex odontoma focusing on the clinical, radiological and histological findings of the lesion.

**CASE REPORT**

A 48-year-old male patient was admitted to our department of oral surgery with a chief complaint of painful swelling of the left maxilla since two weeks. Intraoral examination revealed a firm swelling involving buccal cortical bone and extending antero-posteriorly from the left central upper incisor (21) to the left upper first molar (26). Panoramic radiograph showed a well-defined periapical radiolucent lesion in relation to 26 and a mixed lesion in the anterior left region of maxilla (Figure 1a). Enucleation of the radiolucent lesion with extraction of 26 was done with normal healing of the surgery site (Figure 1b).

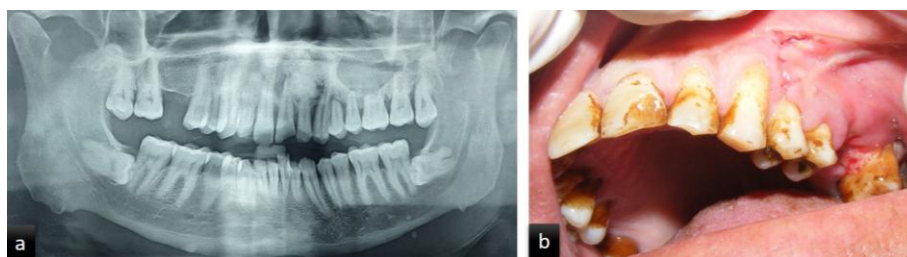


Figure 1: (a) Initial panoramic radiograph; (b) One week post-operative healing.

After 9 months, we have noticed a swelling in the anterior region of the maxilla. Panoramic radiograph and computed tomography (CT) scan sections showed a radiopaque lesion in left anterior region of maxilla (Figure 2). Surgical resection of the lesion was

performed using piezosurgery with extraction of the left upper lateral incisor (22) (Figure 3). The histopathological diagnosis was calcifying odontogenic cyst associated with complex odontoma.

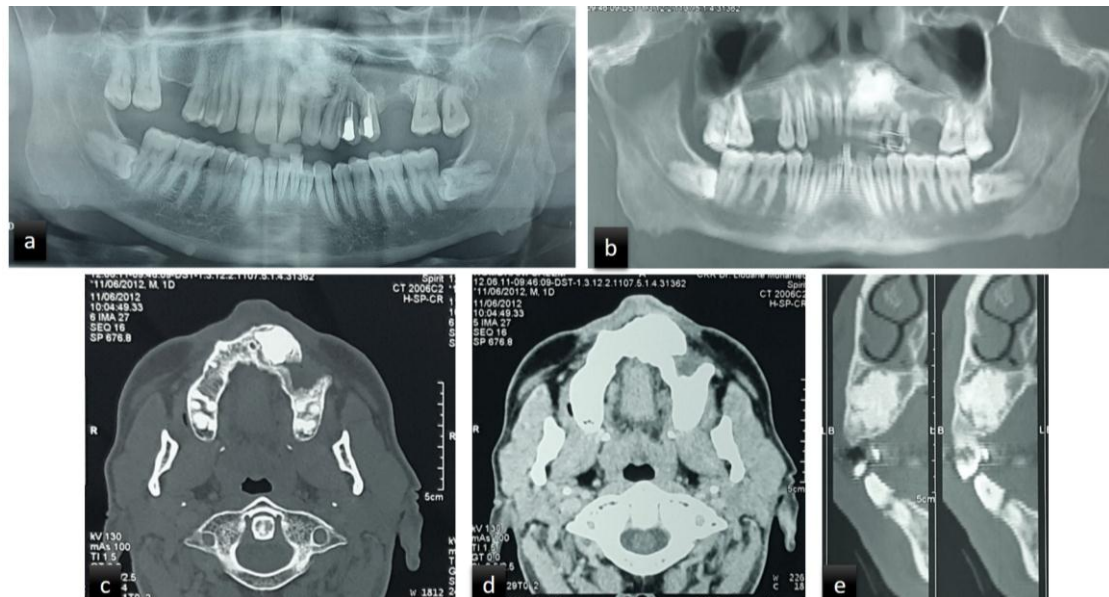


Figure 2: (a) Panoramic radiograph, (b) panorex, (c and d) axial and (e) coronal computed tomography scan sections revealing hyperdense lesion in the anterior region of maxilla.

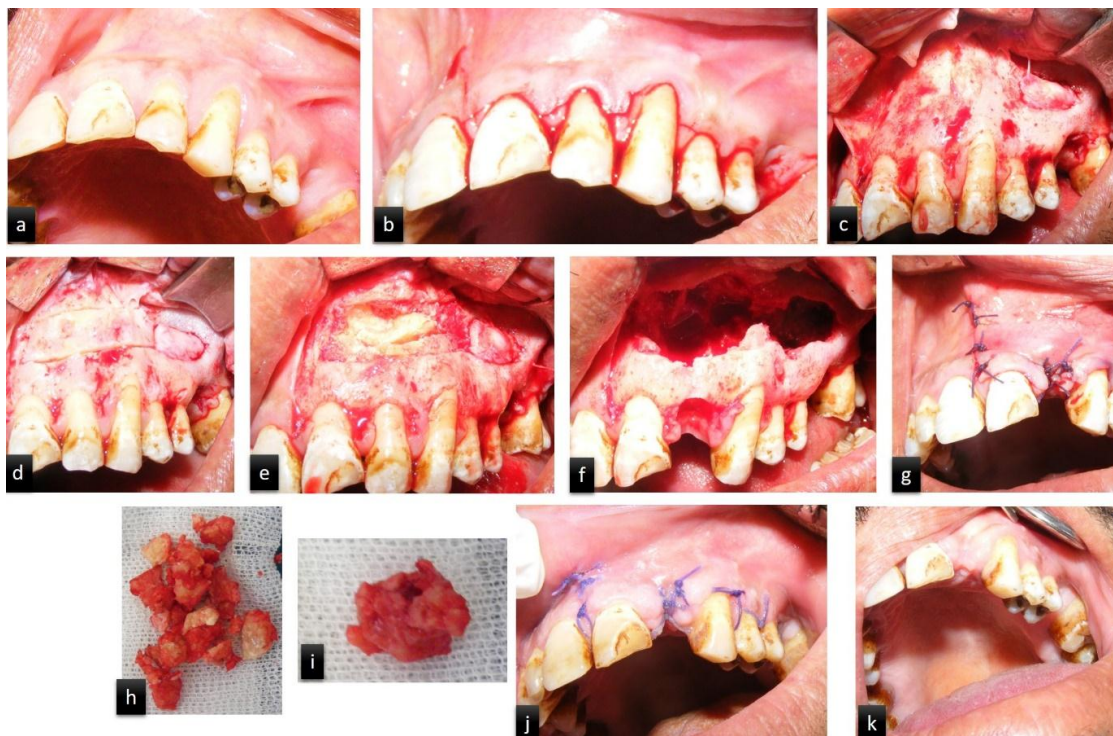
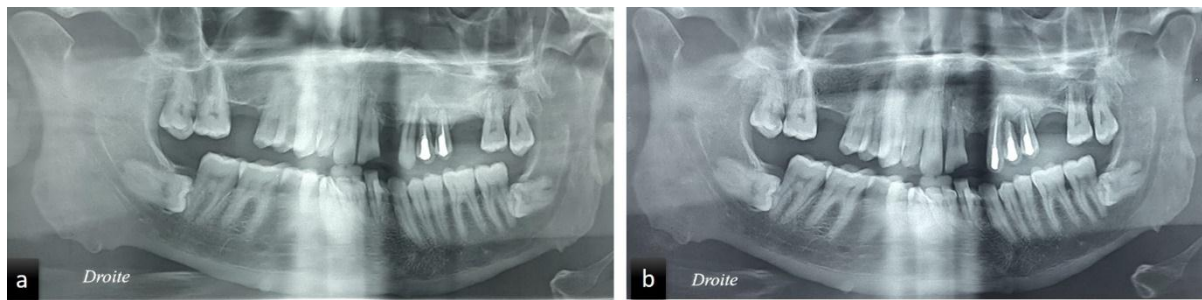


Figure 3: (a-g) Surgical enucleation of the lesion, (h and i) specimens, (j and k) healing one week after surgery.

Panoramic radiographs 3 months (a) and 9 months (b) after surgery showing good healing of the lesion and beginning of reossification (Figure 4). Endodontic

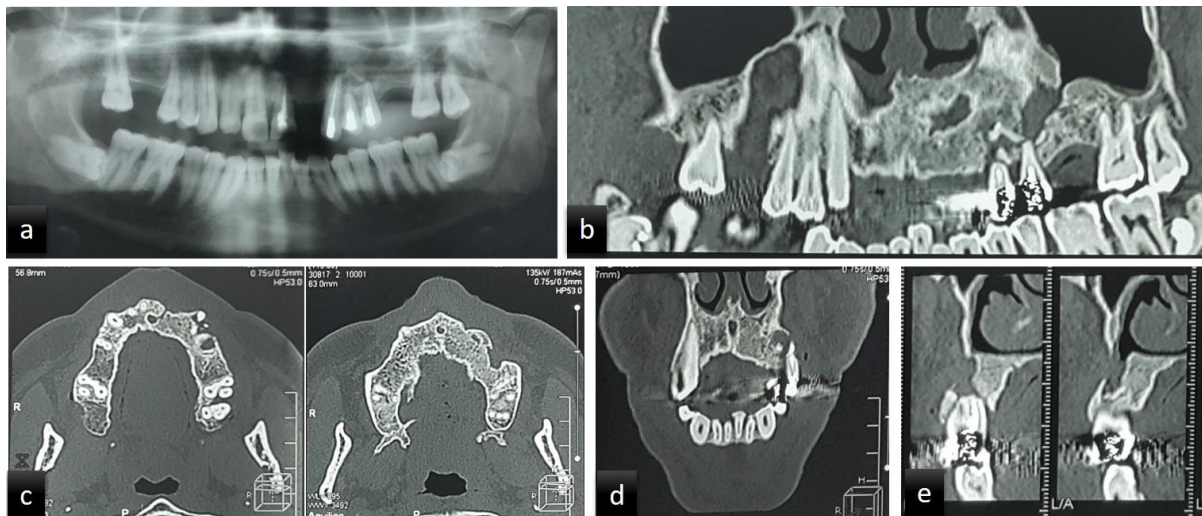
treatments of the left upper canine (23) and the first and second upper left premolar (24, and 25) were performed.



**Figure 4: Panoramic radiographs 3 months (a) and 9 months (b) after surgery.**

Two years after surgery, panoramic radiograph (a) and cone beam computed tomography (CBCT) sections showed a radiolucent lesion in relation with 24 and 25.

Thus, enucleation of the recurrent lesion was performed (Figure 5).



**Figure 5: (a) Panoramic radiograph and (b-e) cone beam computed tomography 2 years after surgery.**

## DISCUSSION

COCs represent about 0.3–0.8% of all odontogenic cysts.<sup>[5]</sup> Clinically, they appear as a painless slow-growing mass, equally affecting the maxilla and mandible, with a predilection for the anterior region (incisor/canine area).<sup>[6,7]</sup> Radiographically, COC appears as a well-limited unilocular or, rarely, multilocular radiolucent lesion of different sizes, shapes and opacity levels.<sup>[5,8]</sup> Impacted teeth may be associated. Root resorption, root divergence or cortical blowing may be observed. Cone beam computerized tomography (CBCT) may be useful to analyse the extent of the lesion.<sup>[5]</sup>

From a clinical and radiographic point of view, the differential diagnosis includes benign radiolucent lesions such as dentigerous cyst, adenomatoid odontogenic tumor, ameloblastic fibro-odontoma, and calcifying epithelial odontogenic tumor.<sup>[5]</sup> Definitive diagnosis is made by histological examination. The histopathology of the COC is typically that of a cyst lined by odontogenic epithelium exhibiting ghost cell keratinization and calcification, with or without areas of epithelial-mediated induction of dental hard tissues.<sup>[7,8]</sup> Solid variant of the COC, called dentinogenic ghost cell tumor (DGCT),

which may show ameloblastomatous proliferations, occurs in bone and occasionally peripherally.<sup>[7,9]</sup>

COC can also occur with odontomas, as in our clinical case, or other odontogenic tumors, such as ameloblastoma, adenomatoid odontogenic tumor, ameloblastic fibroma, and ameloblastic fibro-odontoma.<sup>[7-10]</sup>

The variable histologic appearance and clinical behavior of this lesion has led to different names and designations regarding its classification and has raised the question of whether or not they are cysts or true neoplasms. In the 2005 World Health Organization (WHO) Classification, COC was redesigned as a neoplasm and was renamed calcifying cystic odontogenic tumor (CCOT).<sup>[2]</sup> However no evidence for a neoplastic origin has ever been presented. It has been shown that over 85% of CCOTs are simple cysts either alone (65%) or associated with odontomas.<sup>[11,12]</sup> Very few showed ameloblastomatous proliferations and only 5% of lesions were solid and could be described as true neoplastic DGCT.<sup>[11,12]</sup> Although, simple cystic lesions of COC rarely recur and have a completely benign course.<sup>[11]</sup> Therefore, there seems to be good evidence that simple cystic lesions should be regarded as developmental cysts, which arise

alone or in association with other developmental lesions, especially odontomas.

The new 4<sup>th</sup> edition of WHO classification reverts back to the view that these lesions are benign developmental cysts and has restored the term COC.<sup>[13]</sup> The solid lesions DGCT, which show ameloblastomatous proliferations and may recur, are still regarded as neoplasms and are classified among the odontogenic tumors.<sup>[11-13]</sup>

Treatment of COC consists in complete enucleation of the lesion and curettage.<sup>[5]</sup> Removal of a 1 to 2 mm bone layer around the lesion is recommended in order to remove the epithelial tissue remnants, which might lead to recurrence.<sup>[5,14]</sup>

## CONCLUSION

In summary, we report a rare case of COC associated with an odontoma, simultaneously occurring in the maxilla. Internal calcification detected on CT scan images aided in giving the presumptive diagnosis of this lesion subsequently diagnosed histopathologically as COC associated with complex odontoma. The use of nomenclature and classification should emphasize on biological behavior of the lesion, thus it can be approached and treated accordingly. A long term follow-up is recommended due to the possibility of recurrence.

## REFERENCES

- Gorlin RJ, Pindborg JJ, Clausen FP, Vickers RA. The calcifying odontogenic cyst – a possible analogue of the cutaneous calcifying epithelioma of Malherbe: an analysis of fifteen cases. *Oral Surg Oral Med Oral Pathol*, 1962; 15: 1235–43.
- Praetorius F, Ledesma-Montes C. Calcifying cystic odontogenic tumour. En: Barnes L, Eveson JW, Reichart P, Sidransky D Eds. *Who classification of tumours. Pathology and genetics. Head and neck tumours*. Chapter 6. Lyon: IARC, 2005; 313.
- Fregnani ER, Pires FR, Quezada RD, Shih IM, Vargas PA, De Almeida OP. Calcifying odontogenic cyst: clinicopathological features and immunohistochemical profile of 10 cases. *J Oral Pathol Med*, 2003; 32(3): 163-70.
- Reyes D, Villanueva J, Espinosa S, Cornejo M. Odontogenic calcific cystic tumor: a report of two clinical cases. *Med Oral Patol Oral Cir Bucal*, 2007; 12(2): 126-9.
- Rojo R, Prados-Frutos J, Lázaro IG, Alonso JH. Calcifying odontogenic cysts. *J Stomatol Oral Maxillofac Surg*, 2017; 118(2): 122-4.
- Chindasombatjaroen J, Poomsawat S, Klongnoi B. Calcifying cystic odontogenic tumor associated with other lesions: case report with cone-beam computed tomography findings. *Oral Surg Oral Med Oral Pathol Oral Radiol*, 2012; 113(3): 414-20.
- Basile JR, Klene C, Lin Y-L. Calcifying odontogenic cyst with odontogenic keratocyst: a case report and review of the literature. *Oral Surg Oral Med Oral Pathol Oral Radiol Endod*, 2010; 109(4): e40-e5.
- Lucchese A, Petrucci M, Scivetti M, Pilolli GP, Di Bisceglie MB, Crincoli V, et al. Calcifying odontogenic cysts associated with odontomas: confocal laser scanning microscopy analysis of 13 cases. *Ultrastruct Pathol*, 2011; 35(3): 146-50.
- Goldenberg D, Sciubba J, Tufano RP. Odontogenic ghost cell carcinoma. *Head Neck*, 2004; 26: 378-81.
- Lin C-C, Chen C-H, Lin L-M, Chen Y-K, Wright JM, Kessler HP, et al. Calcifying odontogenic cyst with ameloblastic fibroma: report of three cases. *Oral Surg Oral Med Oral Pathol Oral Radiol Endod*, 2004; 98(4): 451-60.
- Martin LH, Speight PM. Odontogenic cysts: an update. *Diagn Histopathol*, 2017.
- Speight PM, Takata T. New tumour entities in the 4th edition of the World Health Organization Classification of Head and Neck tumours: odontogenic and maxillofacial bone tumours. *Virchows Arch*, 2017; 1-9.
- El-Naggar AK, Chan JKC, Grandis JR, Takata T, Sootweg P, eds. *World Health Organization classification of head and neck tumours*. 4th edn. Lyon: IARC, 2017; Ch8: 232e242.
- Souza LN, Souza AC, Gomes CC, Loyola AM, Durigetto Jr AF, Gomez RS, et al. Conservative treatment of calcifying odontogenic cyst: report of 3 cases. *J Oral Maxillofac Surg*, 2007; 65: 2353–6.