

XANTHOGRANULOMATOUS PYELONEPHRITIS – A CASE REPORT**Dr. Jasima Nilofer F. K.*¹, Dr. Hamsini C.², Dr. P. Karkuzhali³ and Dr. Hemalatha Ganapathy⁴**¹1st yr. Post Graduate, Department of Pathology, Sree Balaji Medical College and Hospital, Chennai.²2nd yr. Post Graduate Department of Pathology, Sree Balaji Medical College and Hospital, Chennai.³Professor and HOD Department of Pathology, Sree Balaji Medical College and Hospital, Chennai.⁴Professor Department of Pathology, Sree Balaji Medical College and Hospital, Chennai.***Corresponding Author: Dr. Jasima Nilofer F. K.**1st yr. Post Graduate, Department of Pathology, Sree Balaji Medical College and Hospital, Chennai.

Article Received on 21/08/2017

Article Revised on 11/09/2017

Article Accepted on 02/10/2017

ABSTRACT

Xanthogranulomatous pyelonephritis is a rare and serious manifestation of chronic kidney inflammation that can be life-threatening if not recognized and treated appropriately, often with antibiotics and surgery. Affected patients are most commonly females in their fifth or sixth decade of life. We are reporting a case of female patient who was diagnosed with right sided non-functional kidney for which right kidney nephrectomy was done. Histopathological evaluation reveals xanthogranulomatous pyelonephritis as diagnosis.

KEYWORDS: Xanthogranulomatous pyelonephritis, Nephrectomy, RCC, Malakoplakia.**INTRODUCTION**

Xanthogranulomatous Pyelonephritis (XGP) is a chronic and severe retroperitoneal infectious/inflammatory process that manifests as chronic destructive granulomatous inflammation of renal parenchyma, often resulting in complete loss of function in the affected kidney. Histologically, XGP is a severe inflammation of the renal parenchyma that occurs in the presence of chronic obstruction and suppuration. The symptoms and signs, as well as the laboratory and urographic findings, of XGP are not pathognomonic, and computed tomography (CT) is the most accurate imaging technique for evaluating the disease. The disease often mimics other inflammatory or neoplastic disorders and is frequently misdiagnosed clinically.

CASE REPORT

A case of 46 years old female patient who was diagnosed with right non-functional kidney, for which right kidney nephrectomy was done by the Dept. of General Surgery, SBMCH. The nephrectomy specimen was then sent for histopathological examination.

GROSS DESCRIPTION

Received right nephrectomy specimen measuring 14 x 10 x 9cm. External surface was irregular with presence of a scar. Cut surface showed multiple cystic spaces, largest cyst measuring 6 x 6 x 5cm, each filled with necrotic material and frank pus; Pelvicalyceal system was distorted.

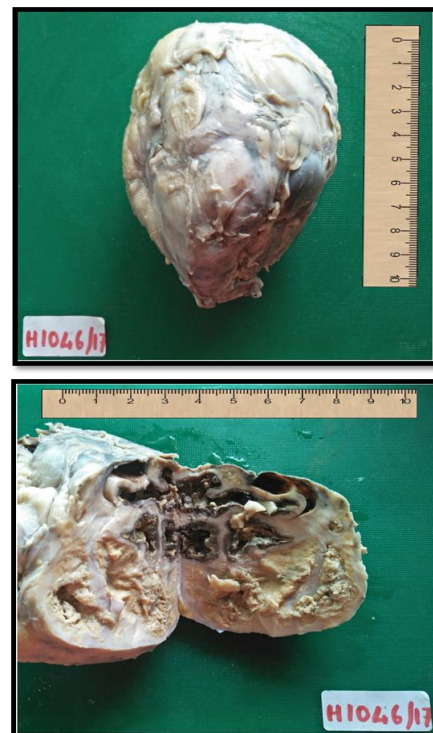


Fig. 1: Nephrectomy specimen showing cystically dilated pelvicalyceal system, surrounded by necrotic areas.

Microscopic Features

Multiple sections from nephrectomy specimen showed areas of necrosis surrounded by dense inflammatory cell collections. Glomeruli were hyalinised. Tubules

appeared atrophied and showed eosinophilic material in the lumen. Blood vessels showed medial thickening. Interstitium showed multinucleated giant cells, foamy macrophages, acute and chronic inflammatory cells. Areas of calcification and hemorrhage were also seen. Ureter showed fibrosis.

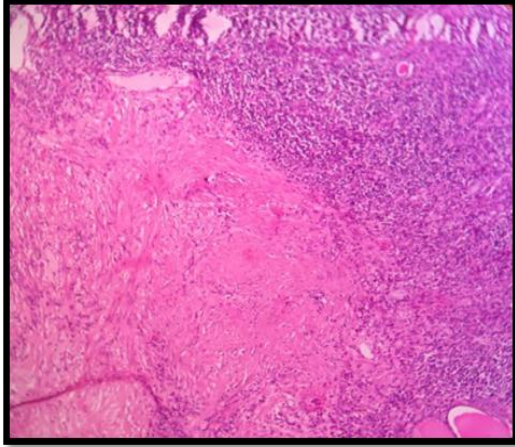


Fig. 2: H. & E. 10x, shows areas of necrosis (black arrow) surrounded by dense inflammatory cell collections (white arrow).

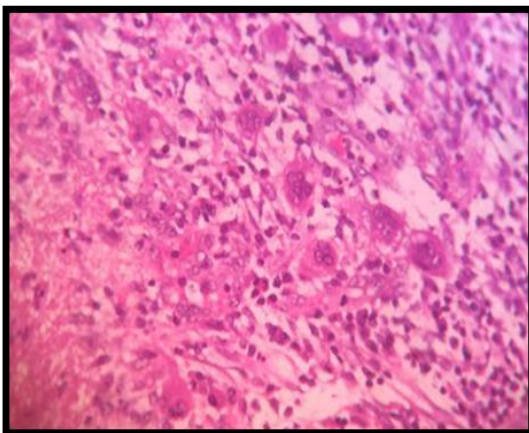
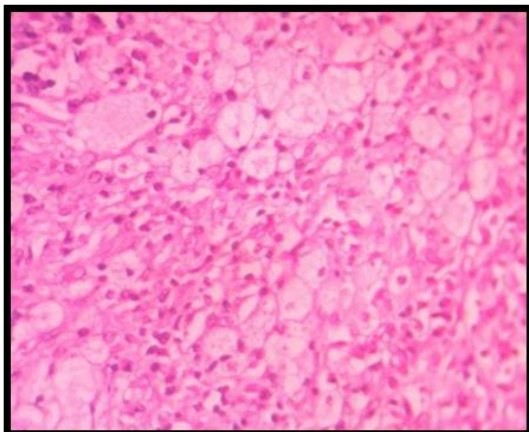


Fig. 3: H. & E. 40x, interstitium shows (a) multinucleated giant cells, (b) foamy macrophages, acute and chronic inflammatory cells.

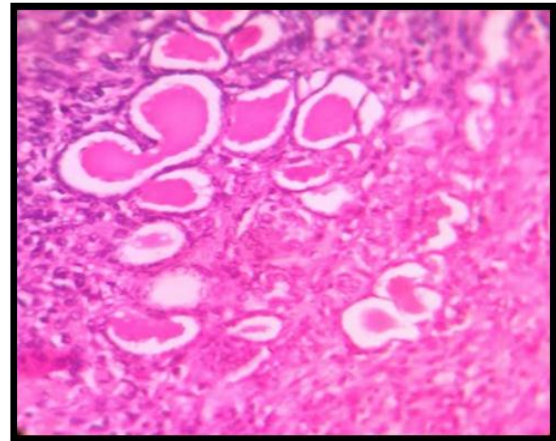


Fig. 4: H. & E. 40x, shows thyroidisation of tubules.

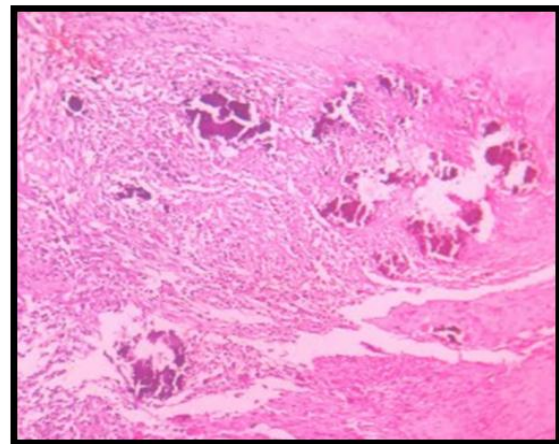


Fig. 5: H. & E. 10x, shows areas of calcification (arrow) and hemorrhage.

With the above features, histological diagnosis of Xanthogranulomatous pyelonephritis was made.

DISCUSSION

Xanthogranulomatous pyelonephritis, first described by Schlagenhauser in 1916, remains a rare disease. Its name is derived from the yellow (xantho) colour on gross pathology and a granulomatous reaction. This inflammation may invade and spread to adjacent structures, most commonly the gastrointestinal tract, urinary tract, and skin.^[1] Patients are typically females in their fifth or sixth decade of life; patients often present with flank pain, lower urinary tract symptoms, as well as constitutional symptoms such as recurrent fevers and weight loss.^[2] Although the pathogenesis of XGP is not known, almost all cases occur in the setting of obstructive uropathy, nephrolithiasis, and/or recurrent urinary tract infections.^[2] Diagnosis of XGP requires a combination of typical clinical symptoms and classic imaging features such as the loss of normal kidney contour and dilated renal calyces surrounding a paradoxically contracted renal pelvis (“bear’s paw sign”^[3]) in patients with a history of urinary tract disease. Definitive diagnosis requires histopathological examination of specimens.

As the affected patients usually have massive obstruction of kidney due to granulomatous tissue which contains lipid laden macrophages, it may be confused with appearance of malakoplakia and RCC.^[2,8,11] Should be differentiated by characteristic large collections of PAS-positive, plump macrophages (von Hanseman cells) and Michaelis-Gutmann bodies (iron- and calcium-laden intracytoplasmic inclusions) in malakoplakia and cytoplasmic mallory-like bodies in RCC. XGP can also be differentiated immunohistochemically with CD68+ lipid laden foam cells and cytokeratin+ kidney ducts.

Recently the coexistence of malakoplakia has been reported in rare cases, suggesting that XGP and malakoplakia may in fact be two entities on the same spectrum of disease.^[4,5]

Once a diagnosis of XGP is established, treatment involves a combination of systemic broad-spectrum antibiotics as well as surgical nephrectomy (partial versus total depending on extent of kidney involvement) for source control.^[6,7] Given the rarity of XGP, there are no guidelines available to inform optimal antimicrobial selection, duration, and timing of surgery; these decisions are often made at the discretion of the attending physician. In exceedingly rare instances of focal disease (less than 10% kidney involvement^[1]), XGP has been successfully treated non-surgically with prolonged courses of antibiotics and followed with serial ultrasonography.

CONCLUSION

Xanthogranulomatous pyelonephritis is a serious condition that can mimic different conditions including malakoplakia and RCC. Careful evaluation of patients by thorough history taking and examination, laboratory investigations, radiological assessment and histopathological examination and immunohistochemical evaluation must be performed in order to help reduce the chances of incorrect diagnosis of the condition.

REFERENCES

1. Craig WD, Wagner BJ, Travis MD. Pyelonephritis: radiologic-pathologic review. *Radiographics*, 2008; 28(1): 255–77.
2. Chuang CK, Lai MK, Chang PL, Huang MH, Chu SH, Wu CJ, Wu HR. Xanthogranulomatous pyelonephritis: experience in 36 cases. *J Urol*, 1992; 147(2): 333–6.
3. Dyer RB, Chen MY, Zagoria RJ. Classic signs in uroradiology. *Radiographics*, 2004; 24: S247–80.
4. Das DP, Pal DK. Co-existing malakoplakia and xanthogranulomatous pyelonephritis of the left kidney: Two different spectrums of the same disease. *Urol Ann*, 2016; 8(2): 252–4.
5. Appleson T, Sharif A, Setty S, Liu D, Wang S, Kanard R, Czech K. A 13-month old with xanthogranulomatous pyelonephritis with features of renal Chow et al. *Journal of Medical Case Reports* (2017) 11:101 Page 4 of 5 malakoplakia. *J Investig Med High Impact Case Rep*, 2016; 4(1): 2324709616630573.
6. Guzzo TJ, Bivalacqua TJ, Pierorazio PM, Varkarakis J, Schaeffer EM, Allaf ME. Xanthogranulomatous pyelonephritis: presentation and management in the era of laparoscopy. *BJU Int*, 2009; 104(9): 1265–8.
7. Kim JC. US and CT findings of xanthogranulomatous pyelonephritis. *Clin Imaging*, 2001; 25(2): 118–21.
8. Parsons MA, Harris SC, Longstaff AJ, Grainger RG. Xanthogranulomatous pyelonephritis: a pathological, clinical and aetiological analysis of 87 cases. *Diagn Histopathol*, 1983; 6: 203.
9. Oosterhof GO, Delaere KP. Xanthogranulomatous pyelonephritis. A review with 2 case reports. *Urol Int*, 1986; 41: 180.
10. Malek RS, Elder JS. Xanthogranulomatous pyelonephritis: a critical analysis of 26 cases and of the literature. *J Urol*, 1978; 119: 589.
11. Goodman M, Curry T, Russell T. Xanthogranulomatous pyelonephritis (XGP): a local disease with systemic manifestations. Report of 23 patients and review of the literature. *Medicine (Baltimore)*, 1979; 58: 171.