

H.PYLORI ASSOCIATED CHRONIC GASTRITIS AND INTESTINAL METAPLASIA - A CLINICOSTATISTICAL AND HITOPATHOLOGICAL STUDY**Dr. K. Anbukkarasi*¹ and Dr. P. Karkuzhali²**¹Postgraduate, Department Of Pathology, Sree Balaji Medical College, Chromepet, Chennai, Tamilnadu.²Professor & HOD, Department Of Pathology, Sree Balaji Medical College, Chromepet, Chennai, Tamilnadu.***Corresponding Author: Dr. K. Anbukkarasi**

Postgraduate, Department Of Pathology, Sree Balaji Medical College, Chromepet, Chennai, Tamilnadu.

Article Received on 01/07/2017

Article Revised on 22/08/2017

Article Accepted on 12/08/2017

ABSTRACT

Chronic gastritis has a high incidence in adults, causing progressive destruction of glandular structures, favoring the development of gastric atrophy. The association of chronic gastritis with intestinal type metaplasia of gastric mucosa has a poor outcome as intestinal metaplasia is regarded as a precancerous lesion. Metaplasia is common in patients with *Helicobacter pylori* infection. The aim of our study was to study chronic gastritis and its association with *H.pylori* and intestinal metaplasia. The study was conducted on a total of 800 patients, aged between 20 and 60 years, who presented for dyspeptic disorders in the period 2015–2016 and were examined clinically and endoscopically. During the gastroscopic examination, fragments of gastric mucosa were collected for the histopathological study and for detection of *H.pylori* infection. For the histopathological study, Hematoxylin–Eosin was performed, while for identifying *H.pylori* infection, giemsa stain was done. A diagnosis of gastritis was established in 390 patients, representing approximately 48.75% of all cases. Most cases with gastritis were found in people of middle age. Gastritis was present in almost all age groups. Of the 390 cases of gastritis, histopathological examination identified the presence of intestinal metaplasia in 45.64% of patients with chronic gastritis, and *h.pylori* positive was found in 51% of patients with chronic gastritis. This study highlights the association of chronic gastritis and *H.pylori* and the presence of intestinal metaplasia, which is a precancerous condition.

KEYWORDS: Intestinal metaplasia, chronic gastritis, *H.pylori*.**INTRODUCTION**

Chronic gastritis is characterized by inflammation of the gastric mucosa, with long-term evolution, characterized by progressive superficial and deep extension of the inflammatory process, eventually leading to destruction of glandular epithelium (atrophic gastritis). According to other authors,^[1] chronic gastritis has a high incidence in adults and the incidence increases with age. Like any inflammatory lesion, chronic gastritis is characterized by a chronic inflammatory cell infiltrate located mainly in the lamina propria of the gastric mucosa, but sometimes also in the submucosa, consisting mainly of lymphocytes and plasma cells. The chronic inflammatory process affects the stomach and causes progressive destruction of glandular structures favoring the development of gastric atrophy.^[2] The association of chronic gastritis with intestinal type metaplasia of gastric mucosa is an aggregate of histopathologic lesions that may have a poor outcome as intestinal metaplasia is regarded as a precancerous lesion that increases the risk of gastric cancer by six times.^[3] Gastric mucosa metaplasia means the replacement of the lining epithelium and/or gastric glands with intestinal type epithelium glands similar to Lieberkühn glands.^[4] Intestinal metaplasia is very

common in adults, being detected in approximately one in four patients undergoing endoscopy. Prevalence of metaplasia is significantly higher in patients infected with *Helicobacter pylori* and heavy smokers.^[4] In our study, we evaluated the relationship between chronic gastritis with intestinal metaplasia and *H.pylori* infection.

MATERIALS AND METHODS

The study was conducted on a total of 800 patients, aged between 20 and 60 years, who presented for dyspeptic disorders at the Gastroenterology department of SBMCH, in the period 2015–2016. They were examined both clinically and by gastroscopy. During the gastroscopic examination, fragments of gastric mucosa were collected for the histopathological study and for highlighting the *H.pylori* infection. Fragments of gastric mucosa were collected using standard endoscopic biopsy from five areas of the gastric wall, according to updated Sydney system. For the histopathological studies gastric mucosa fragments were fixed in 10% neutral formalin solution and embedded in paraffin and stained with Hematoxylin–Eosin and Giemsa stains.

RESULTS

Statistical analysis of patients with dyspeptic syndrome, clinically and endoscopically investigated at SBMCH, Chennai, between 2015 and 2016 allowed us to note that of the total of 800 patients with eso-gastro-duodenal pathology, a diagnosis of gastritis was established in 390 patients, representing approximately 48.75% of all cases. Most cases with gastritis were found in people of middle age, employed, especially between the age groups of 35–45 years and 45-55 years, where over 50% of people with dyspeptic syndrome were diagnosed with gastritis.

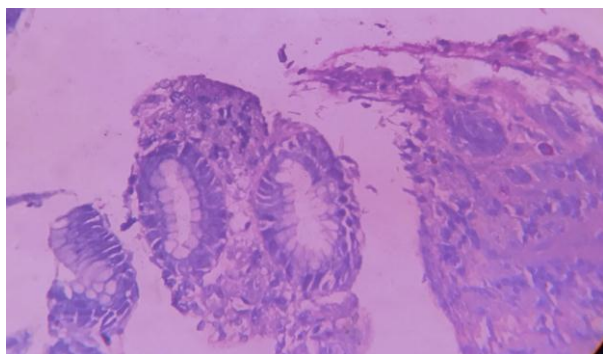


Fig. 1: Chronic gastritis-Giemsa stain showing *H.pylori* positivity.

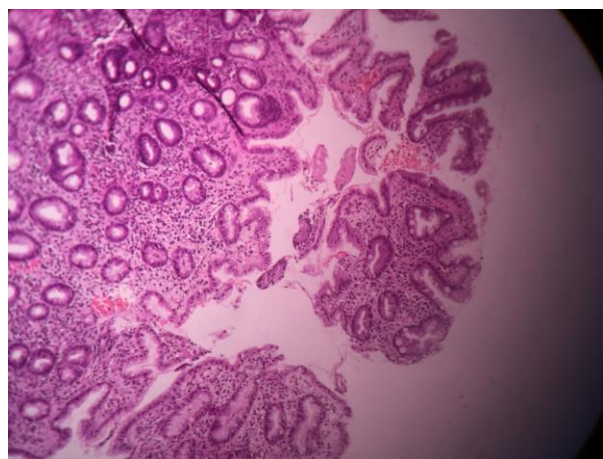


Fig. 2: Chronic gastritis with intestinal metaplasia, showing goblet cells.

In our study, we were particularly interested in the presence of *H. pylori* in patients with gastritis. Of the 390 cases of gastritis, giemsa was positive in 201 patients, representing approximately 51% of all patients with gastritis. Most cases showed the histological form of partial to complete metaplasia, consisting of goblet cells and ciliated cells of intestinal type. The most obvious form of intestinal metaplasia was that with goblet cell proliferation, while the presence of Paneth cells were infrequent. The transition from gastric type epithelium to the intestinal type was sometimes sudden, and sometimes there was a “transition zone”, with cells of various sizes giving a pseudostratified appearance to the surface epithelium were also seen.

DISCUSSION

Gastritis is the most common stomach disorder and, because of its polymorphism, it is very difficult to make an accurate characterization of this disease. According to some authors,^[2] chronic inflammation of gastric mucosa is observed at all ages, with a higher frequency between 20 and 35 years. Clinical and statistical data we obtained showed that gastritis was present in over 48.75% of patients having an upper gastrointestinal distress, which is a very high percentage. The fact is that the evaluation of gastritis incidence in the general population is difficult to determine because the diagnosis of gastritis is often established only superficially based on subjective complaints, and in another section of the patients, showing reduced clinical signs of gastritis although gastric mucosal lesions were observed at endoscopy and confirmed by histo- pathology.

Our study showed that lesions of gastritis can be found at any age but the maximum incidence was seen in people aged between 35 and 50 years. We believe that the data we obtained are more realistic because at this age etiopathogenic factors act more intensively. Thus, certain fried foods, some canned food and meat, spicy foods, alcohol, coffee and tobacco abuse under- lying histological and physiological changes of gastric mucosa are more common in these age groups. Many of the drugs with irritating effect on the stomach, as salicylates, aminophenazone, anti-neuralgics, cortisones, indocide, phenylbutazone, etc., were used by adults included in the study group.

In our study, some cases of chronic gastritis were of atrophic type. Gastric atrophy is considered the final stage of chronic gastritis and as a precancerous condition.^[5-7] Most cases of gastric atrophy are associated with *H. pylori* infection, bacteria regarded as an important cause of chronic atrophic gastritis.^[8,9] Correa P postulates that carcinogenesis occurs as a progression from chronic gastritis to gastric atrophy and intestinal metaplasia, then dysplasia, and ultimately to cancer.^[7] Intestinal metaplasia represents the conversion of gastric glands to a form similar to small bowel mucosal glands containing goblet cells, absorbing cells and Paneth cells. This transformation of the mucosa is a risk factor leading to the development of intestinal-type gastric cancer.^[10]

It seems that intestinal metaplasia is the most frequent and most common change of the gastric mucosa. Although the Sydney system of examination of the gastric mucosa is used a lot worldwide, a large-scale study in Houston showed that intestinal metaplasia was diagnosed in less than 50% in patients with chronic gastritis.^[11]

Numerous studies have shown that *H. pylori* infection is the most common identifiable cause of gastritis in children and adults.^[12] Although *H. pylori* infection is usually acquired during childhood, there is little

information regarding the prevalence of atrophy or intestinal metaplasia in the stomach of the child. Gastric mucosal atrophy in children is either rare or unrecognized, and when identified, it was not well characterized.^[13,14]

In our study, using giemsa staining of the biopsy sample, *H. pylori* was identified at a rate of 51% of cases. Numerous studies show that *H. pylori* infection varies from country to country. However, it is estimated that 60% of the world population is infected with the organism.^[15] Generally, infection is correlated with social and economic conditions.^[16] Infection incidence rates in countries with developing economies reach an impressive rate: 80–90%.^[17,18]

It is well established that chronic inflammation induced by *H. pylori* may lead to loss of normal gastric mucosal architecture, with destruction of gastric glands and replacement by fibrosis of subepithelial connective tissue. This process of gastric atrophy and intestinal metaplasia occurs in approximately half of patients with *H. pylori* infection, especially in patients with severe inflammation.^[19]

Zhang C *et al.* (2005) suggest that *H. pylori* seems to be the most important risk factor for development of glandular atrophy and intestinal metaplasia, but not the only risk.^[20] Other identified risk factors include cigarette smoking, bile reflux, use of NSAIDs, salt, autoimmune gastritis and not yet recognized genetic factors.^[21–23]

CONCLUSION

Chronic gastritis was clinically and endoscopically diagnosed in more than 48% of patients with dyspepsia, and intestinal metaplasia was identified in more than 45% of patients with chronic gastritis.

H. pylori infection was identified in 51% of patients with chronic gastritis, highlighting the importance of bacterium in the pathogenesis of gastric lesions.

REFERENCES

- Ji WS, Gao ZX, Wu KC, Qiu JW, Shi BL, Fan DM, *Effect of Hwei-Decoction on chronic atrophic gastritis and eradication of Helicobacter pylori*, World J Gastroenterol, 2005; 11(7): 986–989.
- Fauci AS, Braunwald E, Isselbacher KJ, Wilson JD, Martin JB, Kasper DL, Hauser SL, Longo DL (eds), *Harrison: principiile medicinei interne*, vol 1, 2, 14th edition, ediția a II-a înlimbaromână, Ed. Teora, București, 2002; 1772–1775.
- Zullo A, Hassan C, Romiti A, Giusto M, Guerriero C, Lorenzetti R, Campo SM, Tomao S, *Follow-up of intestinal metaplasia in the stomach: When, how and why*, World J Gastrointest Oncol, 2012; 4(3): 30–36.
- Dixon MF, Genta RM, Yardley JH, Correa P, *Classification and grading of gastritis. The updated Sydney System. International Workshop on the Histopathology of Gastritis, Houston 1994*, Am J Surg Pathol, 1996; 20(10): 1161–1181.
- Sipponen P, Kekki M, Haapakoski J, Ihamäki T, Siurala M, *Gastric cancer risk in chronic atrophic gastritis: statistical calculations of cross-sectional data*, Int J Cancer, 1985; 35(2): 173–177.
- Correa P, *A human model of gastric carcinogenesis*, Cancer Res, 1988; 48(13): 3554–3560.
- Correa P, *Human gastric carcinogenesis: a multistep and multifactorial process – First American Cancer Society Award Lecture on Cancer Epidemiology and Prevention*, Cancer Res, 1992; 52(24): 6735–6740.
- Kuipers EJ, Pérez-Pérez GI, Meuwissen SG, Blaser MJ, *Helicobacter pylori and atrophic gastritis: importance of the cagA status*, J Natl Cancer Inst, 1995; 87(23): 1777–1780.
- Hopkins RJ, Girardi LS, Turney EA, *Relationship between Helicobacter pylori eradication and reduced duodenal and gastric ulcer recurrence: a review*, Gastroenterology, 1996; 110(4): 1244–1252.
- Walker MM, *Is intestinal metaplasia of the stomach reversible?* Gut, 2003; 52(1): 1–4.
- El-Zimaity HM, Graham DY, *Evaluation of gastric mucosal biopsy site and number for identification of Helicobacter pylori or intestinal metaplasia: role of the Sydney System*, Hum Pathol, 1999; 30(1): 72–77.
- Dohil R, Hassall E, Jevon G, Dimmick J, *Gastritis and gastropathy of childhood*, J Pediatr Gastroenterol Nutr, 1999; 29(4): 378–394.
- Kim KM, Oh YL, Ko JS, Choe YH, Seo JK, *Histopathology and expression of Ki-67 and cyclooxygenase-2 in childhood Helicobacter pylori gastritis*, J Gastroenterol, 2004; 39(3): 231–237.
- Torrente F, Anthony A, Heuschkel RB, Thomson MA, Ashwood P, Murch SH, *Focal-enhanced gastritis in regressive autism with features distinct from Crohn's and Helicobacter pylori gastritis*, Am J Gastroenterol, 2004; 99(4): 598–605.
- Aydemir S, Tekin IO, Numanoglu G, Borazan A, Ustundag Y, *Eosinophil infiltration, gastric juice and serum eosinophil cationic protein levels in Helicobacter pylori-associated chronic gastritis and gastric ulcer*, Mediators Inflamm, 2004; 13(5–6): 369–372.
- Graham DY, Malaty HM, Evans DG, Evans DJ Jr, Klein PD, Adam E, *Epidemiology of Helicobacter pylori in an asymptomatic population in the United States. Effect of age, race, and socioeconomic status*, Gastroenterology, 1991; 100(6): 1495–1501.
- Suerbaum S, Michetti P, *Helicobacter pylori infection*, N Engl J Med, 2002; 347(15): 1175–1186.
- Frenck RW Jr, Clemens J, *Helicobacter in the developing world*, Microbes Infect, 2003; 5(8): 705–713.
- Kuipers EJ, Uytterlinde AM, Peña AS, Hazenberg HJ, Bloemena E, Lindeman J, Klinkenberg-Knol EC, Meuwissen SG, *Increase of Helicobacter pylori-associated corpus gastritis during acid*

- suppressive therapy: implications for long-term safety*, Am J Gastroenterol, 1995; 90(9): 1401–1406.
20. Zhang C, Yamada N, Wu YL, Wen M, Matsuhisa T, Matsukura N, *Comparison of Helicobacter pylori infection and gastric mucosal histological features of gastric ulcer patients with chronic gastritis patients*, World J Gastroenterol, 2005; 11(7): 976–981.
 21. Ogihara A, Kikuchi S, Hasegawa A, Kurosawa M, Miki K, Kaneko E, Mizukoshi H, *Relationship between Helicobacter pylori infection and smoking and drinking habits*, J Gastro- enterolHepatol, 2000; 15(3): 271–276.
 22. Dixon MF, Mapstone NP, Neville PM, Moayyedi P, Axon AT, *Bile reflux gastritis and intestinal metaplasia at the cardia*, Gut, 2002; 51(3): 351–355.
 23. Petersson F, Borch K, Franzén E, *Prevalence of subtypes of intestinal metaplasia in the general population and in patients with autoimmune chronic atrophic gastritis*, Scand J Gastroenterol, 2002; 37(3): 262–266.