

**AN UNUSUAL CAUSE OF NEPHROTIC SYNDROME IN A CHILD; DENSE DEPOSIT DISEASE**Srikanth Burri<sup>1</sup>, Dr. Manjusha Yadla\*<sup>2</sup>, Swarnalatha Gowrishankar<sup>3</sup>, Arun Chitale<sup>4</sup> and PVS Sharma<sup>5</sup><sup>1,2</sup>Department of Nephrology, Gandhi Medical College, Hyderabad, Telangana, India.<sup>3</sup>Department of Pathology, Apollo Hospitals, Hyderabad, Andhra Pradesh.<sup>4</sup>Department of Pathology, Jaslok Hospital, Mumbai.<sup>5</sup>Department of Biotechnology, Srivenkateswara Institute of Medical Sciences, Tirupati, Andhrapradesh, India.**\*Corresponding Author: Dr. Manjusha Yadla**

Department of Nephrology, Gandhi Medical College, Hyderabad, Telangana, India.

Article Received on 04/07/2017

Article Revised on 25/07/2017

Article Accepted on 15/08/2017

**ABSTRACT**

Common causes of nephrotic syndrome in children are minimal change disease, and focal segmental glomerulosclerosis. Though Membranoproliferative glomerulonephritis I (MPGN) is one of the causes in Indian children, MPGN II, better known as dense deposit disease (DDD) is uncommon. Genetic factors play a significant role in the aetiopathogenesis of DDD. One such factor is CFH Tyr 402 His mutation. Herein we report one such case of dense deposit disease due to underlying CFH Y402 mutation, which responded partially to plasma infusion.

**KEYWORDS:** DDD, CFH Y402 mutation, Plasma infusion.**INTRODUCTION**

MPGN II or dense deposit disease (DDD) is occurrence of electron dense deposits within the lamina densa of the glomerular basement membrane (GBM). It is strongly associated with dysregulation of the alternative complement pathway (AP). It accounts for <20% of MPGN in children and is rare in adults. Though the incidence of MPGN in India was reported to be 5.7% - 11.76%, the incidence of DDD is not known.

Herein we report a case of dense deposit disease due to CFH Y402 mutation.

**CASE DETAILS**

A 13 years aged boy presented with edema, oliguria and hematuria of one month duration. On examination, he had pallor, bilateral pitting pedal edema, blood pressure was 150/100 mm of Hg, Fundus was normal. Urine showed 3+albumin, 20-25 RBC/hpf. 24 hour protein excretion was 7.7 gm. His blood urea was 43mg/dl and serum creatinine was 0.8mg/dl. Serum levels of C3 and C4 were within normal limits. Evaluation for secondary causes was done. Serum for hepatitis B surface antigen, hepatitis C, antinuclear antibody were negative. He was borne of consanguineous marriage, first in the birth order. There was no history of similar complaints in the family members.

Renal biopsy showed features suggestive of MPGN and on IF C3 was 3+ along the basement membrane. The

electron microscopy confirmed the diagnosis of dense deposit disease (fig 1,2). A repeat search for low complement levels and for the presence of drusen were negative. Regarding the evaluation for aetiology of DDD, the mutation analysis for the CFH Y402H mutation was found to be positive in both the parents and the child. (fig 3). C3NeF could not be done. Patient was initiated on angiotensin converting enzyme inhibitors, angiotensin blockers along with plasma infusion at 15ml/kg every two weeks.

At the end of six months follow up, his proteinuria decreased to 1gm/day, blood pressure was 150/80 mm of Hg.

**DISCUSSION**

DDD is a rare disease with the incidence of 2-3 /million. It affects females more than the males, the ratio being 3:2. 50% of the children with diagnosis of DDD would progress to endstage renal disease (ESRD) within ten years though the recent NAPRTCS -DDD database reports a rapid progression to ESRD within 4 years of diagnosis. The female gender and the younger age are the probable risk factors for progression of the disease.

The entity is self explanatory with the electron dense transformation of the glomerular basement membrane with the main component being C3. On light microscopy, mild mesangial cellularity (40%) is common than the membranoproliferative pattern (25%). A crescentic pattern (18%) and acute exudative form (12%) are also

reported.<sup>[1]</sup> On IF, deposition of C3 within the glomeruli with little or no staining for immunoglobulin is common.

MPGN II was thought to be an inappropriate term for DDD because: 1) DDD is a complement deposition disease where as MPGN I AND MPGN III are immune complex related diseases 2) the characteristic membrano-proliferative pattern of injury is found in only 25% of DDD patients.

DDD is a complex genetic disease. It is rarely inherited in a simple Mendelian fashion. Various genetic factors were identified like sequence variants in the genes *CFH*, *CFHR5*, *C3*, and *LMNA*, anti-factor H autoantibodies. Amongst these, *CFH* Y402 mutation is the common mutations in DDD.

Though a strong evidence exists for the uncontrolled alternate pathway (AP) activation, there is no definitive serological test for the diagnosis of DDD. But 80% may show evidence of AP dysregulation with low C3 and detectable levels of C3d.

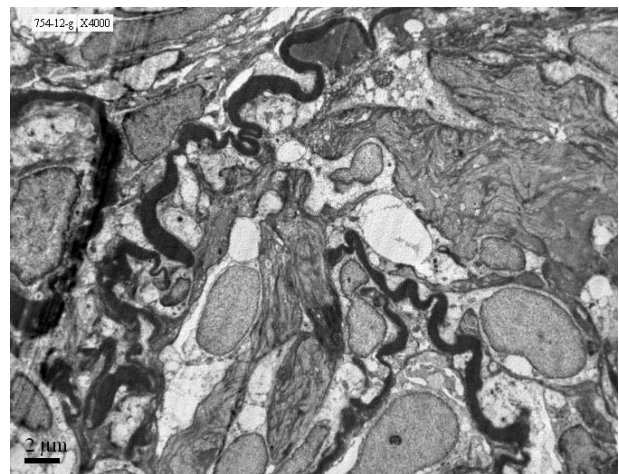
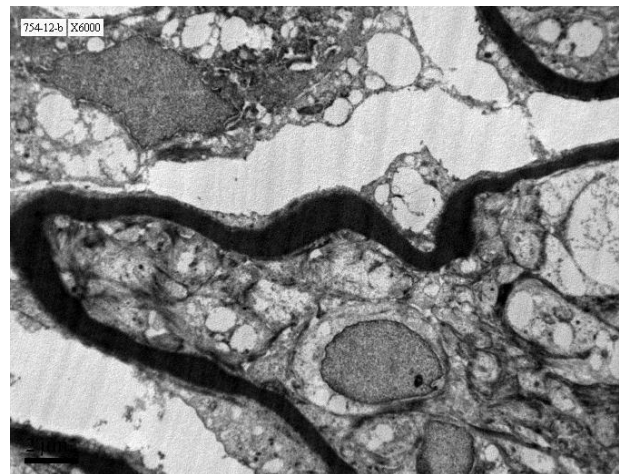
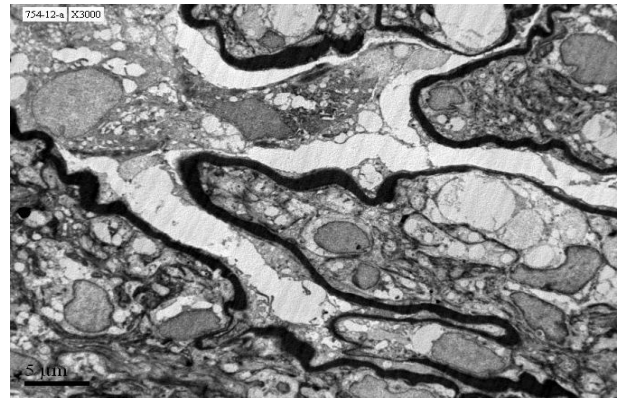
There is no definitive treatment strategy for DDD though the role of plasma exchange, plasma infusion, plasmapheresis are thought to useful in removal of the antibodies, supplementation of factor H in those with deficiency. The recent reports of anti C5 antibody Eculizumab in the mangement of DDD is encouraging.

In our patient electron microscopy confirmed the diagnosis of DDD. The absence of clinical clues and the normal serology did not prompt the diagnosis. Though C3NeF was not done, evaluation for presence of *CFH* mutation was positive in the parents and the child. Hence, a trial of plasma infusion was initiated. There was decrease in proteinuria after six months of therapy with plasma infusion. There is sparse literature regarding DDD in India is not known though one such similar case was reported by Mahajan etal in a postmortem renal biopsy in a child with hematuria and nephrotic syndrome.<sup>[1]</sup>

Though there is a reduction in the degree of proteinuria in our patient, the duration of treatment in the form of plasma exchange and the possibility of side effects such as acquiring blood borne infections remain unclear.

The points of interest are two fold:

1. Early and appropriate identification of the cause of nephrotic syndrome in children.
2. Successful response to plasma infusion in a child with DDD.



## REFERENCES

1. Mahajan V, Tewari R, Minz RW, Jindal G, D'Cruz S. Dense Deposit Disease: A Rare Cause of Steroid Resistant Nephrotic Syndrome. *Indian J Pediatr*, 2013 Jun 20.