wjpmr, 2017,3(5), 138-145

SJIF Impact Factor: 4.103

WORLD JOURNAL OF PHARMACEUTICAL AND MEDICAL RESEARCH

www.wjpmr.com

Research Article

ISSN 2455-3301

WJPMR

# MINIMAL INVASIVE DENTISTRY- EVOLUTION OF CAVITY DESIGNING AND ITS RESTORATION

**Dr. Debapreeti Mohanty[1], Dr. P.V. Samir*[2], Dr. Ramesh Chandra Das[3] and Dr. Sachidananda Sinha[4]**

[1]Post graduate, Department of Conservative Dentistry and Endodontics, Kalinga Institute of Dental Sciences, Bhubaneswar.

[2]Assistant Professor, Department of Pedodontics and Preventive Dentistry, Kalinga Institute of Dental Sciences, Bhubaneswar.

[3]Professor, Department of Conservative Dentistry and Endodontics, Kalinga Institute of Dental Sciences, Bhubaneswar.

[4]Professor and HOD, Department of Conservative Dentistry and Endodontics, Kalinga Institute of Dental Sciences, Bhubaneswar.

***Corresponding Author: Dr. P.V. Samir**

Assistant Professor, Department of Pedodontics and Preventive Dentistry, Kalinga Institute of Dental Sciences, Bhubaneswar.

**Article Received on 14/04/2017** **Article Revised on 05/05/2017** **Article Accepted on 26/05/2017**

## ABSTRACT

Evolution of cavity preparation has come a long way since its introduction by G.V. Black in early 1900's. It stressed more on cutting of a healthy tooth structure along with carious tissue in order to provide adequate retention. Nowadays with the increased quality of the restorative materials retention is no longer an issue related to cavity formation. *G.J. Mount* and *W.R. Hume* in *1997* proposed *a* newer classification of carious lesion and cavity preparation which dealt with cutting of only the demineralised carious region. Several techniques like: chemomechanical caries removal, air abrasion, lasers and ozone evolved along with the minimal cavity preparation which was summarised to be known as minimal intervention dentistry or minimal invasive dentistry.

**KEYWORDS:** Evolution of cavity preparation.

## INTRODUCTION

The disease should be treated first, and the surgical intervention should be a last resort and that too with removal of as little tooth structure as possible. Treatment should begin with identification and elimination of the disease. Restorations by themselves will not and cannot prevent or eliminate further incidence of the disease.[1]

Minimal invasive operative dentistry is a conservative philosophy based on sound science that spans the breadth of the disease continuum, including nonsurgical management of early non-cavitated carious lesion.[2]

Minimal invasive dentistry is been defined as the maximum preservation of healthy dental tissue. Within cariology minimal invasive dentistry include everything from correct diagnosis of primary and secondary caries lesion, the assessment of caries risk, caries prevention and evaluation of caries progression, as well as repair of the restoration as an alternative to replacement.[3]

Minimal invasive dentistry or micro dentistry is a logical extension of conservation of tooth structure. With the advent of resin based composite and acid etching of enamel, smaller preparation minimize the destruction of tooth structure.[4]

The primary strength of minimal invasive dentistry is the involvement of patient in the conservative oriented, longitudinal approach for the preservation and maintenance of their dentition and oral health. The importance of these critical elements of minimal invasive dentistry is having the patient assume responsibility of there day-to-day care of there mouth, and to manage and control, the best of there ability, the risk of disease.[5]

In the presentation of cavity designs, emphasis is placed on minimizing isthmus width, extension into contiguous fissures, and proximal flare, especially with adhesive restorations. The concept of "extension for prevention" as developed in Blacks early cavity design is not promoted, and "prevention for extension" is substituted.[6]

**Historical Perspective on the Evolution of Minimal Invasive Dentistry**

| Year | Authors | Evolution of MID |
|---|---|---|
| 1923 | ***Hyatt*** | Introduced Prophylactic Odontotomy which involved mechanical preparation of pits and fissures and filling them with amalgam. In this way the preparations would be more conservative than if prepared later with amalgam.[2] |
| 1928 | ***Prime*** | Suggested that the over cutting of teeth eventually leads to their fracture.<br>Designed a class II cavity that included a narrow, shallow occlusal step and narrow gingival walls inclined to the axial for retention.[2] |
| 1929 | ***Bodecker*** | Suggested "Fissure eradication"- Widening of fissures mechanically so that they would be less retentive to food particles.[7] |
| 1936 | ***McGhee*** | In his "Textbook of operative dentistry" advocated a class II cavity in which the buccal and lingual margins converged towards the occlusal (Black's margins were parallel). |
| 1951 | ***Miles L. Markely*** | Presented several modifications on class II cavity design.<br>-Occlusal walls that were parallel to enamel prisms. -A constricted occlusal outline.<br>-Proximal margins extended far enough only for access. - A beveled axiopulpal line angle.[2] |
| 1955 | ***Buonocore*** | Developed Acid-etch technique for adhesion of resins.[8] |
| 1956 | ***Vale*** | Reduced the intercuspal width from the recommended one-third to one-fourth.[9] |
| 1963 | ***Jinks*** | Introduced "tunnel prepartion" for initial proximal caries.[9] |
| 1964 | ***Gilmore*** | Recommended that the proximal clearance from the adjacent tooth be limited to 0.5 mm compared to Black's proposed range of 0.8 – 1.2 mm.[10] |
| 1965 | ***Owen*** | Developed the Bis-GMA resin, which is the basis of pit and fissure sealant technique.[2] |
| 1973 | ***Almquist, Cowan and Lambert*** | Proposed a slot preparation consisting of a self retentive proximal box.[2] |
| 1975 | ***Goldman and kronman*** | Made first commercial attempt for chemomechanical removal of caries.[5] |
| 1977 | ***Richard J Simonsen and Stallard*** | Demonstrated the concept of "Preventive Resin Restoration".[2] |
| 1981 | ***Baume, Phillips and Lund*** | Recommended:<br>-Position of the buccal and lingual walls of the cavity is determined by the contacting surface of adjacent tooth.<br>-In mouths relatively free of caries, clearance need be only 0.4 mm.<br>-In mouths susceptible to caries, clearance should be 0.75 mm.[11] |
| 1990's | ***Whitehead and Wilson*** | Used binocular magnification for the detection of caries.[5] |
| 1990 | ***Kidd, Smith and Pickard*** | Suggested the following modifications:<br>- Obtain access to the lesion.<br>- Remove caries at the amelodentinal junction and caries not overlying the dentinal pulp.<br>- Remove the undermined enamel.<br>- Obtain resistance and retention form. - Finishing cavity margins.<br>- Treat caries overlying the pulp - Cavity toilet.[12] |
| 1990 | ***Hunt P.R*** | Suggested the following principles in cavity preparation:<br>-Gaining access to the body of the lesion without being destructive, especially in approximal lesions.<br>-Removal of tooth structure that is infected and incapable of regeneration.<br>-Avoiding the exposure of dentine unaffected by the caries process.[2] |
| 1997 | ***Graham mount*** | Proposed a new cavity classification to take into account the changes in caries activity.<br>Carious lesion occurs in 3 sites on the crown or root of the tooth. ( site-1, site-2 and site-3) with severity of lesion in 5 sizes ( size-0 to size-4).[1] |

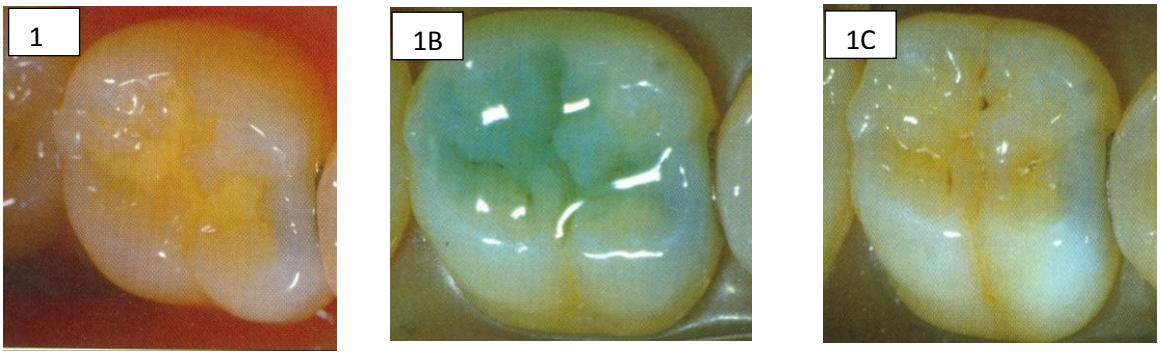


**Fig 1: (A) Site- 1 Size-1 Lesion in Occlusal Fissure (B) Caries Removal (C) Restoration.**

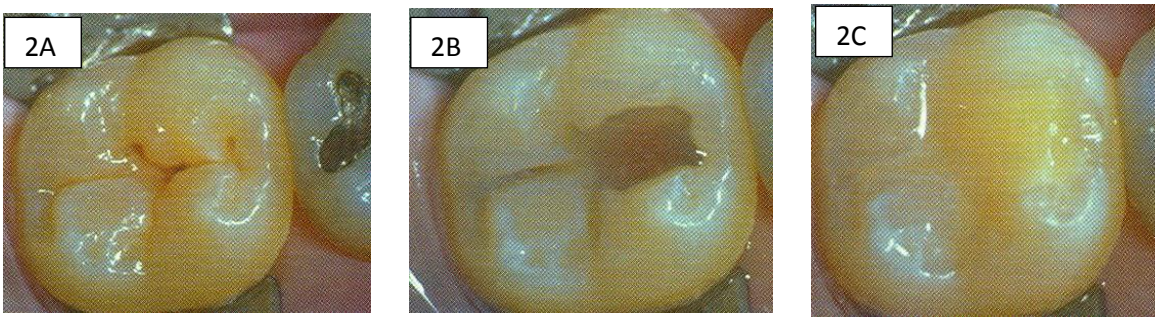


**Fig 2: (A) Site- 1 Size-2 Lesion in Occlusal Fissure (B) Cavity Preparation (C) Restoration.**

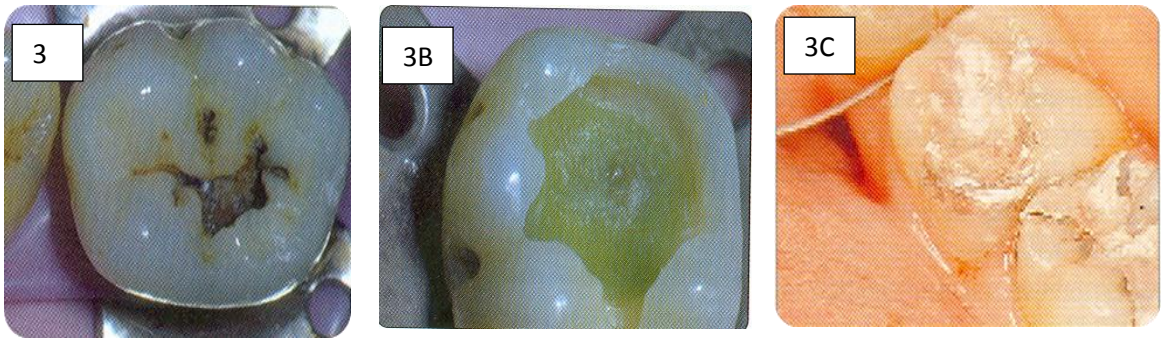


**Fig 3: (A) Site- 1 Size-3 Lesion in Occlusal Aspect (B) Cavity Preparation (C) Restoration.**


**Fig 4: (A) Site- 2 Size-1 Lesion in Proximal Aspect (B) Slot Cavity Preparation Occlusal View (C) Slot Cavity Preparation Proximal View.**

## DISCUSSION

### New Age Classification System of Caries

For almost 100 years, Black's classification of carious lesions by site has given guidance to the profession for their restorative management. It was based purely on the cavity preparation equipment and restorative materials available at that time.[13]

Over a period of past 2 decades, there has been a considerable modification in understanding the initiation and progress of caries and the significance of fluoride and other ions in demineralization – remineralization process.

The instruments available for cavity preparation have changed, and there are now restorative materials capable

of long term adhesion to tooth structure, both to enamel and dentin, in spite of the relatively hostile oral environment.

It was therefore suggested that the profession adopt new classification systems based on the site and size of a lesion where in the two descriptors be used together, and on radiographic evaluation.

A new classification of carious lesion was proposed by *G.J. Mount* and *W.R. Hume* in *1997*. The rationale behind this cavity classification system based on lesion site and size is that it is only necessary to gain access to the lesions and remove areas that are infected and broken down to the point where remineralization is no longer possible.

Carious lesion occurs in 3 sites on the crown or root of the tooth.

**Site 1.** Pits, fissures and enamel defects on occlusal surfaces of posterior teeth or other smooth surfaces, such as cingulum pits on anteriors.

**Site 2.** Approximal enamel immediately below areas in contact with adjacent teeth.

**Site 3.** The cervical one-third of the crown or, following gingival recession, the exposed root.[2]

**Size:** The four stages in the extension of lesion can be defined as follows:

**Size 1 *(Minimal):*** Is a lesion that has progressed to the point where it is just beyond remineralization, so that surgical intervention is indicated.

**Size 2 *(Moderate):*** Is a larger lesion, but there is still sufficient sound tooth structure remaining to support the restoration without further modification of the cavity beyond caries removal.

**Size 3 *(Advanced):*** Is a more extensive lesion that leaves remaining tooth structure at risk of further bulk failure, through the development of a split at the base of a cusp or loss of an incisal corner.

The cavity design is then modified to the extent that the restoration can take the main occlusal load and the remaining tooth structure is protected from undue stress.

**Size 4 *(Extensive):*** Is a lesion in which there has already been serious loss of tooth structure, such as the loss of cusp from a posterior tooth or involvement of incisal edge of an anterior tooth.[1]

| Location | 1- Minimal | 2- Moderate | 3- Advanced | 4- Extensive |
|---|---|---|---|---|
| Site 1: Pits and fissures | 1.1 | 1.2 | 1.3 | 1.4 |
| Site 2: Proximal surfaces | 2.1 | 2.2 | 2.3 | 2.4 |
| Site 3: Cervical surfaces | 3.1 | 3.2 | 3.3 | 3.4 |

**Minimal Invasive Cavity Preparation**
**Restoration of Occlusal Lesions[14,15]**
**Site 1, Size 0**
Sealing a deep fissure before it becomes partially occluded by plaque and pellicle, and in advance of demineralization into dentin, has an acceptable clinical history. The earliest fissure sealants were unfilled or lightly filled resins, but recent research has shown that there are some doubts about the integrity of the acid etch union between resin and enamel in these regions.

It has been shown that a glass ionomer will successfully occlude such a fissure. This is now being termed “fissure protection” to differentiate it from a “resin seal”.

The anatomy of enamel within a fissure differs from that of other surface in that it is covered with a layer of enamel rods that appear to run parallel with the surface rather than at right angles. This means that when it is etched with orthophosphoric acid, it will not develop the usual pattern of porous enamel that allows penetration of the unfilled resin that is normally relied upon to provide the micromechanical attachment. The presence of this type of enamel may well account for loss of the resin seal in many cases.

Neither a resin or a glass ionomer will flow into a fissure beyond the point where the fissure narrows down to approximately 200 μm in width. Therefore, retention of both materials appears to be dependent on adhesion to enamel at the entrance to the fissure rather than mechanical interlocking into the complexities of the fissure. Recent work suggests that even though the enamel rods lie in a different orientation, glass ionomer will still develop ion exchange adhesion and show acceptable longevity.

**Site 1, Size 1**
The lesion occurs either on the occlusal surface of a posterior tooth or in relation to a pit on an otherwise smooth surface. It is identified clinically or radiographically or by transillumination as dentine involvement below the enamel in a particular section of the pit or fissure system. Usually the extent is limited and most of the fissures may be deep and convulated and subject to later attack; they require protection through sealing at this time.

Using the very finest tapered diamond point (#200) at intermediate high speed under air- water spray, enter the fissure in the region of the carious attack and open the enamel far enough to determine the full extent of the lesion. Develop only sufficient access to clean the cavity walls of the entire infected layer of dentine.

Having determined the extent of the problem, open and explore the remaining fissure system, as necessary, using the very fine tapered diamond point to ensure there are no further pockets of active caries. Use small round burs (#008 or #012) to clean the walls of infected enamel.

As the fissure walls become demineralized, the dentin will become involved as well. This may pose a rather dangerous situation because there is often some difficulty in diagnosing the presence of a dentin lesion. Radiographs will not show this early lesion very clearly and laser detector and electrical impedance machines have limitation. In the presence of strong, fluoridated enamel, the occlusal surface entry to the lesion will remain limited, and bacteria-laden plaque can be forced down into a defective fissure.

Under these circumstances, dentin involvement can become advanced before symptoms are noted. The fissure system is a complex series of pits and fissures; therefore, a carious defect will often be limited to a very restricted area, leaving the remaining fissure system sound and uninvolved.

This means that only the carious defect needs to be instrumented. However, prudence suggests that minor apparent defects should be explored in a very conservative manner before sealing the fissure system.

**Site 1, Size 2**

It should be noted that glass ionomer has been recommended for the restoration of both Size 1 and Size 2 lesions in this category. The restoration is well supported by the remaining tooth structure and the ion exchange adhesion will ensure complete sealing of the remainder of the cavity. This means that if there is any demineralized dentin remaining on the floor of the cavity, there will be no further carious activity and there is a potential for remineralization. It is possible to use a resin composite for the restoration but that would also mean cleaning the floor down to sound, healthy dentin to develop an acid-etch union with fully mineralized tooth structure. This may mean removing dentin that could otherwise be remineralized and healed.

**Site 1, Size 3**

Tungsten carbide burs (#140) should be used at ultra high speed to remove any remaining old restoration material and the use of a small diamond cylinder (#156) is the best option to open the enamel to determine the extent of the problem. Round burs (#012 or 016) can then be used to remove infected dentin on the cavity, to avoid the problems arising from pulp exposure.

If it is a new cavity resulting from the active caries, it may be desirable to carry out an indirect pulp capping. Open the cavity with a small diamond cylinder (#156), only as far as required, to gain access to the infected dentin then clean the walls only, using a round bur of appropriate size (#012, # 016).

Seal the cavity with glass ionomer for a minimum of 12 weeks and then reassess the cavity design when preparing the final restoration. At that stage carefully check all remaining cusps to determine the need to protect them from occlusal load. If a cusp has a column of sound dentin providing adequate support for the enamel and there is a more than one half of the medially facing cuspal incline still present, it can remain standing without protection.

**Site 1, Size 4**

This is an extensive cavity, most likely located in a molar tooth. At this there will have been a further breakdown with complete loss of one or more cusps and full restoration with a plastic restorative material will be complex. Amalgam could be utilized for a reasonably satisfactory restoration, but usually an indirect extra coronal restoration such as a full or a three quarter crown will be required subsequently to restore completely the coronal anatomy and occlusion.

Cavity preparation should be carried using a diamond cylinder bur (#156) at intermediate high speed to enter the cavity and round burs (#0126 or 016) to remove the infected dentin. Old restorative material is best- removed using tungsten carbide burs (#140TC) at ultra high speed.

In those cases where caries is highly active, it may be desirable to carry out the indirect pulp cap technique. A protective design for the unsupported cusps can be develop using the #168Dia bur and retentive elements will be incorporated using #168MS burs.[1]

**Restoration of Proximal Lesions[14,15]**

**Site 2, Size 0**

Radiographic evidence of demineralization at the contact area does not necessarily mean that there is cavitation on the proximal surface and in the absence of cavitation, it is often possible to heal the lesion. Proximal lesions progress very slowly because it is not under masticatory load and to a degree is protected from traumatic damage. In contrast to the occlusal fissure lesion, it may take up to four years to penetrate the full thickness of the enamel and an additional four years to progress through the dentin to the pulp.

It is desirable to differentiate between the Size 0 and Size 1 lesion before surgery because, at least theoretically, it should be possible to heal the Size 0 and it is only when cavitation is established that a surgical technique is required. It is essential to avoid the use of a probe to explore the proximal surface because this is the quickest way to actually damage the enamel and cause a cavity.

**Site 2, Size 1**
In posterior teeth, use a small tapered cylinder diamond bur (#168) under air water spray at intermediate high speed. Begin in the occlusal fossa just medial to the marginal ridge. Enter the enamel aiming towards the expected carious lesion.

Usually, the tactile sense available at this speed will allow the operator to feel when the lesion is entered. Approach should be very careful under magnification and good illumination until the defect is identified. The bur should be turned to more upright position to encroach the marginal ridge area to a minimum extent, to enlarge the cavity and improve the visibility. Bur should be leaned facially and lingually to create a funnel shaped access cavity to the lesion.

The entry will now be approximately triangular in outline with the apex towards the central fossa and the base along the medial aspect of the marginal ridge. The carious dentin will now be directly visible and can be removed with small round burs (#008 or 012). It may be necessary to use a bur with a long shank to ensure that the walls and the gingival floor are in sound dentin so that a good seal can be developed around the entire dentin on the axial wall is unnecessary, particularly if there is a risk in exposing the pulp. Glass ionomer will seal and isolate the area, after which the dentin will remineralize.

In anterior teeth, access to the lesions is similar to that described for a posterior tooth and can be gained through the labial or lingual. It is better to approach from the lingual side, thus preserving the labial enamel and minimizing the esthetic problem in the future.

An approach from the labial side occasionally is necessary because of the crowding of the teeth and with consequent overlapping and difficulty of gaining both access and visibility. Enter the lesion with a tapered diamond cylinder (#168) at intermediate high speed under air water spray just medial to the marginal ridge. Extend very conservatively, both incisally and gingivally, to disclose the extent of the problem while maintaining the proximal enamel. Remove caries with small round burs only (#008). Do not extent any further than is essential to eliminate plaque retention because the remaining enamel will remineralize.

**Site 2, size 1 slot cavity**
Open into the lesion using a fine tapered diamond bur (#168) at intermediate high speed under air water spray to maintain a good tactile sense. Extent carefully until the extent of the carious lesion is visible clearly.

Gentle use of a gingival marginal trimmer will allow careful extension without damage to the adjacent tooth. Remove caries with small round burs (#008 and 012) and make clean margins around the entire circumference. Do not extent mesially more than halfway through the marginal ridge.

**Indications:** Caries lesion commencing high on the proximal surface of a posterior tooth leaving less than 2.5mm of the marginal ridge occlusogingivally.

**Site 2, size 2**
Access should be gained with a small diamond cylinder bur (#156) and air water spray at ultra high speed beginning just medially to the marginal ridge and aiming towards the carious lesion. Extend facially, lingually and mesially with the same bur as far as is necessary to expose the extent of caries. Remove the caries with small round burs (#008 or 012) at a low speed. Cavity outline should be completed with hand instruments such as gingival margin trimmer. Retain as much gingival margin as possible to keep the gingival margin of the restoration out of the gingival crevice, even if the enamel is undermined and weakened following removal of the caries, because this enamel is not subjected to occlusal load.

**Site 2, size 3- Anterior teeth**
Access must be gained very conservatively using a #168Dia retaining all possible enamel even though unsupported by dentin. Remove all remaining old restorative material, which is unsatisfactory using #140TC, and remove caries from the walls with small round burs (#012,008). Retention through mechanical interlocks in unnecessary. Smooth all enamel margins using a fine sintered diamond bur (#223).

**Site 2, size 3- Posterior teeth**
Access should be gained with a small diamond cylinder bur (#156) and air water spray at ultra high speed. Remove all remaining old restorative material, which is unsatisfactory using #140TC, and remove caries from the walls with small round burs (#012,008). At this point, determine the extent of the problem and decide if remaining tooth structure requires protection. Identify a split at the base of the cusp if it is present.

For a cusp that is split or at risk, modify the cavity outline by leaning the facial or lingual wall outwards in a straight line from the gingival floor to just beyond the cusp tip using a #168Dia bur at intermediate high speed. Support for one half of a cusp or a single cusp is relatively straight forward, but all four cusps on a molar can be protected at once if necessary. However, maintenance of one cusp gives an indication of the original occlusal height and simplifies replacement of remainder to normal occlusal anatomy.

**Site 2, size 4- Anterior teeth**
After traumatic fracture, there will be very little preparation required. Exposed dentin should be protected as soon as possible with strong glass ionomer, which can subsequently remain as base at the time of restoration. The enamel margins should be beveled (#223) to ensure optimum adhesion.

For an extensive carious lesion or replacement of an old restoration, care must be taken to preserve as much of the

original enamel as possible. Correct access can be gained using #168 or # 156. Avoid the use of pins for retention because of likely future problems such as microcracks in dentin and shadow caused by the pin.

**Site 2, size 4- Posterior teeth**

Open the cavity and remove all traces of old restorative material using a #168Dia bur retaining all possible enamel even though unsupported by dentin. Remove all remaining old restorative materials that are unsatisfactory using#140TC and remove caries from the walls using small round burs (#012,008). Retain any cusp that is based on sound dentin and treat as described for a #2,2 cavity design.

Cusps that are undermined or split should be protected as suggested in the design for a #2,3 cavity design. Retention must be developed in the gingival floor wherever possible, using ditches and grooves cut with a small tapered fissure bur (#168).

**Site 3, size 1**

If a restoration is required, it is sufficient to remove the carious dentin only, using small round burs (#008 or 012). Occasionally, if the enamel is friable, it may be necessary to extend the cavity out into the enamel, but there will be no need to remove all the white lesions representing demineralized enamel. Use a small diamond cylinder (#156) and air water spray at high speed. No instrumentation is required for the restoration of an erosive lesion. Take care to avoid damage to the gingival tissues because hemorrhage will interfere with adhesion.

**Site 3, size 2**

Same procedure is followed as in 3,1. Use round burs (#012,#016)at low speed to remove infected dentin from the walls. Use small diamonds (#168) at intermediate high speed to define the enamel outline but remain conservative with demineralized enamel.

**Site 3, size 3**

Entry is gained from the occlusal margin aiming upwards and inwards towards the lesion. If there is a risk to the root surface of the adjacent tooth, place a short length of metal matrix band and wedge into lightly into place before beginning cavity preparation. Use small diamonds (#168) at intermediate high speed under air water spray and approach the lesion from the most occlusal portion of the caries aiming gingivally towards the most gingival extent of the cavity. Perform gingivectomy if required and control hemorrhage with trichloroacetic acid.

Remove caries around the walls and the gingival floor with small round burs (#012,#016) with long shanks if required, and define the cavity outline. Whenever possible, retain a wall of the tooth structure on side opposite to the access cavity because this will facilitate construction of a matrix and the ultimate placement of the restoration.[1]

**Minimally Invasive Cavity Preparation Techniques[2,5]**

Today, the adhesive restorative materials in conjunction with increased knowledge on the pathology of caries and effective preventive methods allow for minimally invasive techniques. Alternative methods for caries removal have been developed for use with hand instruments, such as atraumatic restorative and chemomechanical techniques. The desire for preparation of small dimensions and microcavities has stimulated new approaches for cavity design and tooth cutting concepts, such as oscillating, kinetic, and hydrokinetic cavity preparation systems.

The preparation technology described shows a wide variety of clinical application, but each of the techniques has significant potential and is currently used in general practice.

| **Minimal Invasive Preparation Techniques** | |
|---|---|
| **Chemomechanical** | **Carisolv** |
| Mechanical<br>Atraumatic restorative treatment<br>Rotary<br>Sonic oscillation | ART<br>High / Low speed bur<br>SONICSYS micro |
| Kinetic | Air abrasion |
| Hydrokinetic | Laser (CO2, Er:YAG, Nd:YAG, etc) |
| Ozone Technology | $O_3$ |

## CONCLUSION

It is apparent that it is time for a change in operative dentistry. It is not possible to really imitate natural tooth structure on a long term basis, so it is best that it be retained as far as possible. Therapeutic methods for the control of the disease are available, and these should be the first line of defense. In the presence of early carious lesions, there is no justification for removal of tooth structure simply to provide a theoretic resistance to further carious attack or to develop mechanical retention for restorative materials.

With the development of new dental restorative materials and advances in adhesive dentistry, a better understanding of the caries process and the tooth's potential for remineralization and changes in caries prevalence and progression, the management of dental caries has evolved from G.V Black's "extension for prevention" to "minimally invasive".

## REFERENCES

1. Mount GJ, Ngo HI. Minimal intervention: Advanced lesion. *Quintessence Int*, 2000; 31: 621-29.
2. Mc Comb D. Conservative operative managment stratergies. *Dent Clin North Am*, 2005; 49: 847-865.
3. Abu Hanna, IA Mjor. Stains v/s Caries. *Operative Dent*, 2008; 33(1): 108-110.
4. Peters MC, McLean ME. Minimally invasive operative care I- Minimal intervention and concepts

for minimal invasive cavity preparations. *J Adhes Dent*, 2001a; 3: 7-16.
5. Christensen GJ. The advantages of minimally invasive dentistry. *J Am Dent Assoc*, 2005; 136: 1563-65.
6. Burke FJT. From extension for prevention to prevention of extension (minimal intervention dentistry). *Dent Update*, 2003; 30: 492-502.
7. Bodecker CF. Dental caries immunization without fillings. *Australian Dental Journal* Dec, 1964; 9(6): 492-495.
8. Tyas MJ, Anusavice KJ, Frencken JE, Mount GJ. Minimal intervention dentistry- A review commission project (1-97). *Int Dent J*, 2000; 50: 1-12.
9. Peters MC, McLean ME. Minimally invasive operative care II- Contemporary techniques and materials: an overview. *J Adhes Dent*, 2001b; 3: 17-31.
10. Rainey JT. Understanding the applications of micro dentistry. *Compend Contin Educ Dent*, 2001; 22: 1018-25.
11. Soderholm KJ, Tyas MJ, Jokstad A. Determinants of quality in operative dentistry. *Crit Rev Oral Bio Med*, 1998; 9: 464-79.
12. Kidd EA. Diagnosis of secondary caries. *J Dent Educ*, 2001; 65: 997-1000.
13. Black AD, ed. G.V. Black`s work on operative dentistry III. Treatment of Dental Caries. Chicago, IL: Medico-Dental publishing, 1936; 60.
14. Hume WR, Mount GJ. Preservation and restoration of tooth structure. 1st ed. St. Louis: Mosby, 1998; 30-35.
15. Mickenautsch S. An introduction to minimum intervention dentistry. Singapore Dent J, 2005; 27: 1-6.