

A CASE STUDY OF TREATMENT OF COMBINATION THERAPY i.e.FISTULECTOMY AND KSHARSUTRA IN COMPLICATED FISTULA IN ANO.**¹Dr. Ram Chidrawar and ²Dr. Ajay Gindewar.**¹M.S, Mch, D.N.B(Uro) Surgeon, ²M.S (Ayu).
Shri Chidrawar Superspeciality Hospital Nanded.***Corresponding Author: Dr. Ram Chidrawar**

M.S, Mch, D.N.B(Uro) Surgeon, Shri Chidrawar Superspeciality Hospital Nanded.

Article Received on 24/11/2016

Article Revised on 13/12/2016

Article Accepted on 03/01/2017

ABSTRACT

Anal fistula represents an important aspect of colorectal practice, being a distressing condition for the patient and sometimes a challenge for surgery. The majority of anal fistula are crypto-glandular origin following the anorectal abscess. The post operative complication of complex fistula in ano is recurrence, fecal incontinence, pain, post surgical ugly scar. With the help of combination therapy in complicated fistula overcomes the complication like ugly scar, and incontinence .etc.

KEYWORDS: Fistula in ano, Ksharsutra, fistulectomy, recurrence.**INTRODUCTION**

Fistula in ano is an inflammatory track which has an external opening in the perianal skin and internal opening in the anal canal or rectum. This tract is lined by unhealthy granulation and fibrous tissue. Fistula in ano is most commonly affecting people, Hippocrates (460 B.C) describe the use of seton to cure fistula in ano. The first surgical lay open of fistula in ano as practiced nowadays was performed by John of Arderne in 1337. The surgical option for low anal fistula are fistulectomy and fistulotomy. A fistulectomy involves complete excision of the fistulous tract, thereby eliminating the risk of missing secondary tract and complete tissue for histopathology. A fistulotomy lays open the fistulous tract, leaving smaller unepithelialized which improved wound healing. Fistula arising from glands of anal crypts is the most common form of perianal sepsis. Any fistula cannot be treated by simple fistulotomy and not by antibiotics. Parks and other have given classification based on the fibrous tract with the special reference of anorectal ring. This classification are four type- 1)intersphincteric 2)trans-sphincteric 3)supra-sphincteric 4)extrasphincteric based on the anatomy of the fistula tract in relation to sphincter. Many procedure tried by surgeon in complicated anal fistula but the fact remains that an "ideal" procedure remains imperceptible. The great Indian surgeon Sushruta use of Kshar in fistula in ano, later that Acharya Chakrapani has explained use of Ksharsutra in fistula in ano. The Ksharsutra is used in fibrous tract caused simultaneous cutting and healing of the wound and allow better wound drainage.

AIM AND OBJECTIVE

To study the cutting and healing of fistula tract by use of Ksharsutra.

PLACE OF WORK

At shree chidrawar superspeciality hospital nanded.

CASE REPORT

A male of 45 yr old admitted in hospital for complaint of –discharge from perineal region from 3yr, pain at perineal region.

PRESENT AND ILLNESS

The above complaint developed from 3 yr .H/O I&D at perineal region 4yr back ,after that above complaints develop.

ON EXAMINATION

General conditions and vitals normal, with
Pulse-86/min
BP-134/80.mmhg
N/H/O HT, DM, PTB, any other disease,

CLINICAL EXAMINATION

An external fistula opening at 12 o clock 8 cm away from anus, tract felt, on per rectal examination, internal opening at 12 o clock. On RGU with fistulogram study – s/o urethral fistula.

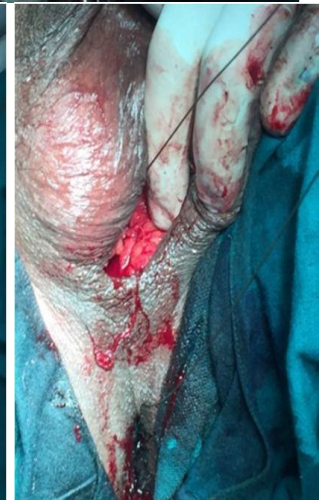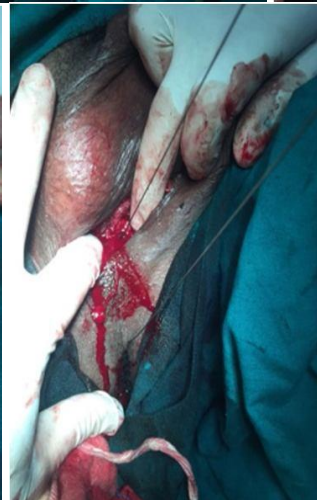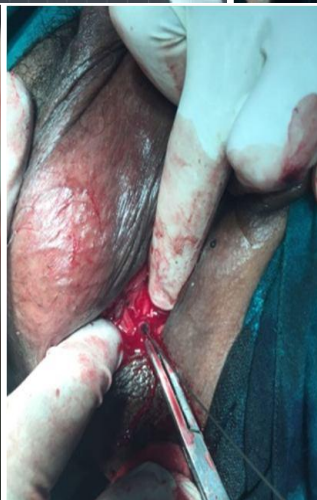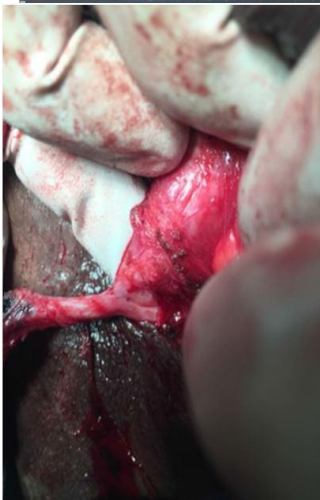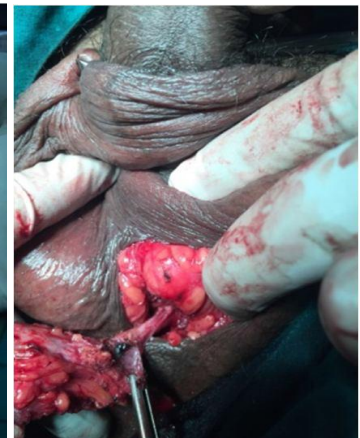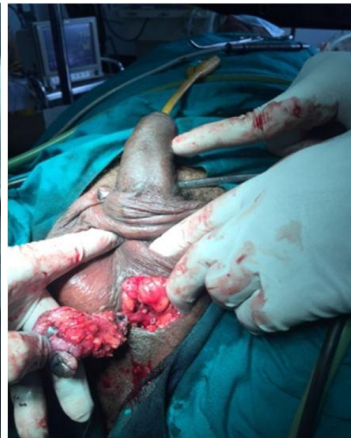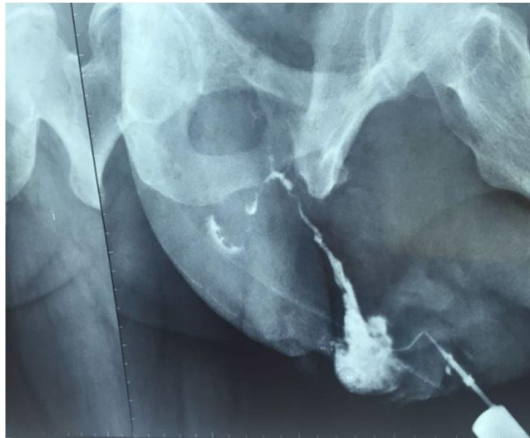
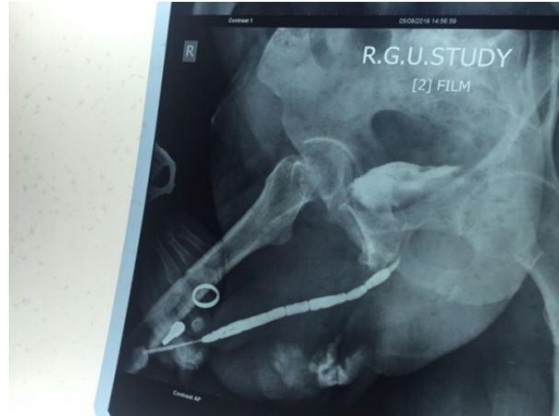
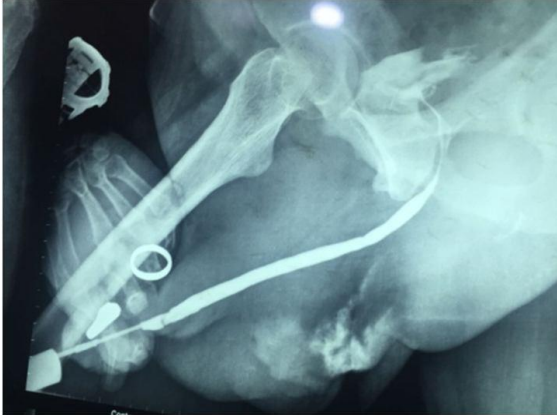OPERATIVE PROCEDURE

Under aseptic condition with spinal anesthesia cystoscopy reveals that no connection with urethra. Methylene blue pass from external fistula opening not coming through anus, circular incision taken around ext opening, tract dissected up to urethra, it's just adherent but not connected with urethra, fibrous tract excised out, then guide wire pass from opening comes through anus,

this tract is now tied with *Ksharsutra*. Secondary suturing taken at upper side.

MANAGEMENT AND OBSERVATION

Antibiotics and anti-inflammatory, with laxative given. *Ksharsutra* is change every 7th day and advice daily dressing with sits bath with luckwarm water with antiseptic solution.



DISCUSSION

A fistulectomy lays open the fistulous tract, leaving smaller unepithelialized Wound healing. *Ksharsutra* is a medicated thread which is prepared by applying coating and recoating 21 times with *tankan Ksharsutra, haridra, snhuhi ksheer*. After that thread is sterilized by UV radiation. The action of *Ksharsutra* is cutting, curreting, draining and cleaning of fistula tract. *Ksharsutra* is hence also work as healing by fresh and healthy granulation tissue.

CONCLUTION

As in the case of complicated fistula in ano if we used only fistulectomy, then post-operative wide open wound, post operative pain, ugly scar, incontinence, is possible so by using *Ksharsutra* we overcome the complication and getting result. So in complicated fistula we used this combination therapy is beneficial.

REFERENCE

1. Gabrils ws. The principle and practice of rectal surgery 5th Edition. Hk lewis and co. ltd London 1961.
2. Sushruta samhita Ambikadatta shastri, chaukhamba prakashan, 2nd edition.
3. Practical guide to operative surgery, S.Das SD publication, 4th edition.