

ULTRASOUND APPEARANCE OF CONGENITAL KIDNEYS DISEASE. LITERATURE
REVIEW AND CASE SERIES.

Ștefania Tudorache^{1,2}, Roxana Drăgușin¹, Maria Florea¹, George Lucian Zorilă¹, Ciprian Laurențiu Pătru¹,
Alex Stepan^{2,3}, Florin Burada^{2,4}, Nicolae Cernea^{1,2}, Alin Stoica^{2*,5} and Dominic Gabriel Ilescu^{1,2}

¹Prenatal Diagnostic Unit, Emergency University Hospital, Craiova.

²University of Medicine and Pharmacy Craiova.

³Department of Pathology, Emergency University Hospital, Craiova.

⁴Human Genomics Research Center, Emergency University Hospital, Craiova.

⁵Department of Pediatric Surgery, Emergency University Hospital, Craiova.

*Corresponding Author: Dr. Alin Stoica

Pediatric surgery, Emergency University Hospital, Craiova, University of Medicine and Pharmacy Craiova.

Email ID: alin.stoica76@gmail.com

Article Received on 22/11/2016

Article Revised on 12/12/2016

Article Accepted on 01/01/2017

ABSTRACT

Background: Recent technological advances in ultrasound imaging offered the opportunity to detect much earlier an increasing number of fetal malformations. A correct diagnosis is essential for adequate counseling and management of the pregnancy. **Methods:** We review the published literature in regards to kidneys ultrasound features throughout pregnancy. The natural evolution, the management, the outcome and pathologic findings of various antenatal detectable kidney diseases are discussed. **Results:** The follow-up of these cases evolution suggests that the diagnosis of some malformations' as multicystic dysplastic kidney (MCDK) may be considered as early as late FT, if detailed scan is performed. **Conclusions:** Long time evolution of fetal kidney's diseases was considered virtually impossible to predict early in pregnancy.

KEYWORDS: First Trimester Ultrasound, Multicystic Dysplastic Kidney, Polycystic Kidney Disease, Screening, Intervention.

INTRODUCTION

Congenital anomalies describe an abnormality of structure or function present at birth. The birth prevalence of congenital anomalies has decreased in recent years from 5.0% in 2001 to 4.1% in 2007,^[1] in part because of primary (nutrition, improved prenatal care) and secondary (pregnancy termination) prevention.

The etiology of congenital anomalies is complex, and their identification is one of the primary goals in first/second trimester ultrasound scans. Like in many other systems, the prevalence of the congenital kidneys anomaly varies depending on the time of observation: fetal life less than 14weeks, less than 24weeks, more than 24 weeks, neonatal, infancy, or childhood¹.

Prenatal ultrasound has a various sensitivity/specificity with gestational age, ultrasound technology, amniotic fluid volume, imaging skills and experience of the observer, and maternal particular factors that influence the ultrasound interpretation.^[2]

Although detailed first trimester ultrasound anomaly ultrasound cannot replace the 18–20weeks of gestation screening scan^[3], the ever improving transabdominal

ultrasound resolution has made it possible for sonographers to perform the routine 11 to 13 +6-week scan.^[4] We shifted the interest toward early anomaly fetal echo, soon after large scale application of genetic ultrasound, due to potential benefits of early reassurance of normality and early surgical therapeutic terminations of pregnancy, with superior acceptability.^[5]

Recent guidelines for scanning in the first trimester recommend fetal kidneys recognition.^[3] On the other hand, with the advance of both technology and research, early pregnancy screening is becoming more sophisticated than ever and complex. Both in the FT and in the ST, dilated pelvis, isolated large or hyperechogenic fetal kidneys are features which make most sonographers to feel uncomfortable by observing them, first because they cannot be certain that the observation implies a pathology sign and second due to implied difficulties in explaining the findings and the outcome to the parents. Both the size and echogenicity of the kidneys are commonly subjectively assessed during a morphological FT or ST scan. Precise diagnosis and prognosis cannot rely only on the ultrasound, bearing in mind the genetic aspects of many renal anomalies and

the laborious assessment of the structure and especially of the function of kidneys.

While there are clear benefits to most women receiving early reassurance that their baby is developing as expected, the evidence that an earlier prenatal diagnosis has less long-term emotional impact than at later gestations is controversial.^[6,42] Many parents experience difficulties to manage the anxiety when an ultrasound marker is highlighted as a potential cause for concern by a sonologist.

LITERATURE REVIEW

Antenatal Detectable Kidneys Congenital Anomalies

In prenatal life, even the size of the kidney, the least subjective part of the assessment of kidneys, may be a problem, particularly due to the difficulties in accurately differentiating the superior pole of the kidney from the adrenal gland. Recognized nomograms were published many years ago.^[7] Moreover, the echogenicity of fetal kidney can only be assessed by comparing it to that of the liver and spleen. Corticomedullary differentiation of the kidneys is also assessed subjectively.^[8] It worth mentioning that gestational age, the amniotic fluid volume, the gain setting and the frequency of the probes influence all these features.

POLYCYSTIC KIDNEY DISEASE (PKD)

PKD can be suspected in the second trimester^[9], but can be confirmed much later in the pregnancy, since nephrogenesis is only completed at around 34 weeks. In 70% of cases the precise diagnosis will only be made in postnatal life.^[10]

The classification of hyperechogenic, enlarged, cystic kidney in the fetus can be simplified as follows^[10]

(1) Non-hereditary lesions: enlarged kidney, filled with large cystic structures; can occur in response to ureteral obstruction or atresia. Renal dysplasia or multicystic dysplastic kidney (MCDK) are the terms used to describe the abnormal differentiation of parenchyma, with cystic dilatation and primitive ducts surrounded by connective tissue. Renal dysplasia has been attributed to abnormal embryonic differentiation or developmental arrest leading to the persistence of mesonephric tissue. The epithelial cell proliferation is involved in cystic expansion. Cysts that lose their connection with their originating tubule are thought to expand by a mechanism of transepithelial fluid secretion, which causes compression and finally atrophy of surrounding parenchyma.^[11] The kidney consists of irregular cysts of varying sizes and has no function. MCDK is the most common type of renal cystic disease, and one of the most common causes of an abdominal mass in infants.^[12] The contralateral kidney is frequently abnormal as well. Ureteropelvic junction obstruction is found in 3% to 12% of infants with MCDK and contralateral vesicoureteral reflux is seen even more often, in 18% to 43% of infants.^[13] MCDK has no medical treatment, thus the bilateral condition is lethal. In unilateral cases, the

patient must be monitored periodically for the first few years, and ultrasound exams are performed to ensure that the healthy kidney is functioning properly and the affected kidney is not causing side effects. In rare cases, e.g. large masses, renal hypertension or malignant transformation, the entire affected kidney is surgically removed.

(2) Genetic renal disorders: enlarged, hyperechogenic and/or cystic kidneys are a heterogeneous group of conditions, often severe. Even those individuals with a single gene defect demonstrate clinical heterogeneity that may be detected before birth.^[10] The classification of cystic kidney diseases according to the pathological anatomical Potter classification is difficult. New molecular genetic findings are important in understanding the underlying pathogenesis, but are less useful in classifying the hereditary diseases. An exact classification of PKD in fetuses and children is very important for parental counseling. Therefore, the investigation of the pathological anatomy of the kidney and liver, in addition to the evaluation of additional malformations and family history, is necessary. The detection of enlarged kidneys need a detailed search for extrarenal features, including skeletal and central nervous system abnormalities, dysmorphic features or intrauterine growth restriction, in order to identify possible genetic syndromes.

A first group with isolated renal features is described as PKD and includes ADPKD and autosomal recessive polycystic kidney disease (ARPKD), which are differentiated by their mode of inheritance. A second group includes renal tubular dysgenesis and Finnish type congenital nephrotic syndrome. The association of renal enlarged cystic changes, is also a feature of some inherited metabolic disorders.

Autosomal recessive polycystic kidney disease (ARPKD)

Clinically, ARPKD is a severe form of inherited childhood nephropathy (1:20000 live births) characterized by fusiform dilatation of the collecting ducts. The kidneys appear spongy and there is no clear separation between cortex and medulla. Renal involvement is always bilateral and mostly symmetrical. The cut surface demonstrates the cortical extension of fusiform or cylindrical spaces arranged radially throughout the renal parenchyma from the medulla to the cortex. ARPKD is invariably associated with a generalized portal and interlobular fibrosis of the liver accompanied by biliary duct hyperplasia and small distal portal vein branches. Up to 30% of affected individuals die in the neonatal period due to respiratory insufficiency and most of surviving infants develop hypertension. Progression to end-stage renal disease occurs in 20–45% of cases within 15 years, but, a proportion of them maintain renal function into adulthood, where complications of liver disease are predominant.

The ultrasonographic features of ARPKD consist of increased echogenicity and symmetric, bilateral renal enlargement, with difficulties in identifying the fetal bladder. Oligohydramnios is typically present. Repeated sonographic measurements of the length of the kidneys appears to be the most useful parameter. In up to one-third of cases, enlargement of the kidneys cannot be detected until the second half of the pregnancy. As pregnancy progresses, the renal cysts gradually change in size and shape, thus the renal ultrasound aspect changes. In milder cases with only a small proportion of dilated nephrons, prenatal ultrasound diagnosis is even more uncertain.^[14]

Autosomal dominant polycystic kidney disease (ADPKD)

ADPKD is a common inherited nephropathy affecting more than 1:1000 of the worldwide population. It is a systemic condition with frequent hepatic and cardiovascular manifestations, in addition to the progressive development of renal cysts that eventually result in loss of renal function in the majority of affected individuals, accounting for 8–10% of cases of end-stage renal disease. Prenatal diagnosis of ADPKD occurring in utero is more often associated with a poor prognosis^[15] and the identification of mutations in PKD1 and PKD2 that account for virtually all cases. Cysts in ADPKD are usually found only in the adult.

Sonographers must be aware of the subtle characteristics of the sonographic aspects of ADPKD since the fetal expression should be limited to hyperechogenic and enlarged but rarely grossly cystic kidneys.^[16] Although this subjective ultrasound feature has a good sensitivity, more than 50% of the diagnoses are made in the presence of an informative family history.^[17,44]

Mutations in cystic kidney disease genes represent a major genetic cause of end-stage renal disease. The molecular mechanisms controlling the expression of these genes are still incomplete understood, but recent research is bringing light: ARPKD, ADPKD and Bardet-Biedl syndrome are three pathologic different entities, but it appears to be a common feature in their pathogenesis: defective cilia.^[18]

Molecular characterization has helped us to understand better the disease. However, identification of the gene(s) involved at molecular level does not make the prenatal diagnosis more feasible, because in most families involved we don't have genetic information at the time of the prenatal scan and complex molecular characterization will often end in pregnancy termination. Furthermore, these genetic conditions have a late onset and uncertain prognosis. For genetic studies are mandatory: the diagnosis of ARPKD in previously affected siblings and DNA available.^[19]

In ADPKD prenatal molecular diagnosis is similar to that in ARPKD.^[10]

Currently molecular genetics can only help in identifying underlying conditions with large echogenic kidneys when the diagnosis has been clearly clinically identified and only if DNA from this case is available and can be screened in order to identify the family mutation(s). At the time of writing, in our country, none of the prenatal genetic tests (conventional karyotype, FISH, QF-PCR, MLPA or array CGH) are free of charge for the patient, through the Health Insurance Institution, the process of subsidize is still ongoing. In our country, aCGH is a much more expensive technique than conventional G-band karyotyping and inaccessible in many of the non-university settings. However, the costs of array CGH seems to decrease.

Second trimester kidneys' ultrasound.

Although discrepancies exist between the demography of antenatal versus postnatal diagnoses^[20,45-46], ultrasound remains the most important tool to assess kidneys' structure, both antenatally and postnatally.^[21] Most renal abnormalities are nowadays diagnosed or suspected antenatally by ultrasound scans. Conditions such as unilateral multicystic dysplastic kidney can be easily recognized and managed based on the experience gained with long-term studies of its natural history.^[22-29] UMCDK associates in 33% cases renal anomalies and non-renal abnormalities in 16% of cases. Of the non-renal abnormalities, congenital heart defects are the most frequent (7%). There are cases of partial (up to 25%) or even complete involution. Long-term associated morbidity such as hypertension or malignancy is rare.^[20] Amniocentesis should be offered. A detailed ultrasound with careful assessment of the fetal heart and contralateral kidney is indicated. In continuing pregnancies, careful assessment of the newborn is indicated^[30],

Polycystic kidney on the other hand, is still a diagnostic problem and remains beyond therapeutic intervention. Termination of pregnancy and postnatal supportive measures are the only available means of dealing with this entity at present.^[17,31-33]

Unfortunately, by the time ultrasound evidence is obtained, the renal damage is already established.

First trimester kidneys' ultrasound

From the 1990, FT appearance of pielectasis drew the attention of sonographers in relation with chromosomal abnormalitie.^[34] In 1994, a large study (13 252 cases), although highlighting the pitfalls of early screening at 12 to 18 weeks, using transvaginal approach, picked-up nine fetuses with "hypoechogenic in the renal bed", from which five fetuses had renal agenesis and enlarged adrenals. In three additional cases, unilateral renal agenesis was accompanied by unilateral enlarged. In one case, a false-positive sonographic diagnosis of Potter syndrome was made. This study underline the difficulties of early detection, and conclude that diagnostic criteria for renal agenesis in the early fetus may be different

from those used in the second half of gestation.^[35] From the same study group, there was obtained fetal renal size in the late FT in 50 normal fetuses. It seems that both kidneys are reliably identifiable from 12 weeks. Kidney diameter measurements obtained in this study are presented for reference in evaluating patients in late first trimester whose fetuses are at risk for kidney abnormalities.^[35]

In 2003 prospective, cross-sectional study of six hundred and sixty-three fetuses study resulted in new size charts for fetal kidney size, in 14 to 42 weeks of amenorrhea.^[46] A very recent report also attempts to establish nomograms for early fetal kidney development during early gestation. 275 normal fetuses were studied, and FT and early ST measurements were obtained by transvaginal ultrasonography, from 13 weeks.^[36]

METHOD AND MATERIALS

Case series

We present cases that are part of a 2-year prospective study regarding the detection of structural abnormalities in the first trimester, using an extended examination protocol. These cases were referred to the Prenatal Diagnostic Unit for FT structural and genetic screening, and for counseling. The university's ethics committee approved the research protocol. All presented cases had isolated uni- or bilateral kidneys congenital anomalies.

Case 1. MCDK.

31-year-old woman, gravida 1, para 0, with no obstetrical, medical or surgical history. The pregnancy evolution was normal up to this point. Detailed two-

dimensional (2D), three-dimensional (3D) and four-dimensional (4D) ultrasound examination was performed, using a Voluson 730 E8 machine (GE Healthcare, Zipf, Austria) at 11+3 weeks of amenorrhea. Gray-scale 2D examination showed unilateral increased echogenicity of the renal cortex, with pyelectasis appearance (Figure 1a), antero-posterior diameter of the right renal pelvis 1.7 mm, normal bilateral renal length. No other associated structural abnormalities were noted in terms of genetic markers and structural features; nuchal translucency 1.46 mm. Normal cardiac sweeps and STIC datasets were obtained. CRL (crown-rump length) was consistent with menstrual dates (59.4 mm). The mother's kidneys appeared normal and the family history was negative for kidney disease.

On the basis of the ultrasound findings and the negative combined screening for chromosomal anomalies, the couple was favorable counseled and expectation was felt to be the right choice. An early second trimester (16 +2 weeks) detailed morphology scan was performed. The diagnostic was unilateral multicystic dysplastic kidney (UMCDK) (right kidney), contralateral borderline pyelectasis (left kidney) (Figure 1b). The psychological pattern of the couple was characterized by an excessive anxiety, with an important profession component (the mother being a physician). The couple denied amniocentesis and after extensive multidisciplinary counseling, she decided medical termination of pregnancy. An intact specimen was obtained and pathological examination confirmed the diagnosis (Figure 2).

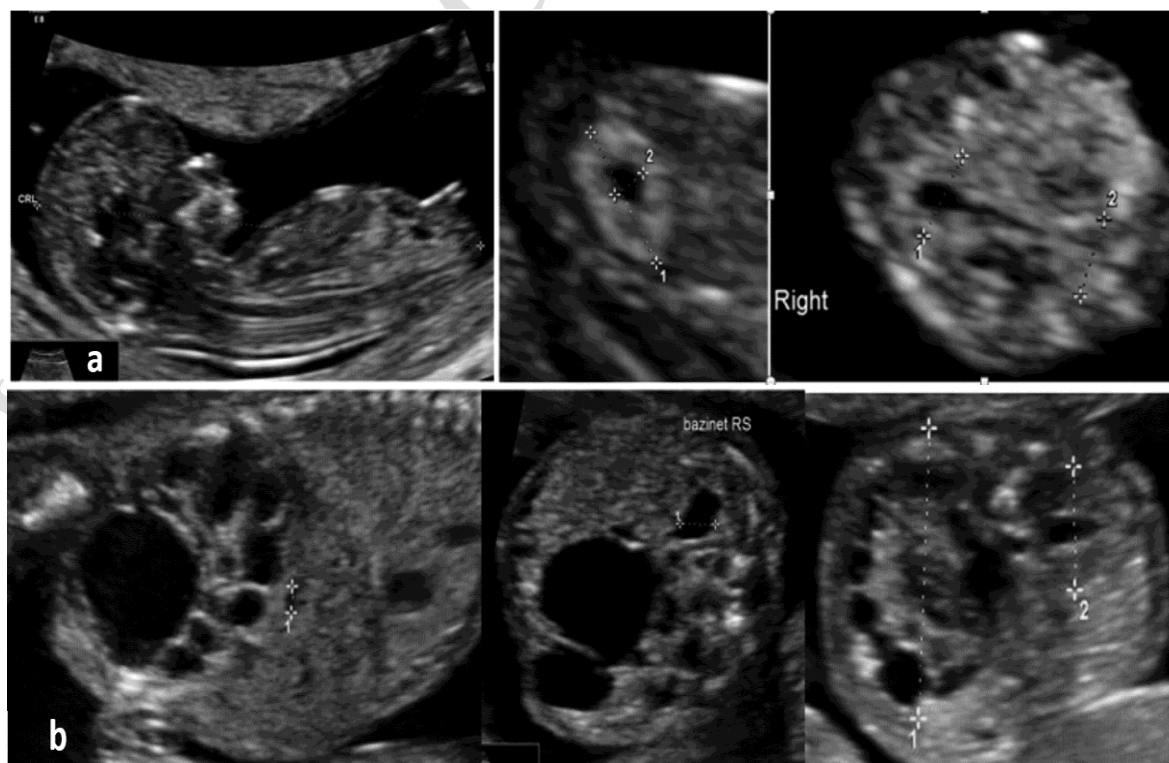


Figure 1: Case 1, ultrasound features 11+3 gestational weeks (a) and 16+2 gestational weeks (b)

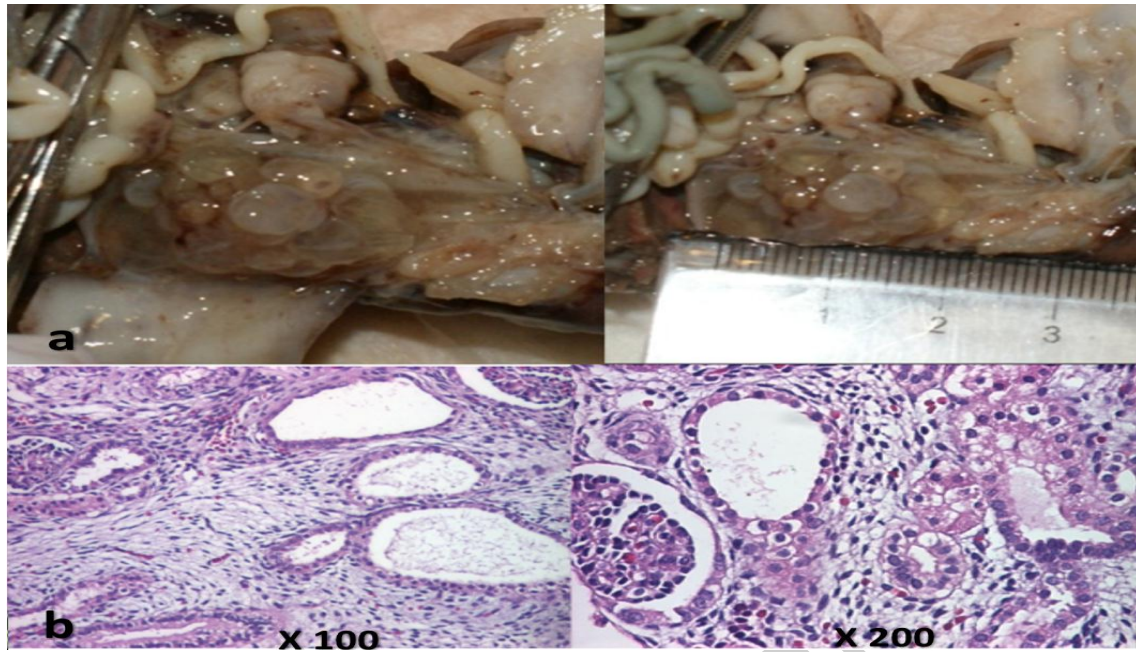


Figure 2: Case 1, macroscopic (a) and microscopic (b) pathology.

Case 2. MCDK.

32-year-old woman, gravida 1, para 0, also low risk pregnancy. The pregnancy was obtained after six years of fertility treatment. We used the same protocol for FT scan. Normal images of the fetal kidneys were obtained (Figure 3a). Also, normal FT genetic markers and normal anatomy were found on extended structural anomaly scan. The mother's kidneys appeared normal as well, and the family history was negative. Negative combined screening for chromosomal anomalies. At the ST (18 weeks) morphology scan, bilateral abnormal images of kidneys were present: unilateral pyelectasis (left kidney)

and hydronephrosis (right kidney). Also, the images could not rule-out the diagnosis of unilateral right megaureter. Amniocentesis showed normal karyotype. After counseling, the couple decided the continuation of pregnancy. The follow-up third trimester scan showed progressive increasing of right kidney volume and MCDK aspect (Figure 3b), and constant normal amniotic fluid volume, normal fetal growth, normal biophysical score. Postpartum, unilateral nephrectomy was performed, with eventless postoperative evolution and pathology confirmed the diagnosis (Figure 4).

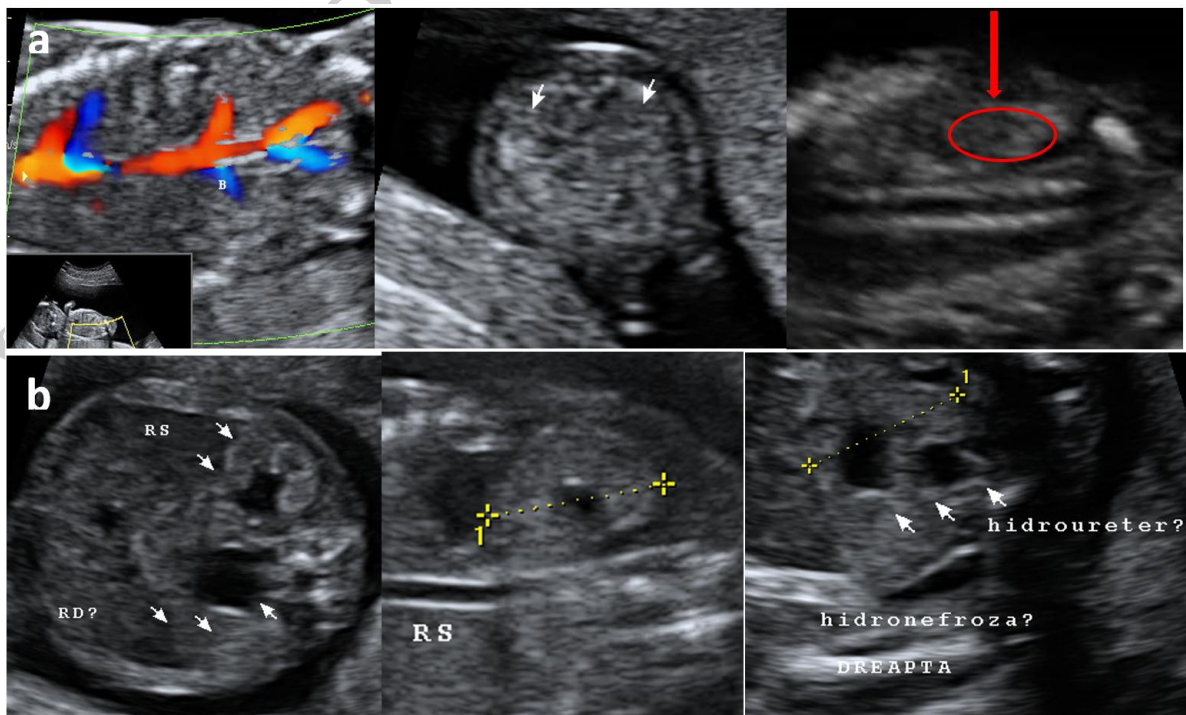


Figure 3: Case 2, ultrasound features 12+2 gestational weeks (a) and 18+1 gestational weeks (b).

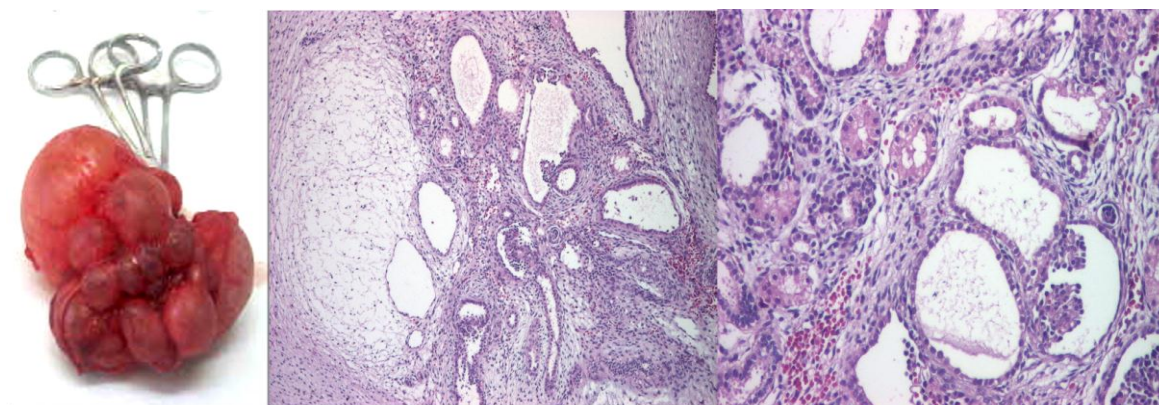


Figure 4: Case 2, macroscopic and microscopic pathology.

Case 3. Pyelectasis and cortical cysts.

A 31-year-old woman, gravida 2, para 0. The pregnancy was obtained after seven years of infertility and an ectopic fallopian pregnancy, and evolved normal up to this point. The scan was performed at 12+4 weeks of amenorrhea. Gray-scale 2D examination showed unilateral pyelectasis appearance, with antero-posterior diameter of the right renal pelvis 4.4 mm, normal bilateral renal length and echogenicity of the renal cortex (Figure 5a). No other associated structural abnormalities were observed at the detailed anomaly FT scan. The nuchal translucency- 2.73 mm. CRL - 73.2 mm. The mother's kidneys appeared normal, no family history present.

The pregnancy also screened negative at FT screening for chromosomal anomalies. The couple was as well favorable counseled and the early second trimester scan was offered. The diagnostic was suspicion of unilateral pyeloureteral duplication and cortical renal cysts (right kidney), normal left kidney (Figure 5b). The couple decided continuation of pregnancy. The psychological pattern of the couple was of intense desire of the long-expected child, maturity and good will. Postpartum findings showed right unilateral pyelectasis and two cortical cysts, normal left kidney (Figure 6).

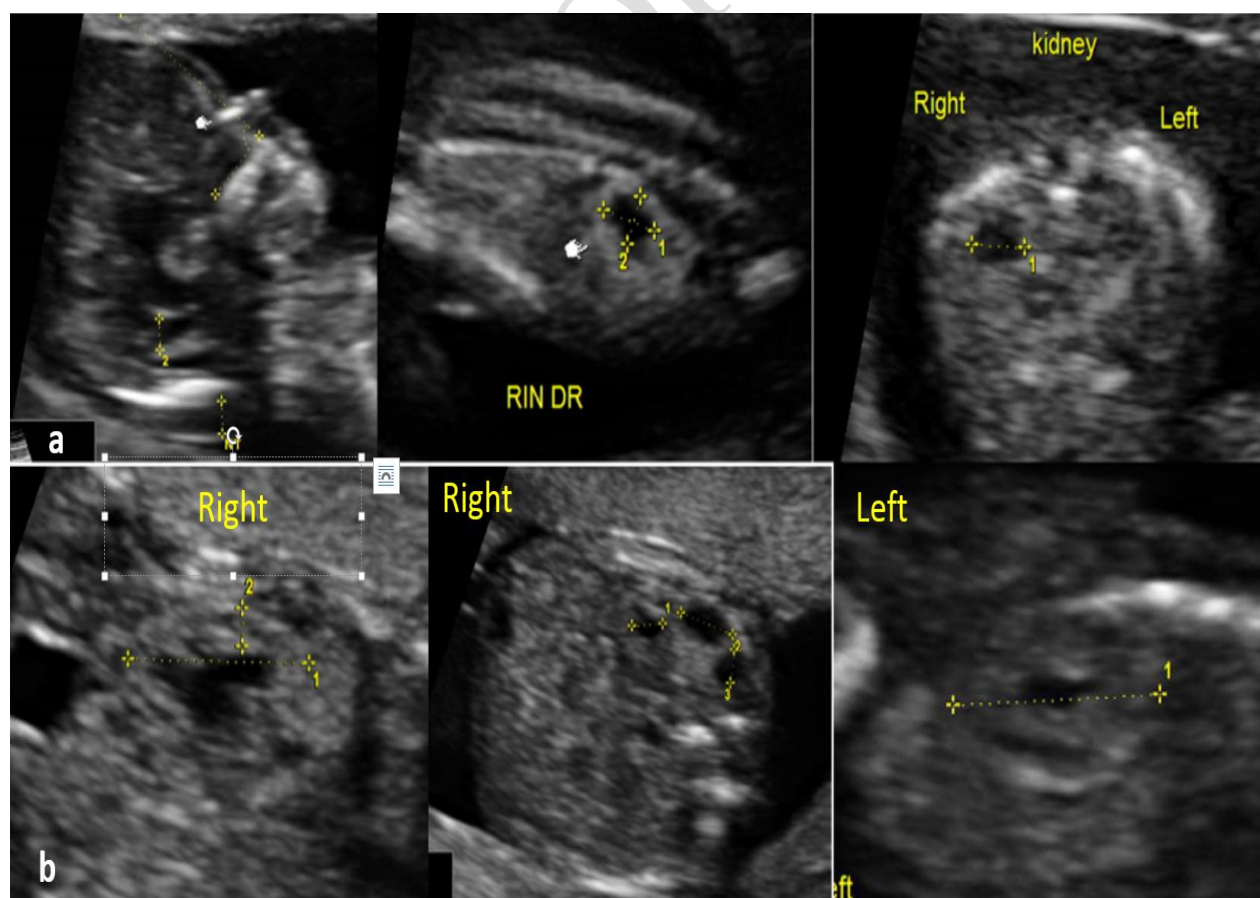


Figure 5: Case 3, ultrasound features 11+3 gestational weeks (a) and 16+2 gestational weeks (b).

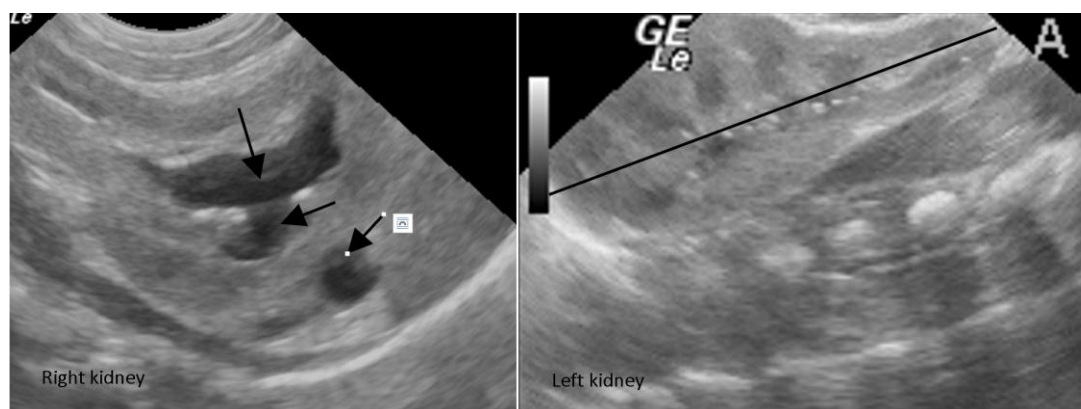


Figure 6: Case 3, ultrasound aspect postpartum, both kidneys.

Case 4. Bilateral agenesis.

24 year-old, gravida 2, para 0, with low-risk pregnancy, first trimester assessment for combined test at 12 gestational weeks. Normal amount of amniotic fluid, normal kidneys and the presence of bladder were noted. The ST anomaly scan (24 gestational weeks) showed severe oligohidramnios. Normal renal parenchyma was not visualized, large heterogeneous (with echogenic and cystic areas) masses in the renal bed, suggesting PKD, were present. A small image of bladder was transitory seen, between the two umbilical arteries abdominal course. Given the poor prognostic of the fetus, the couple elected termination. The autopsy showed abdominal masses attached to the urinary tract with different aspect than normal or polycystic kidneys. The histological examination yielded suprarenal hyperplasia replacing renal parenchyma. This case was previously reported.^[37]

Case 5. ARPKD

26 year-old woman, gravida 1, para 0, with low risk pregnancy. We used the same protocol for FT scan. Also,

normal FT genetic markers and normal FT anomaly scan, except the single umbilical artery noticed at scan. In early ST she was again referred to the PDU, by the general practitioner, for ultrasound suspected rupture of membranes, although the patient had no complaints of vaginal discharge. The operator noted severe oligohidramnios, slightly increase in renal echogenicity, normal kidneys length. Besides the minor marker (single umbilical artery) confirmation, no associated anomalies were found, but the fetus had severe very early-onset intrauterine growth restriction. The very characteristic image of molded fetus could be observed (Figure 7). The clinical exam and the vaginal pH ruled-out the spontaneous rupture of membranes. Medical termination was performed, after an excessive prolonged induction. Due to advanced degradation of the sample, microscopy and genetic assessment could not be performed. Figure 7 degradation of the sample, microscopy and genetic assessment could not be performed.

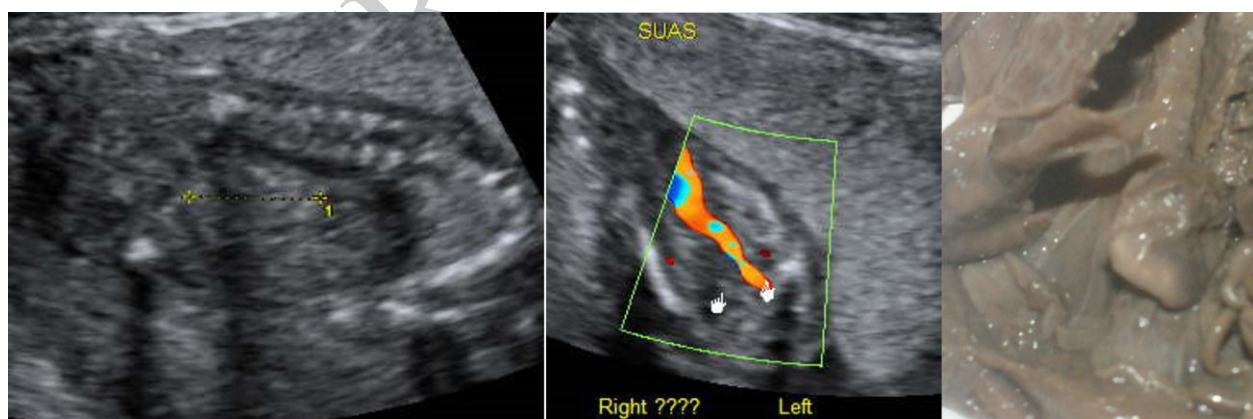


Figure 7: Case 5, ultrasound (kidney and paravesical absent right artery), and macroscopic pathological aspect.

DISCUSSIONS

There is proof that maternal anxiety is almost as profound before invasive maneuvers as before non-invasive ones, like the ultrasound exam. The psychological side effects of prenatal diagnostic procedures are a reality of nowadays medicine.

An abnormal ultrasound finding, although minor, always leads to parental anxiety and emotional confusion. After identifying a FT marker of abnormality, we should be able to clarify whether there is an important feature or not. This attitude might prove to be very difficult in cases of suspected kidneys anomalies, unlike other systems. On the other hand, diagnostic of an abnormality must be correlated with the test's accuracy, and in terms of minor

features in the FT, as pyelectasis and hyperechogenic kidneys, persists vagueness in definition and incidence.

In all presented cases 3D and 4D ultrasound was instrumental in ruling-out associated anomalies.

Two of these cases presented pyelectasis in the FT (cases 1 and 3). Although they presented very different outcome, both structural anomalies showed similar findings at the FT anomaly scan: pyelectasis appearance and normal kidney size. In terms of antero-posterior diameter of the pelvis, the first case was much less ultrasound symptomatic at the FT scan than the second case, yet the ST scan showed a much more severe evolution. The most important feature for the first case was the increased echogenicity of the renal cortex in the FT, with a pyelic diameter less than 2 mm. For the first case, pathology was important in confirming postmortem features, as fetal conventional autopsies is still the gold standard in diagnosis of fetal abnormalities.^[38] To our knowledge this is the first report linking the FT increased echogenicity of kidney parenchyma to early ST development of MCDK by serial scans, and the published literature does not offer sufficient information to draw definite conclusions.

The rest three cases had FT kidney images qualified by trained sonographers as "normal". Subsequently development of UMCDK, bilateral agenesis and ARPKD support our review conclusions.

The literature recommends nondirectiveness as a genetic counseling strategy that supports autonomous decision-making by patients. Yet, in clinical everyday basis, directiveness is difficult to avoid, due to especially nonverbal signals and due to the fact that some patients have difficulties in taking decisions, because of lack of medical knowledge regarding the suspected abnormality.

The pattern of reported cases also supports the hypothesis that patient anxiety level significantly predicts the pregnancy management decisions and also that top decisions are influenced by the difficulties encountered in obtaining the pregnancy.^[39]

There are no solid proofs that the prepregnancy counseling is beneficial for improving the low risk pregnancy outcome³⁵. However, it is important to make an accurate assessment of previous complicated pregnancy, and both maternal and fetal risks in a subsequent pregnancy must be assessed; this approach being able to improve outcome within selected groups, such as patients with high-risk for congenital kidney diseases.^[10] The continuity of care is important, especially when there has been a previous adverse pregnancy outcome.

Our cases' evolutions underline a well-known fact that the diagnosis of normality or abnormality of the kidneys is impossible in the FT. The long time evolution of fetal

kidney's diseases is mostly virtually impossible to predict prenatally, much less in early pregnancy. Unlike other systems (e.g. the heart, with complete embryogenesis at 8 weeks), the fetal kidneys have not completed their development (nephrogenesis is being complete after 34 weeks) and most congenital diseases do not develop in the FT, thus their FT appearance of may be as well unremarkable.

Although the first case suggest that MCDK may be suspected at the FT detailed scan, in our view, early FT scan cannot reliably diagnose any kidney pathology even if using high quality ultrasound systems. FT scan should be seen as a screening tool, despite the growing resolution of the machines. We do not really need to increase the anxiety of the pregnant women (or the anxiety of the couple) before we can give any reliable explanation of our findings, especially knowing that kidneys appear hyperechoic quite frequently in first trimester, without any subsequent abnormality in almost all cases.

Integration of high resolution ultrasound technology into standard clinical care will require thoughtful changes in patient counseling. Although the specifics of each case are distinct, they all underline principles of uncertainty, and lack of correlation between the FT and the ST findings. We can conclude that maybe FT scan has reached the point where guidelines for counseling in respect to FT findings must accompany guidelines for scanning, as for the ST scan. A correct diagnosis is essential for adequate counseling in pregnancy, and kidneys are inaccessible for FT diagnosis. Clinicians involved in antenatal diagnostic should be competent, aware of the limits of FT scan when counseling about suspected kidneys congenital anomalies, especially in early pregnancy.

CONCLUSIONS

At the time of a routine ST scan, isolated enlarged hyperechogenic and/or cystic fetal kidneys, can pose a significant diagnostic dilemma when discovered incidentally. There are multiple etiologies with variable implications in the prognosis of the PKD affected fetus as well as for future pregnancies. The identification of associated extrarenal abnormalities may lead to the recognition of syndromal cystic disease. There is strong evidence to support cilia serving as a common pathway for progressive cystogenesis in the various forms of PKD.

Accurate prenatal diagnosis in the absence of any positive family history is often not possible and a team approach to management – fetal medicine specialist, pediatric nephrologist or urologist, geneticists and pathologist – is very important. The family history and ultrasound examination of the siblings' and of the parents' kidneys is also essential in the prenatal evaluation.

Molecular characterization of PKD has increased our understanding of these diseases. Irrespective of the outcome of the affected pregnancy, DNA should be stored for further genetic counseling, despite their limited availability at the moment for widespread clinical use.

FT prenatal diagnosis holds even more uncertainty. We must acknowledge the possibility of a false-negative result because the differentiation of the renal system is delayed, or the diagnosis is not amenable to prenatal ultrasound at the respective gestational age.

An early diagnosis also carries a high risk of being false-positive. The sonographer should therefore be aware that an early false-positive diagnosis will at least cause significant anxiety to the parents and could even lead to a potentially lethal outcome of a healthy fetus, regarding uncertainty about the diagnosis and the consecutive prognosis^{40–41,43}.

The sonographer's diagnosis may have tremendous consequences for the family involved. This is especially relevant to chronic, non-lethal diseases carrying an uncertain prognosis that may or may not become obvious in adulthood such as ADPKD. The duality between the feasibility of the diagnosis in utero and the late uncertain prognosis of ADPKD often makes difficult the parents' counseling.

Even if ARPKD is suggested, the diagnostic currently has limitations, and detailed ultrasound characterization of the renal structure is difficult.

FUNDING SOURCES: none

DISCLOSURE: None of the authors have a conflict of interest.

ACKNOWLEDGEMENTS

The authors would like to thank the University Hospital researchers for their contribution in collecting the ultrasound data and pregnancy outcome data, and the parents involved for their permission to publish the case.

REFERENCES

- Public Health Agency of Canada (PHAC). Perinatal health Indicators for Canada 2011. Ottawa, 2012; 19–21.
- Kontopoulos E, Odibo A, Wilson RD. Current controversies in prenatal diagnosis 2: are we ready to screen for fetal anomalies with first trimester ultrasound?. *Prenat Diagn.*, 2013; 33: 9–12.
- ISUOG Practice Guidelines: performance of first-trimester fetal ultrasound scan. *Ultrasound Obstet Gynecol.*, 2013; 41: 102–113.
- Nicolaides KH. A model for a new pyramid of prenatal care based on the 11 to 13 weeks' assessment. *Prenat Diagn* 2011; 31: 3–6. Syngelaki A, Chelemen T, Dagklis, T, et al. Challenges in the diagnosis of fetal non-chromosomal abnormalities at 11–13 weeks. *Prenat Diagn.*, 2011; 31: 90–102.
- Kelly T, Suddes J, Howel D, et al. Comparing medical versus surgical termination of pregnancy at 13–20 weeks of gestation: a randomised controlled trial. *BJOG.*, 2010; 117: 1512–1520.
- Fisher J. First-trimester screening: dealing with the fall-out. *Prenat Diagn.*, 2011; 31: 46–49.
- Cohen HL, Cooper J, Eisenberg P, Mandel FS, Gross BR, Goldman MA, Barzel MA, Rawlinson KF. Normal length of fetal kidneys: sonographic study in 397 obstetric patients. *AJR Am J Roentgenol.*, 1991; 157: 545–548.
- Bowie JD, Rosenberg ER, Andreotti RF, Fields SI. The changing sonographic appearance of the kidneys during pregnancy. *J Ultrasound Med.*, 1983; 2: 505–507.
- Nishi T, Iwasaki M, Yamoto M, Nakano R. Prenatal diagnosis of autosomal recessive polycystic kidney disease by ultrasonography and magnetic resonance imaging. *Acta Obstet Gynecol Scand.*, 1991; 70(7–8): 615–617.
- Roume, J. and Ville, Y., Prenatal diagnosis of genetic renal diseases: breaking the code. *Ultrasound Obstet Gynecol*, 2004; 24: 10–18.
- M, Maugey-Laulom B, Eurin D, Didier F, Avni EF. Prenatal sonographic patterns in autosomal dominant polycystic kidney disease: a multicenter study. *Ultrasound Obstet Gynecol.*, 2004; 24: 55–61.
- Ulrike J, Rudnik-Schöneborn S, Zerres K, Misselwitz J Kidney growth and renal function in unilateral multicystic dysplastic kidney disease. *Pediatric Nephrology.*, 1998; 12: 567–571.
- Atiyeha B, Husmanna D, Bauma M. Contralateral renal abnormalities in multicystic-dysplastic kidney disease. *The Journal of Pediatrics.*, 1992; 121: 65–67.
- Wisser J, Hebisch G, Froster U, Zerres K, Stallmach T, Leumann E, Schinzel A, Huch A. Prenatal sonographic diagnosis of autosomal recessive polycystic kidney disease (ARPKD) during the early second trimester. *Prenat Diagn.*, 1995; 15: 868–871.
- Michaud J, Russo P, Grignon A, Dallaire L, Bichet D, Rosenblatt D, Lamothe E, Lambert M. Autosomal dominant polycystic kidney disease in the fetus. *Am J Med Genet.*, 1994; 51: 240–246.
- Fick GM, Johnson AM, Strain JD, Kimberling WJ, Kumar S, Manco-Johnson ML, Duley IT, Gabow PA. Characteristics of very early onset autosomal dominant polycystic kidney disease. *J Am Soc Nephrol.*, 1993; 3: 1863–1870.
- Chaumoitre, K., Brun, M., Cassart, M., Maugey-Laulom, B., Eurin, D., Didier, F., Avni, E. F. and for the Groupe Radiopédiatrique de Recherche en Imagerie Foetale (GRRIF), Differential diagnosis of fetal hyperechogenic cystic kidneys unrelated to renal tract anomalies: a multicenter study. *Ultrasound Obstet Gynecol*, 2006; 28: 911–917.
- Lin F, Satlinb LM. Polycystic kidney disease: the

- cilium as a common pathway in cystogenesis. *Curr Opin Pediatr* 2004; 16: 171–176.
19. Zerres K, Mucher G, Becker J, Steinkamm C, RudnikSchoneborn S, Heikkila P, Rapola J, Salonen R, Germino GG, Onuchic L, Somlo S, Avner ED, Harman LA, Stockwin JM, Guay-Woodford LM. Prenatal diagnosis of autosomal recessive polycystic kidney disease (ARPKD): molecular genetics, clinical experience, and fetal morphology. *Am J Med Genet.*, 1998; 76: 137–144.
 20. Webb NJA, Lewis MA, Bruce J, et al. Unilateral multicystic dysplastic kidney: the case for nephrectomy. *Arch Dis Child.*, 1997; 76: 31–4.
 21. De Bruyn R, Marks SD. Postnatal investigation of fetal renal disease. *Semin Fetal Neonatal Med.*, 2008 Jun; 13(3): 133–41. doi: 10.1016/j.siny.2007.10.008. Epub 2008 Jan 14.
 22. Dungan JS, Fernandez MT, Abbott PL, Thiagarajah S, Howards SS, Hogge WA. Multicystic dysplastic kidney: natural history of prenatally detected cases. *Prenat Diagn.*, 1990 Mar; 10(3): 175–82.
 23. Matsell DG, Bennett T, Goodyer P, Goodyer C, Han VK. The pathogenesis of multicystic dysplastic kidney disease: insights from the study of fetal kidneys. *Lab Invest.*, 1996 May; 74(5): 883–93.
 24. Webb NJA, Lewis MA, Bruce J, et al. Unilateral multicystic dysplastic kidney: the case for nephrectomy. *Arch Dis Child.*, 1997; 76: 31–4.
 25. Gordon AC, Thomas DFM, Arthur RJ, Irving HC. Multicystic dysplastic kidney: is nephrectomy still appropriate? *J Urol.*, 1988; 140: 12314.
 26. Doroshaw LW, Abeshouse BS. Congenital unilateral solitary kidney: report of 37 cases and a review of the literature. *Urol Survey.*, 1961; 11: 219–29.
 27. Ranke A, Schmitt M, Didier F, Droulle P. Antenatal diagnosis of Multicystic Renal Dysplasia. *Eur J Pediatr Surg.*, 2001 Aug; 11(4): 246–54.
 28. van Eijk, L., Cohen-Overbeek, T. E., den Hollander, N. S., Nijman, J. M. and Wladimiroff, J. W., Unilateral multicystic dysplastic kidney: a combined pre- and postnatal assessment. *Ultrasound Obstet Gynecol*, 2002; 19: 180–183.
 29. Okada T, Yoshida H, Matsunaga T, Kouchi K, Ohtsuka Y, Saitou T, Matsuura G, Ohnuma N. Multicystic dysplastic kidney detected by prenatal ultrasonography: natural history and conservative management. *Pediatr Surg Int.*, 2003 May; 19(3): 207–10. Epub 2003 Apr 8.
 30. Aubertin, G., Cripps, S., Coleman, G., McGillivray, B., Yong, S.L., Van Allen, M., Shaw, D. and Arbour, L., Prenatal diagnosis of apparently isolated unilateral multicystic kidney: implications for counselling and management. *Prenat. Diagn.*, 2002; 22: 388–394.
 31. Damen-Elias, H. A. M., De Jong, T. P. V. M., Stigter, R. H., Visser, G. H. A. and Stoutenbeek, P. H., Congenital renal tract anomalies: outcome and follow-up of 402 cases detected antenatally between 1986 and 2001. *Ultrasound Obstet Gynecol*, 2005; 25: 134–143.
 32. Becker AM. Postnatal evaluation of infants with an abnormal antenatal renal sonogram. *Curr Opin Pediatr.*, 2009; Apr; 21(2): 207–13.
 33. Guerriero, S., Gerada, M., Piras, S., Ajossa, S., Ottonello, G., Masnata, G. and Melis, G. B., Bilateral fetal hyperechogenic kidneys associated with normal amniotic fluid: an ethical dilemma in a normal variant?. *Prenat. Diagn.*, 2006; 26: 190–191.
 34. Whitlow, B. J., Lazanakis, M. L., Kadir, R. A., Chatzipapas, I. and Economides, D. L., The significance of choroid plexus cysts, echogenic heart foci and renal pyelectasis in the first trimester. *Ultrasound Obstet Gynecol*, 1998; 12: 385–390.
 35. Moos MK. Preconceptional health promotion: a health education opportunity for all women *Women Health.*, 1989; 15(3): 55–68.
 36. Zalel, Y., Lotan, D., Achiron, R., Mashiach, S. and Gamzu, R., The early development of the fetal kidney—an in utero sonographic evaluation between 13 and 22 weeks' gestation. *Prenat. Diagn.*, 2002; 22: 962–965.
 37. Iliescu D, Tudorache S, Comanescu A et al. Improved detection rate of structural abnormalities in the first trimester using an extended examination protocol. *Ultrasound Obstet Gynecol.*, 2013; 42: 300–309.
 38. Scheimberg I. The genetic autopsy. *Curr Opin Pediatr.*, 2013 Dec; 25(6): 659–65.
 39. Wallerstein R, Strmen V, Durcan J, et al. Factors in decision making following genetic counseling for pre-natal diagnosis of de novo chromosomal rearrangements. *Clinical Genetics.*, 2006; 69: 497–503.
 40. Carr MC, Benacerraf BR, Estroff JA, Mandell J. Prenatally diagnosed bilateral hyperechoic kidneys with normal amniotic fluid: postnatal outcome. *J Urol.*, 1995; 153: 442–444.
 41. Jeffery S, Sagar-Malik AK, Economides DL, Blackmore SE, MacDermot KD. Apparent normalisation of fetal renal size in autosomal dominant polycystic kidney disease (PKD1). *Clin Genet.*, 1998; 53: 303–307.
 42. Fisher J. First-trimester screening: dealing with the fall-out. *Prenat Diagn.*, 2011; 31: 46–49.
 43. Estroff JA, Mandell J, Benacerraf BR. Increased renal parenchymal echogenicity in the fetus: importance and clinical outcome. *Radiology.*, 1991; 181: 135–139.
 44. Cassart M, Eurin D, Didier F, Guibaud L, Avni EF. Antenatal renal sonographic anomalies and postnatal follow-up of renal involvement in Bardet-Biedl syndrome. *Ultrasound Obstet Gynecol.*, 2004; 24: 51–54.
 45. Lewis MA. Demography of renal disease in childhood. *Semin Fetal Neonatal Med.*, 2008 Jun; 13(3): 118–24.
 46. Chitty LS¹, Altman DG. Charts of fetal size: kidney and renal pelvis measurements. *Prenat Diagn.*, 2003 Nov; 23(11): 891–7.