

EFFICACY OF PENTOXIFYLLINE IN THE TREATMENT OF ORAL SUB MUCOUS
FIBROSIS - A PILOT STUDYDr. Chaithra Kalkur¹, Dr. Atul P Sattur and Dr. Kruthika S. Guttal³¹Senior Lecturer, Century International Institute of Dental Sciences and Research Centre, Poinachi, Kasargod, Kerala.²Professor, Department of Oral Medicine & Radiology, S.D.M College of Dental Sciences & Hospital, Sattur, Dharwad-580009, Karnataka.³Associate Professor, Department of Oral Medicine & Radiology, S.D.M College of Dental Sciences & Hospital, Sattur, Dharwad-580009, Karnataka.***Corresponding Author: Dr. Chaithra Kalkur***

Senior Lecturer, Century International Institute of Dental Sciences and Research Centre, Poinachi, Kasargod, Kerala.

Article Received on 21/08/2016

Article Revised on 10/09/2016

Article Accepted on 30/09/2016

ABSTRACT

Objective: This study was designed to determine the effect of Pentoxifylline on the clinical and pathologic course of Oral Submucous Fibrosis (OSMF). **Methods:** This study was conducted as a randomized clinical trial incorporating a control group (antioxidant therapy, Tab Lycored once daily) in comparison to Pentoxifylline test cases (400mg 3 times daily, tablets). The treatment period was 3 months and a total of 50 cases of advanced fibrosis were included in this study. **Results:** Review of the patients and controls was done at an interval of 30 days and subjective and objective measurements were recorded. Significant comparisons with regard to improvement were recorded as objective criteria of mouth opening, tongue movement and protrusion, relief from perioral fibrotic bands and coexisting lesions. Subjective symptoms of burning sensation of mouth, tinnitus, difficulty in swallowing, and difficulty in speech were also recorded. Statistical analysis done using t test, Mann-Whitney test and follow up data at each visit with respect to each other was calibrated using ANOVA test. **Conclusion:** The drug Pentoxifylline is said to have the property of suppressing leukocyte function while altering fibroblast physiology and stimulating fibrinolysis. This investigation points to the effectiveness of Pentoxifylline as an adjunct therapy in the routine management of OSMF.

KEYWORDS: Pentoxifylline, Antioxidant, Lycored, Oral Submucous Fibrosis.

INTRODUCTION

Oral sub mucous fibrosis (OSMF) is a chronic, pre-cancerous condition predominantly seen among betel quid chewers in south Asian countries. The disease was first reported in early 1950s.^[1] In 1952, Schwartz described five Indian women from Kenya with a condition of the oral mucosa including the palate and pillars of the fauces, which he called "atrophia idiopathica (tropica) mucosae oris" later it was termed as oral sub mucous fibrosis (OSMF). Other names are "diffuse oral sub mucous fibrosis", "idiopathic scleroderma of the mouth", "idiopathic palatal fibrosis", "sclerosing stomatitis" and "juxta-epithelial fibrosis". According to WHO the OSMF is an oral precancerous condition. The precancerous nature of OSMF was first postulated by Paymaster he also described the development of a slow-growing squamous cell carcinoma in one third of OSMF cases seen in the Tata Memorial Hospital, Bombay.^[2] Aetiology for OSMF is by a number of factors like chillies consumption, areca nut chewing, autoimmunity and genetic predisposition

have been implicated in the pathogenesis of sub mucous fibrosis.

Pindborg (1966) defined OSMF as, "an insidious, chronic disease affecting any part of the oral cavity and sometimes the pharynx. Although occasionally preceded by and/or associated with vesicle formation, it is always associated with juxta-epithelial inflammatory reaction followed by fibro elastic change of the lamina propria, with epithelial atrophy leading to stiffness of the oral mucosa and causing trismus and inability to eat".^[3] The overall prevalence rate in India is believed to be about 0.2-0.5% and the prevalence by gender varies from 0.2-2.3% in males to 1.2-4.5% in females.^[4] It is considered to have a high degree of malignant potential, which ranges between 2.3% and 7.6%.^[5]

Pentoxifylline is a tri-substituted methylxanthine derivative. This suppresses leukocytes function and alters fibroblast physiology and stimulates fibrinolysis. It also causes neutrophil degranulation and the release of

peroxides, promotes natural killer cell activity and inhibits the production of tumour necrosis factor, and T and B cell activation. Thus the anti inflammatory and immunomodulatory actions of pentoxifylline have definite therapeutic advantages in the management of OSMF.^[6]

This study points to the effectiveness of pentoxifylline as an adjunct therapy in the routine management of OSMF.

MATERIALS AND METHODS

The present study was conducted at the outpatient Department of Oral medicine and Radiology, in a referral dental hospital included in the study after obtaining an informed consent from the patients. The study comprised a prospective clinical analysis of 50 randomly selected OSMF patients, graded as clinically advanced, judged by established clinico-pathologic parameters and evaluated in randomized clinical trial. All the patients recruited to the study were of comparable disease progression and share the common demographic features of ethnicity, geographic localization, and socioeconomic status. A structured format used to collect relevant information from each patient. Before commencing the treatment, patients were counselled to quit habits such as areca nut, pan masala, gutkha chewing and tobacco use.

Inclusion criteria: Patients who were not on any medication for OSMF. Patients who agreed for biopsy and blood investigations and clinically and histopathologically diagnosed OSMF cases. Exclusion criteria: OSMF patients with systemic diseases and patients who are allergic to study drug.

All the participants were explained the need and design of the study, the pharmacological therapy, possible adverse effects and the need for undergoing a thorough clinical examination and investigations before the start of the study. The study sample comprises of 50 OSMF patients and were divided into 2 groups. Experimental drug group comprises of 30 patients where the active treatment option was pentoxifylline, [Trental tab 400mg tablets] and the standard drug group includes 20 patients was managed with antioxidant capsules [Tab. Lycored one capsule before sleep daily]. The patients before administration of pentoxifylline underwent detailed haematological and clinical tests to rule out systemic ailments of hypertension, diabetes mellitus, cardiac diseases, malignant ulcers, duodenal and gastric peptic ulcers, bleeding diatheses, and the like. The haematological work up comprised recording of total leukocyte count [TC], differential count [DC], haemoglobin values [Hb], platelet count [PC], clotting and bleeding times [CT, BT], recordings of blood pressure and pulse characters of the patients. One patient who complained of continued gastric irritation was dropped from the study after the induction period of one month. No other reportable complications or side effects were recorded from any of the patients included in the study design and the clinical trial was carried out further

for 3 more months. Clinical follow up and review of all the patients was carried out at 30 days intervals for the whole trial period of 3 months. During each visit, recordings to evaluate the objective and subjective improvement from disease of both the groups were assessed and scored and entered in a specially designed 'proforma' drawn for the purpose. To prevent bias due to interpersonal variability, the same investigator measured all the patients during each visit.

Diagnosis is based on history, clinical features like burning sensation in the mouth, intolerance to spicy foods, presence of fibrous bands, blanching of the mucosa and restricted mouth opening. All the cases were clinically categorized according to Khanna JN and Andrade Classification.

The following clinical parameters will be assessed during follow up.

1. Mouth opening: Maximum mouth opening between the incisal edges of the upper and lower incisors at the mesio-incisal line angle measured using callipers.
2. Cheek flexibility and Tongue protrusion [measurement in centimetres from the reference point of lip vermillion].
3. Relief from burning sensation-using Visual Analogue Scale.

Statistical comparisons of both the groups were done using T-Test, Mann-Whitney U Test and ANOVA.

RESULTS

The Present study was conducted as a randomized clinical trial. The study sample comprises of 50 OSMF patients. These patients were divided into 2 groups as a control group in comparison to Pentoxifylline test cases.

Pentoxifylline group consists of 29-Male and one Female, where Grade I OSMF-4 Patients, Grade II-10, Grade III-16. Control group consists of 20 -Male, where Grade I OSMF -2 Patients, Grade II-4, Grade III-14 patients. The treatment period was 3 months. Significant comparisons with regard to improvement were recorded as objective criteria and Subjective symptoms were also recorded.

1. Improvement in Mouth opening: The present study showed that there is a marginal increase in mouth opening in test group than control group. However the results are not statistical significant according to 't' test. [Table 1]
2. Improvement in tongue protrusion base-line reference to vermillion lip: The relative difference in tongue protrusion was compared between study and control groups at each visit with respect to base-line value using modified 't' test. Tongue protrusion does not show any significant finding. [Table 2]
3. Visual Analogue Scale: Comparison of improvement of the symptom was made at each visit between both the groups. The comparisons were 'highly significant'

in all the visits. Significant improvement was seen in reduction in burning sensation in the pentoxifylline group when compared to control group according to Mann –Whitney U Test.[Table 3]

4. Comparison of follow up visits by repeated measures: Statistical analysis done by ANOVA test. On follow up visits experiment group shows much improvement in burning sensation than control group.[Graph]

Table 1: Statistical Analysis using T-Test for assessment of Improvement in mouth opening.

		Test		Control		t-value	p
		Mean	Std. Dev.	Mean	Std. Dev.		
Mouth Opening	1st visit	2.5200	0.7008	2.5800	0.7281	-0.2655	0.7920
	2nd visit	2.6000	0.7348	2.6400	0.7507	-0.1703	0.8657
	3rd visit	2.6650	0.7228	2.6600	0.7358	0.0217	0.9828

Table2: Statistical Analysis using T-Test for assessment of Improvement in tongue protrusion.

Tongue Protrusion		Mean	Std. Dev.	Mean	Std. Dev.	t-value	P
	1st visit	1.6150	0.5040	1.5600	0.5009	0.3462	0.7311
	2nd visit	1.7800	0.4819	1.7050	0.4807	0.4928	0.6250
	3rd visit	1.8450	0.4407	1.7700	0.4508	0.5320	0.5978

Table 3: Statistical Analysis using Mann –Whitney U Test to assess burning sensation in according to Visual Analogue Scale.

		Test		Control		U-value	Z-value	P-value
		Mean	Std. Dev.	Mean	Std. Dev.			
VAScore	1st visit	5.8000	2.2384	5.8500	2.0590	198.0000	-0.0541	0.9569
	2nd visit	4.4000	1.9574	5.8000	2.0673	115.0000	-2.2993	0.0215
	3rd visit	3.3000	1.8382	5.1000	2.2455	105.5000	-2.5562	0.106

Graph: Comparison of follow up visits by repeated measures in test group and control group. Statistical analysis done by ANOVA test.

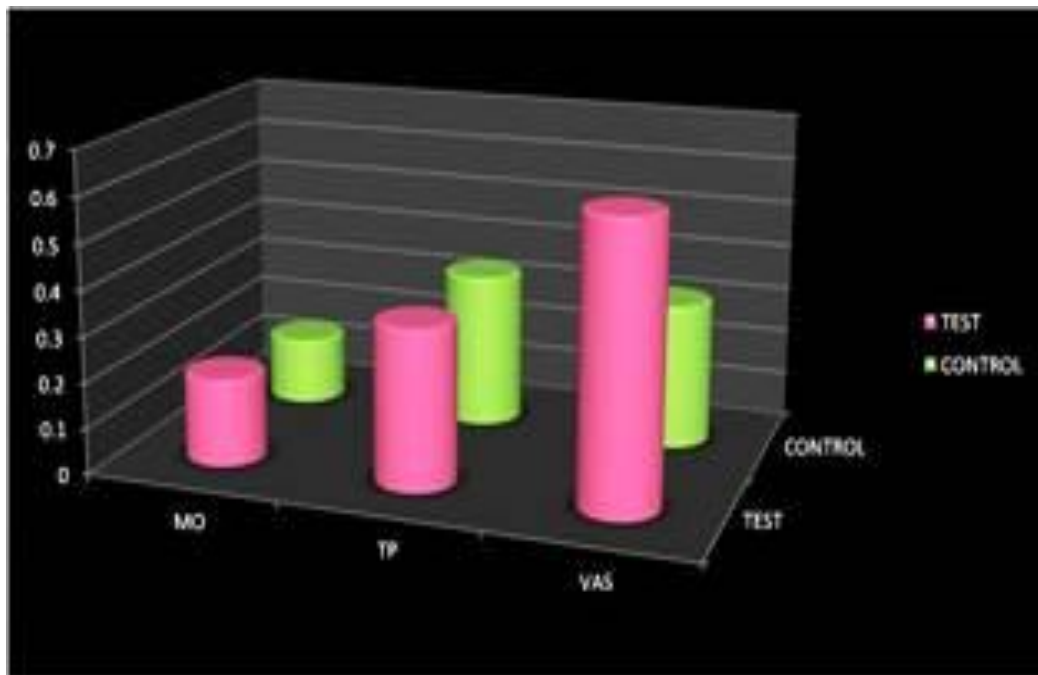
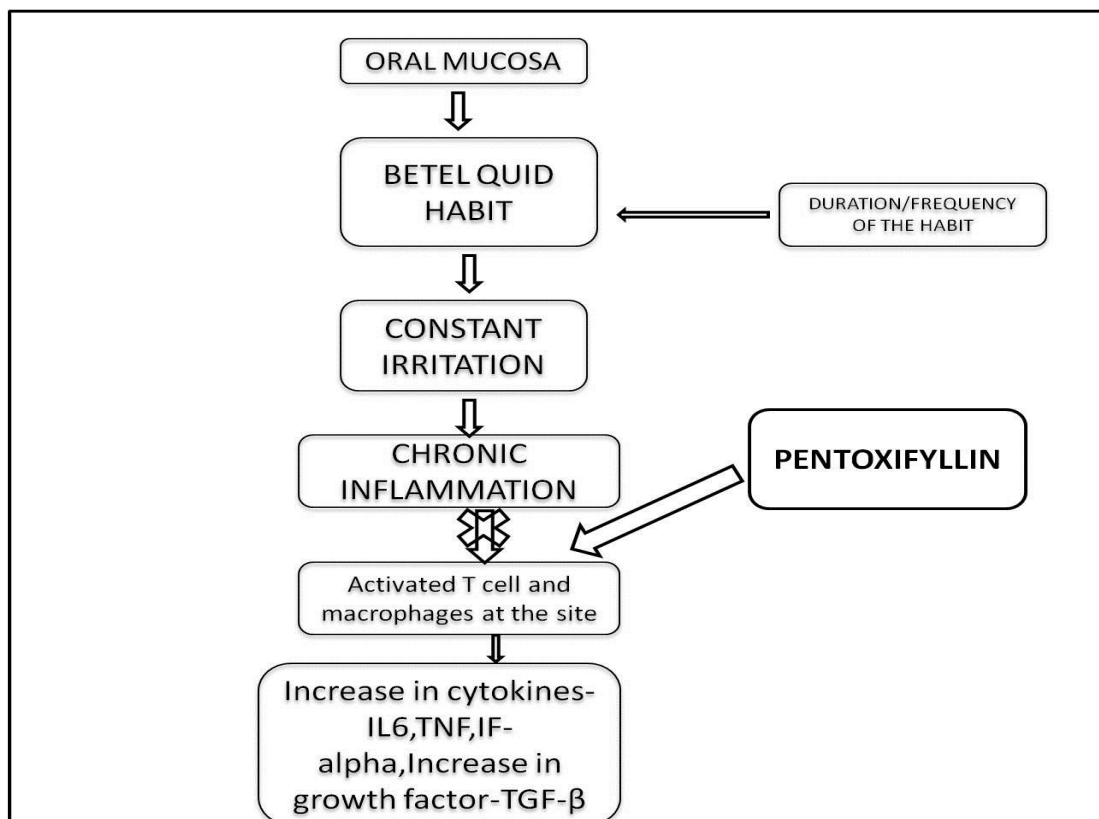


Figure 1: Mechanism of action of Pentoxiflin in OSMF.



DISCUSSION

Pentoxifylline [1-(5-oxyhexyl)-3,7dimethylxanthine] was developed by Hoechst Aktiengesellschaft in the seventies. Pentoxifylline obtained marketing authorisation in Germany 1972 and in the USA 1984 for the treatment of intermittent claudication on the basis of chronic occlusive arterial disease of the limbs. It belongs to a group of vasoactive drugs which improve peripheral blood flow and thus enhance peripheral tissue oxygenation. Pentoxifylline is a methylxanthine that improves perfusion in the impaired microcirculation of peripheral and cerebral vascular beds. This hemorheologic activity mostly involves inhibition of cyclic-3', 5'-phosphodiesterase [PDE], leading to raised intracellular cyclic adenosine monophosphate [cAMP] and activation of protein kinase A [PKA]. Complete absorption of the drug on oral administration. Peak plasma concentration 3.2 hours. Elimination by the kidneys.^[7, 8]

The biologic activities of pentoxifylline includes increasing red cell deformability, leukocyte chemotaxis, antithrombin and anti-plasmin activities, and more importantly to the present context, its fibrinolytic activity. Pentoxifylline decreases red cell and platelet aggregation, granulocyte adhesion, fibrinogen levels, and whole blood viscosity. Recent work has delineated pentoxifylline's ability to decrease production of tumour necrosis factor alpha and reduce some of the systemic toxicities mediated by interleukin-2. These two cytokines are important mediators of the inflammatory response. In addition, pentoxifylline has been shown to increase the

production of PGE₂ and PGI₂ by vascular epithelium, important in maintaining cellular integrity and homeostasis after acute injury.^[7] (Figure 1)

The treatment modalities for OSMF still remain a challenge. Many therapeutic and surgical treatment modalities have been advocated to relieve the patients of the symptoms, but no definitive and widely accepted treatment is available till date. The first step of preventive measure should be in advising the patient to discontinue the habit, through education, counselling and advocacy. Treatment options for OSMF include, iron and multivitamin supplements, lycopene - antioxidant, steroids, hyaluronidase, human placenta extracts, chemotrypsin and pentoxifylline. In severe cases Laser ablation and surgery, including cutting of the fibrous bands of the jaw muscles and temporomandibular joint, has been used. These have proved to be symptomatic and are predominantly aimed at improving mouth movements. However, each treatment has its own limitations.^[9]

The present study showed that there is a marginal increase in mouth opening in test group than control group. However the result of this study was not statistically significant. Significant improvement was seen in reduction in burning sensation in the pentoxifylline group when compared to control group. Adverse effects such as mild gastritis, gastric irritation and peripheral flushing were reported with the use of pentoxifylline. Notably, pentoxifylline's a safe

drug that is usually well tolerated when administered as the conventional controlled-release formulation.

Gastrointestinal symptoms [i.e. nausea and dyspepsia] and dizziness are the most common complaints.

In one study 29 randomly selected OSMF patients, experimental group is given pentoxifyllin tablets and compared with control group which is given multi-vitamin capsules. Treatment period was 7 months. There was significant improvement observed at the end of the trial period.^[10] According to Maher et al. multiple minerals and micronutrients showed significant improvement in mouth opening of 41% of the patients.^[11] Whereas, Borle and Borle showed insignificant improvement in mouth opening with Vitamin A.^[12]

According to Karemore and Motwani study, Lycopene has also showed significant improvement in mouth opening.^[13] Singh et al. showed an improvement in the sign score of the OSMF patients when they were administered a combination of triamcinolone acetonide and hyaluronidase at 15 days interval for 22 weeks.^[14] Mehrotra et al. have shown the efficacy of newer drug pentoxifylline in the improvement of symptoms of OSMF.^[15] Patil et al. evaluated the efficacy of the newer drug, pentoxifylline in the improvement of various clinical parameters such as, mouth opening, tongue protrusion, pain associated with the lesion, burning sensation and difficulty in speech and swallowing in a larger sample than the previously conducted studies.^[16]

CONCLUSION

The present study revealed the use of pentoxifyllin in the treatment of OSMF. The results of the present study showed that pentoxifylline was found to be effective in the management of OSMF. However, it has shown few side effects in the patients who were administered the drug, but showed better patient outcomes.

ACKNOWLEDGEMENT

The study was possible thanks to the Department of Oral Medicine & Radiology, S.D.M. College of Dental Sciences & Hospital, Sattur, Dharwad, Karnataka.

REFERENCES

1. Utsunomiya H, Tilakaratne W M, Oshiro K, Maruyama S et al. Extracellular matrix remodelling in oral submucous fibrosis: its stage-specific modes revealed by immunohistochemistry and in situ hybridization. *Oral Pathol Med.*, 2005; 34: 498–07.
2. Rajendran R. Oral submucous fibrosis: aetiology, pathogenesis, and future research Bulletin of the World Health Organization., 1994; 72 (6): 985-96.
3. Reddy V, Wanjari P V, Banda N R, Reddy. Oral Submucous Fibrosis: Correlation of Clinical Grading to various habit factors. *International Journal of Dental Clinics.*, 2011; 3 (1): 21-4.
4. Khan S, Chatra L, Prashanth SK, Veena KM, Rao PK. Pathogenesis of oral submucous fibrosis. *J Cancer Res Ther.*, 2012; 8: 199-03.
5. Reddy D, Bhat A K. Malignant potential of oral submucous fibrosis due to intraoral trauma. *Indian J Med Sci.*, 2000; 54: 182-7.
6. Chole R H, Gondivkar S M, b, Gadbaill A R et al. Review of drug treatment of oral submucous fibrosis. *Oral Oncology.*, 2012; 48: 393–98.
7. Ward A, Clissold SP. Pentoxifylline review of its pharmacodynamic and pharmacokinetic properties and its therapeutic efficacy. *Drug Eva.*, 1987; 34: 50–97.
8. Dousa TP. Cyclic-3', 5'-nucleotide phosphodiesterase isozymes in cell biology and pathophysiology of the kidney. *Kidney Int.*, 1999; 55: 29–62.
9. Canniff JP, Harvey W. The aetiology of oral submucous fibrosis: The stimulation of collagen synthesis by extracts of areca nut. *Int J Oral Surg.*, 1981; 10: 163-7.
10. Rajendran R, Rani V, Shaikh S. Pentoxifylline therapy: A new adjunct in the treatment of oral submucous fibrosis. *Indian J Dent Res.*, 2006; 17: 190-8.
11. Maher R, Aga P, Johnson NW, Sankaranarayanan R, Warnakulasuriya S. Evaluation of multiple micronutrient supplementation in the management of oral submucous fibrosis in Karachi, Pakistan. *Nutr Cancer.*, 1997; 27: 41-7.
12. Borle RM, Borle SR. Management of oral submucous fibrosis: A conservative approach. *J Oral Maxillofac Surg.*, 1991; 49: 788-91.
13. Karemore TV, Motwani M. Evaluation of the effect of newer antioxidant lycopene in the treatment of oral submucous fibrosis. *Indian J Dent Res.*, 2012; 23: 524-8.
14. Singh M, Niranjana HS, Mehrotra R, Sharma D, Gupta SC. Efficacy of hydrocortisone acetate/hyaluronidase vs. triamcinolone acetonide/hyaluronidase in the treatment of oral submucous fibrosis. *Indian J Med Res.*, 2010; 131: 665-9.
15. Mehrotra R, Singh HP, Gupta SC, Singh M, Jain S. Pentoxifylline therapy in the management of oral submucous fibrosis. *Asian Pac J Cancer Prev.*, 2011; 12: 971-4.
16. Patil S, Maheshwari S. Efficacy of Pentoxifylline in the management of oral submucous fibrosis. *J Oralfac Sci.*, 2014; 6: 94-8.