WJPMR, 2025, 11(12), 317-327

Research Article

Impact Factor: 6.842

WORLD JOURNAL OF PHARMACEUTICAL AND MEDICAL RESEARCH

www.wjpmr.com

ISSN (O): 2455-3301
ISSN (P): 3051-2557
Coden USA: WJPMBB

ASSESSMENT OF REPRODUCTIVE SAFETY AND UTERINE PHARMACOLOGY OF AQUEOUS FRUIT EXTRACT OF *XYLOPIA AETHIOPICA* (XA) IN RATS

Ezenwaeze Malachy Nwaeze*[1], Nwankwo Chibugo Ndidiamaka[2], Nweze Sylvester Onuegbunam[1], Omeke Chidimma Akudo[1], Nwankwo Bartholomew Chinedu [3], Ezenwata Tochukwu Ihuoma[1], Eze Maroline Ebere[1], Nwokike Mathew Onyemaechi[4], Okoro Ngozi Ijeoma[5], Ezinwa Anthony Chijioke[1], Igwe Samuel Agina[1], Leo Clinton Chukwu[6], Ortuanya Kelvin Emeka[7], Nevo Calistus Obiora[7], Ugwuany Samson Ejiofor[1] , Ogbonna Enoch Ejiofor[7], Offordile Ikechukwu Emmanuel[7], Ghasi Samuel Ikenna[8]

[1]Department of Pharmacology and Therapeutics Enugu State University of Science and Technology College of Medicine, Enugu State, Nigeria.
[2]Department of Paediatrics, Alberta Children Hospital Calgary, Canada.
[3]Department of Community Medicine, Enugu State University Teaching Hospital, Enugu, Nigeria.
[4]Department of Pharmacology and Toxicology, University of Rwanda.
[5]Department of Chemical Pathology, Enugu State University of Science and Technology, Enugu, Nigeria.
[6]Department of Pharmacology and Therapeutics, College of Medicine, Chukwuemeka Odumegwu Ojukwu University, Anambra State, Nigeria.
[7]Department of Obstetrics and Gynaecolog , Enugu State University Teaching Hospital, Parklane, Enugu, Nigeria.
[8]Department of Pharmacology and Therapeutics, College of Medicine, University of Nigeria, Enugu, Nigeria.

***Corresponding Author: Ezenwaeze Malachy Nwaeze**

Department of Pharmacology and Therapeutics Enugu State University of Science and Technology College of Medicine, Enugu State, Nigeria. **DOI:** https://doi.org/10.5281/zenodo.17810038

How to cite this Article: Ezenwaeze Malachy Nwaeze*[1], Nwankwo Chibugo Ndidiamaka[2], Nweze Sylvester Onuegbunam[1], Omeke Chidimma Akudo[1], Nwankwo Bartholomew Chinedu [3], Ezenwata Tochukwu Ihuoma[1], Eze Maroline Ebere[1], Nwokike Mathew Onyemaechi[4], Okoro Ngozi Ijeoma[5], Ezinwa Anthony Chijioke[1], Igwe Samuel Agina[1], Leo Clinton Chukwu[6], Ortuanya Kelvin Emeka[7], Nevo Calistus Obiora[7], Ugwuany Samson Ejiofor[1] , Ogbonna Enoch Ejiofor[7], Offordile Ikechukwu Emmanuel[7], Ghasi Samuel Ikenna[8] (2025). Assessment Of Reproductive Safety And Uterine Pharmacology Of Aqueous Fruit Extract Of Xylopia Aethiopica (Xa) In Rats. World Journal of Pharmaceutical and Medical Research, 11(12), 317–327.
This work is licensed under Creative Commons Attribution 4.0 International license.

Article Received on 05/11/2025 **Article Revised on 25/11/2025** **Article Published on 01/12/2025**

ABSTRACT

Background: Xylopia aethiopica is a widely used medicinal plant in West Africa, traditionally employed for the management of reproductive disorders, infections, and metabolic diseases. Despite its ethnomedicinal relevance, scientific evidence on its reproductive safety and uterine pharmacology remains limited. **Objective:** This study evaluated the reproductive safety and uterine pharmacology of Xylopia aethiopica fruit in Wistar rats. **Methodology:** This study, which evaluated the reproductive safety, uterine pharmacology, and systemic effects of aqueous extract of Xylopia aethiopica fruit was carried out in the department of Pharmacology and Therapeutics of Enugu State University of Science and Technology College of Medicine. Fresh fruits of Xylopia aethiopica were purchased, identified, air-dried, powdered, and extracted with water using a Soxhlet apparatus. Acute oral toxicity was assessed in rats at doses of 500–2500 mg/kg, with animals monitored for 48 hours. For the in vivo reproductive study, pregnant Wistar rats were administered undiluted fruit extract ad libitum for 24–96 hours, while pregnancy outcomes were monitored. In vitro uterine contractility was studied using isolated rat uterine horns mounted in organ baths with De Jalon's solution, and responses to the extract were recorded. Data were analyzed using ANOVA, with significance set at $p<0.05$. **Result:** Phytochemical screening revealed abundant tannins, saponins, and alkaloids. In vivo administration to pregnant rats throughout gestation produced no maternal toxicity, abortion, or adverse reproductive outcomes with all treated animals successfully littering comparable to controls. Isolated rat uterus assays demonstrated significant relaxation and inhibition of oxytocin and Ca^{2+} induced contractions, consistent with calcium-antagonistic tocolytic mechanism. Collectively, X. aethiopica fruit extract exhibits tocolytic properties with potential phytotherapeutic application in obstetric care, but safety concerns at higher doses warrant cautious use. **Conclusion:** The aqueous extract of Xylopia aethiopica fruit demonstrated significant pharmacological benefits, including uterine relaxation via calcium antagonism. In vivo administration during gestation revealed no overt maternal or fetal toxicity, supporting its potential reproductive safety at moderate doses.

KEYWORDS: Xylopia aethiopica, uterine pharmacology, reproductive safety.

INTRODUCTION

Xylopia aethiopica (Annonaceae), commonly called negro pepper and known in Igbo as "Uda", in Yoruba as "Eeru", and in Hausa as "Chimba", is a widely utilized West African spice and medicinal plant. Ethnomedically, it has been applied for a broad spectrum of reproductive and perinatal indications, including aiding labour, arresting postpartum hemorrhage, serving as a culinary spice, and importantly for this review, being implicated in fertility regulation and termination of pregnancy in folk practice.[1,2] These longstanding uses provide a cultural and practical rationale for scientific investigation of its potential uterotonic (oxytocic) and abortifacient activity.

a b c d

Figure 1: (a) Fruits of Xylopia aethiopica still attached to the tree (b) leaves of Xylopia aethiopica (c) a cluster of Xylopia aethiopica fruits and (d) dried fruits of Xylopia aethiopica.

Herbal consumption during pregnancy is a growing concern, with many women using herbs for various reasons. Some herbs can induce uterine contractions and high blood pressure, leading to miscarriage, premature birth, or even death. The consumption of herbs during pregnancy is increasingly documented, with many women turning to them for health or cultural reasons. A study on the use of herbal medicine during pregnancy in a group of Bangladeshi women found that 71.80% of pregnant women reported herbal intake, consistent with earlier findings in Bangladesh and in United Kingdom.[3] In Nigeria, the prevalence was 36.8% among pregnant and lactating women, while in Kenya, about 12% of women used herbs throughout pregnancy.[4] Frequently reported herbs include Xylopia aethiopica, ginger, Nigella sativa, Citrus limon, Prunus domestica, and Allium sativum. Other commonly used ones are garlic, peppermint, and Chinese okra. Despite this widespread use, little research exists regarding the reproductive safety and uterine pharmacology of Xylopia aethiopica in pregnancy.

Anatomy and Location of the Uterus

The uterus ("womb") is a hollow, pear-shaped, muscular organ located within the female pelvis, playing a central role in menstruation, conception and childbirth. Its development arises from fusion of the Müllerian (paramesonephric) ducts during embryogenesis. This process gives rise to the fallopian tubes, uterus, and the upper portion of the vagina. In female embryos, the absence of testosterone and Anti-Müllerian Hormone permits normal uterine formation. During pregnancy the uterus undergoes marked enlargement via hyperplasia and hypertrophy of its smooth-muscle (myometrial) component to accommodate and later expel the fetus. It is supported by broad, round and uterosacral ligaments and is situated anterior to the rectum and posterior to the bladder.[5]

Anatomically, the uterus may be divided into the fundus (above the fallopian-tube entrances), the body (corpus), the isthmus and the cervix (including the cervical canal).[5] Histologically, the uterine wall comprises three principal layers: the innermost endometrium (undergoing cyclic changes and decidualization in pregnancy), the thick myometrium (smooth-muscle layer responsible for contraction) and the outer perimetrium (serosal connective tissue).[6]

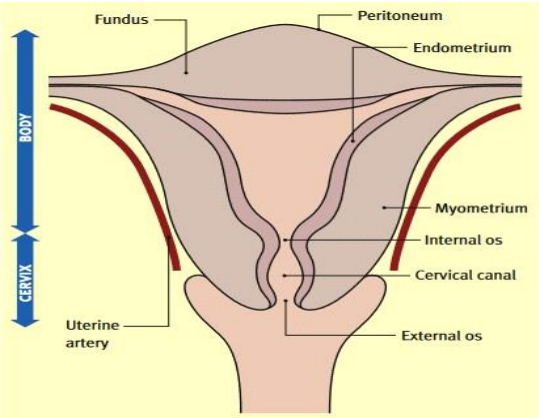

Fig 2: Showing the features of the uterus.[7]

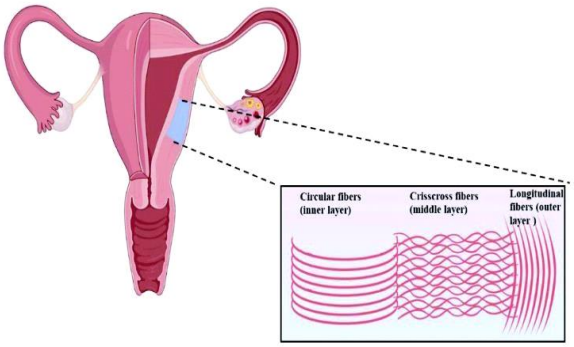

Figure 3: Presenting the features of uterine muscle disposition.[8]

Histology of the uterus

The uterus is composed of three distinct layers: the endometrium, myometrium, and perimetrium. The innermost layer, the endometrium, undergoes cyclical changes during the menstrual cycle to allow for regeneration, decidual transformation, and eventual shedding when implantation does not occur. It provides the environment necessary for embryo attachment and sustains early pregnancy.[9] when there is no conception, the upper two-thirds of the endometrium are shed during menstruation through coordinated actions of hormonal, immune, vascular, and coagulation mechanisms.[10] Structurally, the endometrium consists of connective tissue stroma embedded with glands and covered by a surface epithelium.[11] Estrogen stimulates proliferative growth by enhancing mitotic activity in both glands and stroma, while progesterone dominance reduces estrogen receptor expression, guiding the tissue toward secretory differentiation.

The outermost covering of the uterus, the perimetrium, is a delicate layer made up of loose connective tissue overlain by a squamous mesothelial lining. Between the endometrium and perimetrium lies the myometrium, the thick muscular wall that constitutes the majority of the uterine mass. Its inner and outer zones largely originate from the early paramesonephric ducts.[12]

The uterine system is composed of several layers, including the intermediate part, which adds to the thickness of the uterus and provides large blood vessels for the purpose of suppling nutrients. The myometrium, a smooth muscle, expands and contracts to facilitate parturition.[13]

Justification of the study

The widespread use of Xylopia aethiopica (XA) in West African traditional medicine, particularly in the management of pregnancy-related conditions, underscores the need for systematic evaluation of its reproductive safety and uterine pharmacology. In ethnomedicine, XA fruits are employed for diverse purposes ranging from induction of labour and control of postpartum hemorrhage to fertility regulation and, in some instances, termination of pregnancy. Despite these long-standing uses, the scientific evidence regarding its actual effects on uterine physiology and pregnancy outcomes remains contradictory. While some studies report oxytocic and abortifacient properties, others demonstrate uterine relaxant and tocolytic effects, raising critical questions about its true pharmacological profile.

Given the high prevalence of herbal medicine use during pregnancy in sub-Saharan Africa, often without medical supervision, the potential risks of XA consumption cannot be overlooked. Pregnant women and their unborn babies/fetuses represent a highly vulnerable group; thus, exposure to unverified herbal remedies may lead to adverse reproductive outcomes, fetal loss, or organ toxicity. Conversely, if XA indeed exhibits uterine relaxant activity, it may hold therapeutic potential in obstetric practice as a natural spasmolytic or tocolytic agent. Moreover, the variation in extract preparation methods, dosage regimens, and experimental designs across previous studies has contributed to conflicting results. Most published reports lack standardized methodologies, mechanistic insight, or comprehensive toxicity evaluations, making extrapolation to human use highly uncertain. Therefore, a well-controlled study assessing both in vivo reproductive outcomes in pregnant rats and in vitro uterine contractility using isolated uterine tissue is critically important.

Ultimately, this study will clarify the reproductive safety profile of aqueous XA fruits in pregnancy, determine whether XA acts as an oxytocic/abortifacient or a uterine relaxant, thereby resolving ethnomedicinal controversies surrounding the plant usage, generate mechanistic insights into its uterine pharmacology, particularly regarding calcium and oxytocin pathways, provide safety data on systemic effects (hematological, biochemical, histological) relevant to long-term or high-dose use and contribute to public health policy by informing safe herbal medicine use during pregnancy and guiding potential therapeutic applications in obstetrics.

Therefore, embarking on this study is not only scientifically necessary but also of significant clinically, pharmacologically, and of public health relevance in ensuring safe motherhood and evidence-based integration of traditional medicine into modern healthcare.[9]

METHODOLOGY

Plant Material Collection and Extraction Process

This study was carried out in the department of Pharmacology and Therapeutics of Enugu State University of Science and Technology College of Medicine. Mature, fresh fruits of Xylopia ethiopica were obtained from Eke–Akiyi market in Uzo-Uwani LGA, Enugu State. Identification was carried out by a botanist from the Department of Agriculture, Enugu State University of Science and Technology. The fruits were washed under running tap water to eliminate surface contaminants, air-dried at ambient laboratory temperature for 14 days, and then pulverized into fine powder with an electronic blender (Moulinex). Extraction was performed using a Soxhlet apparatus with water as solvent, following the procedure of Airaodion et al.[14] Approximately 25 g of powdered sample was placed in the Soxhlet thimble, while 250 mL of water was added to a round-bottom flask fixed to the Soxhlet extractor and condenser on an electric heating mantle (Isomantle) set at 60°C. The solvent vaporized, condensed, and dripped onto the sample. Once the chamber filled, the siphon returned the solvent to the boiling flask, initiating a continuous cycle. This extraction was run intermittently for a cumulative period of 18 hours, ensuring that power supply interruptions and overnight runs were avoided. The resulting extract was

collected in a 1000 mL beaker and concentrated to dryness using a water bath (A3672-Graffin Student Water Bath) at 35°C. The weight of the residue and concentrated extract was measured, and the dried extract stored at 4°C until further analysis.

Oral Acute Toxicity Studies

The acute oral toxicity study followed the method of Cherr Lake[15] Thirty rats were randomly allocated into six groups (n=5). Group A received distilled water (10 mL/kg), while Groups B–F were administered 500, 1000, 1500, 2000, and 2500 mg/kg of the extract, respectively, by gastric intubation. The animals were monitored for 24 hours for behavioral and physical signs of toxicity (hyperactivity, salivation, paw-licking, writhing, muscle weakness, or respiratory distress), and for an additional 48 hours for possible mortality.

Experimental Design and Animal Treatment

Thirty male and thirty female Wistar rats (170–200 g) were procured from the Central Animal House, Enugu State University College of Medicine. The animals were acclimatized for one week under standard housing conditions (well-ventilated cages, free access to feed and water). Care and handling complied with the Guide for the Care and Use of Laboratory Animals (National Academy of Science/National Institute of Health). After acclimatization, body weights were recorded. Estrus synchronization in females was induced using diethylstilbestrol (1 mg/kg, dissolved in paraffin oil). Mating was achieved by housing one male with each female. On day 7, vaginal smears were collected with saline-moistened cotton swabs, smeared on glass slides, stained with Giemsa, and examined microscopically for protein coagulates to confirm pregnancy. Confirmed pregnant rats were divided into five groups (n=6).

- Group A (Control): Normal saline ad libitum
- Group B: Undiluted X. aethiopica extract ad libitum for 24 h
- Group C: Undiluted X. aethiopica extract ad libitum for 48 h
- Group D: Undiluted X. aethiopica extract ad libitum for 72 h
- Group E: Undiluted X. aethiopica extract ad libitum for 96 h

Animals were observed until delivery. Any confirmed pregnant rat that failed to litter was regarded as having miscarried.

In vitro Effect of X. aethiopica Extract on Isolated Rat Uterus

The technique of Airaodion et al. [14] was adopted. Mature pregnant rats were sacrificed by stunning and decapitation. The abdominal cavity was opened, and the uterine horns excised and transferred into De Jalon solution, continuously aerated and maintained at 37°C, pH 7.4. The solution per liter contained: NaCl (9 g), KCl (0.42 g), $CaCl_2$ (0.06 g), $NaHCO_3$ (0.5 g), and glucose (0.5 g). Each uterine horn was mounted vertically in a 35 mL organ bath with one end tied to a tissue holder and the other to an isometric force-displacement transducer linked to a digital recorder (Medicaid Physiopac). Resting tension was adjusted, and tissues allowed to equilibrate for 30 minutes. After establishing spontaneous rhythmic contractions, dose-response curves were obtained for X. aethiopica extract and reference drugs. Each administration was followed by at least 1 min observation, then tissues were rinsed thrice with De Jalon solution. Test substances were applied at final bath concentration (FBC).

Percentage (%) Rise in Amplitude of Contraction

$A_{test} - A_{baseline} / A_{baseline} \times 100\%$

Phytochemical Screening of X. aethiopica

Preliminary phytochemical tests were carried out on the ethanol extract to identify secondary metabolites: Tannins: 0.5 g extract dissolved in 1 mL water, filtered, and treated with ferric chloride. Blue-black, green, or blue-green precipitate confirmed tannins.[16] Alkaloids: 0.5 g extract refluxed in 1% HCl, filtered, and tested with Mayer's, Dragendorff's, and picric acid reagents. Precipitation indicated alkaloids.[6] Saponins: 0.5 g extract shaken vigorously in water. Persistent frothing upon heating indicated saponins.[16] Steroids: 0.5 g extract filtered, 1 mL added to 2 mL H_2SO_4. A reddish-brown ring at the interface indicated steroids.[16] Terpenoids: 5 mL extract mixed with chloroform, evaporated, and boiled with 3 mL concentrated H_2SO_4. Grey coloration indicated terpenoids. Flavonoids: 100 mg extract dissolved in 5 mL water, filtered, and treated with lead subacetate. Yellow precipitate indicated flavonoids. Anthraquinones: Extract macerated in benzene, filtered, then treated with 10% ammonia. Pink, violet, or red coloration confirmed anthraquinones.[17]

Statistical Analysis

Data were analyzed using GraphPad Prism. Results were expressed as Mean ± SD. One-way ANOVA with Tukey's post-hoc test was used to compare means. Significance was set at $p < 0.05$.

RESULT

The result of assessment of reproductive safety and uterine pharmacology of aqueous extract of xylopia aethiopica (XA) fruit in albino wistar rat, in addition to acute oral toxicity and phytochemical analysis of Xlopia aethiopica are documented below. Table 1 on acute toxiciotry study shows that no mortality was observed up to 2000 mg/kg, while 60% mortality occurred at 2500 mg/kg. Using the linear interpolation method, the median lethal dose (LD_{50}) was estimated to be 2417 mg/kg body weight. Figure 4 on phytochemical screening of the aqueous fruit extract of Xylopia aethiopica revealed the presence of several bioactive constituents in varying proportions.

Table 1: Shows result of acute oral toxicity study.

Group	Dose (mg/kg)	Deaths	% Mortality
A	0 (control)	0	0%
B	500	0	0%
C	1000	0	0%
D	1500	0	0%
E	2000	0	0%
F	2500	3	60%

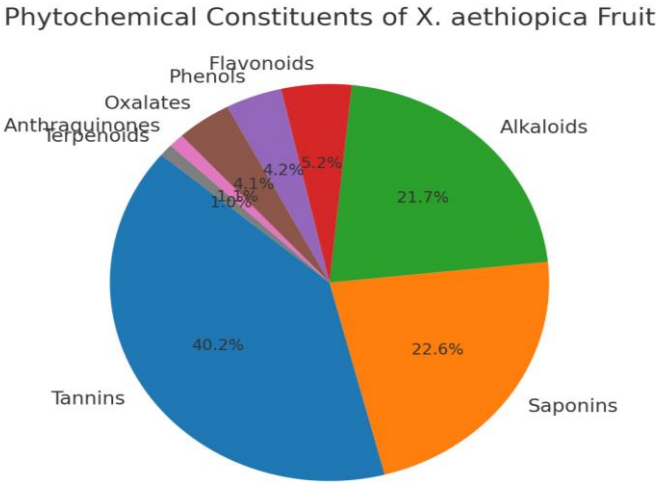

Figure 4: Showing outcome of the phytochemical screening of the aqueous fruit extract of X. aethiopica fruit.

Result of in vitro effect of aqueous fruit extract of X. aethiopica on Isolated Rat Uterine

The response of the rat uterus to standard drug, oxytocin was concentration-dependent. At lower doses 0.2ml (0.02iu) and 0.4ml (0.04iu), the tissue showed minimal contraction, whereas a higher dose 0.8ml (0.08 IU) elicited a marked and significant contractile response (fig.5a). The aqueous extract of Xylopia aethiopica elicited a concentration-dependent relaxation of the isolated rat uterus. As the volume of the extract was increased from 0.4 ml (200ug) to 0.8 ml (400ug), a progressive reduction in uterine contractile response was observed, with the maximum relaxation occurring around 0.8 ml (400ug) as seen in figure 5b. On comparing the standard drug, oxytocin, with the extract, it was noted that oxytocin initially produced a marked uterine contraction. However, following incubation with an equal volume (0.8 ml) of the extract, the uterus exhibited a relaxation response with only slight contractions being noticed, the amplitude of which was markedly reduced compared to the pre-incubation oxytocin-induced contractions. Upon washout and introduction of 0.8ml (0.08 IU) of oxytocin, oxytocin again elicited a strong contractile response. Conversely, when the oxytocin was washed and subsequently re-exposed to the extract, uterine relaxation was once more observed as seen in figure 5c. In further comparison, both calcium chloride and oxytocin produced pronounced uterine contractions; however, subsequent administration of the aqueous extract attenuated these responses and instead induced a distinct relaxation effect, as shown in Figure 5d.

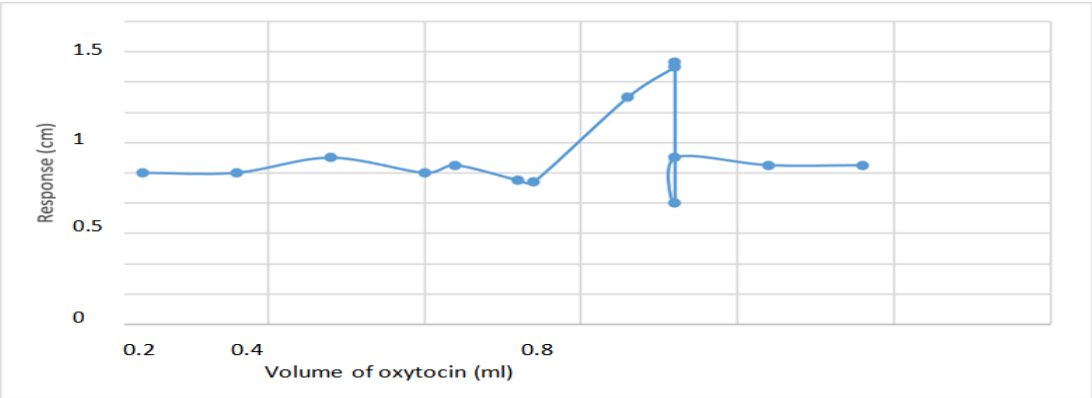

Figure 5a: Response of the rat uterus to the standard drug, oxytocin.

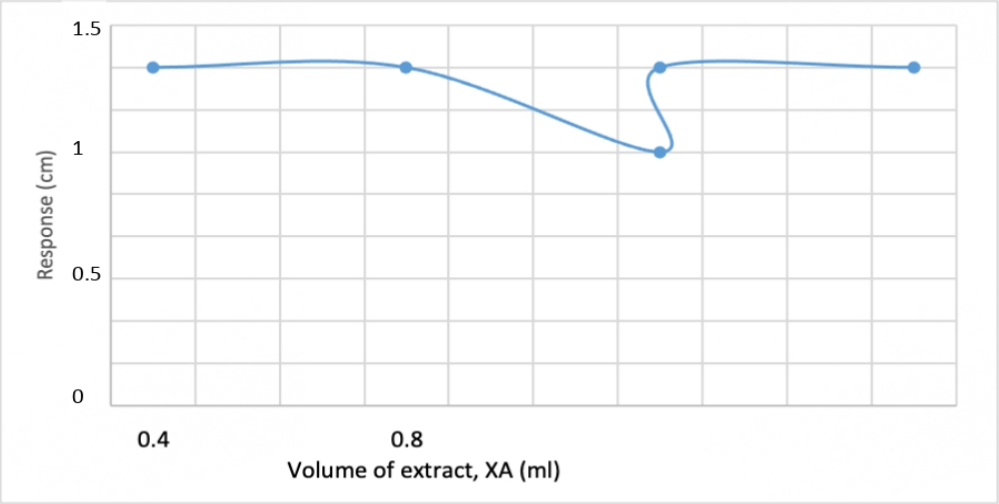

Figure 5b: Response of the rat uterus to the aqueous extract of X. aethiopica.

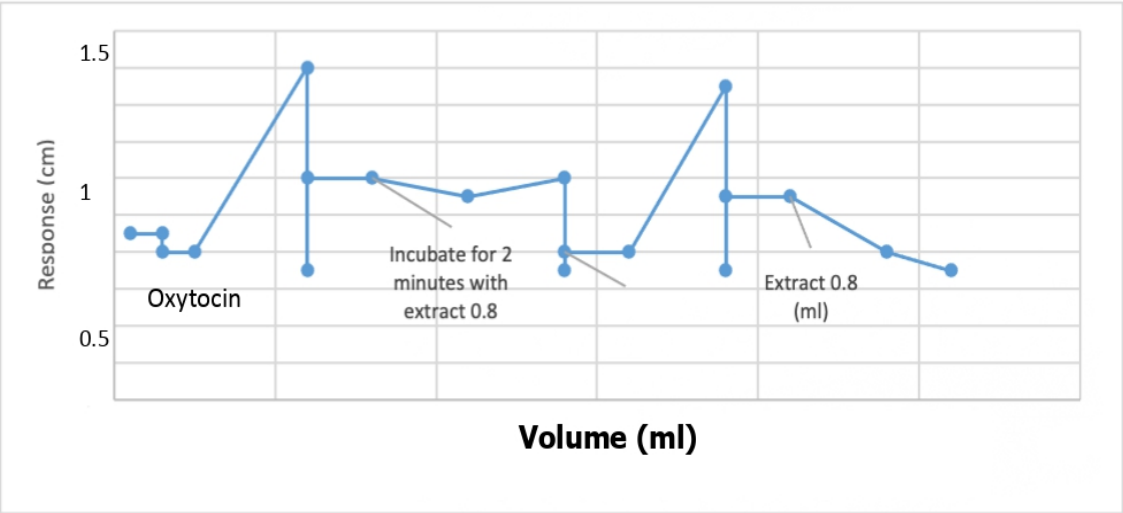

Figure 5c: Response of the rat uterus to oxytocin and aqueous extract of X. aethiopica.

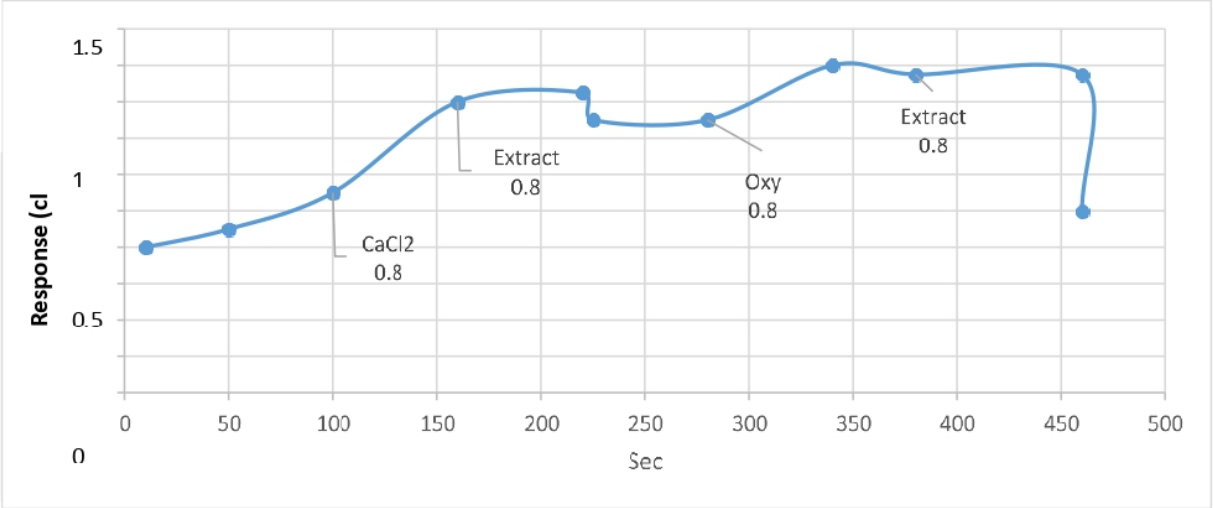

Figure 5d: Actions of oxytocin, Cacl2 and extract of X. aethiopica on the rat uterine.

Assessment of Xylopia Aethiopica Effect on Pregnancy

Potential effects of undiluted Xylopia aethiopica fruit juice on pregnancy outcome in rats, with particular attention to the risk of abortion or pregnancy loss was investigate after confirmation of pregnancy with presence of protein coagulate as seen in plate 1. Table 2 and figure 6 showed that following confirmation of pregnancy and monitoring for signs of abortion or pregnancy loss, that all pregnant rats in both the control group (normal saline) and the treatment groups exposed to undiluted Xylopia aethiopica fruit juice delivered viable litters. All pregnant rats in both control and treatment groups delivered within the normal gestational period of 21–23 days. There was no evidence of delayed parturition, premature delivery, or abortion in any of the groups as shown in table 3.

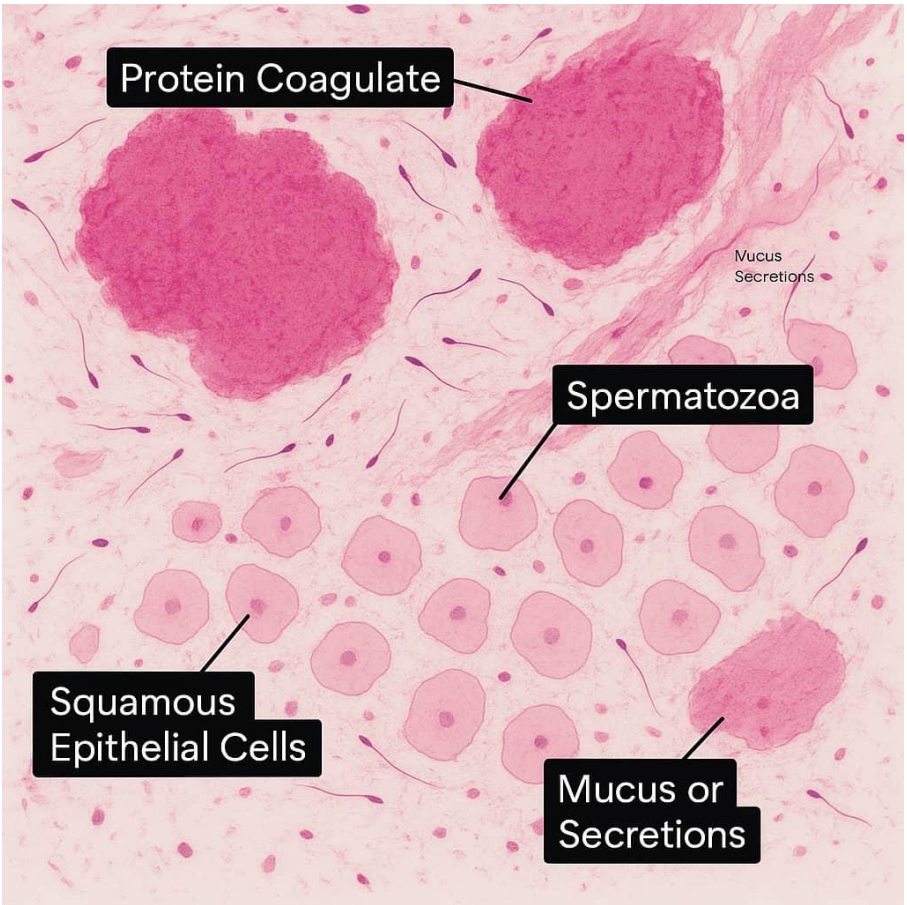

Plate 1: Protein coagulates observed on slides on which vaginal smears of mated rats were made which indicates positive pregnancy test.

Table 2: shows that all the pregnant rats treated with X. aethiopica successfully littered at the end of pregnancy.

Treatment Groups	Pregnancy Test	Type of treatment	Number that Littered	Percentage (%) that littered
A	Positive	Normal Saline	5	100
B	Positive	Undiluted X. aethiop fruit juice ad libitum for 24 hours	5	100
C	Positive	Undiluted X. aethiop fruit juice ad libitum for 48 hours	5	100
D E Positive	Positive	Undiluted X. aethiop fruit juice ad libitum for 72 hours Undiluted X. aethiop fruit juice ad libitum for 96 hours	5 100	100

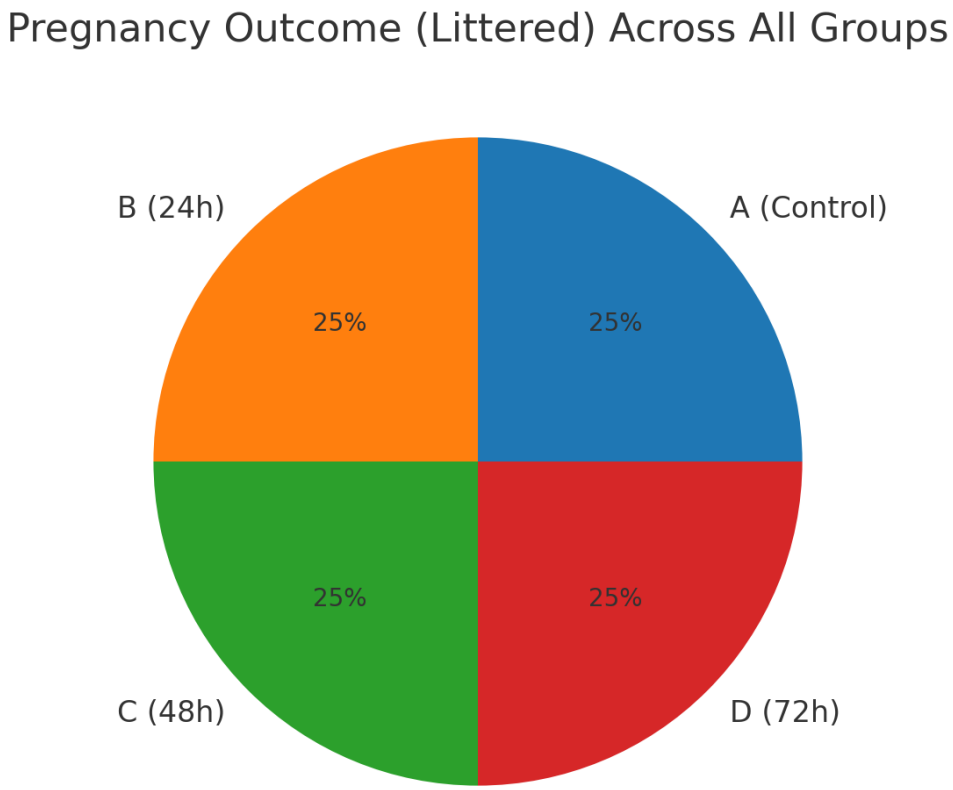

Figure 6: Pie chat representation of outcome of in vivo activity of xylopia aethiopica on a pregnant rats' uteri.

All pregnant rats in both control and treatment groups delivered within the normal gestational period of 21–23 days.

Table 3: Effect of Xylopia aethiopica fruit juice on gestational duration in pregnant rats.

Treatment Groups	Type of treatment	Number of pregnant rats	Normal time of delivery (21–23 days)	Percentage (%) delivered at normal gestation	Abortion/Delay observed
A (Control)	Normal Saline	5	5	100	None
B	Undiluted X. aethiopica fruit juice ad libitum (24 h)	5	5	100	None
C	Undiluted X. aethiopica fruit juice ad libitum (48 h)	5	5	100	None
E	Undiluted X. aethiopica fruit juice ad libitum (72 h) Undiluted X. aethiopica fruit juice ad libitum (96 h)	5	5 5	100 100	None None

DISCUSSION

In vivo study revealed that administration of aqueous extract of Xylopia aethiopica to pregnant rats throughout gestation did not induce any observable maternal toxicity, abortion, or adverse reproductive outcome. All treated rats appeared physically fit, and littering occurred successfully in all groups without differences compared to the control. These findings suggest that X. aethiopica extract does not exert overt teratogenic or abortifacient effects in rats at the doses tested.

This result is consistent with earlier studies reporting relative reproductive safety of X. aethiopica. Previous study observed that ethanolic extract of X. aethiopica administered to pregnant rats did not significantly alter gestation length or number of live births, although high doses showed mild reductions in pup body weight,[18] similarly, another report had it that aqueous fruit extract of X. aethiopica had no teratogenic effect and did not interfere with implantation or fetal viability.[19]

Contrary to these findings, other studies have raised concerns about possible reproductive toxicity at higher doses or with prolonged use. A study on the effects of graded doses of Xylopia aethiopica on pregnancy outcome in rats reported that high doses of X. aethiopica caused slight fetal growth retardation,[20] while another on the effect of Xylopia aethiopica fruit extract on reproductive hormones in pregnant Wistar rats showed mild alterations in reproductive hormones when extract was administered during pregnancy.[21] This suggests that

while moderate doses may be safe, higher concentrations could pose subtle risks to fetal development.

Ethnobotanical reports also highlight the use of X. aethiopica fruits by traditional healers to ease labor and improve post-partum recovery.[22, 23] The lack of adverse pregnancy outcomes in this study supports its traditional application, though caution is warranted considering that variations in extraction method, dosage, and duration of exposure may influence outcomes.

Overall, the findings from this study align with the majority of reports indicating that X. aethiopica is relatively safe in pregnancy at moderate doses, with no observable abortifacient or teratogenic effects.

In the isolated rat uterus study, the aqueous fruit extract of Xylopia aethiopica (XA) produced a clear uterine relaxation rather than the anticipated contraction. As a check on tissue viability and signaling, both oxytocin and $CaCl_2$ elicited the expected dose-dependent contractions, but pre-incubation with the XA extract significantly attenuated the amplitude of these responses. This pattern (basal relaxation + inhibition of oxytocin- and Ca^{2+}-evoked contractions) is most consistent with a calcium-antagonistic/tocolytic pharmacologic profile at uterine smooth muscle. The above findings align with several earlier studies on postpartum rat uteri which revealed that ethanol fruit extracts of X. aethiopica do not possess oxytocic activity, instead, they caused dose-dependent relaxation of the uterus supporting present results.[24, 25] Aqueous and ethanol extracts of X. aethiopica have been shown to relax isolated rabbit ileum and guinea-pig smooth muscle, suggesting a generalized spasmolytic property mediated via calcium channel inhibition.[26,27] Similar uterine relaxant effects have been reported for Corchorus olitorius extract on isolated uterine strips, suggesting a broader phytotherapeutic motif among traditional plants used in obstetrics.[28]

Uterine contraction requires intracellular calcium influx through voltage-dependent L-type Ca^{2+} channels and oxytocin receptor-mediated pathways (via PLC–IP_3). XA extract inhibited contractions induced by both oxytocin and $CaCl_2$, suggesting it interferes with Ca^{2+} mobilization or influx. This could account for its mechanical interpretation. Phytochemical reports show that X. aethiopica contains flavonoids, alkaloids, saponins, terpenoids, and steroids many of which are associated with Ca^{2+} antagonism, PDE inhibition, or niric oxide mediated relaxation.[29,30]

Thus, it can be concluded that Xylopia aqueous extract exerts calcium channel blocking effects (and possibly opens K^+ channels or enhances cAMP/cGMP pathways), resulting in reduced uterine tone and inhibition of both receptor-mediated and direct Ca^{2+}-driven contractions.

This observation can be exploited in obstetrics when there is need for tocolysis. The spasmolytic effect also suggests possible use as a tocolytic in dysmenorrhea or preterm contractions and in prevention of postpartum hemorrhage which is consistent with earlier reports since the extract clearly lacks oxytocic activity and instead relaxes uterine muscle.

The aqueous extract of Xylopia aethiopica (XA) fruits in this study contained diverse secondary metabolites, with tannins (3.96%) as the most abundant, followed by saponins (2.23%) and alkaloids (2.14%). Lower levels were observed for flavonoids (0.51%), phenols (0.41%), oxalates (0.40%), anthraquinones (0.11%), and terpenoids (0.10%). This pattern is consistent with previous reports that identified tannins, saponins, alkaloids, flavonoids, terpenoids, phenols, and anthraquinones as major constituents of XA fruit extracts.[31, 15]

Quantitatively, the rank order observed in this work (tannins > saponins > alkaloids >> others) partly agrees with earlier studies. For example, a study on Comparative Biochemical Evaluation of the Proximate, Mineral, and Phytochemical constituents of Xylopia aethiopica Whole Fruit, Seed, and Pericarp reported higher levels of tannins (16.46 mg/g), saponins (4.65 mg/g), alkaloids (6.81 mg/g), oxalates (3.16 mg/g), anthraquinones (4.72 mg/g), and terpenes (3.72 mg/g) in whole fruits, compared to seeds and pericarps.[32] While absolute values differ, likely due to differences in units (% of extract in this study vs. mg/g dry plant in theirs), the relative dominance of tannins and saponins is consistent.

Differences across studies can also be attributed to solvent type and extraction conditions.[15] compared aqueous and acetone extracts and found that both contained tannins, alkaloids, flavonoids, and steroids, but the aqueous extract exhibited stronger antioxidant activity, supporting the efficiency of water as a solvent for polyphenols. The relatively low terpenoid yield in our aqueous extract (0.10%) is consistent with the poor solubility of many terpenoids in water.

Our oxalate content (0.40%) also aligns with previously published values; a study on Comparative Biochemical Evaluation of the Proximate, Mineral, and Phytochemical Constituents of Xylopia aethiopica Whole Fruit, Seed, and Pericarp reported oxalates at about 3.16 mg/g (~0.316% w/w), confirming its presence in small but relevant amounts.[32] Similarly, it was also reported that saponins, flavonoids, tannins, alkaloids, and phenols in XA fruits, further validating the reproducibility of these findings.[33]

Reviews on X. aethiopica consistently emphasize that variations in quantitative levels reflect plant part used, geographical origin, harvest season, and analytical techniques.[34] However, across studies, tannins, saponins, alkaloids, flavonoids, and phenolics remain dominant constituents, underscoring their central role in

the pharmacological activities (antioxidant, antimicrobial, anti-inflammatory) widely attributed to this plant.

In summary, our results corroborate the general phytochemical profile of X. aethiopica fruits described in the literature, with high tannin, saponin, and alkaloid contents as defining features of its aqueous extract.

CONCLUSION AND RECOMMENDATION

The aqueous fruit extract of Xylopia aethiopica demonstrated significant pharmacological benefits, including uterine relaxation via calcium antagonism which can be exploited in tocolysis. In vivo administration during gestation revealed no overt maternal or fetal toxicity, supporting its potential reproductive safety at moderate doses. However, considering the potential for dose-dependent effects, further studies on reproductive hormones, fetal development, and long-term offspring outcomes are recommended.

ACKNOWLEDGMENT

We are deeply appreciative of everyone whose consistent support and encouragement played a crucial role in completing this study.

Disclosure of conflict of interest

The authors declare no conflict of interests.

Ethical approval

Approval of the ethics committee was obtained.

External funding

None.

REFERENCES

1. Burkill HM. The Useful Plants of West Tropical Africa, Vol. 1. Royal Botanic Gardens, Kew; 1985.
2. Igwe CU et al. Traditional uses of Xylopia aethiopica (Annonaceae) in pregnancy and postpartum care. J Med Plants Res, 2010; 4(9): 753-758.
3. Jahan S, Mozumder ZM, Shill DK. Use of herbal medicines during pregnancy in a group of Bangladeshi women. Heliyon. 2022; 8(1): e08854. DOI: https://doi.org/10.1016/j.heliyon.2022. e08854
4. Adeoye I, Etuk V. Prevalence, predictors and pregnancy outcomes of unprescribed and herbal medicine use in Ibadan, Nigeria. BMC Complementary Medicine and Therapies, 2023; 23(1): 17. DOI: 10.1186/s12906-023-03838-8
5. Clark KM, Pandya AM. Anatomy, Abdomen and Pelvis: Cardinal Ligaments (Mackenrodts, Transverse Cervical, or Lateral Cervical Ligaments). StatPearls. StatPearls Publishing Copyright © 2024, Stat Pearls Publishing LLC.; 2024.
6. Ramanah R, Berger MB, Parratte BM, DeLancey JO. Anatomy and histology of apical support: A literature review concerning cardinal and uterosacral ligaments. International Urogynecology Journal, 2012; 23(11): 1483-94.
7. Ellis H. Anatomy of the uterus. Anaesthesia & Intensive Care Medicine, 2005; 6(3): 74-75.
8. Hanuman S, Pande G, Nune M. Current Status and Challenges in Uterine Myometrial Tissue Engineering, 2023; 14(1): 2251847.
9. Philip M, Snow RJ, Gatta PAD, Bellofiore N, Ellery SJ. Creatine metabolism in the uterus: Potential implications for reproductive biology. Amino Acids, 2020; 52(9): 1275-1283.
10. Han C, Wang C, Han L, et al. Incarceration of the gravid uterus: A case report and literature review. BMC Pregnancy and Childbirth, 2019; 19(1): 408.
11. Edwards JK, Solsona B, N EN, et al. Switching off hydrogen peroxide hydrogenation in the direct synthesis process. Science, 2009; 323(5917): 1037-41.
12. Hanuman S, Pande G, Nune M. Current Status and Challenges in Uterine Myometrial Tissue Engineering, 2023; 14(1): 2251847.
13. Taylor AH, Habiba M. The Myometrium in Heath and Disease. In: Habiba M, Benagiano G, eds. Uterine Adenomyosis. Springer International Publishing, 2016; 71-79.
14. John-Dewole, O., et al. (2012). Phytochemical and antimicrobial studies of extract of the fruit of Xylopia aethiopica. J. Med. Plants Res.
15. Erickson EN, Emeis CL. Breastfeeding Outcomes After Oxytocin Use During Childbirth: An Integrative Review. J Midwifery Women's Health, 2017; 62: 397–417. doi: 10.1111/jmwh.12601
16. Omotayo, O. F., et al. (2012). Effect of methanolic extract of Xylopia aethiopica fruits on cytoprotection in cold stress-induced gastric ulcer in albino Wistar rats. Research Journal of Pharmaceutical, Biological and Chemical Sciences, 3(1): 874–881.
17. Landgraf R, Neumann ID. Vasopressin and Oxytocin Release Within the Brain: A Dynamic Concept of Multiple and Variable Modes of Neuropeptide Communication. Front Neuroendocrinol, 2004; 25: 150–76. doi: 10.1016/j.yfrne.2004.05.001
18. Okwuosa, C. N., Nwodo, F. O. C., & Onoh, F. (2014). Evaluation of the teratogenic potential of Xylopia aethiopica fruit extract in Wistar rats. Journal of Ethnopharmacology, 151(2): 747–752.
19. Ekechukwu, N. E., Akah, P. A., & Okoli, C. O. (2011). Effects of graded doses of Xylopia aethiopica on pregnancy outcome in rats. African Journal of Reproductive Health, 15(3): 123–130.
20. Ajibade, T. O., Fakunle, P. B., & Adebayo, A. H. (2013). Effect of Xylopia aethiopica fruit extract on reproductive hormones in pregnant Wistar rats. African Journal of Biotechnology, 12(20): 3040–3046.
21. Akinmoladun, F. O., Komolafe, T. R., & Farombi, E. O. (2010). Ethnopharmacological importance of Xylopia aethiopica in pregnancy and childbirth.

Journal of Medicinal Plants Research, 4(17): 1746–1751.
22. Burkill, H. M. (1997). The Useful Plants of West Tropical Africa (2nd ed.). Royal Botanic Gardens, Kew.
23. Uguru, M. O., Okoye, T. C., Akah, P. A., Nworu, C. S., & Udegbunam, S. O. (2019). Evaluation of the oxytocic and safety profile of ethanol fruit extract of Xylopia aethiopica on postpartum rat uterus. Journal of Ethnopharmacology, 236: 23–31. https: //doi.org/10.1016/j.jep.2019.02.009
24. Eze, C. O., Onyeyili, P. A., & Anaga, A. O. (2020). The oxytocic and abortifacient activities of Xylopia aethiopica ethanol fruit extract on isolated rat uterus. Journal of Medicinal Plants Research, 14(7): 319–326. https: //doi.org/10.5897/JMPR2019.6901
25. Iwu, M. M. (1993). Handbook of African Medicinal Plants. Boca Raton: CRC Press. (pp. 245–247).
26. Woode, E., Ameyaw, E. O., & Boakye-Gyasi, E. (2011). Spasmolytic effect of an aqueous fruit extract of Xylopia aethiopica on guinea pig ileum. Journal of Pharmacology and Toxicology, 6(2): 142–151.
27. Mansour, S. E., Ramadan, M. A., & El-Kholy, W. M. (2019). Uterine relaxant and antioxidant effects of Corchorus olitorius leaf extract in rats. BMC Complementary and Alternative Medicine, 19(1): 85. https: //doi.org/10.1186/s12906-019-2497-4
28. Ajaiyeoba, E. O., & Ekundayo, O. (1999). Essential oil constituents of Xylopia aethiopica fruits. Planta Medica, 65(6): 571–572. https: //doi.org/10.1055/s-2006-960845
29. Adaramoye, O. A., Aluko, A., & Farombi, E. O. (2009). Mechanisms of the vasorelaxant effect of Xylopia aethiopica extract in rat aorta. Journal of Smooth Muscle Research, 45(3): 133–145. https: //doi.org/10.1540/jsmr.45.133
30. Ullah S, Ahmad S, Guo X, Ullah S, Ullah S, Nabi G and Wanghe K (2023) A review of the endocrine disrupting effects of micro and nano plastic and their associated chemicals in mammals. Front. Endocrinol. 13: 1084236. doi: 10.3389/fendo.2022.1084236
31. Ngwoke, K.G., et al. (2015). Phytochemical and antioxidant properties of extracts of Xylopia aethiopica fruits. Chem. Sci. Rev. Lett., 4(13): 267–270.
32. Adewuyi, A., et al. (2022). Evaluation of mineral composition, phytochemical and proximate constituents of Xylopia aethiopica, Piper guineense and Rhaphiostylis beninensis. Heliyon, 8(11): e11477.
33. Morakinyo, A.O., et al. (2025). Phytochemical and Pharmacological Evaluation of Xylopia aethiopica: A Systematic Review (2000–2024). Adeleke Univ. J. Sci.
34. Ogu, A. O., Ezeokonkwo, C. A., & Nwodo, F. O. C. (2012). Reproductive and teratogenic effects of Xylopia aethiopica fruit extract in pregnant albino rats. Nigerian Journal of Physiological Sciences, 27(2): 179–185.