WJPMR, 2025, 11(11), 118-126

Review Article

WORLD JOURNAL OF PHARMACEUTICAL AND MEDICAL RESEARCH

www.wjpmr.com

Impact Factor: 6.842

ISSN (O): 2455-3301

ISSN (P): 3051-2557

Coden USA: WJPMBB

A STREAMLINED SPECIFICATION OF WARTS (MASSA), A SKIN DISORDER, ENCOMPASSING ITS PREDECESSORS, CURRENT STATE, METHOD OF DIAGNOSIS, AND STAGES OF MEDICAL TREATMENT

Yash Srivastav[1*], Nutan Shrivastava[2], Madhaw Kumar[3], Nikita Sharma[4], Mohammad Aqil Siddiqui[5], Jyotsana Shrivastava[6]

[1] Assistant Professor, Shri Venkateshwara University, Gajraula, Uttar Pradesh, India.
[2]City Women's College, Jankipuram, Lucknow, Uttar Pradesh, India.
[3]Goel Institute of Pharmacy & Sciences, Lucknow, Uttar Pradesh, India.
[4]Signa College of Pharmacy, Kanpur, Uttar Pradesh, India.
[5]Lucknow College of Pharmacy, Lucknow, Uttar Pradesh, India.
[6]Dr. Rammanohar Lohia Avadh University, Uttar Pradesh, India.

***Corresponding Author: Yash Srivastav**
Assistant Professor, Shri Venkateshwara University, Gajraula, Uttar Pradesh, India.
DOI: https://doi.org/10.5281/zenodo.17483378

How to cite this Article: Yash Srivastav1*, Nutan Shrivastava2, Madhaw Kumar3, Nikita Sharma4, Mohammad Aqil Siddiqui5, Jyotsana Shrivastava6 (2025). A Streamlined Specification Of Warts (Massa), A Skin Disorder, Encompassing Its Predecessors, Current State, Method OF Diagnosis, And Stages Of Medical Treatment. World Journal of Pharmaceutical and Medical Research, 11(11), 118–126.
This work is licensed under Creative Commons Attribution 4.0 International license.

Article Received on 03/10/2025 **Article Revised on 23/10/2025** **Article Published on 01/11/2025**

ABSTRACT
The word "warts" refers to all morphological types of warts and can also be used to refer to lesions that resemble warts but are not brought on by HPV infection, such as seborrheic keratoses or seborrheic "warts." Only HPV-related warts are covered by the term "warts" in this guideline. Giuseppe Ciuffo, a physician, was the first to show that warts are caused by a viral infection in 1907. Harald zur Hausen, a virologist, was the first to identify the human papillomavirus (HPV) as the cause of warts in 1976. His ongoing studies produced the data required to create an HPV vaccination, which was initially made accessible in 2006. Based on their anatomy or morphology, HPV-associated warts are classified as (i) common warts (Verruca vulgaris), (ii) plantar warts (Verruca plantaris), (iii) flat or plane warts (Verruca plana), and (iv) vaginal warts (Condyloma accuminatum). Human papillomavirus (HPV) infections of keratinocytes, the main cell type in the epidermis, result in warts. A noticeable wart develops weeks or even months after infection at the basal layer and clonal growth, which is followed by the formation of epidermal thickening and hyperkeratinization. There are more than 150 distinct genotypic forms of HPV, which are categorised according to specific viral DNA variations. Most frequent warts are caused by HPV types 1, 2, 4, 27, or 57, while HPV types 3 or 10 generate plane warts. In addition to being found on the skin, the HPV types that were first discovered in epidermodysplasia verruciformis (EV) and their closely related genotypes can also cause premalignant dysplasias and squamous cell carcinoma, particularly when immunosuppression is present. Warts are common among people all over the world. Approximately 7–12% of the population is thought to be affected by warts, while the exact prevalence is unknown. The incidence in school-age children is between 10 and 20 per cent. Meat handlers and immunocompromised patients also exhibit a higher incidence. It covers the pathophysiology, aetiology, diagnosis, treatment, and hazards associated with warts.

KEYWORDS: Warts, Epidemiology, Aetiology, Treatments.

INTRODUCTION
Warts are most commonly caused by human papillomavirus (HPV) infection, which can be acquired through direct contact with an infected individual or environmental exposure. Based on their appearance or location, they can be divided into common warts, plantar warts, and genital warts, for instance. Numerous destructive and immunotherapeutic techniques, both invasive and non-invasive, have been used to treat common warts. Among the damaging therapies are laser ablation, electrocautery, cryosurgery, and surgical excision.[1] Salicylic acid, trichloroacetic acid, formaldehyde, and 5-fluorouracil are examples of medical substances that can cause harm. It is estimated that 40% of people worldwide carry HPV in their bodies. Approximately 14% of the general population is affected

by plantar warts each year. Young people are more susceptible to getting plantar warts for several reasons, the most prevalent being immunodeficiency or excessive use of public bathrooms and/or showers. This illness should be addressed since it can have a significant impact on a patient's quality of life by producing disillusionment due to chronicity or relapse, as well as feelings of guilt, dread, and anxiety about other people's negative attitudes. The success of various treatment techniques for cutaneous warts varies, and recurrence is frequently the outcome. Additionally, therapies might cause pain, which restricts their usage in youngsters in particular. Over the past three decades, numerous varieties of human papillomaviruses have been identified. The cutaneous signs of an HPV infection are called warts. Depending on the HPV type causing the infection and the epithelial surface, warts can take on a variety of shapes. Clinical signs of HPV infection include common warts (Verruca vulgaris), plantar warts (Verruca plantaris), flat or plane warts (Verruca plana), and vaginal warts (Condyloma acuminata). Contact can spread warts directly between people or indirectly through fomites on left surfaces.

Skin that is macerated and comes into contact with abrasive surfaces—conditions that are prevalent in swimming pools and laundry rooms—is more likely to become infected through the environment,[2] Benign lesions called warts can develop on the skin and mucosa. The human papillomavirus (HPV), of which there are more than 100 varieties, is the cause of warts. HPV may happen anywhere. Common warts, vaginal warts, flat warts, deep palmoplantar warts (Myrmecia), localised epithelial hyperplasia, epidermodysplasia verruciformis, and plantar cysts are among the main signs of HPV infection. Both direct and indirect contact can spread warts. The risk of acquiring warts is increased by situations that interfere with the normal epithelial barrier. Therapy could be challenging. Within a few years, warts frequently go away on their own. Certain high-risk HPV subtypes, such as types 6, 11, 16, 18, 31, and 35, are linked to cancer. Immunocompromised patients and those with genital warts are typically the ones who experience malignant transformation. The carcinogenic potential of HPV strains 5, 8, 20, and 47 can result in epidermodysplasia verruciformis. Even though 65–78% of warts resolve on their own, prompt intervention is necessary due to the cosmetic deformity, propensity to spread, and related low quality of life. Nonetheless, both patients and dermatologists continue to find the treatment of various wart forms frustrating. Eliminating the lesions is the primary objective of wart treatment, along with reducing discomfort, avoiding scarring, and preventing recurrence. The location, size, quantity, and kind of warts, together with the patient's age and degree of cooperation, will all influence the treatment option. The two primary therapeutic approaches for treating warts are immunotherapy, which is predicated on stimulating the immune system to combat the virus and inhibit its activity, and the traditional, destructive and aggressive approach, which involves chemical cautery, cryotherapy, electrocauterization, surgical excision, and laser ablation. No single treatment works well for every patient, and the success percentage of immunological and destructive operations ranges from 65% to 85%. The treatment should ideally be straightforward, affordable, and unlikely to cause any unfavourable side effects.[3-6]

Fig 1: Wart-Infected Humans.

COMMON WART VARIETIES

❖ **Plantar warts**

On the soles of the feet, plantar warts develop. They can be uncomfortable because, in contrast to other warts, they develop inward under the strain of walking.

❖ **Flat warts**

The soles of the feet develop plantar warts. In contrast to other warts, they develop inward as a result of walking pressure, which can be uncomfortable.

❖ **Common warts**

Verruca vulgaris, or common warts, usually develop on the hands, knees, elbows, and fingers. They sometimes resemble cauliflowers and are thick, gritty, and rough with a rounded top.

❖ **Filiform warts**

Finger-like growths called filiform warts usually appear close to the lips, eyes, or nose.

❖ **Mosaic warts**

Clusters of tiny, flat warts that develop on the hands or soles of the feet are known as mosaic warts.

❖ **Genital warts**

Sexual contact is how genital warts are spread, and they affect the genital area.[7]

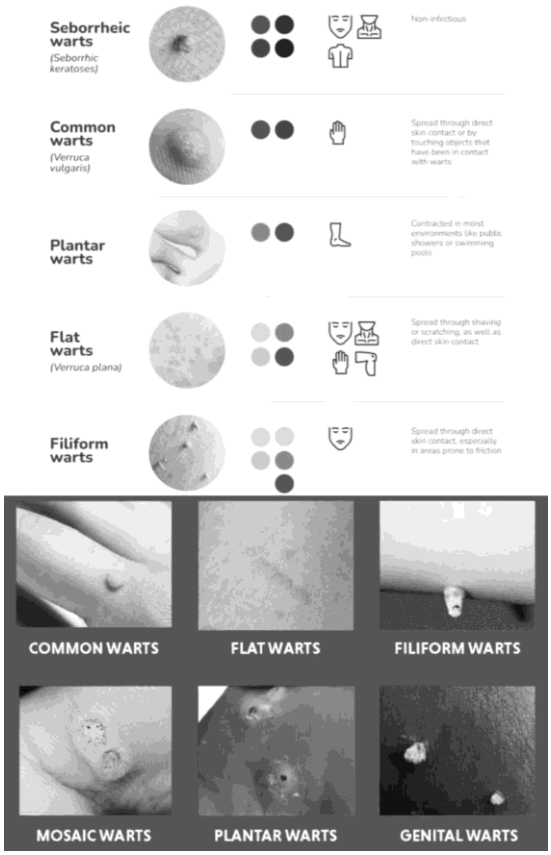

Fig 2: Warts Categorisation.

EPIDEMIOLOGY

One of the many human papillomaviruses can cause warts, which are cutaneous and occasionally mucosal lesions. evaluation of warts' clinicoepidemiological features. Materials and Procedures. Genital and nongenital warts, which are further classified as common, plane, palmoplantar, mosaic, and digitate/filiform, were the two main locational groups assigned to one hundred consecutive patients with warts who presented to our institution's department. outcomes. In our study, 90 people had nongenital warts and 10 had genital warts; the most common types of nongenital warts were common (42%), palmoplantar (20%), and flat (18%). Each genital wart was acuminate. All mosaic patients, 40% of palmoplantar patients, and 20% of genital wart patients were included in the second decade, which was the most prevalent age group. Overall, there was a 66% male preponderance. Every filiform wart case included a male. Mosaic warts were more common among women. The typical occupations were housewives (16%), labourers (28%), and students (32%). The most prevalent concerns were itching (15%), pain (16%), and cosmetic concern (92%). Within six months, all genital wart patients sought therapy. Conclusions. The most prevalent nongenital wart types were common, palmoplantar, and plane warts. Although the second decade saw the highest overall frequency, the first decade saw one-third of all aircraft wart instances.[8.9] The most often affected areas were the extremities (66.7%); the face was next in line (23%). A common medical issue, particularly among White people, is warts. Frequency: Roughly 10% of people globally suffer from warts, which are widespread. The prevalence can reach 10% to 20% in school-age children. Meat handlers and immunocompromised patients are more likely to have them. Age: Any age can be affected by warts. Prevalence rises among school-aged children and peaks between the ages of 12 and 16, despite being uncommon in infancy and early childhood. Race: White people are twice as likely as Black or Asian people to get warts. Inuit and American Indians are more likely to have focal epithelial hyperplasia, often known as Heck disease. Sex: There are almost equal numbers of men and women. The goal of the guideline is to enhance clinical outcomes for patients with HPV infectious skin diseases, lower medical expenses and economic burden, improve the overall quality of medical services for skin warts, and methodically and effectively guide the clinical care of warts. 4.2. Implementation, evaluation, and dissemination. According to a case report from 2016, 53 a generalized wart is a diffuse cutaneous wart that is more than 20 in number and spreads over multiple body parts. According to a 1989 nonrandomized controlled study, 54, recurring warts were those that resurfaced close to the initial locations of fully removed warts. Patients with common warts, particularly those with many warts, who are unable to tolerate cryotherapy and local injections, are advised to undergo thermotherapy.[10]

ETIOLOGY

Benign lesions called warts can develop on the skin and mucosa. The human papillomavirus (HPV), of which there are more than 100 varieties, is the cause of warts. HPV may happen anywhere. Human papillomavirus-induced cutaneous warts are benign proliferative lesions that can develop at any stage of life. There is an urgent need for evidence-based guidelines that are thorough, up-to-date, and systematic in order to guide clinical practice. Interleukins' function in HPV-induced malignant lesions has been thoroughly investigated, but less is known about their function in benign lesions like warts. In order to offer fresh insights on the subject, this study gathers

information from the past ten years regarding the role of interleukins in the pathophysiology of warts.[11-14] There is no visible scarring when warts go away on their own. Only a small number of the more than 100 HPV virus subtypes are capable of causing skin warts at certain anatomical locations. However, HPV can spread to any area of the body through physical contact. Genital warts, flat warts, and palmoplantar warts are frequently caused by HPV. Direct or indirect contact can easily spread warts, particularly when the usual epithelial barrier is compromised. In addition to the skin, mucosal membranes can also get warts. In general, HPV seldom spreads throughout the body; it typically just affects the skin's epithelial layers. Although the virus is known to reproduce in the epithelium's top layer, viral particles can also be discovered in the basal layer. HPV types 2, 4 (the most prevalent) are linked to common warts, followed by types 1, 3, 27, 29, and 57.

Types 3, 10, and 28 are the causes of flat warts.
Type 1 is the most prevalent source of deep palmoplantar warts, followed by types 2, 3, 4, 27, and 57. Type 60 causes cystic warts.
Types 13 and 32 are responsible for focal epithelial hyperplasia. Type 7 causes butcher's warts.[15-17]

PATHOPHYSIOLOGY

The human papillomavirus, a deoxyribonucleic acid virus that infects the epithelium and penetrates the epidermis, is the cause of warts, a benign skin growth. Human papillomavirus is released by warts and can spread to other persons or infect other locations in the area. Warts can be spread by intimate skin-to-skin contact; the human papillomavirus is more likely to infect skin that has been injured or cut. Additionally, contaminated surfaces or items can spread warts. Children are more vulnerable to warts because their bodies are less likely to have evolved immunity to the virus that produces them, whereas most adults have gained immunity to the virus. explains the pathophysiology of warts, their various forms, the most popular remedies for them, and offers several compounded wart therapy formulae. A small number of HPV's 100 subtypes have the potential to cause cancer. HPV strains 6, 11, 16, 18, 31, and 35 are among these subtypes. Immunocompromised people and those with genital warts are more likely to have malignant transformation. Moreover, HPV strains 5, 8, 20, and 47 have the capacity to cause cancer in those who have epidermodysplasia verruciformis. Although warts are usually benign, there have been reports that they can occasionally turn cancerous and progress into verrucous carcinoma. Often confused with a common wart, verrucous carcinoma is a slow-growing tumor that belongs to the well-differentiated squamous cell malignancy category. Although it can happen anywhere on the body, the plantar surface is where it most frequently occurs. Verrucous cancer is damaging locally but seldom spreads.[18-22]

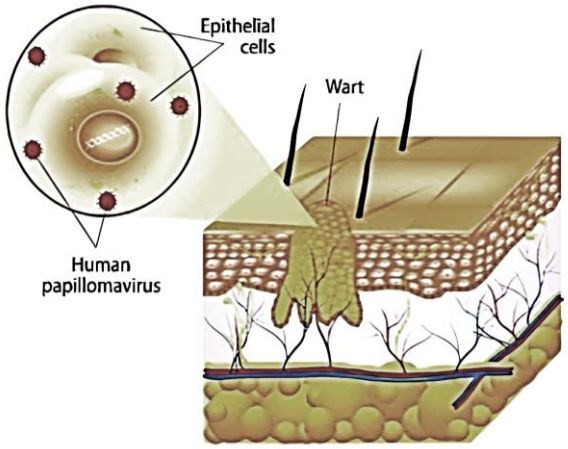

Fig 3: Pathophysiology of Warts.

WART HISTOPATHOLOGY

The Verrucca vulgaris, or common wart: Acanthosis, digitated epidermal hyperplasia, papillomatosis, compact orthokeratosis, hypergranulosis, tortuous capillaries within the dermal papillae, and vertical tiers of parakeratotic cells with red blood cells trapped above the tips of the digitations are among the histopathologic characteristics. Radially pointing toward the lesion's core are elongated rete ridges. HPV-infected cells exhibit wrinkled-looking nuclei surrounded by vacuoles and coarse keratohyalin granules in the granular layer. Pathognomonic cells are koilocytic cells. Butcher's: Acanthosis, hyperkeratosis, and papillomatosis are characteristics of butcher's warts. Clusters of centrally situated shrunken nuclei inside the granular layer rete ridges can be detected, together with little vacuolized cells. Filiform: Although they may have noticeable papillomatosis, filiform warts resemble typical warts in appearance. Heck disease, or focal epithelial hyperplasia: Acanthosis, blunting, hyperplastic mucosa with a thin parakeratotic stratum corneum, rete ridge anastomosis, and whiteness of epidermal cells as a result of intracellular edema are the hallmarks of focal epithelial hyperplasia. Vacuolated cells and noticeable keratohyalin granules may be present in some.[23-28] Deep Palmoplantar: Although the disease is located far below the skin's surface plane, deep palmoplantar warts resemble regular warts. Polygonal, refractile-looking, eosinophilic, cytoplasmic inclusions composed of keratin filaments that create ringlike formations are a characteristic of endophytic epidermal development. The higher layers of the epidermis may include basophilic parakeratotic cells that are laden with virions and basophilic nuclear inclusions. Flat: In light microscopy, flat warts resemble regular warts. The granular layer may contain cells with pyknotic, basophilic, centrally placed nuclei surrounded by conspicuous perinuclear vacuolization. People call these "owl's eye cells. "Cystic: Horny substance fills a cyst wart. Squamous, granular, and basal cells make up the wall. Large nuclei and transparent cytoplasm with eosinophilic inclusion bodies are characteristics of many epithelial cells. A foreign

body granuloma could result from the cyst rupturing.[29,30]

WART DETECTION

Common warts on the hands and feet are typically easy to diagnose. When a wart is removed, the capillary loops of the elongated dermal papillae are exposed, which frequently causes pinpoint bleeding. Warts must be differentiated from other keratotic lesions on the hands or feet, such as actinic keratoses, knuckle pads, or, less frequently, focal palmoplantar keratoderma or squamous cell carcinoma, either clinically or histologically. Corns and calluses or callosities on the feet can be mistaken for warts, although they should be able to be differentiated with careful examination and paring. Plane warts may need to be differentiated from lichen planus or thin actinic or seborrheic keratoses, and other hyperkeratotic lesions like lichen planus or angiokeratoma may confuse limbs.[31-33] Laboratory Studies: Although it has low sensitivity, immunohistochemical identification of HPV structural proteins verifies the virus's existence. Southern blot hybridisation is a more sensitive and specific method of identifying viral DNA for HPV types. Viral DNA is amplified for testing using the polymerase chain reaction. HPV is not necessarily present in older lesions, even if it can be seen in younger ones. Procedures: If there is any uncertainty about the diagnosis, a biopsy is taken. Tiny black spots that indicate thrombosed capillaries are frequently visible when a wart is pressed. The diagnostic gold standard, transmission channels, laboratory testing, therapeutic principles, clinical cure criteria, definitions, and therapies of common warts, flat warts, plantar warts, CA, and EV are all included in this guideline. There are recommendations regarding special groups, including pregnant women and children. This thorough and systematic evidence-based guideline is intended to improve the overall quality of medical services by providing systematic and effective guidance for the clinical practice of cutaneous warts. Around 2025, we will revise this guideline in accordance with the international guide's requirements. Warts typically last longer when the immune system, particularly cell-mediated immunity, is compromised.[34-37] Warts may be big, widespread, and resistant to therapy when immune function is significantly compromised, as occurs after an organ or bone marrow transplant or as a result of a severe combined immunological deficiency. Unusually severe or protracted warts should raise the possibility of an underlying immunological deficit because they may be the initial sign of less severe immunosuppressed conditions, including lymphoma, idiopathic CD4 lymphocytopenia, or HIV infection. Skin squamous cell carcinomas and premalignancy are also linked to papillomavirus infection. Both a modest immunological deficit and increased carriage of certain HPV types are linked to EV's familial tendency to develop scaly and flat wart-like keratotic lesions in adolescence, which often advance to squamous cell carcinoma in early adulthood. People who have been immunosuppressed for a long time, especially those who have received organ transplants, have a similar skin problem. Individuals with these illnesses had higher frequencies of HPV types that cause plane warts and those in the beta-papillomavirus subgroup than immunocompetent individuals.[38]

WART MANAGEMENT AND TREATMENT

Following a diagnosis, the course of treatment is determined by the patient's choices, symptoms, and financial constraints. Warts can be treated in a variety of ways, but none of them are particularly effective, and recurrences are frequent with all of them. The most concerning element of managing warts is the at least 30% recurrence rate when medication seems to be effective, which is likely caused by the virus resurfacing from the surrounding tissue reservoir. Although no single treatment is 100% effective in every patient, the success rates for both immunological and destructive procedures range from 65 to 85 per cent. Warts can be effectively treated with local destructive methods such as laser, electrocautery, and cryotherapy. However, these treatments are not feasible for patients with several lesions due to scarring, dyspigmentation, or recurrence. Resolving the infection depends on the host's age, HPV serotype, immunological condition, and infection site. Within two years of the commencement of symptoms, a wart or verruca may go away in immunocompetent people. Generally speaking, one should begin with the least costly and comfortable course of action. No treatment: Warts might just be a mild annoyance, depending on their location and size. An expectant approach to care is perfectly acceptable if the affected person is immunocompetent.[39,40] When widespread or on areas like the face, some warts can be painful, impair function, or cause significant aesthetic discomfort and humiliation. Several potential treatments might be taken into consideration under these conditions. Multiple recurring warts are often treated with the more costly and invasive procedures. Another component of treatment is observation, which should constantly be taken into account. Within 24 months, about two-thirds of warts are reported to spontaneously go away. The wart has a little chance of growing larger and possibly spreading to other places, which is the main drawback. Topical agents are typically used first. A frequent first-line treatment for common warts is salicylic acid. The patient can use it at home and doesn't need a prescription. Cure rates range from 50% to 70%. Other treatments include topical 5-fluorouracil, imiquimod, retinoic acid, podophyllin, cryotherapy, and interferon. Interventional treatment: There are many different ways to treat warts, but the evidence supporting their utility, either separately or in combination, is frequently weak. There are also a lot of home remedies that might be effective. Although many patients might prefer a permanent scar to a persistent, ugly, and bothersome wart, therapy should ideally leave no scars. Although there isn't a specific antiviral treatment for HPV, several of the available ones disrupt the viral life cycle. Damage or destruction of the diseased epithelium is the most popular therapy strategy. In addition to causing cell death, this can also expose and

display antigens, which may trigger an immunological response.[41,42] Reducing epidermal proliferation, or more precisely, DNA replication, should thin the wart and prevent the growth of new viruses. Few substances can destroy the virus particles, or virucide, at their surface, but they might not have an impact on virus-infected cells in the lower layers of the epidermis. The likelihood of an immune response to the infected keratinocytes could be increased by directly stimulating the immune system in the wart's vicinity. Although the immune response's contribution to wart removal following destructive or other inflammatory treatments is unknown, immunosuppressed individuals' poor or nonexistent response to treatment would imply that it is crucial. Common differences between studies include (i) not distinguishing between common and plane warts; (ii) including both children and adults as participants; (iii) evaluating clearance by cleared warts or clear patients; (iv) including different body sites; and (v) comparing treatments between participants or between individuals or between right-left or wart-warts. These guidelines describe the available evidence for a wide range of therapies because few of the existing treatments for warts have undergone extensive, rigorous trials. A treatment term of three to four months with variable follow-up times has been employed in numerous investigations. In these conditions, the cure rate for warts treated with a placebo is between 20 and 30 per cent. Destructive therapies: Chemical methods, like (a) salicylic acid and others (c–j) below, or physical methods, like (b) cryotherapy and others (k–n) below, can cause damage to the epidermis. Salicylic acid (see Appendices 1 and 2) (level of evidence 1+; strength recommendation): The most used preparation for treating viral warts is salicylic acid (SA) formulations. SA is an irritant at high concentrations and is believed to function by encouraging the exfoliation of epidermal cells. It is hypothesised that these effects can boost host immunity, which could be another way to combat warts. SA paints are the most widely used over-the-counter products. These are frequently used with lactic acid and contain SA at concentrations ranging from 10% to 26% in a collodion or polyacrylic base. Weaker cream preparations can be prepared, and plasters with 40% SA and ointments with 50% SA are also readily accessible. Although there is no trial data to support their effectiveness, the latter are occasionally used to treat facial warts. The formulation determines the SA application technique. Before applying wart paints, it is advised that lesions be soaked, abraded, or pared down. Paring should be done carefully to prevent abrading the normal skin around the patient, as this could transmit the disease. Using a 17% SA gel with lactic acid was beneficial, according to a study examining the impact of occlusion. 8. A qualitative study has revealed that patients find treatment challenging because SA paints irritate the surrounding skin, and there is little expectation of a cure.[43] Treatment adherence is believed to be low. SA (all formulations) was found to be more beneficial than a placebo in 2011, according to a meta-analysis of five studies involving 333 participants. According to the study, 95% of similar trials would give a treatment advantage of a 1·15–2·24 times enhanced likelihood of clearing [relative risk (RR) 1·60, 95% confidence interval (CI) 1·15–2·24]. Warts treated with SA are also 1·6 times more likely to clear than those treated with a placebo. 337 of the 813 patients in 16 SA studies were cured, according to a pooled analysis; the mean cure rate was 49%, with a range of 0–69%. On the other hand, the cure rate for a placebo was 23% (range: 5–73%). The Cochrane review was recently revised to add two significant studies that were published in the last few years11–12. 13 In a study by Bruggink et al.11, 250 primary care patients were randomly assigned to one of three treatment plans: 30% SA ointment, twice-weekly cotton-bud cryotherapy, or no treatment for 13 weeks. The aggregate cure rates for all sites were 15%, 49%, and 8%; the cure rates for hand warts were 17%, 46%, and 7%, and for plantar warts, they were 33%, 30%, and 23%. Therefore, in this trial, SA was more effective than no treatment at all, but less effective than cryotherapy for treating hand warts. In regards to plantar warts, neither treatment seems to be very successful. Data from the Cockayne et al. experiment also supports the ineffectiveness of cryotherapy and SA non treating plantar warts. Twelve This included 240 plantar wart patients treated in podiatric clinics in the United Kingdom using either "gentle" cryotherapy (up to four treatments administered by spray or probe, typically with preparatory paring of surrounding skin) or SA 50% for 12 weeks. Both treatments had a modest cure rate of only 14%, and there was neither a placebo nor a no-treatment group. Although the effectiveness of SA has been supported by recent research, nothing is known about the widely used SA paint formulas. Patients with persistent warts may benefit from cidofovir, which has been used to treat CMV infections in HIV patients. Fluorouracil has been administered for 30 days to treat warts under occlusion and to treat actinic keratosis. Flat warts have been treated with tretinoin, a vitamin A derivative, with varying degrees of efficacy. Some patients have also claimed success with intralesional injections of bleomycin, interferon alfa, and immunotherapy (Candida). Cimetidine, retinoids, and cidofovir are examples of systemic therapies that have been tested. Other nonpharmacological treatments include propolis, hypnosis, heat, adhesiotherapy, and other plant extracts. It is challenging to determine whether these therapies are effective in the absence of controlled trials, and the fact that warts do go away on their own. Cryotherapy, lasers, electrodesiccation, and excision are surgical procedures. When considering results, it's crucial to remember that roughly two-thirds of warts go away on their own over the course of 12 to 24 months, leaving virtually little scarring or remaining flaw.[44] However, scars, discomfort, expense, and other effects are unavoidable when warts are treated medically or surgically. More significantly, there are failures linked to each and every wart treatment. Although warts are usually asymptomatic, depending on where they are, some

people may experience pain. Although it is uncommon, warts have been known to undergo malignant transformation (Level V).[45]

Fig 4: Several effective medications for Warts.

DISCUSSION AND CONCLUSION

In addition to giving a general overview of warts, our review papers discuss their pathophysiology, epidemiology, diagnostics, alternative therapies, and many causes. Although warts can be treated with skin-related drugs and other therapies, our findings indicate that more clinical research is needed due to the complexity of warts. Warts need to be treated with more randomised controlled trials. We want to provide an initial warts assessment in the future. To provide more accurate information regarding warts and their treatment, future counselling-based research in our state or nation will evaluate patients' mental and physical health with the help of our colleagues.

ETHICAL STATEMENT

A pharmacist needs to act with integrity and honesty. A pharmacist refrains from actions that undermine their dedication to acting in their patients' best interests, such as discriminatory acts, inappropriate behaviour, and unfavourable working conditions that cloud judgment. A pharmacist keeps up their level of expertise.

ACKNOWLEDGEMENT

The authors would like to thank Shri Venkateshwara University, Gajraula, Uttar Pradesh, India, City Women's College, Jankipuram, Lucknow, Uttar Pradesh, India, Goel Institute of Pharmacy & Sciences, Lucknow, U.P., India & Signa College of Pharmacy, Kanpur, Uttar Pradesh, India, for extending their facilities.

CONFLICT OF INTEREST

The authors attest that they are free of any known financial or personal conflicts of interest that would taint the findings of this study.

INFORMED CONSENT

Using websites, review articles, and other sources to produce research content.

REFERENCES

1. Chuang TY, Perry HO, Kurland LT, Ilstrup DM: Condyloma acuminatum in Rochester, Minn., 1950-1978. I. Epidemiology and clinical features. Arch Dermatol, 1984; 120: 469-75.
2. Fleischer AB Jr, Parrish CA, Glenn R, Feldman SR: Condylomata acuminata (genital warts): patient demographics and treating physicians. Sex Transm

Dis, 2001; 28: 643-7. 10.1097/00007435-200111000- 00006
3. Leung AK, Barankin B, Leong KF, Hon KL: Penile warts: an update on their evaluation and management. Drugs Context, 2018, 7: 212563. 10.7573/dic.212563
4. Lynch MD, Cliffe J, Morris-Jones R: Management of cutaneous viral warts. BMJ, 2014; 348: g3339. 10.1136/bmj.g3339
5. Ockenfels HM: Therapeutic management of cutaneous and genital warts. J Dtsch Dermatol Ges, 2016; 14: 892-9. 10.1111/ddg.12838
6. Gibbs S, Harvey I: Topical treatments for cutaneous warts. Cochrane Database Syst Rev, 2006; CD001781. 10.1002/14651858.CD001781.pub2
7. Williams HC, Pottier A, Strachan D: The descriptive epidemiology of warts in British schoolchildren. Br J Dermatol, 1993; 128: 504-11. 10.1111/j.1365-2133.1993.tb00226.x
8. Ockenfels HM, Hammes S: Laser treatment of warts [Article in German]. Hautarzt, 2008; 59: 116-23. 10.1007/s00105-007-1468-9
9. Leman JA, Benton EC: Verrucas. Guidelines for management. Am J Clin Dermatol, 2000; 1: 143-9. 10.2165/00128071-200001030-00001
10. Connolly M, Bazmi K, O'Connell M, Lyons JF, Bourke JF: Cryotherapy of viral warts: a sustained 10-s freeze is more effective than the traditional method. Br J Dermatol, 2001; 145: 554-7. 10.1046/j.1365- 2133.2001.04449.x
11. Tabrizi SN, Garland SM: Is cryotherapy treating or infecting?. Med J Aust, 1996; 164: 263. 10.5694/j.1326- 5377.1996.tb94183.x
12. Sri, J. C., Dubina, M. I., Kao, G. F., Rady, P. L., Tyring, S. K., &Gaspari, A. A. (2012). Generalized verrucosis: a review of the associated diseases, evaluation, and treatments. Journal of the American Academy of Dermatology, 66(2): 292-311.
13. Boeckmann, L., Martens, M. C., & Emmert, S. (2020). Molecular biology of basal and squamous cell carcinomas. In Sunlight, Vitamin D and Skin Cancer (pp. 171-191). Springer, Cham.
14. Emsen IM and Kabalar ME (2010): Epidermodysplasia verruciformis: An early and unusual presentation. Can J Plast Surg, 18: 21-24.
15. Aşkın, Ö. (2017). Anogenital HPV. Fundamentals of Sexually Transmitted Infections, 17.
16. Satyaprakash, A., & Mansur, C. (2016). 12 Human Papilloma viruses. Mucocutaneous Manifestations of Viral Diseases: An Illustrated Guide to Diagnosis and Management, 207.
17. Gross G, Pfister H. (2004): Role of human papillomavirus in penile cancer, penile intraepithelial squamous cell neoplasias and in genital warts. Med Microbiol Immunol, 193: 35–44.
18. Purnell D, Ilchyshyn A, Jenkins D, Salim A, Seth R, Snead D. (2001): Isolated human papillomavirus 18-positive extragenitalbowenoidpapulosis and idiopathic CD4+ lymphocytopenia. Br J Dematol, 144: 619–621.
19. Nayak SU, Shenoi SD and Bhat ST (2015): Bowenoid papulosis. Indian J Sex Transm Dis AIDS, 36: 223-225.
20. Sterling JC, Gibbs S, HaqueHussain SS, MohdMustapa MF, Handfield-Jones SE. (2014): British Association of Dermatologists' guidelines for the management of cutaneous warts 2014. The British Journal of Dermatology, 171(4): 696-712. DOI: 10.1111/bjd.13310. Epub 2014 October 1.
21. Syrjanen, S., Termine, N., Capra, G., Paderni, C., Panzarella, V., & Campisi, G. (2012). Oral HPV infection: current strategies for prevention and therapy. Current pharmaceutical design, 18(34): 5452-5469.
22. Sun, D., Jiang, H., Yang, P., & Liu, Y. (2020). HPV-related verrucous carcinoma of the endometrium: report of one case and review of literature. International Journal of Clinical and Experimental Pathology, 13(6): 1444.
23. Borborema-Santos, C. M., Castro, M. M. D., Santos, P. J. B. D., Talhari, S., &Astolfi-Filho, S. (2006). Oral focal epithelial hyperplasia: report of five cases. Brazilian dental journal, 17(1): 79-82.
24. Galanakis, A., Palaia, G., Tenore, G., Del Vecchio, A., & Romeo, U. (2014). Focal epithelial hyperplasia in a human immuno-deficiency virus patient treated with laser surgery. World Journal of Clinical Cases: WJCC, 2(7): 293.
25. Schnadig VJ, Clark WD, Clegg TJ, Yao CS. (1986): Invasive papillomatosis and squamous carcinoma complicating juvenile laryngeal papillomatosis. Arch Otolaryngol Head Neck Surg, 112: 966-71.
26. Gupta D, Holden J, LayfieldLr. (2001): Papillomatosis. Appl Immunohistochem Mol Morphol, 9: 86-91.
27. Kaliterna, V., &Barisic, Z. (2018). Genital human papillomavirus infections. infection, 6: 8.
28. Piccolo, Vincenzo. (2020): "Update on dermoscopy and infectious skin diseases." Dermatology Practical & Conceptual, 10.1.
29. Tschandl P, Argenziano G, Bakos R, et al. Dermoscopy and entomology (entomodermoscopy) J DtschDermatolGes, 2009; 7(7): 589–596.
30. Abreu AL, Souza RP, Gimenes F, Consolaro ME. (2012): A review of methods for detect human Papillomavirus infection. Virol J., 9: 262.
31. Elder DE, Elenitsas R, Johnson BL, George F. (2005): Diseases caused by viruses. In: Lever's Histopathology of the skin. DE Elder, R Elenitsas, BL Johnson, F George. (eds). Published by: Lippincott Williams & Wilikins. 9 th edition.
32. Bacaj, Patrick, and David Burch. (2018): "Human papillomavirus infection of the skin." Archives of pathology & laboratory medicine, 142.6, 700- 705.
33. Lowry DR, Androphy EJ. (2003): Warts. In: Fitzpatrick's dermatology in general medicine. IM Freedberg, AZ Eisen, W Klaus, KF Austen, LA Goldsmith, SI Katz (eds). Published by: McGraw-Hill Inc. New York. 6th edition, 2: 2119-2131.

34. Jaled M and Moreno HC (2009): Virus papilomahumano (HPV) Parte II - clínica y terapéutica. Dermatología Argentina; 16(2): 102- 109.
35. Vender R, Bourcier M, Bhatia N, et al., (2013): Therapeutic options for external genital warts. Journal of Cutaneous Medicine and Surgery, 17(6-Suppl): S61-S67.