

**MOUNIER-KUHN SYNDROME A CASE REPORT AND LITERATURE REVIEW****Dr. Osama A. Mabrouk Kheiralla*¹, Dr. Walid G. Babikr. MD², Dr. Madani M. A. Globawe. MBBS³**¹Assistant Professor of Radiology - Department of Radiology - Faculty of Medicine - University of Najran - Radiology Consultant - NUH - KSA.²Assistant Professor of Internal Medicine - Faculty of Medicine - University of Najran - Internal Medicine Consultant - NUH - KSA.³Faculty of Medicine - University of Najran - Internal Medicine Resident - NUH - KSA.***Correspondence for Author: Dr. Osama A. Mabrouk Kheiralla**

Assistant Professor of Radiology, Department of Radiology, Faculty of Medicine, University of Najran, Radiology Consultant, NUH, KSA.

Article Received on 27/02/2016

Article Revised on 15/03/2016

Article Accepted on 05/04/2016

ABSTRACT

Mounier–Kuhn syndrome is a rare respiratory tract condition characterized by abnormal dilatation of the trachea and main bronchi, it may present with symptoms similar to Asthma or Chronic obstructive pulmonary disease (COPD), so it is important for the primary health care practitioner to keep in mind this syndrome when evaluating patients with symptoms similar to Asthma or Chronic obstructive pulmonary disease (COPD) specially when the patient does not respond to treatment of these diseases, because early diagnosis and management of Mounier–Kuhn syndrome may lead to good outcome and will prevent complications of this disease. This is a case report of a 46-year-old farmer was presented to the radiology department for evaluation of long history of recurrent attacks of lower respiratory tract infections associated with shortness of breath, dyspnea, wheezing and productive cough; Mounier– Kuhn syndrome was confirmed by Chest X-ray CT scan and Bronchoscopy.

KEYWORDS: Mounier–Kuhn syndrome Tracheobronchomegaly Chronic obstructive pulmonary disease (COPD) Asthma.**INTRODUCTION**

Mounier–Kuhn syndrome (MKS) or Tracheobronchomegaly is a rare congenital disease characterized by abnormal dilation of the trachea and main bronchi due to atrophy or absence of their elastic fibers and smooth muscles. The airway is flaccid and markedly dilated during inspiration and collapsed during expiration.^[1, 2] Because of the loss of inherent tracheal wall support, diverticula develop, commonly in posterior part.^[3, 4] Patients frequently have mucus retention secondary to weakened airways and multiple diverticuli forming pockets of mucus that lead to inefficient cough, further impeding mucociliary clearance.^[5] These compromised airway protective mechanisms, often result in recurrent pneumonias, bronchiectasis and fibrosis.^[4, 6]

CASE REPORT

A 46-year-old farmer was presented to the radiology department for evaluation of recurrent pneumonia with productive cough shortness of breath, dyspnea and wheezing. His condition started since he was 10 years old with recurrent attacks of lower respiratory tract infection with productive cough, wheezes and fever, his

symptoms completely recover after management, and the patient becomes asymptomatic between the attacks. On the last 5 years, respiratory tract infections became more frequent and more aggressive with fever, productive cough, shortness of breath and expectoration of mucoid, purulent, foul smelling sputum, sometimes it becomes bloody streaked. Patient was frequently hospitalized, sputum for AAFB was negative but still he received antituberculous treatment without improvement.

On physical examination he was unwell, febrile 38.5°C, respiratory system examination revealed tachypnea with RR 28 Bpm, decreased breath sound with bilateral lower lobe crackles. Laboratory investigations revealed leukocytosis (21.500X10⁹/l), ESR (22 mm/hr.). Sputum was negative for AAFB, but was positive for Haemophilus influenzae and Pseudomonas aeruginosa.

Chest X-ray showed dilated trachea and main bronchi with bilateral diffuse interstitial lung markings, nodular shadows band bronchiectasis (Figure 1).

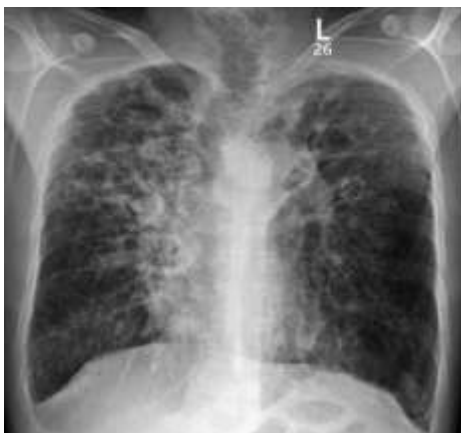

Figure 1: AP Chest X-ray showing dilated trachea and main bronchi with bilateral diffuse interstitial lung markings, nodular shadows and bronchiectasis.

Computed tomography (CT) scan revealed increased diameter of trachea and main bronchi with transversal diameters of the trachea of 4.8 cm, while right and left main bronchi had diameter of 2.9 cm and 2.8 cm

respectively, with ground glass opacification and multiple bilateral nodules and cystic bronchiectatic changes noted bilaterally (Figures 2).

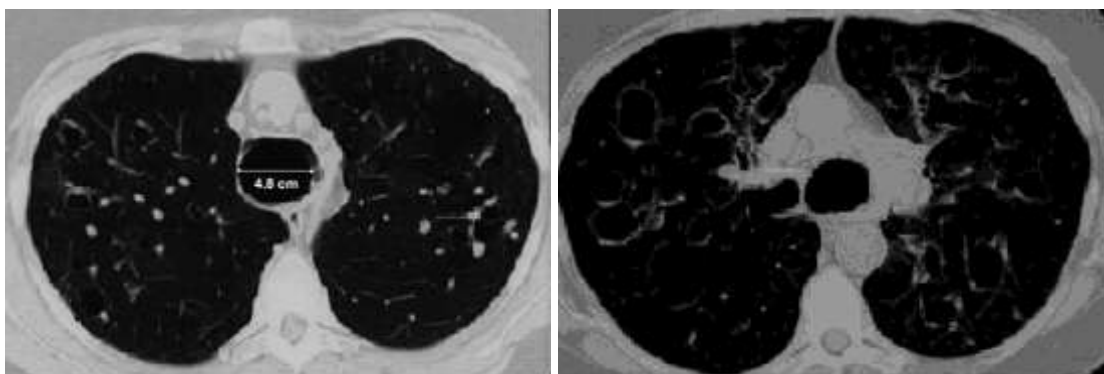


Figure 2: CT scan showing increased diameter of trachea and main bronchi with transversal diameters of the trachea of 4.8 cm, while right and left main bronchi had diameter of 2.9 cm and 2.8 cm respectively, with ground glass opacification and multiple bilateral nodules and cystic bronchiectatic changes noted bilaterally.

A Flexible bronchoscopy was performed and revealed markedly enlarged airways with thick mucus and few ulcerations on the anterior bronchial wall, whitish

cartilaginous nodules were noted on the anterior wall of the proximal portion of the trachea (Figure 3).




Figure 3: Flexible bronchoscopy showing markedly enlarged airways with thick mucus and few ulcerations on the anterior bronchial wall, whitish cartilaginous nodules were noted on the anterior wall of the proximal portion of the trachea.

DISCUSSION

Mounier-Kuhn syndrome is a rare congenital abnormality of the trachea and main bronchi of uncertain etiology. Its main characteristic feature is complete absence or atrophy of elastic fibers and smooth muscle tissues of the trachea and main bronchi, which allows the trachea and the main bronchi to become dilated on inspiration and narrowed or collapsed on expiration. Tracheobronchomegaly was observed at first at an autopsy done by Czyhlarz in 1897,^[5] but only in 1932 Mounier-Kuhn, bronchoscopist, described the endoscopic and radiographic appearance of the enlargement of airway with recurrent respiratory infections.^[7] Less than 100 cases have been reported until 2002 in the World literature^[8], despite an expected incidence of 1% of tracheobronchomegaly cited in a previous retrospective study.^[3] The etiology remains uncertain, a congenital connective tissue weakness, in combination with inhalation of irritants like cigarette smoke and air pollution, are discussed as possible factors in the development of this syndrome.^[2] A familial form has been described with a possible recessive inheritance.^[9] Acquired forms have been reported as mechanical ventilation complication in premature infants, and pulmonary fibrosis in adults.^[10,11] Secondary tracheobronchomegaly was also described in association with Ehlers-Danlos Syndrome; Marfan Syndrome, Kenny-Caffey Syndrome, Brachmann-de-Lange Syndrome, connective tissue diseases, ataxia telangiectasia, Bruton-type agammaglobulinemia, ankylosing spondylitis, cutis laxa, and light chain deposition disease^[12,13], despite the fact that most of the cases appear sporadically. It has also been described with other anomalies of the tracheobronchial tree, as lower trachea duplication, tracheal trifurcation and right upper-lobe hypoplasia.^[1]

The diagnosis is reached by an image examination. Standard chest radiographs often do not demonstrate all the extent of the disease, but the dilatation of the trachea and bronchi; irregularly corrugated or scalloped appearance of the air columns can be showed.^[14] In evaluation of patients with tracheobronchomegaly HRCT scan is the examination of choice. On CT scan, the diagnosis is made when the transverse diameter of trachea measures greater than 3.0 cm and that of right and left main bronchi exceeds 2.4 cm and 2.3 cm respectively.^[15] The transverse diameter of trachea in our case is 4.8 cm, right and left main bronchi had diameter of 2.9 cm and 2.8 cm respectively. There are few data about the use of the magnetic resonance image (MRI) at the diagnosis of the tracheobronchomegaly, but the HRTC may probably be superior concerning lung tissue and bronchiolar tree evaluation.^[16] The bronchoscopy can also offer a dynamic view of the airway, and possibility of the collect bronchoalveolar fluids and biopsy in selected cases, but its routinely use is unnecessary.^[1]

Management and treatment of patients affected by Mounier-Kuhn syndrome are difficult.^[17]

The basic standard in management of patients with tracheobronchomegaly is postural drainage to clear out secretions, antibiotic therapy for infectious exacerbations and bronchodilators may be used during exacerbations. Surgery is rarely done due to diffuse nature of disease with tracheal stenting being useful in advanced cases with reports of tracheobronchial endoprosthesis being used with some success.^[18-19]

CONCLUSION

Despite it is rare, Mounier-Kuhn Syndrome can be misdiagnosed in patients with recurrent respiratory tract infections. CT scan must always be considered when evaluating patients with symptoms similar to Asthma or Chronic obstructive pulmonary disease (COPD) specially when the patient does not respond to treatment of these diseases, to rule out Tracheobronchomegaly, because early diagnosis and management of Mounier-Kuhn syndrome may lead to good outcome and will prevent complications of this disease.

REFERENCES

1. Menon B, Aggarawal B, Igbal A: Mounier-Kuhn Syndrome: report of 8 cases of tracheobronchomegaly with associated complications. *South Med J*, 2008; 101(1): 83–87.
2. Ricardo Beneti, Maurício Fregonesi Barbosa, Marcelo Domingos Mansano, Vanessa Carolina de Barros Silva, Giacommo Amaral Zambon: Mounier-Kuhn Syndrome, a case report. *The American Journal of Case Report*, 2009; 10: 69-71.
3. Himalstein MR, Gallagher JC. Tracheobronchomegaly. *Ann Otol Rhinol Laryngol*, 1973; 82: 223-7.
4. Ghanei M, et al. Mounier-Kuhn syndrome: a rare cause of severe bronchial dilatation with normal pulmonary function test: a case report. *Respir Med*, 2007; 101(8): 1836–9.
5. Atman Shah, Abubakr A. Bajwa, Akram Khan: Mounier-Kuhn syndrome masquerading as obstructive lung disease. Case report. *Respiratory Medicine CME*, 3 (2010): 73–75.
6. Jain P, et al. Mounier-Kuhn syndrome. *Indian J Chest Dis Allied Sci*, 2002; 44(3): 195–8.
7. P. Mounier-Kuhn, Dilatation de la trachée; constatations radiographiques et bronchoscopiques, *Lyon Medical*, 150 (1932), pp. 106–109.
8. Sorenson SM, Moradzadeh E, Bakhda R: Repeated Infections in a 68- year-old man. *Chest*, 2002; 121: 644–46.
9. Spencer H: Congenital abnormalities of the lung: congenital tracheobronchomegaly. In: Spencer H (ed.), *Pathology of the Lung*. 4th ed. Oxford, UK: Pergamon Press, 1985: 129–30.

10. Bhutani VK, Ritchie WG, Schaffer TH: Acquired tracheomegaly in very preterm neonates. *Am J Dis Child*, 1986; 140: 449–52.
11. Woodring JH, Barrett PA, Rehm SR et al: Acquired tracheomegaly in adults as a complication of diffuse pulmonary fibrosis. *Am J Roentgenol*, 1989; 152: 743–47.
12. Huete-Garin A, Sagel SS. Mediastinum. In: Lee JKT, Sagel SS, Stanley RJ, Heiken JP, editors. *Computed body tomography with MRI correlation*. 4th edition. Philadelphia: Lippincott Williams & Wilkins; 2006. pp. 311–410.
13. Fortuna FP, Irion K, Wink C, Boemo JL. Mounier Kuhn syndrome. *J Bras Pneumol*. 2006; 32: 80–3. [PubMed]
14. Shin MS, Jackson RM, Ho KJ: Tracheobronchomegaly (Mounier-Kuhn syndrome): CT diagnosis. *Am J Roentgenol*, 1988; 150: 777–79.
15. Lee JK (2006) *Computed body tomography with MRI correlation*. 1: 408-409.
16. Vock P, Spiegel T, Fram EK, et al: CT assessment of the adult intrathoracic cross section of the trachea. *J Comput Assist Tomogr*. 1984; 8: 1076–82.
17. Villani PC, Ambrosi F, Grimaldi F. The Mounier-Kuhn syndrome (tracheobroncomegaly). The diagnostic role of computed tomography. *Radiol Med* 1995; 90: 313.
18. Giannoni S, Benassai C, Allori O, Valeri E, Ferri L, et al. (2004) Tracheomalacia associated with Mounier-Kuhn syndrome in the Intensive Care Unit: treatment with Freitag stent. A case report. *Minerva Anesthesiol* 70: 651-659.
19. Pilavaki M, Anastasiadou K, Vlachoanni E, Drosos H, Petridis A, et al. [Tracheobronchomegaly (Mounier-Kuhn syndrome): roentgen findings and tracheal stent instrumentation]. *Pneumologie*, 1995; 49: 556-558.