

**CONTEMPORARY PERSPECTIVES ON DIAGNOSIS, MORPHOLOGICAL  
CONFIRMATION, AND PROGNOSTIC EVALUATION OF THE  
CARDIOESOPHAGEAL JUNCTION CANCER (REVIEW ARTICLE)****Umirov Avazbek Abdunazarovich<sup>\*1,2</sup>, Yusupbekov Abrorjon Akhmedjanovich<sup>1</sup> and Urunbaev Sundr  
Davlatovich<sup>2</sup>**<sup>1</sup>Republican Specialized Scientific-Practical Medical Center of Oncology and Radiology. 383. Farabi str.,  
Shaykhontohur district, Tashkent, Uzbekistan.<sup>2</sup>Syrdarya Regional branch of Republican Specialized Scientific-Practical Medical Center of Oncology and Radiology.<sup>1</sup>Khondamir str., Dustlik district, Gulistan city, Syrdarya Region, Uzbekistan.**\*Corresponding Author: Umirov Avazbek Abdunazarovich**Republican Specialized Scientific-Practical Medical Center of Oncology and Radiology. 383. Farabi str., Shaykhontohur  
district, Tashkent, Uzbekistan.

Article Received on 09/04/2025

Article Revised on 30/04/2025

Article Published on 21/05/2025

**ABSTRACT**

This review summarizes current issues on the morphological, anatomical, physiological and molecular biological features of tumors of the cardioesophageal junction (CEJ), including classification by Siewert type, growth and differentiation patterns, as well as precancerous changes in the mucosa in conditions of chronic gastroesophageal reflux. Particular attention is paid to prognostic and predictive factors, immunohistochemical markers (HER2, PD-L1, MSI, Ki-67, etc.), the possibilities of instrumental and molecular diagnostics (NBI, EUS, PET-CT, liquid biopsy). The importance of a multimodal approach for personification of therapy, prognosis and early diagnosis of CEJ tumors is emphasized.

**KEYWORDS:** Cardioesophageal cancer, adenocarcinoma, Barrett's esophagus, Siewert classification, molecular diagnostics.

**INTRODUCTION**

Cardioesophageal cancer is a major concern in modern oncology due to its aggressive nature and difficulties in diagnosis and treatment. In recent decades, there is a tendency of increase in the incidence of adenocarcinoma of the distal esophagus and cardiac part of the stomach, especially in Western countries. According to the US National Cancer Institute, the incidence of esophageal adenocarcinoma increased 7-fold from 1975 to 2009.<sup>[27]</sup> According to Tillyashaykhov M.N. (2023), 770 new cases of esophageal cancer were registered in Uzbekistan in 2022, the incidence rate is 2.1 per 100,000 population. The highest frequency was detected in the Republic of Karakalpakstan (8.8 per 100,000), the lowest - in the Syrdarya region (0.7 per 100,000). Most patients are diagnosed at stage III of the disease (47.4%), while the five-year survival rate is only 22.8%. Morphological verification was established in 94.5% of cases, mainly represented by squamous cell carcinoma.<sup>[11]</sup> Epidemiological indicators of SC cancer vary depending on the geographic region and ethnicity. In Russia, the standardized incidence rate of esophageal cancer is 6.7 per 100,000 population, with men being affected 3 times more often than women.<sup>[9]</sup> The five-year survival rate of patients with esophageal cancer remains low, which is

associated with late diagnosis and aggressive biological behavior of the tumor. According to the European Society for Medical Oncology, the overall five-year survival rate does not exceed 20%.<sup>[24]</sup> The etiology and pathogenesis of esophageal cancer are multifactorial and include both exogenous and endogenous factors. Smoking and alcohol consumption are among the main risk factors for the development of SC carcinoma of the esophagus.<sup>[21]</sup> Chronic gastroesophageal reflux, leading to the development of Barrett's esophagus, is considered a precancerous condition associated with an increased risk of adenocarcinoma of the lower third of the esophagus.<sup>[31]</sup> Obesity is also a significant risk factor, especially for adenocarcinoma, which is associated with increased intra-abdominal pressure and an increased incidence of gastroesophageal reflux.<sup>[23]</sup> Genetic and molecular abnormalities, such as mutations in the TP53, CDKN2A genes and amplification of the ERBB2 (HER2/neu) gene, play an important role in the carcinogenesis of CEJ cancer.<sup>[14]</sup>

The importance of the research topic is due to the increasing incidence of CEJ, the complexity of its diagnosis and treatment, as well as an unfavorable prognosis for patients. The development of effective

methods for early diagnosis, morphological verification and prognosis of CEJ is a priority task in modern oncology.

The purpose of the study is a comprehensive study of the anatomical, physiological, morphological and molecular features of the cardioesophageal zone in order to optimize the diagnosis, verification and prognosis of malignant neoplasms of this localization.

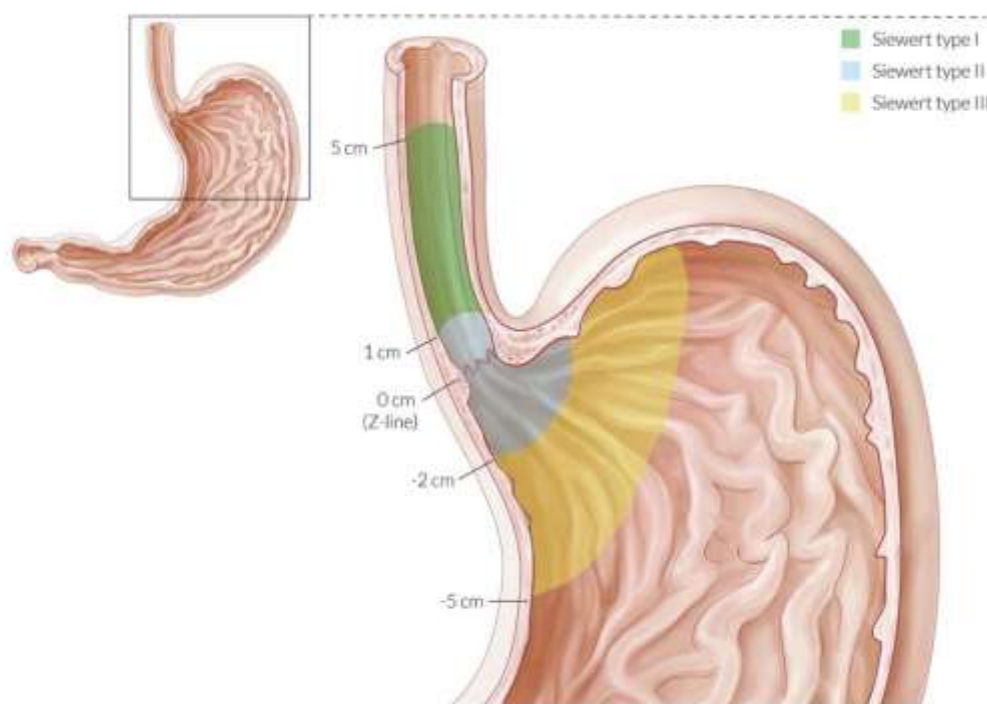
#### Anatomical, physiological and pathogenetic features of the cardioesophageal junction

The cardioesophageal junction is a complex anatomical and physiological region located at the border between the distal esophagus and the proximal stomach. Its microanatomy is characterized by the transition of the stratified squamous epithelium of the esophagus to the simple columnar epithelium of the stomach, which forms the so-called Z-line. The submucosal layer of this zone contains cardiac glands that produce mucus, as well as neuroendocrine cells involved in the regulation of motility and secretion.<sup>[32]</sup>

Chronic gastroesophageal reflux (GER) is a key risk factor for the development of epithelial metaplasia in the esophagus. Chronic exposure of the lower esophageal mucosa to acidic gastric contents can result in the replacement of normal squamous epithelium by

columnar epithelium, known as Barrett's esophagus. This condition is considered precancerous and is associated with an increased risk of esophageal adenocarcinoma.<sup>[31]</sup>

The biological behavior of CEJ tumors is of particular interest in oncology, since the boundary between esophageal adenocarcinoma and gastric cardiac adenocarcinoma remains a matter of debate. The morphological boundary between the esophagus and cardia is determined by the transition from stratified squamous epithelium of the esophagus to simple columnar epithelium of the stomach, which corresponds to the Z line visible during endoscopic examination. The Z line (from the German word "Zerrata" - serrated) is the dividing line between the pale pink mucosa of the esophagus and the bright red mucosa of the stomach. Normally, the Z line is located at the level of the esophagogastric junction, but in some pathological conditions, such as gastroesophageal reflux disease or Barrett's esophagus, it can shift. In Barrett's esophagus, the columnar epithelium extends proximally into the esophagus, which leads to a change in the location of the Z line. The most widely used classification is that proposed by J.R. Siewert, which subdivides adenocarcinomas of the esophagogastric junction into three types depending on the location of the tumor epicenter relative to the anatomical Z line<sup>[30]</sup> (Fig. 1):



**Figure 1: Siewert classification of cardio-esophageal junction cancer.**

Type I - adenocarcinoma of the distal esophagus, the center of which is located 1-5 cm above the Z line.

Type II - true adenocarcinoma of the esophagogastric junction zone, the tumor center is within 1 cm above and 2 cm below the Z line.

Type III - adenocarcinoma of the subcardiac part of the stomach, the center of which is located 2-5 cm below the Z line with possible involvement of the distal esophagus.<sup>[30]</sup>

The division into these types is important for the choice of treatment tactics and prognosis of the disease. For example, type I tumors often require approaches similar to the treatment of esophageal cancer, while for types II and III, strategies used for gastric cancer are preferable.<sup>[30]</sup>

**Morphological verification** of CEJ cancer plays a key role in choosing the optimal treatment tactics and predicting the outcome of the disease. The main histological types of CEJ tumors are adenocarcinoma, squamous cell carcinoma, and rare variants such as signet ring cell carcinoma. Adenocarcinoma is the most common histological type of CEJ cancer. According to the data presented in the study by Siewert *et al.*, adenocarcinoma accounts for a significant proportion of cancer cases in this location. It is divided into subtypes: tubular, papillary, and mucinous forms, each of which has its own morphological and clinical features. SC carcinoma is less common and is characterized by an aggressive course with early metastasis. According to a study conducted at the Russian Oncological Research Center named after N.N. Blokhin, the incidence of squamous cell carcinoma in the CEJ is 2.9% of cases.<sup>[4]</sup> Signet ring cell carcinoma is a specific histological subtype of gastric adenocarcinoma characterized by the presence of malignant cells with abundant intracellular mucin, which displaces the nucleus to the periphery, giving them a characteristic ring shape.<sup>[3]</sup> This subtype is associated with a more aggressive biology and a worse prognosis.

The degree of tumor differentiation has a significant impact on its biological behavior. Low-differentiated CEJ tumors are characterized by high aggressiveness and a tendency to early metastasis. A study by Siewert *et al.* showed that the highest frequency of low-differentiated cancer (more than 70%) is observed in type III tumors according to the Siewert classification. Invasiveness is determined by the depth of tumor penetration into the organ wall and the involvement of surrounding tissues. Deep invasion often correlates with an unfavorable prognosis and limits the possibilities of radical surgical treatment.<sup>[29]</sup> The stromal component of the tumor, including fibroblasts, immune cells, and vasculature, plays an important role in supporting tumor growth and forming a microenvironment that promotes disease progression. Changes in the stroma can affect tumor sensitivity to various types of therapy.<sup>[4]</sup>

Biopsy material is the main method of morphological verification of CEJ tumors. To obtain reliable results, it is recommended to perform a multifocal biopsy with material collection from 6-8 tumor sites. This allows taking into account tumor heterogeneity and increasing the accuracy of diagnosis.<sup>[1]</sup> With submucosal infiltrative tumor growth, false-negative results are possible, which requires a repeated deep biopsy or the use of additional diagnostic methods, such as endoscopic ultrasonography.<sup>[1]</sup>

**Immunohistochemical and molecular markers** play a key role in diagnostics; among the most significant markers are CK7, CK20, CDX2, HER2/neu, Ki-67, p53, MUC2, MUC5AC, as well as promising markers such as Claudin 18.2, FGFR2 and VEGFR.

CK7 and CK20 are cytokeratins, the expression of which helps to determine the origin of epithelial tumors. Studies have shown that CK7 and CK20 expression profiling helps differentiate adenocarcinomas of different origins. For example, gastric adenocarcinomas frequently express CK7 but not CK20, whereas adenocarcinomas can express both markers.<sup>[26]</sup> CDX2 is an epithelial-specific transcription factor. Its expression in CEJ tumors may indicate intestinal metaplasia or tumor origin from the intestinal epithelium. Positive CDX2 expression is associated with intestinal-type adenocarcinomas and may have prognostic significance.<sup>[16]</sup> HER2/neu (human epidermal growth factor 2) is a tyrosine kinase receptor that is amplified or overexpressed in approximately 15-20% of patients with gastric and CEJ adenocarcinomas. Determination of HER2 status is important for the prescription of targeted therapy with trastuzumab. It is recommended to perform immunohistochemical examination of HER2 with subsequent confirmation by fluorescence in situ hybridization (FISH) in case of equivocal results.<sup>[15]</sup> Ki-67 is a marker of cell proliferative activity. A high Ki-67 index indicates increased proliferation of tumor cells and may correlate with an aggressive course of the disease. Studies have shown that a high level of Ki-67 expression is associated with an unfavorable prognosis in patients with gastric adenocarcinoma.<sup>[35]</sup> Tumor suppressor protein (p53), mutations of which are often found in various malignancies, including gastric cancer. Disturbances in the TP53 gene lead to dysfunction of the p53 protein, which contributes to uncontrolled cell proliferation. Detection of TP53 mutations may have prognostic value and influence the choice of treatment tactics.<sup>[20]</sup>

MUC2 and MUC5AC are mucins whose expression may vary depending on the type of adenocarcinoma. MUC2 is usually associated with the intestinal type of adenocarcinoma, while MUC5AC is associated with the diffuse type. Determination of the expression profile of mucins can help in the classification of tumors and prediction of their behavior.<sup>[17]</sup>

PD-L1 is a programmed death ligand, the expression of which on tumor cells can suppress the immune response. Determination of the PD-L1 level is used to assess the potential efficacy of PD-1/PD-L1 inhibitor therapy. A positive result is defined as a combined positivity score (CPS)  $\geq 1$ .<sup>[25]</sup>

Molecular subtypes according to the classification of The Cancer Genome Atlas (TCGA) include: CIN (chromosomal instability): characterized by chromosomal instability and often associated with HER2 amplification. Virus positive: associated with Epstein-

Barr virus infection and frequently exhibits hypermethylation.<sup>[33]</sup> Microsatellite instability (MSI): characterized by a high mutation rate and a deficiency in the DNA repair system. Genomically stable: does not exhibit overt chromosomal instability or MSI.<sup>[33]</sup>

Promising markers such as Claudin 18.2, FGFR2 and VEGFR are under investigation. Claudin 18.2 is a component of tight junctions between gastric epithelial cells and its expression in tumor cells makes it an attractive target for targeted therapy.<sup>[29]</sup> FGFR2 (fibroblast growth factor receptor 2) and VEGFR (vascular endothelial growth factor receptor) are involved in angiogenesis and cell proliferation processes,

and their overexpression may promote aggressive tumor growth.<sup>[34]</sup>

### Instrumental and laboratory diagnostics of cardioesophageal cancer

To objectively evaluate the diagnostic utility of various approaches for cardioesophageal cancer, a comparative analysis was performed examining the sensitivity, specificity, and overall diagnostic accuracy of principal diagnostic methods. The findings are presented in a summarized table, accompanied by a clinical and diagnostic commentary informed by data from published literature.

**Table 1: Comparative assessment of the effectiveness of instrumental and laboratory diagnostic methods for cardioesophageal cancer.**

Diagnostic method	Sensitivity (%)	Specificity (%)	Diagnostic accuracy (%)	Source
Endoscopy with NBI	88,4	95	93	Koshelev D.S., 2017
Chromoendoscopy	87	83	85	Shavrov V.A., 2017
EUS	88,8	89,5	89,3	Kruglova I.I., 2010
PET-CT	85	88	86,5	Kruglova I.I., 2010
Liquid biopsy	70	>95	82,5	Virko M., 2024; Imyanitov et al., 2017

Narrow Band Imaging (NBI) endoscopy demonstrates high sensitivity (88.4%) and particularly high specificity (95%) in detecting intraepithelial neoplasia and early cancer in the CEJ area.<sup>[6]</sup> The method allows visualization of subepithelial vascular networks and microarchitecture of the mucosa without the use of dyes, which minimizes the subjectivity of interpretation.

Chromoendoscopy, on the contrary, requires the introduction of contrast agents (e.g. Lugol's solution, indigo carmine), which somewhat increases the invasiveness and duration of the procedure. However, the sensitivity of the method remains high (87%), with a specificity of 83%.<sup>[13]</sup> In clinical practice, the combined use of NBI and chromoscopy is recommended, which increases reproducibility and reduces the likelihood of missing small foci of neoplasia.

Endoscopic ultrasonography (EUS) examination provides the highest accuracy in determining the depth of tumor invasion (T-stage), especially in lesions of the mucosal and submucosal levels. The sensitivity of the method reaches 88.8%, specificity 89.5%, overall accuracy 89.3%.<sup>[7]</sup> Compared to CT and MRI, EUS provides an advantage in morphological detailing of the organ wall and is the method of choice for preoperative evaluation of tumors.

Positron emission tomography combined with CT allows not only to visualize metastases, but also to assess the metabolic activity of the tumor (SUVmax). At the same

time, the sensitivity and specificity of the method for staging M (metastasis) vary within 85% and 88%, respectively.<sup>[7]</sup> However, PET-CT has limited effectiveness in detecting peritoneal implants <5 mm and can give false negative results with low tumor metabolism.

Liquid biopsy is the youngest, but rapidly developing diagnostic method. Despite lower sensitivity (70%) in early forms of CEJ cancers, it has high specificity (>95%) and provides unique opportunities to follow up of the tumor molecular profile without the need for repeated invasive interventions.<sup>[2,22]</sup> Liquid biopsy is especially valuable in cases of suspected micrometastatic disease and progression after targeted therapy.

Each method has its own strengths, and their choice should be determined by the clinical scenario. NBI and chromoscopy are leaders in early detection of neoplasms; EUS is optimal for local staging; PET-CT for assessing systemic spread; liquid biopsy for molecular monitoring. The best diagnostic results are achieved with a multimodal approach, when each method complements the others.

### Interpretation of prognostic and predictive factors in cardioesophageal zone cancer

Analysis of factors influencing prognosis and therapy effectiveness in CEJ cancers requires dividing parameters into prognostic (determine the natural course of the disease) and predictive (predict the response to a



specific type of treatment). Below is a detailed discussion of both.

**Table 2: Comparative characteristics of prognostic and predictive factors.**

Factor	Prognostic value	Predictive value	Source
<b>Differentiation grade</b>	Low grade of differentiation worsens prognosis	None	Stilidi I.S., 2007
<b>Invasion grade (T)</b>	Deep invasion reduces survival	None	RUSSCO, 2018
<b>Lymph node status (N)</b>	More nodes reduce the prognosis	None	RUSSCO, 2020
<b>HER2-positive</b>	Ambiguous	Efficacy of trastuzumab in the presence of HER2 amplification	Karnaukhov N.S., 2022
<b>PD-L1 expression</b>	Controversial	Potential predictor of response to immunotherapy	Danilova N.V., 2022
<b>MSI-status</b>	Improves prognosis	High efficacy of immunotherapy for MSI-H	Fedyanin M.Y. et al., 2012
<b>Lymphocytic infiltration</b>	Positive impact on survival	None	Stilidi I.S., 2007
<b>CAFs (stromal fibroblasts)</b>	Associated with invasion and worse prognosis	None	Stilidi I.S., 2007

As can be seen from Table 2, poorly differentiated gastric cancers demonstrate higher aggressiveness, a tendency to invasion and metastasis, which negatively affects overall and disease-free survival.<sup>[10]</sup> However, this factor does not predict sensitivity to specific methods of therapy, and therefore is not predictive. The depth of tumor invasion (according to the TNM system) is one of the most reliable prognostic factors: invasion beyond the submucosal layer (T2 and above) sharply reduces five-year survival.<sup>[8]</sup> However, this factor does not indicate a preference for a particular type of therapy, and, therefore, does not play a predictive role. The number and level of damage to regional lymph nodes (N) correlate with the likelihood of distant metastasis and the prognosis of overall survival.<sup>[1]</sup> The higher the N stage, the worse the prognosis. At the same time, the status of the lymph nodes does not directly affect the choice of therapy, with the exception of recommendations for the volume of lymph node dissection.

HER2 positivity is determined in 10–20% of cases, more often in the intestinal type of tumor and proximal localization.<sup>[5]</sup> Although the prognostic role of HER2 is controversial (some studies show a worse prognosis, others - no effect), its predictive value is unambiguous: the presence of HER2 amplification predicts a positive effect from the use of trastuzumab. The expression of PD-L1 on tumor and immune cells can be associated with the presence of a response to immune drugs (PD-1/PD-L1 inhibitors), especially with a high CPS  $\geq 1$ .<sup>[19]</sup> At the same time, the prognostic role of PD-L1 remains debatable: some authors indicate an association with an aggressive biology, others - the lack of a significant correlation. Microsatellite instability (MSI) is detected in

10–20% of patients and is associated with a favorable prognosis, a lower incidence of lymph node metastasis, and a better response to immunotherapy.<sup>[12]</sup> Thus, MSI has both prognostic and predictive value. The presence of dense lymphocytic infiltration indicates a more pronounced antitumor immune response and is associated with increased survival.<sup>[10]</sup> However, a direct relationship with the response to therapy, in particular to immunotherapy, has not been established to date. Tumor-stromal fibroblasts enhance invasiveness and angiogenesis, forming an unfavorable microenvironment. Their presence is a prognostically unfavorable factor, but has no predictive value yet. Morphological regression of the tumor after chemotherapy reliably correlates with an increase in overall and disease-free survival.<sup>[10]</sup> However, this is a retrospective prognostic marker, not a predictive one - it is not used to select therapy before it is started.

## CONCLUSION

The cardioesophageal junction is an anatomically and functionally unique area characterized by histological and pathogenetic heterogeneity, which directly affects approaches to diagnostics, classification and treatment of tumors of this localization. The morphological distinctiveness of the junction between the stratified squamous epithelium of the esophagus and the simple columnar epithelium of the stomach underlies the development of various precancerous conditions. Among these, Barrett's esophagus—characterized by metaplastic transformation of the esophageal epithelium—plays a central role as a precursor to esophageal adenocarcinoma.

Features of the biological behavior of CEJ tumors are

correlates not only with their morphological subtype, but also with their anatomical position relative to the Z line, the main mark of the Siewert classification, which has both diagnostic and therapeutic significance. Morphological verification with determination of the grade of differentiation, nature of invasion and stromal component allows stratifying patients by the risk of progression and survival, as well as choosing the optimal treatment tactics. The importance of biopsy material as a primary source of morphological information requires standardized approaches to collection and interpretation of histological data, especially in the presence of infiltrative or submucosal tumor growth.

The widespread introduction of immunohistochemical and molecular markers, including CK7, CDX2, HER2, Ki-67, p53 and PD-L1, has not only deepened our understanding of the pathogenesis of CEJ tumors, but also opened up prospects for personalized therapy. Biomarkers such as HER2 and MSI have demonstrated clinically significant predictive value, while TME markers - lymphocytic infiltration and CAFs - are becoming increasingly important in the prognostic aspect.

Instrumental methods, including NBI endoscopy, chromoscopy, endosonography and PET-CT, in combination with liquid biopsy and digital pathology, form the basis of a multimodal diagnostic algorithm. The choice of method should be based on the clinical task: from early detection of neoplasia to assessment of invasion and metastasis. Thus, an integrative approach combining anatomical and morphological data, molecular characteristics of the tumor and modern diagnostic technologies are basis for prognostic stratification and individualization of therapy for patients with cardioesophageal cancer.

#### **Funding**

There was no funding from any other parties.

#### **Authors' contribution**

All authors have contributed to the manuscript equally, have read and approved the final manuscript to publication. Each author agrees to be held accountable for all aspects of the research.

*All authors declare no competing interests*

#### **REFERENCE**

1. Association of Oncologists of Russia. Clinical guidelines for the diagnosis and treatment of gastric cancer, 2020.
2. Virko M. (2024). Liquid biopsy: a safe and reliable method for diagnosing, monitoring and selecting cancer therapy. *MedconsOnline*.
3. Gagaev R.A. Clinical observations of endoscopic diagnosis and treatment of early signet ring cell gastric cancer. *Endoscopic surgery*, 2017; 23(3): 50-54.
4. Davydov M.I., Turkin I.N., Stilidi I.S., et al. Cardioesophageal cancer: classification, surgical tactics, main prognostic factors. *Bulletin of the Russian Oncological Research Center named after N.N. Blokhin, Russian Academy of Medical Sciences*, 2003; 14(3):82-87.
5. Karnaukhov N.S. HER2-positive gastric cancer: current state of the problem. *Oncology. Journal im. N.N. Blokhin*, 2022; 28(2): 63–72.
6. Koshelev D.S. Confocal laser endomicroscopy in diagnostics of upper gastrointestinal tract diseases. Abstract of PhD thesis. Moscow 2017.
7. Kruglova I.I. Possibilities of endosonography in clarifying diagnostics of gastric cancer. *Creative surgery and oncology*, 2010; 1: 38–40.
8. Russian Society of Clinical Oncology (RUSSCO). 2018. Gastric cancer. Clinical guidelines.
9. Starinsky V.V., Petrova G.V., Mikhailova S.A. Malignant neoplasms in Russia in 2012 (incidence and mortality). Moscow: Federal State Budgetary Institution "P.A. Herzen Moscow Oncology Research Institute" of the Ministry of Health of the Russian Federation, 2014.
10. Stilidi I.S. et al. Modern approaches to the diagnosis and treatment of gastric cancer. *Grekov Surgery Bulletin*, 2007; 4: 5–14.
11. Tillyashaykhov M.N., Ibragimov Sh.N., Dzhanlich S.M. The state of oncological care for the population of the Republic of Uzbekistan in 2022. — 2023; 4–182.
12. Fedyanin M.Yu., Tryakin A.A., Tyulyanin S.A. Microsatellite instability as a prognostic factor and predictor of sensitivity to therapy. *Oncology*, 2012; 14(2): 18–26.
13. Shavrov V.A. Confocal laser endomicroscopy in diagnostics of gastrointestinal diseases. *Rus. journal of gastroenterology, hepatology, proctology*, 2016; 26(5): 52–58.
14. Agrawal N., Jiao Y., Bettegowda C., et al. Comparative genomic analysis of esophageal adenocarcinoma and squamous cell carcinoma. *Cancer Discov*, 2012; 2(10): 899-905.
15. Bang Y.J., Van Cutsem E., Feyereislova A., et al. Trastuzumab in combination with chemotherapy versus chemotherapy alone for treatment of HER2-positive advanced gastric or gastro-oesophageal junction cancer (ToGA): a phase 3, open-label, randomised controlled trial. *The Lancet*, 2010; 376(9742): 687–697.
16. Barrett T., Tong T., French C.A., et al. Expression of CDX2 in normal and malignant human tissues. *Modern Pathology*, 2002; 15(9): 958–964.
17. Bartman A.E., Sanderson S.J., Ewing S.L., et al. Aberrant expression of MUC5AC and MUC2 in colorectal polyps. *International Journal of Cancer*, 1999; 80(2): 210–218.
18. Cunningham D., Allum W.H., Stenning S.P., et al. Perioperative chemotherapy versus surgery alone for resectable gastroesophageal cancer. *New England Journal of Medicine*, 2013; 355(1): 11–20.

19. Danilova N.V. Экспрессия PD-L1 в опухолях желудка: роль в прогнозировании и выборе терапии. *Онкология*, 2022; 24(1): 45–52.
20. Hollstein M., Sidransky D., Vogelstein B., et al. 53 mutations in human cancers. *Science*, 1991; 253(5015): 49–53.
21. IARC Working Group on the Evaluation of Carcinogenic Risks to Humans. Personal habits and indoor combustions. Volume 100E. A review of human carcinogens. IARC Monogr Eval Carcinog Risks Hum, 2012; 100(Pt E): 373–472.
22. Imyanitov E.N., Kuligina E., Yanus G.A. The role of liquid biopsy in cancer diagnostics and treatment. *Practical Oncology*, 2017; 18(2): 92–101.
23. Kubo A., Corley D.A., Mark D., et al. Body mass index and adenocarcinomas of the esophagus or gastric cardia: a systematic review and meta-analysis. *Cancer Epidemiol Biomarkers Prev.*, 2006; 15(5): 872–878.
24. Lordick F., Mariette C., Haustermans K., et al. Oesophageal cancer: ESMO Clinical Practice Guidelines for diagnosis, treatment and follow-up. *Ann Oncol*, 2016; 27(5): 50–57.
25. Muro K., Chung H.C., Shankaran V., et al. Pembrolizumab for patients with PD-L1–positive advanced gastric cancer (KEYNOTE-012): a multicentre, open-label, phase 1b trial. *The Lancet Oncology*, 2016; 17(6): 717–726.
26. Park S.Y., Kim H.S., Hong E.K., et al. Expression of cytokeratins 7 and 20 in primary carcinomas of the stomach and colorectum. *Human Pathology*, 2007; 38(5): 653–659.
27. Pohl H., Welch H.G. The role of overdiagnosis and reclassification in the marked increase of esophageal adenocarcinoma incidence. *J Natl Cancer Inst*, 2005; 97(2): 142–146.
28. Rustgi A.K., El-Serag H.B. Esophageal carcinoma. *N Engl J Med.*, 2014; 371(26): 2499–2509.
29. Sahin U., Koslowski M., Dhaene K., et al. Claudin-18 splice variant 2 is a pan-cancer target suitable for therapeutic antibody development. *Clinical Cancer Research*, 2008; 14(23): 7624–7634.
30. Siewert J.R., et al. Classification of adenocarcinoma of the oesophagogastric junction. *Br J Surg*, 2000; 87(11): 1457–1464.
31. Spechler S.J. Barrett's esophagus. *N Engl J Med.*, 2002; 346(11): 836–842.
32. Stachura J., Orłowska J., Celiński K., et al. The microanatomy of the esophagogastric junction area and its possible implications for the pathogenesis of gastroesophageal reflux disease. *Pol J Pathol*, 2001; 52(1): 23–28.
33. The Cancer Genome Atlas Research Network. Comprehensive molecular characterization of gastric adenocarcinoma. *Nature*, 2014; 513(7517): 202–209.
34. Turner N., Grose R. Fibroblast growth factor signalling: from development to cancer. *Nature Reviews Cancer*, 2010; 10(2): 116–129.
35. Ueno H., Mochizuki H., Hashiguchi Y., et al. Prognostic significance of Ki-67 expression in rectal cancer treated with preoperative radiotherapy. *Diseases of the Colon & Rectum*, 2002; 45(5): 627–632.