

**INTRAPERITONEAL BLADDER RUPTURE FOLLOWING A BLUNT TRAUMA: A
CASE REPORT**

Nachid A., Safwate R., Tmiri A.*, Moumen O., Kbirou A., Moataz A., Dakir M., Debbagh A. and Aboutaieb R.

Department of Urology, University Hospital Center Ibn Rochd, Casablanca, Morocco.



*Corresponding Author: Tmiri A.

Department of Urology, University Hospital Center Ibn Rochd, Casablanca, Morocco.

Article Received on 12/03/2025

Article Revised on 02/04/2025

Article Accepted on 22/04/2025

ABSTRACT

Intraperitoneal bladder rupture is a rare consequence of blunt abdominal trauma, often associated with high-impact injuries. We report the case of a 47-year-old male involved in a high-speed car collision, presenting with abdominal pain, hematuria, and peritoneal signs. Imaging revealed a 12 mm defect in the superior bladder wall with intraperitoneal contrast leakage, but no associated pelvic fractures or solid organ injury. Emergency surgical repair was performed with a favorable outcome. This case underscores the importance of considering bladder rupture in trauma patients with abdominal pain and hematuria, even in the absence of pelvic fractures.

KEYWORDS: Bladder, rupture, urinary, rupture.**INTRODUCTION**

Urinary bladder rupture entered the literature as early as 1826 when the London Medical and Physical Journal published two cases in the setting of blunt abdominal trauma.^[1]

One patient suffered multiple trauma after a collapsing load of construction rubble buried him. Another patient sustained a bladder rupture from a lower abdominal blow with a fence post during an intoxicated foot race.

Today, bladder injuries remain relatively uncommon, representing only 0.36% of all blunt abdominal trauma admissions in a study of 15,168 patients.^[2]

Patients with bladder injury often present following motor vehicle collisions with suprapubic pain and gross hematuria. On examination, they can exhibit classic, yet nonspecific peritoneal signs that warrant further workup. Although bladder contusion is a common injury that may be treated non-operatively, full thickness bladder rupture should be considered in the differential diagnosis as a potential surgical emergency. Signs that raise the index of suspicion for bladder rupture include gross hematuria, pelvic fracture, acute kidney injury, and little to no urine output with catheterization.^[3]

Bladder ruptures can be intraperitoneal, extraperitoneal, or both. Intraperitoneal ruptures which comprises 15% of all bladder ruptures are associated with severe blunt force trauma to a distended bladder. These injuries often occur across the bladder dome where the wall is mobile, attenuated and predisposed to balloon out. Fortunately,

intraperitoneal lacerations are amenable to surgical repair with success rates at 100 percent in several case series.^[4,5] Extraperitoneal ruptures are more common (80% of cases), generally occur in the setting of pelvic fracture, and involve the anterolateral bladder wall, trigone, and bladder neck. A minority of patients have combined intraperitoneal and extraperitoneal injury (5% of cases). Although some complex extraperitoneal ruptures are surgically repaired, the literature currently suggests that most extraperitoneal ruptures can be non-operatively managed.^[6]

Herein, we present a case of isolated intraperitoneal bladder rupture following a car collision. Surgical management will be discussed in context of recent clinical practice guidelines for bladder rupture from the EAU Trauma Guidelines.^[7]

PRESENTATION OF THE CASE

A 47-year-old man presented to the emergency department following a car collision in which he was the seatbelt-restrained driver. Airbags deployed when her vehicle hit another car at a high speed with craniofacial and abdominopelvic impact. Emergency medical services arrived at the scene and transported him to the Trauma Center of CASABLANCA.

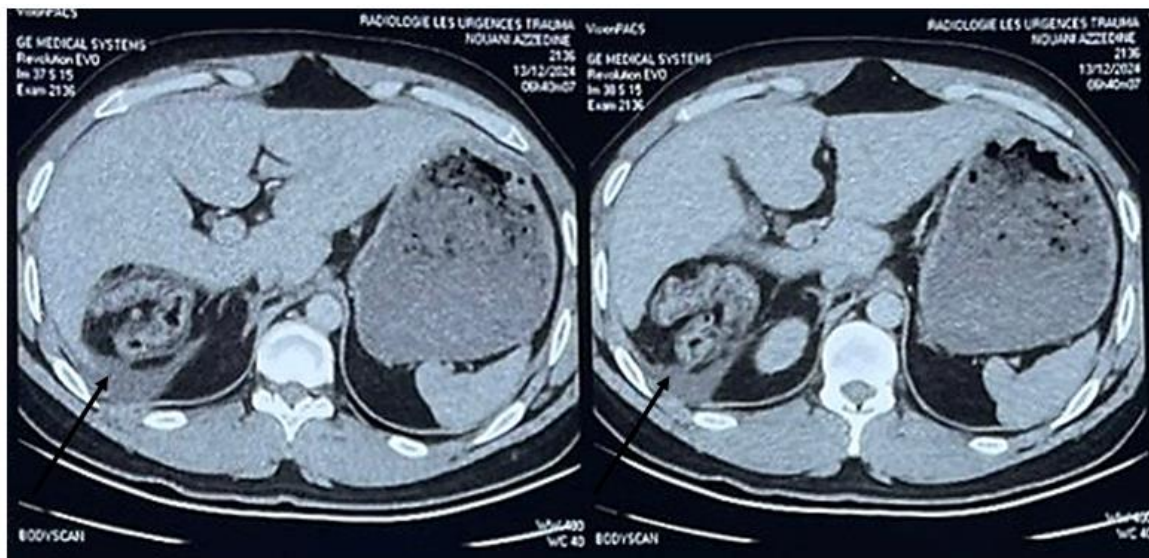
Upon arrival as a Trauma Alert, he was in severe abdominal and flank pain. He appeared lethargic and confused, the head trauma did not cause any loss of consciousness or neurological symptoms. He was afebrile but tachycardic, with normal blood pressure.

His abdomen was distended and guarded with rebound tenderness. There was frank blood at the urethral orifice. Plain radiographs of the pelvis revealed no evidence of fracture.

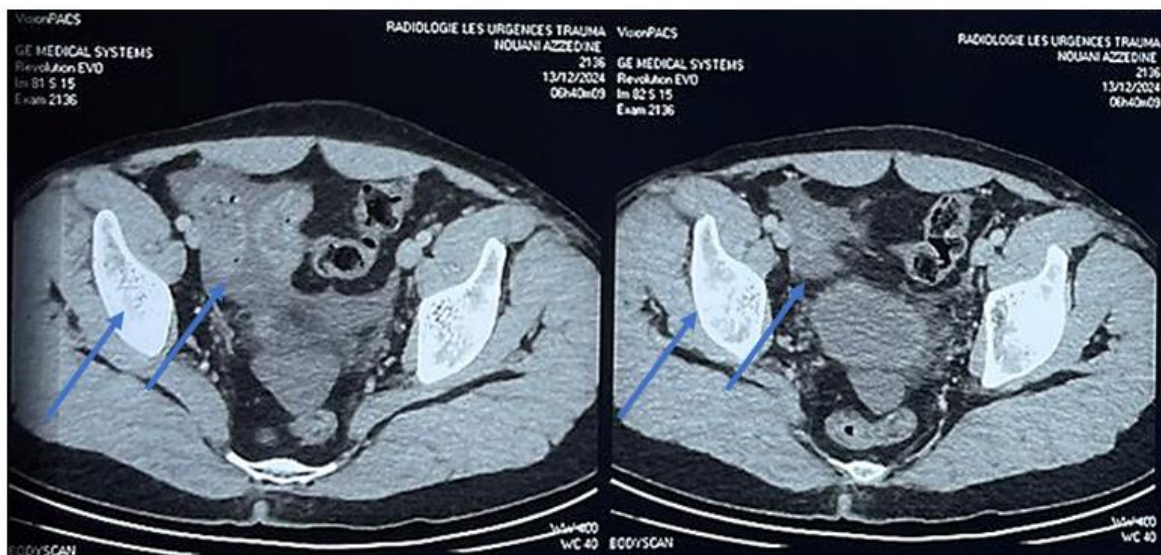
Laboratory data were significant for a hemoglobin of 12.0 mg/dL, leukocytosis of 13.2×10^3 WBC/ L, and elevated serum creatinine of 1.79 mg/dL.

Brain CT showed no evidence of acute trauma. CT urogram showed no evidence of acute trauma of the

liver, spleen, pancreas, kidneys and adrenal glands, but revealed a moderate abundance peritoneal effusion within the abdomen and pelvis (Fig. 1), infiltration of the pelvic fat in the peri-vesical area and leakage of the contrast agent at the excretory phase through a defect in the vesical wall (Fig. 2), located in the superior wall of the bladder, approximately 12 mm in diameter with no leakage of the contrast through the ureters.



A.



B.

Fig. 1: A: CT abdomen showing simple fluid density (urine) in perihepatic space and hepatorenal fossa. B: CT pelvis showing simple fluid density (urine) surrounding the bladder.

Trauma surgery then performed an emergent exploratory laparotomy and found a full-thickness rupture across the bladder dome (Fig. 3). Approximately one liter of clear urine was drained from the abdomen. The bladder was repaired in two layers with absorbable sutures and a

bladder catheter was left in place. The bladder repair was then tested intraoperatively by filling the bladder with fluid via the bladder catheter until the bladder distended and no leak was observed.

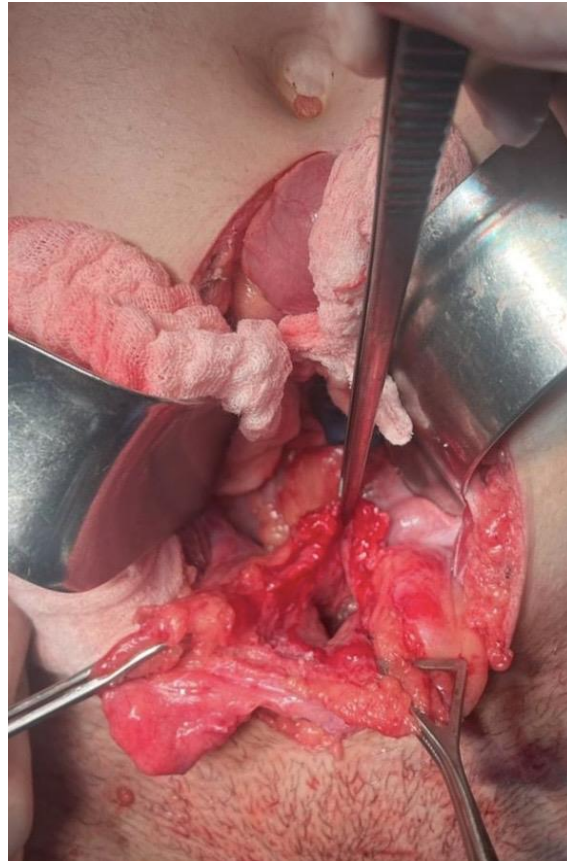


Fig. 3.

Intraoperative view of low midline laparotomy showing ruptured bladder dome. (Ruptured bladder wall held with Duval forceps)

On postoperative day one and two, he was in stable condition. Laboratory data showed his leukocytosis normalized as did his serum creatinine.

He continued to recover well, advancing to a regular diet on post-operative day two with her pain well controlled.

By postoperative day three, hematuria resolved, he was discharged that day with instructions to keep the bladder catheter in place for seven more days. Follow up in the out-patient clinic the following week, showed he was without complications; and the indwelling catheter was removed without incident.

DISCUSSION

Our patient was a seatbelt-restrained driver who suffered an intraperitoneal bladder rupture in the absence of pelvic fracture.

Intraperitoneal injuries generally follow blunt force compression of a large, distended bladder positioned at the posterior aspect of the ventral abdominal wall and superior to the protection afforded by the bony pelvis.

With respect to motor vehicle collisions, deceleration against seatbelt restraints represent a common injury

mechanism. In these cases, the weak and mobile bladder dome ruptures, and remaining forces distribute throughout the abdomen, often causing multiorgan injury.

Management of intraperitoneal bladder rupture hinges on early recognition and surgical intervention. While extraperitoneal ruptures can generally be managed non-operatively with a bladder catheter, guidelines from both the American Urologic Association (AUA) and the European Association of Urology (EAU) advocate for surgical repair of intraperitoneal lacerations.^[7,9]

Free urine in the abdomen and pelvis leads to acute renal failure and sepsis, which is responsible for mortality rates over 20% when not promptly identified.^[10]

Several imaging studies can provide evidence to raise the index of suspicion for bladder rupture. Sonographic scans can identify free fluid in the pelvis^[11], but are unreliable in distinguishing between fluids like urine, blood or succus. Non-contrast CT scans can identify simple fluid ascites, but often cannot identify a laceration on the bladder itself.^[12] Both plain film cystography and CT urogram are highly sensitive and specific studies available for the diagnosis or exclusion of bladder rupture, as in our case and others in the literature.^[13,14] CT urogram may be preferred in the setting of trauma where spine boards and fragments of pelvic fractures may mask bladder injury under fluoroscopy.

Nonetheless, the additional time needed, summative radiation exposure, and financial burden of CT urogram may not be appropriate in unstable patients and those with acute abdomen and free intraperitoneal fluid who already require laparotomy for other concurrent intra-abdominal injuries.

Operative repair can be performed by trauma surgery or urology. One retrospective study from South Africa noted that their trauma service repaired all intraperitoneal bladder ruptures except those complicated by concomitant extraperitoneal rupture and complex pelvic injury, in which case they consulted a urologic surgeon for support.^[15] Laparotomy is generally preferred when there is concern for multi-organ trauma, but reports and case series have demonstrated excellent outcomes with laparoscopic repair.^[16,17] One or two-layered closure of the dome is accomplished with absorbable sutures. Permanent sutures represent a potential nidus for calcium deposition and future bladder stone formation.^[18]

Postoperative cystography can identify leaks in the repaired bladder wall, but studies have shown it is often unnecessary.^[5,19]

Postoperative hospital care is focused on monitoring urine output and maintenance of an unclogged and free flowing indwelling bladder catheter to prevent catheter-associated urinary tract infections (CAUTI's).

On postoperative day one the patient's urine output was over 4 liters. This is likely due to "post obstructive polyuria" as a normal physiologic response to eliminate volume and solutes that accumulated. Bladder catheter maintenance is crucial to prevent CAUTI's, especially with the highly susceptible patient population seen in trauma and critical care settings.^[20] Antibiotic prophylaxis can reduce the incidence of CAUTI's throughout the duration of an indwelling catheter^[21], but further precautions are necessary. Nursing education for proper bladder bag placement and twice-daily perineal care reduces CAUTI's as much as 70% in trauma patients.^[22] On discharge, patients are instructed to continue these measures until one-week outpatient follow up.

CONCLUSION

We present a case of a 47-year-old man with intraperitoneal bladder rupture in the setting of a blunt traumatic seatbelt injury. Our patient recovered uneventfully after surgical repair, a three-day hospitalization, and ten days with an indwelling bladder catheter. Recently developed clinical practice guidelines reaffirm the significance of surgical repair for intraperitoneal injuries.

Postoperative care is focused on preventing catheter-associated urinary tract infections.

Conflicts of interest: none.

Funding: None.

REFERENCES

1. R. McLeod, Fracture of the pelvis and rupture of the bladder; Rupture of the bladder from a blow, Lond. Med. Phys. J., 1827; 5: 417–420.
2. K.A. Matlock, A.H. Tyroch, Z.N. Kronfol, S.F. McLean, M.A. Pirela-Cruz, Blunt traumatic bladder rupture: a 10-year perspective, Am. Surg. June 6, 2013; 79: 589–593 [PMID: 23711268].
3. I. Guttman, H.A. Kerr, Blunt bladder injury, Clin. Sports Med., April 2, 2013; 32: 239–246 [PMID: 23522505].
4. J.N. Corriere Jr, C.M. Sandler, Management of the ruptured bladder: seven years of experience with 111 cases, J. Trauma, September 9, 1986; 26: 830–833 [PMID: 3746959].
5. K. Inaba, M. McKenney, F. Munera, et al., Cystogram follow-up in the management of traumatic bladder disruption, J Trauma, January 1, 2006; 60: 23–28 [PMID: 16456432].
6. B. Phillips, S. Holzmer, L. Turco, et al., Trauma to the bladder and ureter: a review of diagnosis, management, and prognosis, Eur. J.Trauma Emerg. Surg. December 6, 2017; 43: 763–773 [PMID: 28730297].
7. Lumen N, Kuehhas FE, Djakovic N, Kitrey ND, Serafetinidis E, Sharma DM, et al. Review of the current management of lower urinary tract injuries by the EAU Trauma Guidelines Panel. Eur Urol., 2015; 67(5): 925–9.
8. R.A. Agha, A.J. Fowler, A. Saeta, (SCARE Group), et al., The SCARE statement: consensus-based surgical case report guidelines, Int. J. Surg., 2016; 34: 180–186 [PMID: 27613565].
9. A.F. Morey, S. Brandes, D.D. Dugi 3rd, et al., Urotrauma: AUA guideline, J. Urol., August 2, 2014; 192: 327–335 [PMID: 24857651].
10. H.A. Ridinger, R.T. Kavitt, J.K. Green, Urinary ascites and renal failure from unrecognized bladder rupture, Am. J. Med., September 9, 2012; 125: e1–2 [PMID: 22748402].
11. K. Bain, V. Kassapidis, V. Meytes, G. Glinik, FAST examination diagnosing bladder rupture following blunt pelvic trauma, BMJ Case Rep., September, 2018; 2018: 2017-223933. [PMID: 29563130].
12. W. Landman, B. Khurana, A. Briggs, et al., BWH emergency radiology-surgical correlation: intraperitoneal urinary bladder rupture, Emerg. Radiol., December 6, 2015; 22: 713–716 [PMID: 25998022].
13. J.P. Vaccaro, J.M. Brody, CT cystography in the evaluation of major bladder trauma, Radiographics, September-October 5, 2000; 20: 1373–1381 [PMID:10992026].
14. P.V. Quagliano, S.M. Delair, A.K. Malhotra, Diagnosis of blunt bladder injury: a prospective comparative study of computed tomography

- cystography and conventional retrograde cystography, *J. Trauma*, August 2, 2006; 61: 410–421. [PMID: 16917459].
15. R.J. Urry, D.L. Clarke, J.L. Bruce, G.L. Laing, The incidence, spectrum and outcomes of Traumatic bladder injuries within the Pietermaritzburg Metropolitan Trauma Service, *Injury*, May 5, 2016; 47: 1057–1063. [PMID:26854075].
 16. D. Mortelmans, N. Messaoudi, J. Jaekers, et al., Laparoscopic repair of intraperitoneal bladder rupture after blunt abdominal trauma, *Urol. J.*, (March 1, 2014; 11: 1338–1340. [PMID: 24595949].
 17. F.J. Kim, M.F. Chammas Jr, E.V. Gewehr, A. Campagna, E.E. Moore, Laparoscopic management of intraperitoneal bladder rupture secondary to blunt abdominal trauma using intracorporeal single layer suturing technique, *J. Trauma.*, July 1, 2008; 65: 234–236. [PMID: 18580538].
 18. H. Jang, E.K. Park, D.S. Han, C.J. Kim, Y.S. Lee, Bladder stone formation on permanent suture material ten years after laparoscopic high uterosacral ligament suspension, *Clin. Exp. Obstet. Gynecol.*, 2017; 44(3): 472–474. [PMID: 29949298].
 19. K. Inaba, O.T. Okoye, T. Browder, et al., Prospective evaluation of the utility of routine postoperative cystogram after traumatic bladder injury, *J. Trauma Acute Care Surg.*, December 6, 2013; 75: 1019–1023. [PMID: 24256676].
 20. B. Shaver, S.A. Eyerly-Webb, Z. Gibney, et al., Trauma and intensive care nursing knowledge and attitude of Foley catheter insertion and maintenance, *J. Trauma Nurs.*, January/February 1, 2018; 25: 66–72. [PMID: 29319654].
 21. R.G. Gomez, L. Ceballos, M. Coburn, et al., Consensus statement on bladder injuries, *BJU Int.*, July 1, 2004; 94: 27–32. [PMID: 15217426].
 22. A. Elkbuli, A. Miller, D. Boneva, et al., Targeting catheter-associated urinary tract infections in a trauma population: a 5-S bundle preventive approach, *J Trauma Nurs.*, November/December 6, 2018; 25: 366–373. [PMID: 30395037].