

**THE CRANIO-ORBITAL SURGICAL APPROACH FOR TUMOURS OF THE ORBIT
AND ANTERIOR SKULL BASE****Dr. Jaspreet Singh Badwal***

MDS Oral and Maxillofacial Surgery, Recently Resigned from Civil Hospital Dhuri, District Sangrur, Punjab.

***Correspondence for Author: Dr. Jaspreet Singh Badwal**

MDS Oral and Maxillofacial Surgery, Recently Resigned from Civil Hospital Dhuri, District Sangrur, Punjab.

Article Received on 28/02/2016

Article Revised on 19/03/2016

Article Accepted on 10/04/2016

ABSTRACT

The cranio-orbital approaches have been successfully employed for resection of tumours involving the orbit and anterior skull base. With modifications of the cranio-orbital bone flap (changing the position and size of the flap), incorporation of posterior orbitotomy or zygomatic osteotomy, the cranio-orbital approaches can be specifically tailored to optimize the access to tumours located in a variety of locations.

KEYWORDS: Cranio-orbital approach, tumours orbit, anterior skull base surgery.**INTRODUCTION**

The cranio-orbital approaches have been successfully employed for resection of tumours involving the orbit and anterior skull base. These frontolateral approaches incorporate the orbital roof and provide greater access to tumours of the orbit and cribriform plate. With modifications of the cranio-orbital bone flap (changing the position and size of the flap), incorporation of posterior orbitotomy or zygomatic osteotomy, the cranio-orbital approaches can be specifically tailored to optimize the access to tumours located in a variety of locations (Anand VK, 1998).¹ It is pertinent to mention that like many other approaches in skull base surgery, these approaches require a team of surgeons comprising of maxillofacial / craniomaxillofacial surgeon, neurosurgeon and otolaryngologic surgeon. The benign tumours afflicting these areas mostly include meningiomas, neurilemmomas, and a variety of orbital tumours.

The cranio-orbital approach with its various modifications, may be classified as below:^[1]

1. Supraorbital approach
2. Supraorbital-pterional approach
3. Superolateral cranio-orbital approach
4. Cranio-orbital zygomatic approach

The following discussion will provide a description of these various modifications.

A. The Supraorbital Approach^[2]

The patient is placed supine on the table. Lumbar drains are placed for controlled withdrawal of cerebrospinal fluid (CSF). The head is fixed in a Mayfield head rest.

A bicoronal incision is made behind the hairline and the scalp flap is retracted. The line of incision extends from the level of zygomatic arch on the operated side to the superior temporal line on contralateral side. The superior temporal artery and frontalis branches of facial nerve are preserved through intrafacial dissection. Subsequently, the temporalis muscle is detached from its insertion anteriorly, to as far as the zygomatic arch. This muscle is then retracted posteriorly to expose the junction of zygomatic, frontal and sphenoidal bones. Thenceforth, the periosteum of frontal bone is incised posteriorly, dissected forward, and retracted over the anteriorly turned scalp flap. The intact base of this periosteum is then dissected free from the roof and lateral wall of orbit. A high speed air drill is used around the supraorbital notch to free the supraorbital nerve.

To raise the osteotomy bone flap, two burr holes are drilled (Fig. 1). The first is the MacCarty's keyhole, which is made in the temporal fossa at the fronto-sphenoidal junction, just behind the zygomatic process of frontal bone. While the hole is drilled, its upper half exposes the dura mater and the lower half exposes the periorbita, the two membranes being separated by the roof of the orbit. The second hole is made in the frontal bone superior to the nasion. To keep it as small as possible, for postoperative aesthetics, this hole is made with a high speed drill such as the Midas Rex. In adults, this hole would invariably pass through the anterior and posterior walls of the frontal sinus. The mucosa lining the sinus cavity is exenterated, and the posterior wall removed (cranialization). The sinus is then plugged with muscle or fat. All instruments exposed to the frontal sinus are removed and re-sterilized, and the surgical attire replaced.

The two holes are joined by two bony cuts. The first cut is made with a high speed drill, which passes through the frontal bone about 4 cm. above the superior orbital rim. The second cut extends from the anterior burr hole, inferiorly and laterally, towards the supraorbital foramen, lateral to the trochlear groove. It then passes laterally through the orbital roof, and then directed inferolaterally towards the lateral margin, finally meets the second burr hole.

During this process, the orbital contents are protected with a brain spatula. Particular attention must be paid to keeping the periorbita intact. All attempts should be made to avoid injury to the supraorbital nerve and the trochlear attachment of the superior oblique muscle. The removed and preserved craniotomy flap thus includes the upper half of the lateral orbital rim, the anterior portion of orbital roof and the adjacent frontal bone.

The supraorbital approach can be incorporated into a bifrontal bone flap (Fig. 2) for malignant tumours that require craniofacial resection, or for large tumours extending into the anterior cranial fossa.

A) The Supraorbital-pterional approach^[3]

This approach provides excellent exposure of anterior and middle cranial base with minimal brain retraction. Henceforth, the supraorbital pterional approach replaces the frontotemporal approach in many instances. Access to deep lesions is available through the subtemporal and subfrontal routes. The approach is highly suitable for large lesions extending to cavernous sinus and parasellar areas, besides being applicable to primary lesions of cavernous sinus and upper clival tumours.

The initial skin and fascia exposure is same as for the supraorbital approach described previously. Three holes are drilled as shown in figure (Fig. 3). The first hole is made in the frontal bone off the midline, above the nasion. Further entering of frontal sinus is managed as previously described. The second hole is the MacCarty's keyhole, made in the temporal fossa at the frontosphenoidal junction, just posterior to the zygomatic process of frontal bone. The third hole is made posteriorly near the floor of the temporal fossa. Next, clean bone cuts are made between the burr holes, with a high speed drill. The first cut passes from the paramedian frontal burr hole to the posterior temporal burr hole, about 4 cm. above the supraorbital rim. Following this, the second bone cut is made, extending from the posterior temporal burr hole to the MacCarty keyhole. The paramedian frontal burr hole and the MacCarty keyhole are connected with a bone cut passing through orbital roof and lateral orbital rim, as described before in the supraorbital approach. The craniotomy flap is then freed by fracturing it at sphenoid ridge. This osteotomy bone flap thus includes the superior orbital rim, the anterior portion of orbital roof, the upper portion of lateral orbital rim, and the adjacent frontal and temporal

bones. The sphenoid wing may then be drilled to the base of anterior clinoid process using high speed air drill.

B) The Suprolateral Cranio-orbital Approach^[4]

This approach provides access to orbital tumours, which require a cranial approach and which are not accessible through lateral and anterior orbital approaches. It gives wide superior and lateral exposure of orbital contents. The modification is specifically applicable to large orbital neoplasms, tumours in the orbital apex, optic canal lesions, lesions with intracranial extensions, and medial orbital tumours.

The superolateral modification requires removal of two bone flaps – (a) the cranio-orbital flap composed of superior and lateral orbital rim; (b) a posterior bone flap composed of the remainder of roof and lateral wall of orbit (Fig. 4). After resection of the lesion, the orbital walls can be reconstructed in their entirety or the surgeon may choose to leave out the posterior flap, in order to provide orbital decompression.

The cranio-orbital bone flap is raised as described in the supraorbital approach. Hence, the technique for posterior bone flap requires detailed description. The orbital contents and dura mater over the frontal bone are gently retracted and protected with brain retractors. In the medial part of orbital roof, an anteroposterior bone cut is made through the frontal bone. The muscle cone around the optic canal is not interrupted. This cut is made immediately lateral to the ethmoid sinuses and the trochlear insertion of superior oblique muscle is left undisturbed. The second bone cut is made in the inferior part of lateral orbital wall, as shown in figure (Fig. 4). Here, the anteroposterior cut extends back through the zygomatic bone into the greater wing of sphenoid. These two cuts are connected to permit removal of an orbital flap, which includes the posterior parts of roof and lateral wall of orbit. In case, there is an intracranial extension of the orbital tumour, the dura mater can be opened by the neurosurgeon. If a permanent decompression is required, the smaller posterior orbitotomy flap can be discarded, and the cranio-orbital flap replaced. Otherwise, both the flaps are used for complete reconstruction.

C) The Cranio-orbital Zygomatic Approach^[5]

The procedure of the cranio-orbital zygomatic approach involves modifications based on the supraorbital-pterional approach (Fig. 5). A supraorbital-pterional free bone flap is raised that consists of the frontotemporal bone in continuity with the anterosuperior and lateral rim of orbital roof. Thereafter, a posterior orbitotomy flap is raised as described in the superolateral cranio-orbital approach. Subsequently, to gain more operative space, the zygomatic arch is sectioned by making oblique osteotomies placed at either end of the zygomatic arch. With the inferior surface of the sectioned zygomatic arch still attached to the masseter, the zygomatic arch is reflected inferiorly. This provides excellent exposure to the floor of middle cranial fossa. If required, it may be

followed by careful drilling of the medial aspects of sphenoid wing. This approach provides multidirectional access to the trans-sphenoidal, subfrontal, subtemporal, trans-sylvian and retrochiasmatic areas.

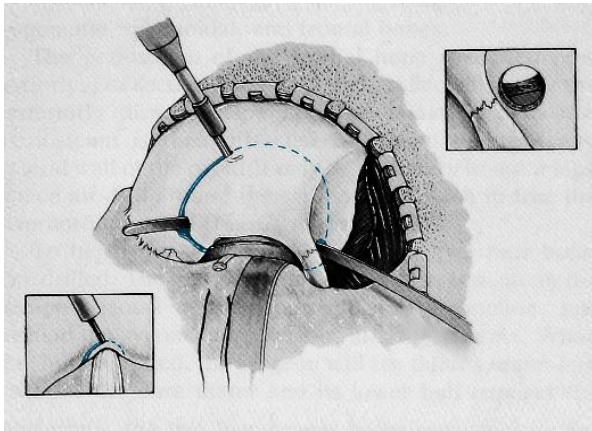


Fig. 1: A schematic diagram illustrating Supraorbital Approach.

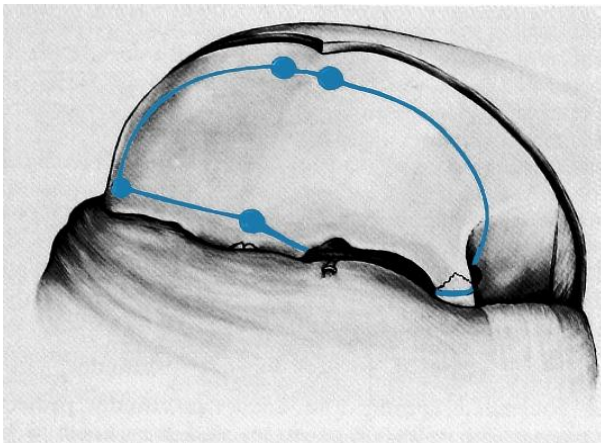


Fig. 2: A schematic diagram illustrating the Bifrontal Flap.

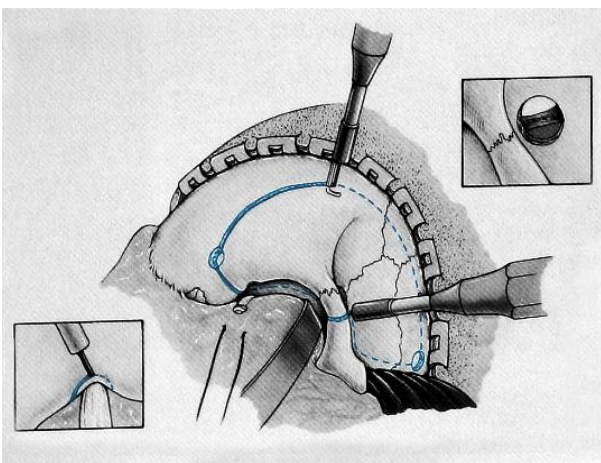


Fig. 3: Diagram illustrating the Supraorbital-pterional Approach.

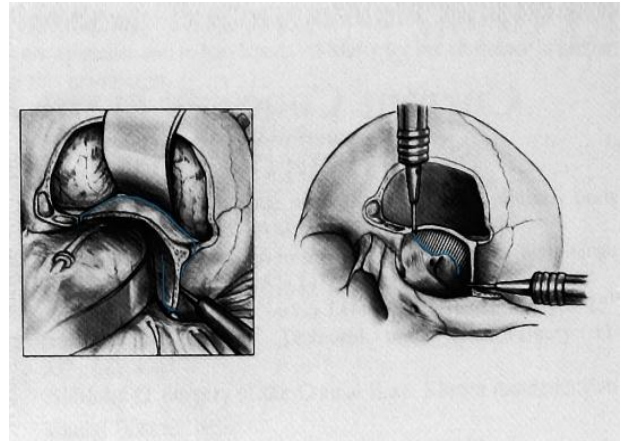


Fig. 4: Diagram illustrating the Superolateral Orbital Approach.

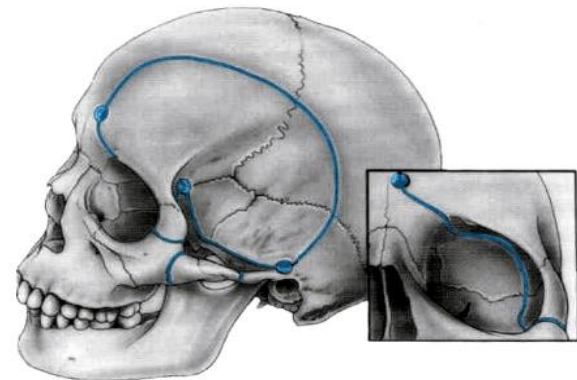


Fig. 5: Diagram illustrating the Cranio-orbital Zygomatic Approach.

CONCLUSIONS

The cranio-orbital approaches provide a variety of exposures to lesions of the orbit and anterior skull base. The posterior orbitotomy results in shortening of distance to targeted lesions and minimization of brain retraction. The approaches can be tailored and adjusted to specific lesions, so as to provide greater access to the anterior and temporal fossae, with improved exposure of cavernous sinus.

CONFLICT OF INTERESTS

The author declares that there is no conflict of interests that could influence this work.

ACKNOWLEDGEMENTS

The author declares that there was no financial aid obtained from any source for the preparation of this manuscript.

REFERENCES

1. Bowles AP, Anand VK. Cranioorbital Approach. In: Donald PJ, editor. Surgery of the skull base. Philadelphia: Lippincott-Raven Publishers, 1998; 263-286.

2. Jane JA, Park TS, Pobereskin LH, Winn HR, Butler AB. The supraorbital approach: Technical note. *Neurosurgery*. 1982; 11: 537-542.
3. Al-Mefty O. Supraorbital-pterional approach to skull base lesions. *Neurosurgery*. 1987; 21: 474-477.
4. Al-Mefty O. Superolateral orbital exposure and reconstruction. *Surg Neurol*. 1985; 23: 609-613.
5. Al-Mefty O. The cranio-orbital zygomatic approach for intracranial lesions. *Contemporary Neurosurgery*. 1992; 14: 1-6.