

ORAL VORICONAZOLE CAUSING SEVERE HYPOKALEMIA, ACUTE QUADRIPLÉGIA AND
PROLONGED QT INTERVAL: A RARE CASE REPORTDubey AP^{*1}, Viswanath S.², Suhag V.³, Pathak A.⁴, Rathore A.⁵, Kapoor A.⁶¹Senior Resident Medical Oncology, Army Hospital (R&R) Delhi-110010 (India).²Senior Advisor Medical Oncology, Army Hospital (R&R) Delhi-110010 (India).³HOD Radiation Oncology, Army Hospital (R&R) Delhi-110010 (India).⁴Senior Resident Medical Oncology, Army Hospital (R&R) Delhi-110010 (India).⁵Senior Resident Medical Oncology, Army Hospital (R&R) Delhi-110010 (India).⁶Senior Advisor Medical Oncology, Army Hospital (R&R) Delhi-110010 (India).***Correspondence for Author: Dr. AP Dubey**

Senior Resident Medical Oncology, Army Hospital (R&R) Delhi-110010 (India).

Article Received on 01/02/2016

Article Revised on 20/02/2016

Article Accepted on 08/03/2016

ABSTRACT

Antifungal agents of the azole family have long been described as potentially arrhythmogenic. Voriconazole is a broad spectrum antifungal in the azole family, with excellent bioavailability, both orally and intravenously. Hypokalemia is an uncommon side effect of oral voriconazole therapy. We present a case of young patient of haematological malignancy, who was started on empirical oral voriconazole therapy which resulted in severe hypokalemia, causing long QT interval and flaccid quadripareisis.

KEYWORDS: Voriconazole, hypokalemia, quadripareisis.**INTRODUCTION**

Voriconazole is a broad spectrum triazole, effective for the treatment of invasive fungal infections in immunocompromised host. As reported with other triazoles, voriconazole though less often is also associated with prolongation of QT interval and life threatening arrhythmias such as torsades de pointes.^[1,2,3,4] Hypokalemia is a very rare adverse effect of voriconazole.^[5,6] We report an extremely unusual case of a young individual suffering from relapsed Non Hodgkin's lymphoma who developed severe hypokalemia, long QT interval and flaccid quadriplegia after treatment with voriconazole.

CASE HISTORY

This 33 years old man was diagnosed as a case of relapsed Non Hodgkins Lymphoma (Anaplastic large cell type) with extranodal involvement in nasopharynx. He had received 6 cycles of chemotherapy (ifosamide, cisplatin and etoposide). Post 6 cycles, response assessment revealed patient in complete remission. While in hospital, patient developed high grade fever and mucoid nasal discharge. Clinical examination revealed tachycardia, tenderness in right maxillary sinus. No other abnormal findings were present. Patient's investigations

are as tabulated in Table-1. Total leucocyte counts were 3000/cumm with ANC 1500/cumm. ENT consultation was taken and patient was started on empirical antibiotics (Meropenem 1gram tds) and oral antifungal (voriconazole 400 mg 12 hrly on day 1 then 200 mg 12 hrly thereafter) in view of immunocompromised state due to chemotherapy. Patient tolerated the treatment and responded well, became afebrile by day 3 of the treatment. On day 4 patient developed generalised weakness of all four limbs which progressed rapidly resulting in complete quadriplegia over next 6 hours. Examination revealed complete loss of power in all four limbs, flaccidity, diminished reflexes and bilateral mute plantars. Higher mental functions and speech were normal, no cranial nerve deficits, no bladder bowel involvement or sensory deficit. Arterial blood gas analysis revealed serum potassium of 2.0 meq/l and serum magnesium of 1.3 meq/l. ECG showed bradycardia, U waves, and prolonged QT/QU interval (Figure-1). Voriconazole was stopped and patient was given parenteral potassium and magnesium supplements. His condition started improving in next 12 hrs and he was up about in next 36 hrs. His serum electrolytes and ECG returned to normal post correction of electrolytes. (Figure-2)

Tab 1. Investigations.

Investigation	Day 1	Day 4
Hb(g/dl)	11.8	11.3
TLC(per mm ³)	3000	2900
DLC(%)	P50L38	P48L41
S. creatinine(mg/dl)	0.9	0.9
S. Potassium(meq/l)	3.6	2.0
S. Magnesium(meq/l)	1.8	1.3
S. Bilirubin(mg/dl)	1.2	1.2
SGOT/PT(U/L)	54/48	50/44
S. Albumin(g/dl)	3.6	3.5

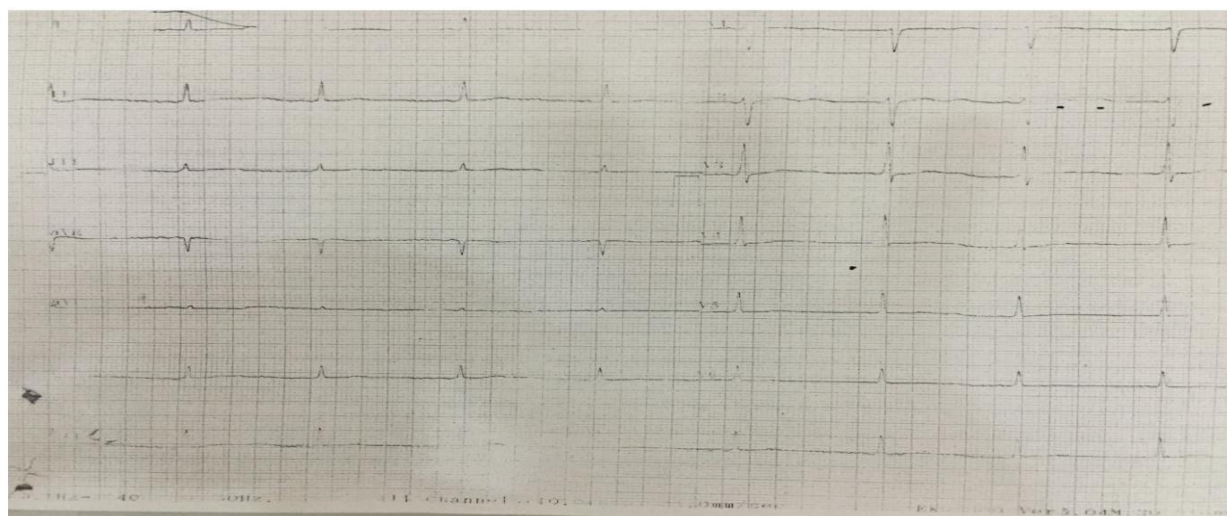
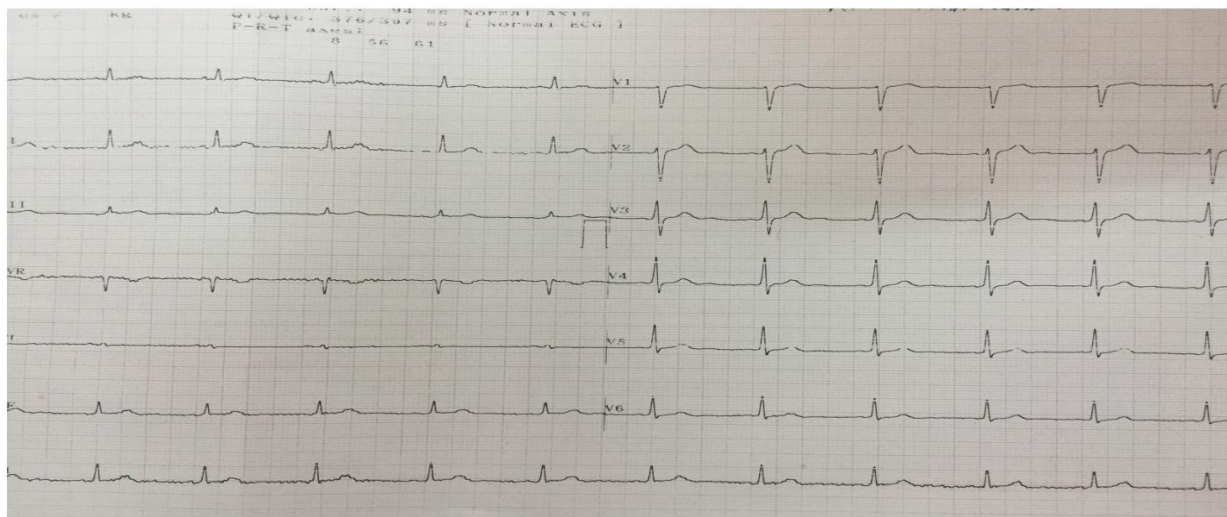


Figure-1: ECG showing bradycardia, U waves, and prolonged QT/QU interval.

Fig 2: Reversal of ECG changes post cessation of therapy and K⁺ supplementation.

DISCUSSION

Fungal infections are prevalent among immunocompromised hosts. Voriconazole is a broad spectrum antifungal agent of azole family with wide spectrum action against invasive fungal infections including aspergillosis. It has an excellent bioavailability both orally and parenterally. Antifungal agents of azole

group have long been implicated in causing prolongation of QT interval and life threatening arrhythmias like torsades de pointes.^[4] However the cases of prolongation of QT interval and arrhythmias that develop after treatment with ketoconazole^[1], itraconazole^[2], or fluconazole^[3] alone have been reported more frequently. Although the drug package insert warns about such adverse reactions, there are hardly five case reports

published, implicating voriconazole as a cause of prolongation of QT interval and arrhythmias with two-thirds of them receiving the drug intravenously.^[7, 8, 9, 10]

Even hypokalemia is not a common side effect of voriconazole therapy. Comparison studies of voriconazole to amphotericin B have shown 18.4% prevalence of hypokalemia and only 2.4% of them developing potassium level slower than 2.5 mmol/l in patients receiving voriconazole.^[5,6] So although there are rare reports of voriconazole causing long QT interval and hypokalemia, there is no published case report of voriconazole as such with combination of both these rare adverse effects. Our patient developed severe hypokalemia causing acute onset quadriplegia and prolongation of QT interval, all of which reverted with cessation of therapy and potassium supplementation.

Our patient was a known case of haematological malignancy with no previous history of cardiovascular, renal or neurological disease. Based on his symptomatology and clinical findings, he received standard dose of oral voriconazole empirically and developed severe hypokalemia causing acute quadriplegia as well as prolongation of QT interval. He was fortunate enough not to develop arrhythmia. Risk factors causing QT prolongation are additive and frequently cluster in cases of arrhythmias.^[11] Patients of haematological malignancies, who are receiving chemotherapy, are at increased risk of developing prolongation of QT interval and arrhythmias when treated with voriconazole or other systemic antifungal agent.^[8] These patients are at increased risk of receiving medication which have role in prolongation of QT interval like antiemetic including 5HT₃ antagonists or haloperidol, antimicrobials or diuretics. Patients receiving chemotherapy are also at increased risk of developing electrolyte imbalance due to frequent vomiting, diarrhoea, altered intake and various drugs which make them prone to develop such adverse effects.^[12,13]

CONCLUSION

Severe hypokalemia resulting in prolongation of QT interval and causing quadriplegia from voriconazole therapy is a rare documented adverse event. Due to dearth of published case reports, there is a possibility that this condition is under-recognized. Based on a single case, though it is difficult to conclude anything, but it is recommended that baseline screening of ECG and electrolytes as well as review of concomitant medications and mode of delivery of other drugs that predominantly affect QT, to be done. Special consideration to be given to patients who are at high risk of developing recurrent electrolyte abnormalities.

REFERENCES

1. Paserchia LA, Hewett J, Woosley RL. Effect of ketoconazole on QTc. *ClinPharmacol Ther*, 1994; 55: 146.
2. Nelson MR, Smith D, Erskine D, Gazzard BG. Ventricular fibrillation QT interval or induce secondary to itraconazole induced hyperkalemia. *J Infect*, 1993; 26: 348.
3. Khazan M, Mathis AS. Probable case of torsades de pointes induced by fluconazole. *Pharmacotherapy*, 2002; 22: 1632-7.
4. De Ponti F, Polluzi E, Cavelli A, Recanatini M, Montanaro N. Safety of non-arrhythmogenic drugs that prolong QT or induce torsades de pointes. *Drug Safe*, 2002; 25: 263-86.
5. Macias-Garrido E, Garcia-Frade F. Hipopotasemia en pacientes hospitalizados. *Med IntMex*, 2008; 24(1): 3-7.
6. Walsh T, Pappas P, Winston DJ, Lazarus HM, Pettersen F, Raffalli J, et al. Voriconazole compared with liposomal amphotericin B for empirical antifungal therapy in patients with neutropenia and persistent fever. *N Eng J Med.*, 2007;
7. Y. Alkan, W.E. Haefeli, J. Burhenne, J. Stein, I. Yaniv, I. Shalit. Voriconazole induced QT interval prolongation and ventricular tachycardia: a non concentration dependent adverse effect. *Clin Infect Dis.*, 2004; 39: e49-52.
8. J.A. Philips, F.M. Marty, R.M. Stone, B.A. Koplan, J.T. Katz, L.R. Baden. Torsades de pointes associated with voriconazole use. *Transpl Infect Dis.*, 2007; 9: 33-36.
9. C. Eiden, H. Peyriere, R. Tichitt, M. Cociglio, P. Amedro, J. Blayac, et al. Inherited long QT syndrome revealed by antifungals drug-drug interaction. *J Clin Pharm Ther*, 2007; 31: 321-324.
10. E. Aypar, T. Kendirili, E. Tutar, E. Ciftci, E. Ince, T. Ileri, et al. Voriconazole -induced QT interval prolongation and torsades de pointes. *PediatrInt*, 2011; 53: 761-763.
11. D. Justo, D. Zeltser. Torsades de pointes induced by systemic antifungal agents: lessons from a retrospective analysis of published case reports. *Mycoses*, 2006; 49: 463-470.
12. D. Zeltser, D. Justo, A. Halkin, V. Prokhorov, K. Heller, S. Viskin. Torsades de pointes due to noncardiac drugs: most patients have easily identifiable factors. *Medicine (Baltimore)*, 2003; 82(4): 282-290.
13. T.K. Becker, S.J. Yeung. Drug induced QT prolongation in cancer patients. *Oncol Rev.*, 2010; 4: 223-232.