

ROMPED EXTRA-UTERINE OVARIAN PREGNANCY: CASE REPORT

Nadim Chaimaa*, Loukili Najoua, CHATER Sara, Dagdag Samia, Pr. A. Anssari, Pr. M. Elyousfi, Pr. F. Elhassouni, Pr. Kh. Fethi and Pr. S. Bargach

Department of Gynecology-Obstetrics Oncology and High-Risk Pregnancy at The Rabat Maternity Hospital.



*Corresponding Author: Nadim Chaimaa

Department of Gynecology-Obstetrics Oncology and High-Risk Pregnancy at The Rabat Maternity Hospital.

Article Received on 02/08/2024

Article Revised on 23/08/2024

Article Accepted on 12/09/2024

ABSTRACT

Ovarian pregnancy is a rare ectopic pregnancy in which the ovary is the site of implantation. It is not always easy to diagnose and manage. It is a particular pathology, and the clinician is confronted with a poor clinical semiology and a difficult ultrasound diagnosis. Therapeutic management is mainly surgical, and histopathological examination is essential to confirm the diagnosis. We have documented one case of ovarian pregnancy. The patient presented to the emergency department with pelvic pain at 5 weeks' amenorrhea. Preoperative ultrasound evoked the diagnosis of a ruptured EP. An emergency laparotomy was performed, which led to the diagnosis of a ruptured ovarian pregnancy. Surgical treatment was radical.

KEYWORDS: Ovarian pregnancy, ectopic pregnancy, ultrasound, surgical treatment, case report.

INTRODUCTION

Ectopic pregnancy (EP) covers a number of clinical entities, all of which have in common an implantation outside the uterine cavity.^[1] Ectopic pregnancy is a problem in gynecology, accounting for 12 to 14 per 1,000 pregnancies, or one ectopic pregnancy per 76 deliveries, and remains a major cause of maternal mortality in the first trimester of pregnancy.^[2] Ovarian Pregnancy (OP) is a variety of EP where the ovary is the site of implantation.^[3] It occupies a special place in ectopic pregnancies because of its rarity, which is related to its location, and on the other to diagnostic procedures. OP is potentially diagnosed during surgery.^[3] Its pathophysiology is poorly understood, and may be secondary to reflux of the fertilized ovocyte into the ovary.^[4,5,6] We report a case of ruptured ovarian pregnancy diagnosed preoperatively.

CASE REPORT

Mrs RS, aged 30, G3 P2, was admitted to the gynecological emergency department for shock associated with acute abdominal pain in a 5-week amenorrhea context. She has a history of a caesarean section and the use of an oral contraceptive method (estro-progestogen) stopped 3 months before conception. clinical examination on admission revealed a blood pressure of 70 mmHg systolic and 45 mmHg diastolic, heart rate 120 bpm and temperature 36°C; abdominal examination revealed a distended abdomen with declive matity and pelvic defense; Vaginal taucher revealed pain on mobilization of the uterus associated with a cry of

Douglas without vaginal bleeding; abdomino-pelvic ultrasonography showed a very abundant hematic peritoneal effusion; transvaginal ultrasound showed the presence of a rounded mass containing a vetelline vesicle in the left latero-uterine region, corresponding to a gestational sac (Figure 1). Serum BHCG levels returned positive at 3500 mIU/ml. An emergency laparotomy was performed for a ruptured ectopic pregnancy, complicated by haemorrhagic shock, with life-threatening complications, which permitted aspiration of 1000cc of hemoperitoneum and localized the origin of the bleeding in the left ovary, which was tumefied and the site of a ruptured pregnancy (Figure 2). The patient benefited a left ovariectomy for hemostasis. histological examination confirmed the diagnosis of ovarian pregnancy. post-operative surveillance was unremarkable.

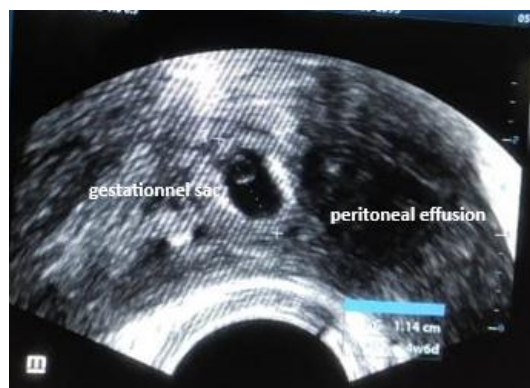

Figure 1: Transvaginal ultrasound showing a peritoneal effusion associated with a gestational sac.

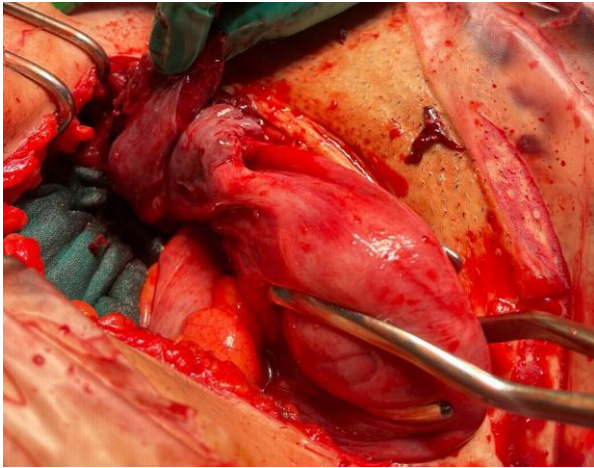


Figure 2: Left Ovarian pregnancy seen during exploratory laparotomy.

DISCUSSION

Ovarian pregnancy is a rare form of ectopic pregnancy. Ovarian pregnancy was first suspected by Mercurius in 1614.^[7] Their frequency is estimated at 2-3% of EP, representing an incidence of around 1/2500 to 1/5000 births.^[8]

The pathophysiology of OP has not been clearly defined. There are a number of hypotheses, but the mechanism seems to be transtubal reflux of the fertilized oocyte into the ovary. Novak^[9] recalls the three main theories to explain the pathogenesis, including two for primitive OP: 1) the theory of intra-follicular fertilization, in this case a non-expelled ovum is fertilized inside the unruptured follicle; 2) the theory of extra-follicular fertilization by Baden and Heins^[10]: fertilization takes place outside the follicle and implantation is ovarian. 3) the theory of ovarian transplantation of an EP resulting from a tubo-abdominal abortion.^[11] Most cases of OP are diagnosed before to the 12 SA.^[6] Certain OP may continue till the second trimester^[12], possibly to their benefit. Rarely, the OP may be bilateral or be a component of a heterotopic pregnancy.^[12]

The population at risk is a little different from those of patients with tubal EP, as it is most often represented by young, fertile, multiparous women with an IUD.^[13]

OP shares the same risk factors as EP in general. The specific risk factors for OP are still poorly established. Conversely, Philippe E.^[14] has considered the potential role of the endométriose in the etiology of OP.

The clinical symptomatology of OP is similar to that of other EPs, represented by the triad formed by abdominal pain, secondary amenorrhea and metrorrhagia in a genitally active woman.^[15,16]

Pain corresponds to rupture of the ovarian capsule by the OP and the formation of hemoperitoneum.^[6,17] Patients are most often seen in an emergency context, with significant hemoperitoneum or even in a state of

hypovolemic shock^[17], signs reported in our case. This supports data from the African literature, with 95% of ruptured EPs in the Cissé series and 80.2% in the Baldé series in Guinea Conakry.^[2]

The paraclinical diagnosis of EP is made by the combination of a β HCG level above 1500IU/l, the absence of an intrauterine gestational sac and the presence of a latero-uterine mass.^[18]

Certain ultrasonographic signs are highly suggestive of ovarian pregnancy: the presence of a round anechogenic image with a hyperechoic corona on the surface of the ovary, the presence of ovarian parenchyma such as a corpus luteum or follicle surrounding the mass, and an echogenicity of the mass higher than that of the ovary.^[19]

The differential diagnosis is often a corpus luteum cyst or a hemorrhagic cyst.

Treatment of OP depends on the clinical situation and the stage of diagnosis; it is essentially surgical. Many surgical techniques have been described: wedge-shaped resection of the ovary taking away the OP, enucleation of the OP, cystectomy of the corpus luteum taking away the trophoblast, curettage of the trophoblast with coagulation or haemostatic suturing of the bed of the OP with total preservation of the ovary.^[20] In rare cases, due to advanced pregnancy development, ovariectomy or even adnexectomy may be required.^[19] This was the case with our patient.

In many cases, OP is diagnosed at the stage of complications that preclude medical treatment. The addition of methotrexate (MTX) may be considered to compensate for inadequate surgical treatment.

Anatomopathological examination confirms the diagnosis of OP based on Spielberg's anatomical criteria of 1878^[21]: the tube on the affected side, including the pinna, must be free of lesions; the ovarian sac must occupy the usual anatomical position of the ovary; the ovary and gestational sac must be connected to the uterus by the utero-ovarian ligament; ovarian tissue must exist within the ovular sac.

The prognosis of OP, due to the absence of tubal damage, is not a risk factor for repeat EP.^[3] Only one case of recurrence of OP has been described in the literature, involving the contralateral ovary.^[22]

CONCLUSION

Ovarian pregnancy is a rare pathology; its diagnosis is difficult and is often made intraoperatively. Like all other EPs, ovarian pregnancy is a medical emergency that can lead to surgery if not treated early. Early diagnosis improves prognosis.

REFERENCES

1. Nadi M., Richard C., Filipuzzi L. Grossesse interstitielle, angulaire et cornuale : diagnostic, traitement et futur obstétrical. *Gynécologie Obstétrique Fertilité & Sénologie* 2017 <http://dx.doi.org/10.1016/j.gofs.2017.05.002> [in press]
2. THIAM O., FAYE P.M., SARR I.S.S., SEYE Y., GUEYE M.L., TOURE A.O., SECK M., CISSE M., DIENG M. Grossesse extra-utérine ovarienne rompue : à propos de deux cas. *Journal de la SAGO*, 2018; 19(°2): 46-50.
3. Agdi M, Tulandi T. Surgical treatment of ectopic pregnancy. *Best Pract Res Clin Obstet Gynaecol*, Aug. 2009; 23(4): 519-27. PubMed| Google Scholar
4. Ghi T., Banfi A., Marconi R. et al. Three dimensional sonographic diagnosis of ovarian pregnancy. *Ultrasound Obstet Gynecol*, 2005; 26(1): 102-104.
5. Kraemer B., Kraemer E., Guengoer E. et al. Ovarian ectopic pregnancy: diagnosis, treatment, correlation to Carnegie stage 16 and review based on a clinical case. *Fertil and Steril*, 2009; 92(1): 392.
6. Sergent F., Mauger F., Gravier A., Verspyxk E., Marpeau L. Ovarian pregnancies: reevaluation of diagnostic criteria. *J Gynecol Obstet Biol Reprod*, 2002; 31(8): 741-746.
7. Grall J., Jacques Y. La grossesse ovarienne: à propos de quatre cas. *Revue Française de Gynécologie*, 1978; 73(2): 139-145.
8. Job-Spira N., Coste J., Aublet-Cuvelier B. et al. Fréquence de la grossesse extra-utérine et caractéristique des femmes traitées. *La Presse médicale*, 1995; 24(7): 351-355.
9. Novak E. *Gynecologic and Obstetric Pathology*. Philadelphia, WB Saunders, 1952; 3rd edition. Google Scholar
10. Baden, Heins. Ovarian pregnancy. *Amer J Obstet Gynec*, 1952; 64: 353-358. PubMed | Google Scholar
11. Wynne HM. *Bull. John Hopkins Hosp*, 1919; 30: 93. Google Scholar
12. Grimes H, Nosal R, Gallagher J. Ovarian pregnancy: a serie of 24 cases. *Obstet Gynecol*, 1983; 61(2): 174-180. PubMed | Google Scholar
13. Hebertsson G, Magnusson SS, Benediktsdottir K. Ovarian pregnancy and IUCD use in a defined complete population. *Acta Obstet Gynecol Scand*, 1987; 66(7): 607-610. PubMed | Google Scholar
14. Philippe E. *La grossesse extra-utérine*. Paris, Masson and Cie., 1961. Google Scholar
15. Balde I.S., Diallo F.B., Conte. Ectopic pregnancy at the Ignace Deen University Hospital in Conakry: Epidemiologic, social, demographic, therapeutic, and prognostic aspects. *Médecine et Santé Tropicale*, 2014; 24: 297-300.
16. Jean-François M., Adrien S.Z., Boniface S.O. et al. Aspects actuels de la grossesse extra- - utérine à Libreville (Gabon) : à propos de 153 cas. *Cahier Sante*, 2002; 4(12): 405-408.
17. Ercal T, Cinar O, Mumcu A, Lacin S, Ozer E. Ovarian pregnancy: relationship to an intrauterine device. *Aust N Z J Obstet Gyneacol*, 1997; 37(3): 362-364. PubMed | Google Scholar
18. Millet I., Melanie C., Emma P.B. et al. Urgences gynécologiques corrélations radio-chirurgicales. *Imagerie de la Femme*, 2015. <http://dx.doi.org/10.1016/j.femme.2015.03.002>
19. Olfa Zoukar et al. La grossesse ovarienne à propos d'un cas et revue de la littérature. *Pan African Medical Journal*, 2021; 40(208). 10.11604/pamj.2021.40.208.32011
20. Tabassum M, Atmuri K. The unexpected ovarian pregnancy at laparoscopy: a review of management. *Case Rep Obstet Gynecol*, 2017; 2017: 9856802.
21. Rabetafika Ranaivoson, H. V., Ranaivomanana, V. F., Nomenjanahary, L., Andriamampionona, T. F., & Randrianjafisamindrakotroka, N. S. *Grossesse ovarienne: à propos de 3 cas et une revue de la littérature*. *Pan African Medical Journal*, 2016; 25. doi:10.11604/pamj.2016.25.128.10834 10.11604/pamj.2016.25.128.10834
22. Chahtane A, Dehaymi M, Rhrab B, Kharbach A, El Armani S, Chaoui A. La grossesse ovarienne: à propos de 14 observations avec revue de la littérature. *Revue Française de Gynécologie obstétrique*, 1993; 88(1): 35-38. Google Scholar