wjpmr, 2024, 10(3), 60-67

SJIF Impact Factor: 5.922

WORLD JOURNAL OF PHARMACEUTICAL AND MEDICAL RESEARCH

www.wjpmr.com

Research Article

ISSN 2455-3301

WJPMR

HISTOLOGICAL FINDINGS IN THE AQUEOUS EXTRACT OF *PSIDIUM GUAJAVA* (GUAVA) LEAVES TREATED LIVER OF DIABETIC WISTAR RAT

Uthman Ademola Yusuf[1]*, Betty Banda[1], Mwewa Masamba[1], Michelo Miyoba[2], Aminat Adejoke Yusuf[3], Samuel Bolaji Mesole[4]

[1]Department of Human Anatomy, School of Medicine and Health Sciences, Mulungushi University, Livingstone Campus, Zambia.

[2]Department of Clinical Sciences, School of Medicine and Health Sciences, Mulungushi University, Livingstone Campus, Zambia.

[3]Department of Medical Biochemistry, Faculty of Basic Medical Sciences, Ladoke Akintola University of Technology, Ogbomoso, Nigeria.

[4]Department of Clinical Sciences, School of Medicine, Eden University, Lusaka, Zambia.

***Corresponding Author: Uthman Ademola Yusuf**

Department of Human Anatomy, School of Medicine and Health Sciences, Mulungushi University, Livingstone Campus, Zambia.

Article Received on 16/01/2024 **Article Revised on 06/02/2024** **Article Accepted on 26/02/2024**

ABSTRACT

Psidium Guajava has widely been seen to contain antihyperglycemic constituents. The study objective was to evaluate the antihyperglycemic effect of aqueous extract of *Psidium Guajava* in the liver of streptozotocin-induced diabetic male Wistar rats. Thirty male Wistar rats weighing between 180-220 g were randomly selected into five groups (6 per cage); normal control, diabetic control, diabetic +metformin, diabetic +guava and guava leaves only group. Diabetes mellitus was induced using a single intraperitoneal dose of streptozotocin (70mg/kg BW) and established a steady state of hyperglycemia after 72hours. The aqueous extract of *Psidium Guajava* and metformin of 200 mg/kg BW was administered orally using orogastric cannula daily for a period of 4 weeks. The results showed that the Diabetic +Guava and diabetic + metfor min group's body weight was statistically significant when compared to the diabetic group ($P<0.05$). The blood glucose in diabetic + guava and Diabetic + metformin group was normoglycemic by week 4 and it was statistically significant when compare to diabetic group ($P<0.05$). The histological findings of the normal control and guava leaves only groups showed normal histoarchitecture, diabetic group showed high degree of disorganization in the histoarchitecture with many necrotic hepatocytes and a lot of collagen accumulation. The diabetic+Guava and diabetic+Metformin group showed little disorganization in their histoarchitecture and had both healthy and necrotic hepatic tissues present with little accumulation of collagen. *Psidium Guajava* are able to lower elevated blood glucose levels and ameliorate the effects of STZ on the liver morphology.

KEYWORDS: Liver, Hematoxylin and Eosin stain, Diabetes mellitus, streptozotocin, *Psidium guajava*.

INTRODUCTION

Diabetes Mellitus is the most progressive disease characterized by hyperglycemia on two or more occasions occurring due to either impaired insulin secretion by the pancreatic beta cells or peripheral insulin resistance.[1] It develops when the pancreas does not produce enough insulin or when the body can't use the insulin it does make adequately. Diabetes is a chronic condition that affects people all over the world. The International Diabetes Federation projected that 425 million individuals (1 in 11 of the world's population) had diabetes in 2017, with that number expected to rise to 693 million by 2045. In 2017, it was responsible for about 4 million deaths, or 10.7% of all deaths worldwide, outnumbering HIV/AIDS, Tuberculosis, and Malaria combined.[2]

Type 1 diabetes, also known as Juvenile onset diabetes or insulin-dependent diabetes, accounts for 5-10% of all diabetes occurrences. It happens when the pancreatic beta cells are destroyed by the immune system. Type 2 diabetes affects 90-95% of people with the disease. It can range from insulin resistance due to a lack of insulin to insulin resistance due to a problem with insulin secretion.[3] Another type is Gestational diabetes that identifies women who develop diabetes mellitus during gestation;

It usually has its onset in the third trimester of pregnancy. Long-term hyperglycemia is linked to an increase in hyperlipidemia, the formation of oxygen radicals, and a reduction in antioxidant status.[1]

Diabetes mellitus must be well-managed in order to avoid the devastating complications that can result if it is not. It is, however, costly to manage, and many patients find it difficult to adhere to the prescribed medications and diet recommendations.[4] Side effects of commercially available oral hypoglycemic medications include gastrointestinal discomfort, weight gain, and hepatic impairment.[5] As a result, new potential medicines for the prevention and treatment of diabetes mellitus are urgently needed. Traditional medicine has been practiced for many years, and numerous plant extracts have been utilized to treat a variety of ailments, including diabetes mellitus. Human and animal studies have looked at the anti-hyperglycemic properties of many plants. Despite the fact that most herbal drugs have shown potential usefulness, they have not been thoroughly tested for their potential effects on various organs of the body.

Psidium guajava (guava) is a genus of tropical and subtropical plants in the Myrtaceae family that is widely cultivated across the world. Its fruit is widely used as a food source and is processed into juice and jam. Psidium guajava leaves have been utilized as folk medicine due to their low toxicity and significant therapeutic potential or herbal tea to treat diarrhea and diabetes in India, China, Pakistan, Bangladesh, and Mexico.[6]

It was verified by[7] that aqueous soluble extract from guava leaves have anti-hyperglycemic function against type 2 diabetes. Previous research has revealed that it contains antioxidant, antibacterial, anti-inflammatory, and hypoglycemic characteristics, making it suitable for use as a natural medicine in the treatment of Type 2 diabetes.[8]

The global prevalence of diabetes mellitus has been steadily increasing over the last decade, but has been underestimated due to a lack of precise information regarding disease status, particularly in developing countries, where nearly half of the population is unaware of their illness status.[9] WHO estimates that more than 422 million people worldwide have diabetes mellitus. In 2000, the prevalence of diabetes in the WHO African Region was estimated at 7.02 million people, out of which 0.702 million (10%) people had type 1 diabetes and 6.318 (90%) had type 2 diabetes. About 113,100 people died from diabetes related causes, 561,00 were permanently disabled and 6,458,400 experienced temporary disablements. In 2019, diabetes was the direct cause of 1.5 million deaths and 48% of all deaths due to diabetes occurred before the age of 70 years (2)

Diabetes is one of the top ten causes of death, with a 5% increase in premature deaths between 2000 and 2016, compared to non-communicable diseases, with 1.6 million deaths in 2016 and 4.2 million deaths in 2019.[9]

In this study the effect of *Psidium Guajava* on the liver will give information on the toxic and protective measure which will be accounted for in future and it is important as it will give scientific knowledge on the use of *Psidium Guajava* in our setting.

MATERIALS AND METHODS

Plant materials

Guava leaves were gathered from the Livingstone fruit farm in Zambia's Southern Province's Livingstone area. The guava leaves were pounded after being oven dried. The crushed and sieved dry pounded guava leaves were then used to make a homogeneous powder. The extraction was done using,[10] methods.

Animals and Animal Management

This study involved thirty adult male Wistar rats (Rattus norvegicus) who were presumed healthy. The animals were between the ages of 8 and 10 weeks, with a body weight between 180g and 220 g. The animals were housed in the animal holdings of the Department of Anatomy, Mulungushi University School of Medicine and Health Sciences Southern Province, Zambia, in five cages (6 rats each cage). They were fed regular animal feeds (Wealth-gate pelletized feeds) and had unrestricted access to clean water.

Induction of diabetes

Diabetes was induced using Streptozotocin (STZ). After an overnight fasting period, the rats were weighed and a baseline glucose level was established. The animals were induced using a single intraperitoneal streptozotocin at a dose of 70 mg/kg body weight and then returned to their regular feeding schedule.[11] After 72 hours of induction, a fasting blood glucose was taken via a tail vein puncture. Blood glucose levels were measured using a glucometer. Fasting blood glucose levels of more than 10 mmol/l / 250 mg/dl was regarded diabetic in animals.

Experimental Design

30 Wistar rats weighing between 180-220 g were randomly selected into five groups (6 per cage); Group A: normal control, Group B: diabetic control, Group C: diabetic +guava D: diabetic +metformin, and Group E: guava leaves only group.

Guava Leaves Mode of Administration

The dose of the aqueous extracts of Guava leaves used in these studies were adopted from the report of,[12] The guava leaves were dissolved in physiological saline daily and administered orally with use of oro-gastric cannula to Group C and E at 200 mg/kg bw (at 9.00 – 10.00 a.m. each day) for a maximum period of four weeks and Group D rats was given 200 mg/kg bw of metformin, Group A rats (n=6) received neither STZ nor Guava leaves extract.

Measurement of Blood Glucose

Glucose oxidase method of one touch ultra 2 glucometers was used to assess blood glucose in overnight fasted rats at 9:00 – 10:00 hours (Accu-Chek Compact Plus). By snipping the tip of the tail, blood was taken from the median caudal vein. Blood glucose levels were checked weekly basis, one week of acclimatization period before the induction of diabetes and during the four weeks of treatment.[13]

Measurement of the Body Weight (g)

The Wistar rats' body weight (g) were monitored one week of acclimatization period prior to induction of diabetes and on a weekly basis for four weeks during the experimental therapy. A weighing scale was used to determine the body weight (Venus VT 30 SL).[11]

The Relative Organ Weight (%)

The rat's relative organ weight was calculated as the ratio of the brain's weight to the rat's terminal body weight, with the unit recorded as a percentage (percent) using a sensitive weighing scale (SonyF3G brand).[13]

Histological Process

Animals were sacrificed by euthanasia at the conclusion of this investigation. They were pinned through the fore and hind paws while lying supine on the dissection board. The animals' abdomen were dissected using the surgical blade, and each organ was extracted and weighed meticulously. Histological tissue was fixed for 72 hours in newly prepared formo saline and processed for regular histological examinations stained with Haematoxylin and Eosin (H&E) to identify changes in cellular morphology. Additionally, special stains like periodic acid Schiff and Masson trichome were applied.[11]

Photomicrography

At the Department of Human Anatomy, Mulungushi University School of Medicine and Health Sciences, Livingstone Campus, Southern Province Zambia, photomicrography of histological sections of the liver were taken with an Olympus Microscope (New York, United States of America) and camera.

Statistical Analysis

Data was presented as mean ± standard error of the mean (mean±SEM); analyzed using one-way ANOVA and all graphs were drawn using excel. P values less than 0.05 ($p<0.05$) will be taken to be statistically significant.

Data collection plan and tools

This was accomplished by monitoring body weight and blood glucose levels before and after drug administration for four weeks and recording the results in a data input sheet. After the rats had been sacrificed, the relative organ weight was obtained and a histological study of the liver was performed.

Data management and storage

Zipped folders were used to store all of the information obtained.

RESULTS

The average body weight on weekly basis

Figure 1 shows the average body weight of the rats on a weekly basis. In the week of acclimatization (-1) and induction week (week 0), there was no significant change in body weight among the groups ($p>0.05$). By week three of treatment there was a reduction in body weight of rats in diabetic group when compared to other groups ($p<0.05$). By week four the body weight of the diabetic group continued to decrease and when compared to the other groups it was statistically significant across the groups ($p<0.05$). there was no significant when the diabetic +Guava and diabetic +metformin groups was compared to control ($p>0.05$).

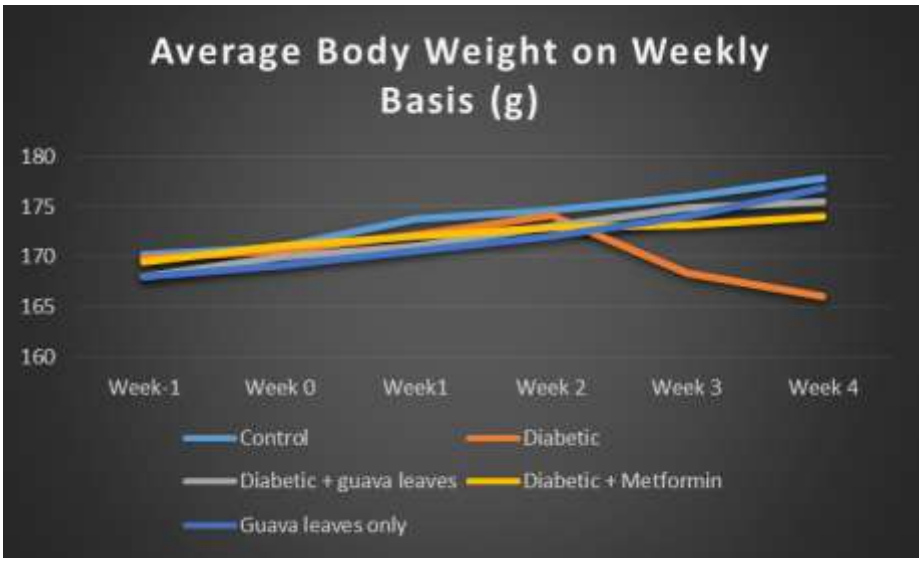

Figure 1: Average body weight (g) on weekly basis. Data expressed as mean±SEM ($p<0.05$).

Average Blood Glucose Levels on Weekly Basis (mg/dl)

Figure 2 shows the average blood glucose on a weekly basis in mg/dl. In the week of acclimatization (week -1) there was no significant change in their blood glucose. After induction (week 0), increased levels of blood glucose were noticed in diabetic group, the groups treated with guava leaves and metformin. In week 1 and 2 of treatment, there was significant decrease ($p<0.05$) in the blood glucose in the groups treated with guava leaves and Metformin. However, by week three, the blood glucose reduced significantly ($p<0.05$) in the Diabetic+guava and Diabetic+mertiformin groups, this decrease was statistically significant ($p< 0.05$) compared to the diabetic group. There was no significant ($p>0.05$) change in blood glucose in the control group and guava leaves only group. By the end of treatment (28 days), the groups treated with guava leaves aqueous extract and metformin returned blood glucose levels to normoglycemic with no significant difference to the control group and guava leaves only group ($p>0.05$).

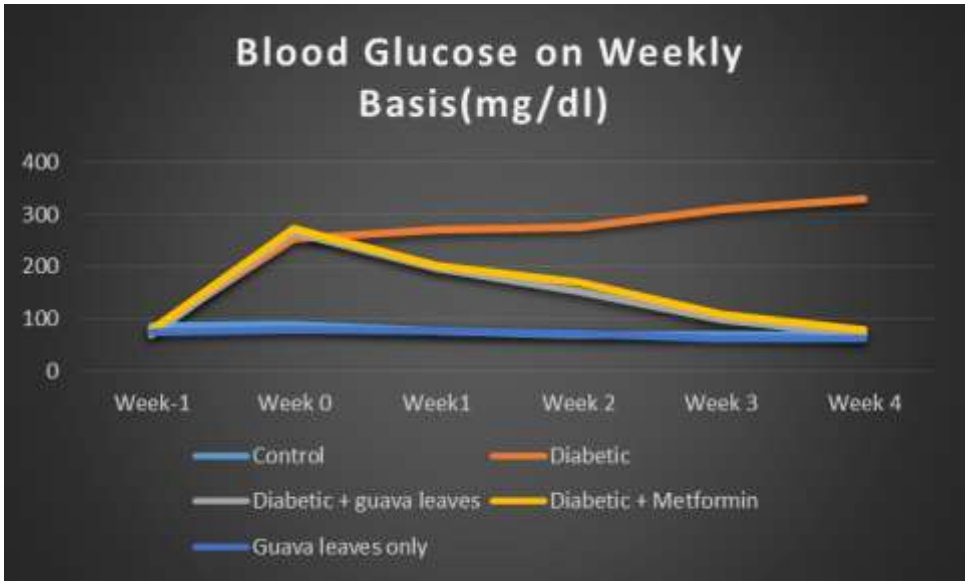

Figure 2: Changes in blood glucose (mg/dl) levels weekly. Data expressed as mean±SEM ($p<0.05$).

The relative Liver weight of the rats

Figure 3 shows a graph of the relative weight of the liver. The liver weight in the control group was higher than all of the other groups, there was no significant difference in the weight between the control group and guava leaves only group ($p>0.05$). The diabetic group had the lowest relative organ weight compared to the other groups and it was significant when compared ($p<0.05$).

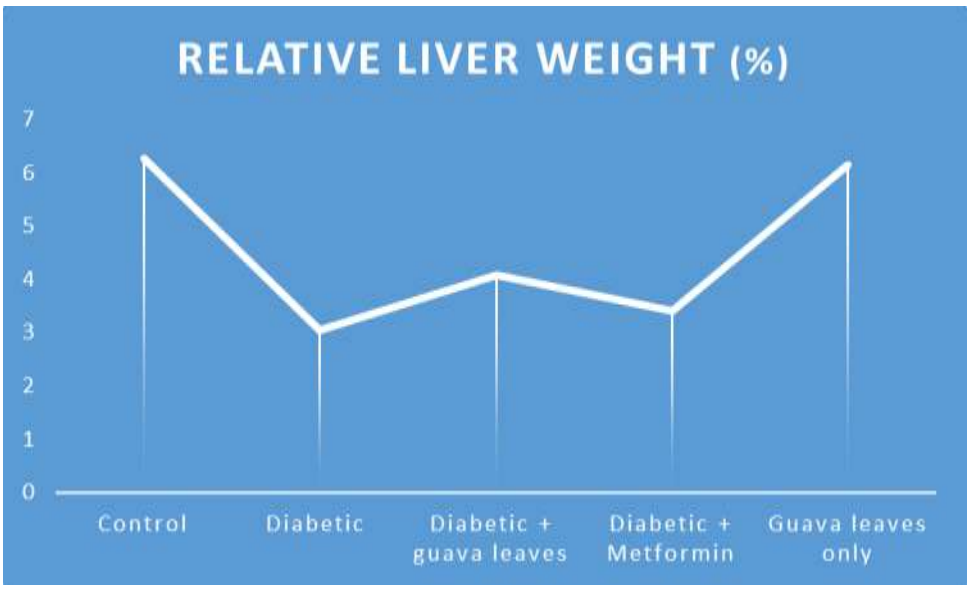

Figure 3: Relative Liver weight of the rats (%). Data expressed as mean±SEM ($p<0.05$).

Histological Findings

Hematoxylin and Eosin stain (H&E) of the Liver

The liver in the normal control and Guava only groups showed normal histoarchitecture with numerous healthy hepatocyte, (Figure: 4A and E). diabetic group showed that the histoarchitecture was disorganized with many necrotic hepatocyte (Figure 4 B). Diabetic+Guava and Diabetic+metformin groups showed little disorganisation in their histoarchitectures and there are both healthy and necrotic hepatocyte present (Plates: 4 C and D).

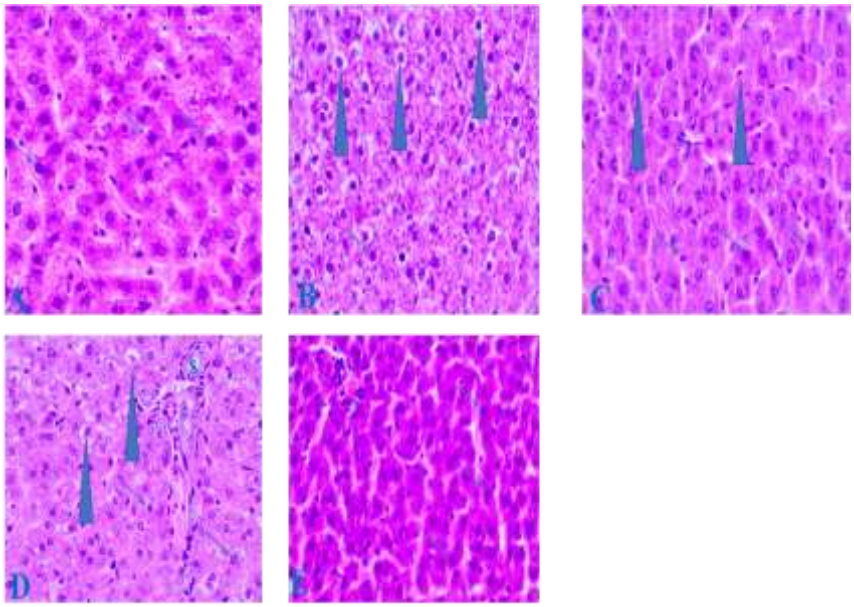

Figure 4: Photomicrograph showing the Liver at week four. H&E stain X400. A- Normal control, B – Diabetic, C – Diabetic+Guava, D – Diabetic+Metformin and E- Guava only. Arrow – hepatocyte, Arrow head – Necrotic hepatocyte, S – Sinusoid.

Periodic Acid Schiff stain of the Liver

Normal control and Guava only groups (Figure: 5A and E) the PAS revealed positive reaction while Diabetic+Guava and Diabetic+metformin groups (Figure: 5 C and D) showed a bit of positive reaction. Diabetic group showed no reaction (Figure: 5 B).

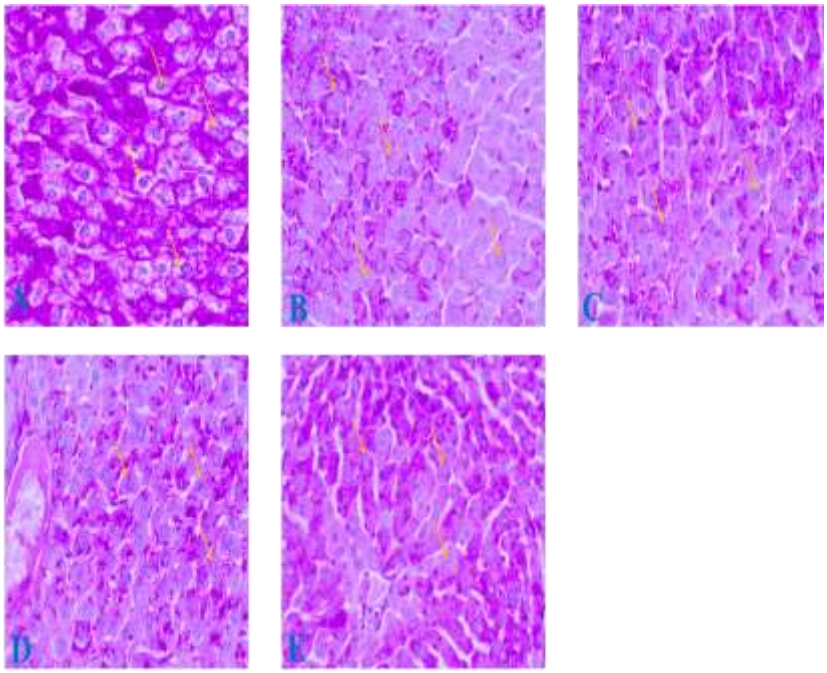

Figure 5: Photomicrograph showing the Liver at week four. PAS stain X400. A- Normal control, B – Diabetic, C – Diabetic+Guava, D – Diabetic+Metformin and E- Guava only. Arrow – hepatocyte, Arrow head – Necrotic hepatocyte, S – Sinusoid.

Masson Trichrome stain of the Liver

In the normal control and Guava only groups showed normal distribution of collagen (Figure 6 A and E). diabetic group showed a lot of accumulation of collagen (Figure: 6 B). Diabetic+Guava and Diabetic+metformin groups showed a little accumulation of collagen (Figure: 6 C and D).

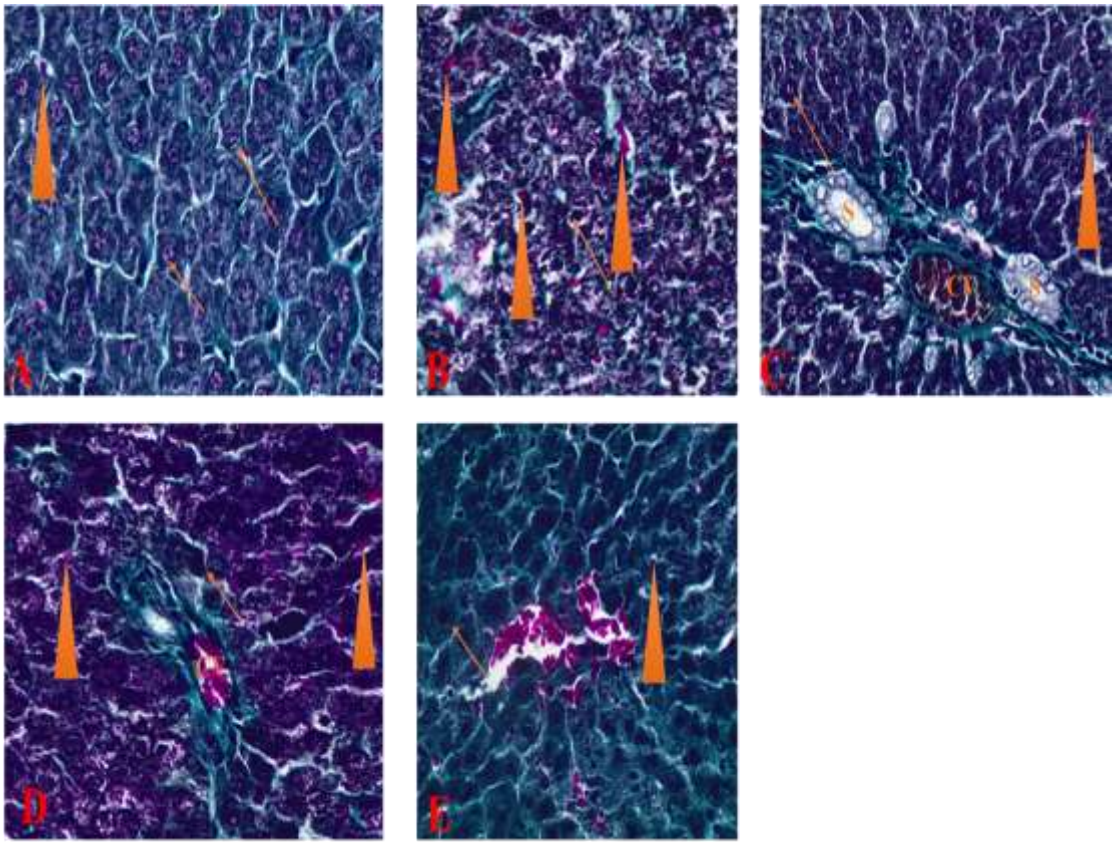

Figure 6: Photomicrograph showing the Liver at week four. Masson stain X400. A- Normal control, B – Diabetic, C – Diabetic+Guava, D – Diabetic+Metformin and E- Guava only. Arrow – hepatocyte, Arrow head – Necrotic hepatocyte, S – Sinusoid.

DISCUSSION

Herbs have been used as medicinal for several years to cure or rather manage different ailments such as diabetes mellitus.[4] In the study, there was an establishment of a rat model with diabetes by a 70mg/kg body weight Streptozotocin induction that was aimed at determining the effects of guava leaves extract (*Psidium guajava*) on the blood glucose, bodyweight, the relative liver weight and histological changes of the liver in the Diabetic Wistar rat.

In this study, the body weight of the Diabetic rats began to decrease in the third week compared to the other groups, this was because of the increase of glucose via gluconeogenesis by lipolysis, decrease in tissue proteins and increase in muscle wasting in Diabetes rats which is in agreement with.[14] By the end of week four the body weight was maintained in the Diabetic+Guava and Diabetic+Metiformin with no significant difference to the control group, this aligns with the findings by.[15] that *Psidium guajava* causes a significant return to normal body weight, plasma insulin, plasma glucose, glycogen, and enzymes that break down carbohydrates. *Psidium guajava* will increase the translocation of GLUT-2 from cytoplasm to the membrane to facilitate the glucose within the liver.[15] There was also reduction in the body weight by week 3 in the Diabetic rats receiving metformin to a value with no significant difference to the control group, this supports the research that found that metformin not only significantly lowers plasma fasting insulin levels by inhibiting complex 1 of the mitochondrial respiratory chain, but also lowers blood glucose levels without overt hypoglycemia.[16]

It was observed that after induction, increased levels of blood glucose were noticed in diabetic group, Diabetic+guava and diabetic+metformin. There was no significant change in blood glucose in the control group and guava leaves only group. The blood glucose in the diabetic group continued to increase. However, by week three, the blood glucose reduced significantly ($p<0.05$) in the Diabetic+guava and Diabetic+metiformin groups, this decrease was statistically significant ($p< 0.05$) compared to the diabetic group. By week 4 the groups treated with guava leaves aqueous extract and metformin returned blood glucose levels to normoglycemic with no

significant difference to the control group and guava leaves only group (p>0.05). This aligns with the research,[1] who extracted guava leaves polysaccharides and further tested the antidiabetic effects on Streptozotocin-induced diabetic mice in combination with a high-fat diet, the authors revealed that guava leaves polysaccharides was associated with a significant reduction in total cholesterol, triglycerides, glycated serum protein, creatinine, fasting blood glucose, and malonaldehyde content, and increased total superoxide dismutase and total antioxidant capacity enzyme activity in vivo. uptake through GLUT-4 in vitro. This indicates that guava leaves extracts are very effective in the treatment of diabetic rats.

The present study showed that *Psidium guajava* extract could maintained the relative liver weight in the extract only group and the Diabetic+Guava group. Guava leaves contain high amount of antioxidants and anti-providing nutrients which are essential not only for life but also help to control the free radical activities. It also has a variety of phytochemicals which include beta-carotene, lycopene, vitamins C, E, and A and other substances.[17] Metformin also maintained the relative liver weight.

In the hematoxylin and eosin stain, the liver histoarchitecture of the rats in the diabetic group showed that the histoarchitecture was disorganized with many necrotic hepatocytes, it showed marked structural alterations in the liver ,this was because of elevated free radical generation that lead to increased mitochondrial oxidative stress that is characterized by inflammation and cellular necrosis from a report by.[14] However, in the Diabetic+Guava and Diabetic+metformin groups showed mild to little disorganisation in their histoarchitectures and they both had healthy and necrotic hepatocyte present. This aligns with a report by.[18] in which the hepatocellular function-enhancing effect of the aqueous extract of *Psidium guajava* leaves is reported. The phytochemical report of this study reported that the various extracts' contents, particularly the presence of flavonoids, which have been documented to have antioxidative effects, may be responsible for the extract's ability to improve hepatocellular function.[18] Additionally, the extract's saponins are known to have hypocholesterolemic effects, which may help to lower the metabolic load on the liver.[19]

The Periodic Acid Schiff stain is used for the demonstration of carbohydrates and carbohydrate rich compounds in tissues, it demonstrates polysaccharides, mucin, glycogen, certain glycoproteins and glycolipids.[20] In this stain it showed positive reaction in the normal control and guava leaves only group. The Diabetic group showed no reaction due to the effect of hyperglycemia affecting the metabolism of lipids, carbohydrates and proteins while Diabetic + Guava and Diabetic+ Metiformin groups showed a bit of positive reaction. This aligns with the findings by.[21] that guava leaves are a great source of many macro- and micronutrients that are good for your health, as well as bioactive substances. 82.47% moisture, 3.64% ash, 0.62% fat, 18.53% protein, 12.74% carbohydrates, 103 mg ascorbic.[21] Minerals like calcium, potassium, sulphur, sodium, iron, boron, magnesium, manganese, and vitamins C and B are present in guava leaves. Guava leaves are an excellent alternative for human nutrition as well as animal feed to prevent micronutrient deficiencies due to their greater contents of Mg, Na, S, Manganese, and Boron.[22] Therefore this showed that guava extract was trying to ameliorate the damage on the liver caused by diabetes mellitus.

The Masson Trichome stain shows level collagen deposition in the tissues.[23] The normal control and Guava only groups showed normal distribution of collagen . The diabetic group showed a lot of deposition of collagen due to the hepatic stellate cells and cellular production of transformin growth factor, collagen and fibronectin causing fibroblast response to diabetes condition which was reported in a study by.[24,25] Diabetic group receiving guava leaves and Metformin showed a little deposition of collagen. This effect produced by the guava leaves extract was due to its antioxidant activity, bioactive compounds and selenium that proved to produce synergistic effects as reported by.[17,26]

CONCLUSION

The Aqueous leaf extract of *Psidium guajava* possess antihyperglycemic effect and the ability to ameliorate the damage initiated by hyperglycemia on the liver of male Wistar rats.

ACKNOWLEDGEMENTS

I appreciate Mulungushi University management for providing part of the fund used in carrying out this research.

REFERENCES

1. Luo, Y., Peng, B., Wei, W., Tian, X., Wu, Z., Antioxidant and Anti-Diabetic Activities of Polysaccharides from Guava Leaves. Molecules, 2019; 24: 1343. https://doi.org/10.3390/molecules24071343.
2. Roglic, G., World Health Organization (Eds.), Global report on diabetes. World Health Organization, Geneva, Switzerland, 2021.
3. Diagnosis and Classification of Diabetes Mellitus, Diabetes Care, 2018; 36: S67–S74. https://doi.org /10.2337/dc13-S067.
4. Bishal, G., Allesandra, F., Edwin, V.T., Per, K., 2017. Challenges in diabetes mellitus type 2 management in Nepal: a literature review, Global Health Action, 9: 1.
5. Peñalver, M., Timon, M., Collantes, S., Update on the treatment of type 2 diabetes mellitus. World J. Diabetes. PubMed, 2017; 7: 12 to 25.
6. Ojewole, J.A.O., Anti-Inflammatory and analgesic effects of Psidium guajava Linn. (myrtaceae) leaf

aqueous extracts in rats and mice. Methods Find Exp Clin Pharmacol, 2018; 28: 441.
7. Shen, S.C., Cheng, F.C., Wu, N.J., Effect of guava (Psidium guajava Linn.) leaf soluble solids on glucose metabolism in type 2 diabetic rats. Phytother Res, 2017; 22: 1458–1464.
8. Hu, X.F., Zhang, Q., Zhang, P.P., Sun, L.J., Evaluation of in vitro/in vivo anti-diabetic effects and identification of compounds. Physalis Alkekengi Fitoter, 2018; 127: 129–137.
9. Pouya, S., Petersohn, I., Salpea, P., Malanda, B., Global and regional diabetes prevalence estimates for 2019 and projections for 2030 and 2045. Results Int. Fed. Diabetes, 2019; 157.
10. Seo, J., Lee, S., Elam, M.L., Johnson, S.A., Kang, J., Arjmandi, B.H., Study to find the best extraction solvent for use with guava leaves (Psidium guajava L.) for high antioxidant efficacy [WWW Document]. URLhttps://www.researchgate.net/publication/262113212_Study_to_find_the_best_extraction_solvent_for_use_with_guava_leaves_Psidium_guajava_L_for_high_antioxidant_efficacy#read (accessed 1.12.22), 2021.
11. Yusuf, U.A., Adenowo, T.K., Adeeyo, O.A., Adegoke, A.A., Mesole, B.S., Okeniran, O.S., Neurobehavioural Study on the Effect of Aqueous Extract of Citrus medica Leaf on Prefrontal Cortex of Hyperglycemia Wistar Rats. J. Mol. Histol. Med. Physiol, 2018; 4–6.
12. Jayachandran, M., Vinayagam, R., Xu, B., Guava leaves extract ameliorates STZ induced diabetes mellitus via activation of PI3K/AKT signaling in skeletal muscle of rats. Mol. Biol. Rep., 2020; 47: 2793–2799. https://doi.org/10.1007/s11033-020-05399-2.
13. Yusuf, U.A., Sijumbila, G., Mesole, S.B., Mulemena, J.A., Kamvuma, K., Eweoya, O.O., Adenowo, T.K. Histological Study on the effect of aqueous extract of citron leaf on pancreas of hyperglycemic wistar rats. Issues Biol. Sci. Pharm. Res., 2019; 7(5): 82–90.
14. Furman, B.L., Streptozotocin-induced Diabetic Models in Mice and Rats. Curr Protoc Httpsdoi101002cpz, 2021; 178 4: 78.
15. Díaz-de-Cerio, E. Health effects of Psidium guajava L. leaves: an overview of the last decade. Int J Mol Sci., 2017.
16. Nadezda, A., Francesca, I., Aleksasandra, G., Victor, M., Mechanism of action of metformin in type 2 diabetes. Redox Biology, https://doi;10.1016 /j.redox. 2020.101517, 2020; 34: 1015–1057.
17. Masuda, T., Inaba, Y., Maekawa, T., Yamaguchi, H., Nakamoto, K., Kuninaga, H., Simple detection method of powerful antiradical compounds in the raw extract of plants and its application for the identification of antiradical plant constituents. J Agric Food ChemGoogle Sch, 2018; 1851–1858.
18. Roy, C., Kamath, J., Asad, M., Hepatoprotective activity of Psidium guajava Linn. leaf extract. Indian J Exp BiolPubMed, 2017; 44: 305–311.
19. Farag, R.S., Abdel-Latif, M.S., Abd El Baky, H.H., Tawfeek, L.S. Phytochemical screening and antioxidant activity of some medicinal plants' crude juices. Biotechnol Rep PubMed, 2020.
20. Yusuf U.A., Kafula, F., Kaimba, K., Kalipenta, W., Kabwe, H., Mulemena, A.J., Kamvuma, K.M., Phiri, S.B., Michelo, M., Bolaji, S.M., Phiri, A., Zimba, W. The Role of an Aqueous Extract of Cactus on Histopancreatic Architecture in Streptozotocin Induced Diabetes Mellitus in Wistar Rats. Eur. J. Pharm. Res., 2022; 2(2): 11-16.
21. Manikandan, R., Anand, A. Evaluation of antioxidant activity of psidium guajava Linn. In streptozotocin – induced diabetic rats. Free Radicals Antioxid, 2018; 1: 72–76.
22. Bellido, D., Goday, A., Sajoux, I. Short-Term Safety, Tolerability and Efficacy of a Very Low-Calorie-Ketogenic Diet Interventional Weight Loss Program versus Hypocaloric Diet in Patients with Type 2 Diabetes Mellitus. Nutrition & Diabetes, 2019; 6(9).
23. Yusuf, U.A., Kalipenta, W., Kaimba, K., Kafula, F., Kabwe, H., Chanda, W., Michelo, M., Phiri, S.B., Phiri, C.N., Mulemena, A.J. Cactus Extract and Anti-diabetic: hepatoprotective effect in Diabetic Wistar Rats.WJPPS, 2022; 11(7): 16-27.
24. Manaras K, Jongdee N, uraporn V, Vipavee A and Wipapan K Effect of glabridin on collagen deposition in liver and amelioration of hepatocyte destruction in diabetic rats. Experimental and Therapeutic Med, 2019; 18(2): 1164-1174. https://doi.org/10.3892/etm.2019.7664.
25. Uthman Ademola Yusuf, Musonda Kambele, Wana Iputu , Mpeza Kalowa, Michelo Miyoba, Isabel Namfukwe Luambia Luambi, Precious Simushi and Aminat Adejoke Yusuf. Histological investigation of aqueous extract of cactus on the heart of diabetic Wistar rats. GSC Biological and Pharmaceutical Sciences, 2023; 22(01): 134–142.
26. Uthman Ademola Yusuf, Mwewa Masamba, Betty Banda, Sam Beza Phiri, Michelo. Miyoba, Aminat Adejoke Yusuf, John Mulemena, Kingsley M Kamvuma, Olubukola Iyanuoluwa Ademola Maintenance of Renal integrity of Diabetic Wistar Rats treated with aqueous extract of *Psidium guajava* MUMJ., 2023; 4(1): 162-170.