

**AN INSIGHT OF THE METHODOLOGY OF CONVENTIONAL MICRO ANATOMY
TECHNIQUES**

A. Manoj* and Annamma Paul*

*Department of Anatomy, School of Medical Education-Mahatma Gandhi University, Kottayam, Kerala, India-686008.

*Corresponding Author: Dr. Manoj A.

Department of Anatomy, Government Medical College-Thrissur under Directorate of Medical Education Trivandrum of Health and Family Welfare Department, Government of Kerala, India-680596.

Article Received on 14/07/2023

Article Revised on 03/08/2023

Article Accepted on 24/08/2023

ABSTRACT

The aim of the study was Fixation of tissues in order to prevent autolysis and putrefaction, Ensure the tissue processing was adequate for excellent paraffin sections, Identification of the microscopic architecture of tissue by treating with Conventional staining and Calibration of the measurement of specimens. The samples were received and provide unique identification number, fixed in 10% Formaldehyde. On second day, tissue was transferred to the Automatic Tissue Processor (ATP) for undergoing Dehydration, Clearing, Infiltration and Impregnation with paraffin wax. On third day the impregnated tissue block was transferred to the well of L-block which containing liquid molten paraffin wax with 56°C for embedding. On fourth day the tissue containing paraffin block was subjected to section cutting until to get tissue ribbon with 10-15 cm by a Rotary Microtome. The tissue ribbon was flatten in a floatation bath and mounted on a microscope slide. The paraffin wax was de-waxed by transferring the slide to an incubator or hot plate (40° to 50°C) for 1 hour or dry overnight in the storage box. The remaining wax was de-parffinized by keeping the slide in xylene for 5 minutes. Hydration of the tissue was undergone by descending grades of alcohol of 100%, 90%,80% and 70% for 30 to 60 second each. Staining was done by dipping the slide in Haematoxylin stain for 3 to 5 minutes and wash with running tap water for 15 seconds. Differentiation of nucleus and cytoplasm was done by dipping the slide in 0.5% hydrochloric alcohol. Slide was dipped in ammonia for further blueing. Slide was washed with 95% alcohol. Counter staining was undergone by treatment with Eosin-Y for 10-60 seconds. Dehydration was by washing the slide in ascending grades of alcohol 70%, 95% and 100%. Tissue was permanently mounted on slide by adding DPX and inverted on a cover slip. Microscopic architecture of tissue was identified by compound microscope with 10X and 40X magnifications. The actual size of the specimen was calibrated by micrometry.

KEYWORDS: Fixation, Tissue processing, Paraffin sections, Microtomy, Staining by Haematoxylin &Eosin, Microscopy and Calibration.

INTRODUCTION

Histology is the study of the architecture of microscopic structure of biological cells and organization of body tissues and organs by using light, fluorescence or electron microscopes. The term is derived from the Greek "histos" meaning web or tissue, and refers to the "science of tissues". The observation of a thin slice or section of tissues, which have been previously prepared using appropriate processes called Histological techniques. Histology and Histopathology are often discussed and described together. The knowledge of understanding of normal histology is essential for histopathological interpretation. Histopathology is a branch of pathology which deals with the study of disease in a tissue section to prepare histology slides of a sample or specimen and examine them first in order to find out if the cells or tissue are healthy or diseased. Histo-

pathology Expert should also be able to inform histologists about normal variations of tissue morphology, improving in this way histo-pathological interpretations hence histology and histopathology are inter-dependent. Therefore Histo-technique is the processing of tissue, whether biopsies, larger specimen removed at surgery, or tissue from autopsy so as to enable the pathologist to study them under microscope.

The following review is intended to educate the scientific community and public for exploring the fundamental principles and procedures of microanatomy techniques. Let's see the pioneers who contributed for the development of this branch of science. Francois Bichat of France (1771-1802)^[1] was aptly described as the 'Father of Histology'. Zacharias Jansen constructed the first compound microscope in 1591 but had several optical problems.^[2] The development of the simple

microscope was credited to Anton van Leeuwenhoek who started the development of simple microscopes with single lenses but with improved magnification and resolution in 1673.^[3] In 1827, Joseph Lister corrected the spherical and chromatic aberrations observed in early microscopes.^[4] The specialty of Pathology first came into fruition in Germany in the 1800s. Johannes Muller can be called the 'Father of Histopathology in 1838.^[5] Hill John in 1770 introduced the first hand microtome to cut sections of twig.^[6] The first Microtome suitable for sectioning animal tissues was first constructed in 1848 by John Quekett^[7], whose first to decalcify tissue. The Cambridge rocker was developed in 1885 by Horace Darwin^[8] and the sledge developed by Jung in 1910.^[9] Motorized microtomes are the modern machines invented by William Caldwell 1884.^[10] Paraffin wax is the most popular medium for embedding as infiltration and support during sectioning by several researchers and its discovery has been variously attributed to Edwin Klebs-1869^[11], later Born & Sickler –1871, Giesbrecht and Butshili-1881. In 1845, Hermann Lebert reported that the microscope could be used to differentiate malignant and benign tissue by examining the cellular morphology.^[12] Carmine and Saffron were used the early dyes in the field of microscopy. Haematoxylin was reportedly first used successfully by Wilhelm von Waldeyer in 1863. By the late 1870s, Ernst Abbe had further advanced the science of microscopy with the development of apochromatic lens, substage condenser to gather light and immersion lenses.^[14] The Haematoxylin & Eosin (H&E) stain was developed in 1875 by A Wissowzky^[15], which is, gold standard in medical diagnosis. Ziel Nelson Acid fast stain was developed in 1883 by Paul Ehrlich for staining acid fast organism, mycobacteria and later it was modified by Franz Ziehl and Friedrich Neelson.^[16] Formalin, widely used for fixation of tissues today was first used in 1893^[17] by Alexander Butlerov. The modern binocular microscope was developed in 1902 by John Leonard Riddell.^[18] The Giemsa stain appeared in 1902 by Gustav Giemsa^[19] for nucleic acids and some parasites. PAS invented in 1946 by JFA MacManus^[20] for staining connective tissue, mucous, glycocalyx. Alcian blue method invented by Haddock and C Wood in 1950^[21], has been used for staining acid polysaccharides in cartilages and other similar structures. The first automated tissue processor (ATP) was made in Germany in 1909 and modified by Julius lipshaw 1971.^[22] Paraffin waxes of different melting points were made available to facilitate sectioning created by KV Reichenbach 1830.^[23] In 1839, the 1 inch by 3 slides was adopted by the Microscopical Society of London which became the global standard.^[24] In 1840, the glass cover slip was developed by the Chance Glass Company of Birmingham, England. Canada Balsam was the early mountant used in histopathology which was first used in 1835.^[25] The Coplin jar was invented by W.M.L Coplin in 1897 for pre-staining with alcohol buffer to allow slide to stand vertically. Leuchart's type embedding moulds was also introduced in same period.^[26] Tissue floatation

bath was introduced by Gaskell in 1890 for stretching, smoothening and location of sections onto glass slides. Embedding Rings were introduced by Dr. James B. McCormick in 1958^[26] for holding and identifying sample block and fit well in microtome chuck adapters. The cassettes system also invented by Dr. McCormick was introduced in 1968.^[26] Fluorescence Microscope was developed by AH Coons, Creech and Jones in 1941.^[27] Ernst Ruska and Max knoll developed the first Electron microscope with four hundred power magnification in 1931.^[28] Architecture of microanatomy of human liver documented by Manoj et al dispenses the comprehensive mastery of liver parenchyma and stroma.^[32] Manoj et al suggested manual method of microscopic calibration of tissues to determine its actual size.^[33] The afore documented reviews inspired the author for exploring the methodologies of Conventional microanatomy technique based on the study, an Architecture of the microscopic anatomy of human liver.

MATERIALS AND METHODS

The materials required for the protocol for Histotechnique has depicted in Table:1. The stock and working solution of 10% formalin, 10% Nitric acid, Ascending grades of alcohol, Potassium dichromate, Gelatin, Ascending grades of alcohol, Xylene, Molten paraffin wax, Potassium dichromate, Descending grades of alcohol, Haematoxylin, Eosin-Y, 0.5% Hydrochloric acid, Ammonia water, 95% Alcohol, Post staining dehydration by ascending grades of alcohol have been showing in Table: 2. The methodology was conducted for partial fulfilment of Post graduate degree of Anatomy during 1995-1997 at Histology laboratory of the department of Anatomy, School of Medical Education-M.G University, Kottayam, Kerala, India.

Protocol for Histology Techniques

Tissue processing was designed to remove all extractable water from the tissue, replacing with support medium that provides sufficient rigidity to enable sectioning of tissue without damage or distortion. Tissues were processed by the following protocols to obtain thin translucent sections and treated with suitable staining so as to enable the student, researcher or clinician to determine the tissue under microscope.

Protocol Day-1

Sample collection

Samples of human tissue collected by Histo-technologist at Specimen Reception Station (SRS) (Fig1.1) .It has to be dropped into 10% formalin and kept Unique identification/ Accession tags /number/codes (UIN) by entering the details with year and month of specimen in the log book / laboratory register for documenting the identity of the sample and also generates it in laboratory computer.

Preparation of Tissue

The prime aim of the preparation of tissues is by fixation and decalcification for treatment of soft tissues and

bone/calcified tissues respectively, in order to preserve the cellular structure of the tissue and prevent autolysis.

Table 1: Depicting the Materials / Consumable Required for Histotechniques.

Sr. No	Materials	Specification	Company
1	Light Microscope	Compound Monocular	Olympus CHB monocular
2	Automated Tissue Processor(ATP)	Carousal type /Tissue transfer	
3	Microtome	Rotary microtome/Minot	
4	Microtome knife and Sharpener	Steel knives/Disposable blades	
5	Paraffin wax Trimmer	Hand razor/Fine fret saw	
6	Drying Oven/Hot plate	India mart	
7	Bunsen Burner		
8	Tissue floatation bath		Labfriend India
9	Warming plate		India amart
10	Specimen collecting containers		Esticate
11	Beaker	500 ml	Indiamart
12	Pipettes	100 ml	MV Glass slides
13	Microscope slide and cover slips	25.4x76.2 mm	India mart
14	Coplin jars	Borosilicate glass	Deschem
15	Porcelain dish	75ml	India mart
16	Staining jar	60 ml	
17	Microscope slide tray	75x25mm	
18	Slide storage box/Rack		Harpel sons
19	Leukhard embedding mould	Brass	Cellpath
20	Camel haired brush	Picking Ribbon	Camel
21	Fine pointed or curved forceps	Picking tissue	EISCO
22	Diamond pencil	Marking slides	Sankalp
23	Scalpel	Surgical	India mart
24	Paraffin wax	Melting point 50° to 70°c	
25	Formaldehyde	10% Formalin	
26	Isopropyl Alcohol	99%	HUMCO
27	Xylene	Dimethyl benzene	Purechem
28	DPX	Mountant	Biolab
29	Egg Albumin	Tissue adhesive	ACS
30	Haematoxylin	Ehrlich, nuclear stain	Himedia
31	Eosin	Counter stain	ACS
32	Glacial acetic acid, Mercuric oxide, Ammonium aluminium sulphate		CDH

Fixation: It was the most important step in tissue processing in which physiochemical process involving diffusion of fixatives into the tissue by potential physical and chemical reactions. The purpose of fixation is to preserve tissue permanently in as like a state as possible. It is the first and crucial step of tissue processing which was carried out two occasions. In the first step, at the moment of collection of tissue or organ is to be preserved in fixing fluid. In the second stage once the tissue reaches the histology lab after collection, it has to be cut in bits or blocks of 3 to 5 mm thick and put it in 50 ml of 10% formaldehyde or neutral buffered formalin (NBF) within 3 to 5 hours (Table-2) (Fig.2). Ensure whether identification tag is held in the tissue containers. In some tissues 10% formalin interferes the staining properties for which neutral formalin can be used. The other fixative using for visibility of specific cellular details requires special fixatives viz. Zenker's fluid, Helly's fluid', Bouin's fluid, Schaudinn's solution, Ohlmachers solution, B5 fixative and Carnoy's - Labrumfluid.

Decalcification

In the current study decalcification was not required but for sake of understanding the procedure we were included it. It is the process of removing calcium from tissues and making suitable for section cutting. It is required for preparing sections of bone and teeth in order to facilitate cutting. Calcified tissues can be cut into 2 to 6 mm thickness by sharp knife/hacksaw. This is followed by fixation in neutral or buffered formalin. Following fixation, the tissue must be thoroughly washed and the excess fixative must be removed before specimen is subjected to decalcification. Suspend the tissue slice in 100 ml of 5% Nitric acid solution by means of a gauze bag tied with a string for one day for cancellous bone and two days for compact bone, in order to check the decalcification by mechanical or chemical tests. In mechanical test check the tissue is bending or not. In chemical test add concentrated ammonia (sp. gr 0.88) to 5ml of decalcifying fluid to check its turbidity. Presence of turbidity indicates tissue has not decalcified. If the solution is not turbid add 0.5ml of ammonium oxalate in

which turbidity is again appears indicating presence of calcium. After 5 hrs transferring the tissue to fresh decalcifying and repeat the calcium checking test. If

there is no turbidity, decalcifying fluid is free of calcium and the specimen is ready for further processing.

Table 2: Showing the Preparation of Stock solution and Working solution for Histo-Techniques.

Sr. No	Purpose	Stock solution			Double distilled water	Working Solution
		Reagent	Requirement	Mol.Wt		
1	Fixation	10% Formalin	Formalin 10 ml		90 ml	-
2	Decalcification	5% Nitric acid	Con Nitric acid 5 ml Deionized H ₂ O		95 ml	-
3	Tissue process Dehydration	80% Alcohol	80 ml		20 ml	-
		95% Alcohol	95ml		5 ml	-
		100% Alcohol	100			-
4	Tissue process Clearing	Xylene	100 ml			-
5	Tissue process Impregnation	Molten Paraffin wax	50-56°C		-	-
6	Adhesive	Pot.Dichromate Gelatin	1% 1%		500 ml 500 ml	- -
7	Pre-staining Clearing	Xylene	100 ml			-
8	Pre-staining Hydration	100% Alcohol	100		-	-
		90% Alcohol	90 ml		10 ml	-
		80% Alcohol	80 ml		20 ml	-
		70%	70 ml		70 ml	-
9	Staining	Haematoxylin	Crystals 1gm 95% alcohol 10 ml Amm. Alum 20gm Mer. Oxide 0.5 g		200 ml	-
Eosin-Y		1 gm 95% alcohol 325 ml Glacial acet. a0.4 ml		80 ml	-	
11	Post-staining Differentiation of nuclei	0.5% Hydrochloric acid	Con. Hcl 2.5 ml		500 ml	
12	Blueing	Ammonia water	28% Na 1.5 ml		500 ml	
13	Removing H ₂ O	95% Alcohol	95ml		5ml	
14	Post staining Dehydration	70%,95%, 100%	70,95, 100 ml		30,5 ml	-

Protocol of Day-2

Processing of Tissue

The basic principle of tissue processing requires the exchange of fluids using a series of solutions for a predetermined length of time in a controlled environment.

Following fixation and decalcification the tissue blocks are processed in preparation for paraffin embedding.^[11] The four major steps of tissue processing involves are Dehydration, Clearing, Infiltration and Embedding. It has to be carried out in manual or automatic tissue processing. Manual tissue procedure was tedious and requires constant attention (Fig.2). Automatic Tissue processor (ATP) was an excellent device consists of a series of 10 vats or beakers and 2 paraffin wax baths arranged in a circle with timing device(Fig.1.2) These containers hold reagents and paraffin wax. With timing lever set at zero, the machine started at about 4.30 PM. The basket with the cassettes automatically change the position and takes a bath in different reagents kept in beakers in order to accomplish dehydration, clearing and

infiltration. The final dip in the warm paraffin wax until the technician arrives in the morning at 6.30 AM. The cassettes were then opened and the tissues embedded.^[22]

1. Dehydration

It is the removal of water from aqueous fixed tissue by using increasing strength of alcohol. The tissue blocks were placed in stainless steel or plastic perforated containers called cassettes or capsules.^[26] Collect all the cassettes to be processed for the day before starting the dehydration process. During dehydration the tissues are passed through a series of progressively increasing concentrations of alcohol with one change in each concentration and a duration of one hour in each case. The duration for which tissues are kept in each strength of alcohol depends upon the size of the tissue, fixative used and type of tissue. In first and second step 80% alcohol for two times bath with one hour each duration at 4.30 pm to 6.30 pm. In third step 90% alcohol for one time bath for one hour at 6.30 pm to 7.30 pm. In fourth to sixth step 100% alcohol for three times bath with one hour each duration at 7.30 pm to 11.30 pm. Other fluids

can also be used, Methylated spirit, Methanol, Butanol and Acetone.

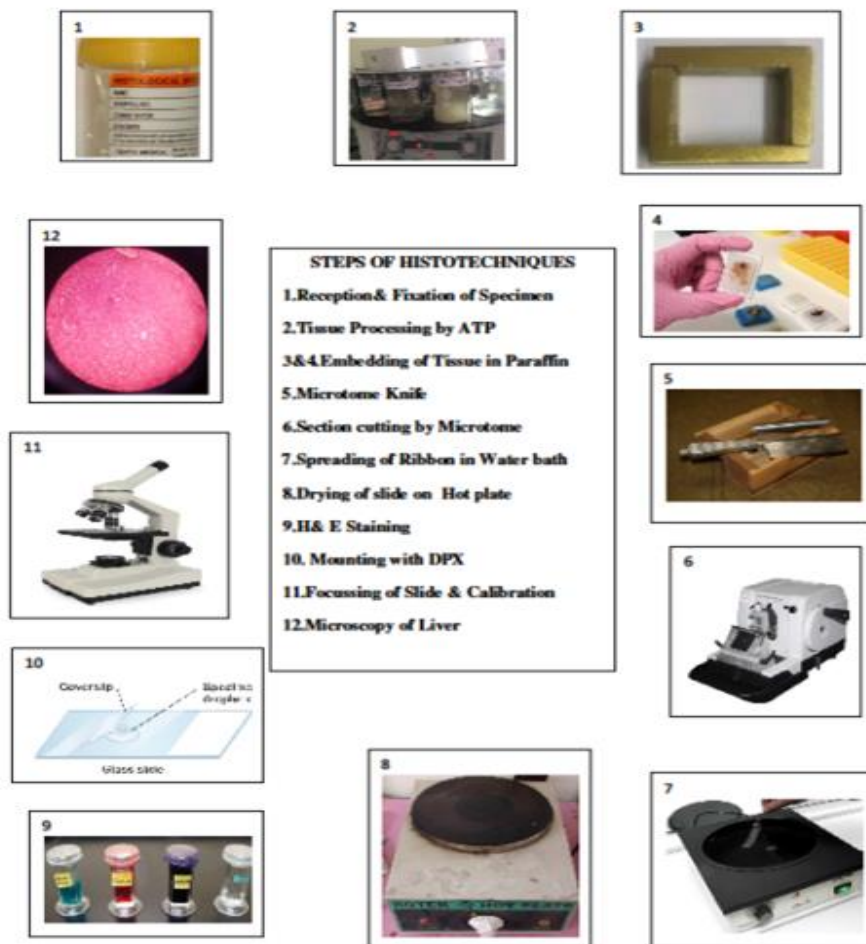


Figure 1: Exhibiting the steps of methodology of MicroAnatomy techniques.

Step-2: Clearing

Clearing is required to remove alcohol from tissues. Xylene was using as clearing agent which help to replace or clear the alcohol and makes room for the paraffin during infiltration and impregnation. Tissue blocks were cleared with xylene during 7 and 8th steps of tissue processing for two times bath with one hour each duration at 11.30 pm to 02.30 am. Other clearing agents are Toluene and Chloroform.

Step-3: Infiltration and Impregnation

The role of infiltration agent is to remove the clearing agent from the tissues and completely permeate the tissue with Paraffin wax^[11&23] in order to fill all the tissue cavities. Therefore removal of clearing agent is called impregnation and permeation of embedding medium is infiltration. This will allow the tissue to harden and produce a wax block from which thin sections can be cut. Tissues were transferred after clearing to 9 and 10 steps of tissue processing to a bath of molten paraffin wax in 50° to 60° in an embedding oven or two times bath carried out for 2 to 3 hours in automatic processor at 2.30 am to 6.30am. The temperature of the melted paraffin wax is critical if the paraffin is too hot the tissue will be

cooked and greatly distorted. The use of a vacuum impregnation oven reduces impregnation time to 15 minutes which is necessary for dense tissues.

Step-4: Embedding/ Casting /Blocking

It is the process by which the tissues or the specimens are enclosed in a mass of the embedding medium/Paraffin wax^[23] by using moulds. It is important for preserving tissue morphology and giving the tissue support during sectioning. Cassettes were removed from the paraffin wax. The plastic lid was removed from one cassette at a time. The suitable mould was chosen. Tissues were picked out from cassettes by a pair of forceps. Tissue was placed in the mould, Leukhardt (Ls) mould^[26] (Fig.1.3) consists of two L shaped strips of heavy brass or metal are arranged on a sheet of heavy metal or glass as the base which can be moved to adjust the size of the mould to the size of the specimen. Meanwhile commercially available paraffin wax^[11&23] should be filtered inside the oven through a coarse filter paper into another container. The infiltrated –impregnated tissue is transferred by snapping the base of tissue cassette into the base mould and then fill the mould with paraffin in the bottom of the cavity or the well made out by two Ls. Orient the tissue until it is lying flat or in desired position

in the desired plane by warm blunt nosed warm forceps. Then pour the melted paraffin at 56° to 58° over the tissue. The remainder paraffin wax poured over the top of the mould. Run the warm forceps around the tissue to ensure that any wax which may have solidified during the transferring from paraffin bath to the mould is

melted. Make sure that there is no air bubbles around the tissue. When the tray is filled with moulds, transfer to a refrigerator or to an icy tray to complete hardening of the paraffin for 15 to 30 minutes. Place the identification tag to the tissue is extremely important.

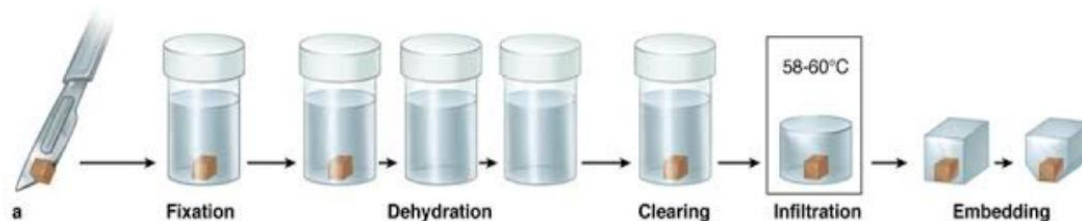


Figure 2: Exhibiting the steps of Processing of Tissue by manual method.

Protocol of Day-3

Preparation of Sections

The embedded tissues were now taken for section cutting. The basic instrument/ apparatus used for cutting paraffin sections is the Rotary Microtome (Fig.1.6) which produces thin sections of 5 to 10 μ thickness. The quality of section depends upon the quality of the knife (Plane wedge) in which the knife has to keep in perfect conditions (Fig.1.5). In order to get good quality sections the knife should be sharpened by honing and stropping. Honing entails the grinding of the edge of the knife on a special stone for sharpening the knife. Stropping is done with a leather in order to polishing an already fairly sharp edge which removes friction during honing.^[7-10]

Technique of Section Cutting

Trimming the Paraffin block

It is the removal/ shaving/ scraping of excess paraffin from tissue block. Embedded paraffin block were trimmed with a hand razor or fine fret saw to expose the whole surface of the tissue using by microtome. The block face was finally trimmed with microtome knife. The sides of the block must be parallel and the tissue should be 1 to 3 mm from the edge on all sides. The labelled trimmed blocks were stored in card board boxes.

Attachment of the Trimmed Paraffin block to the Microtome.

The trimmed paraffin block was attached to the microtome head before it is ready for cutting. For that, knife was first fixed in a clamp in which positioning of the knife edge helps in orienting the paraffin block. The paraffin block was either attached directly to the microtome head or fixed to a holder that is clamped to the microtome head. When using a Rotary microtome the paraffin block should be clamped into the head by melting the paraffin on the back of the block and fix it to the holder. Orient the tissue block appropriately before beginning to cut the block.

Cutting / Sectioning

Sectioning is the process of cutting tissue into thin slices in which the tissues is typically embedded with an

optimal cutting temperature (OCT). The orientation of the block should be such that the top and the bottom of the block are parallel and horizontal to the edge of the knife at the moment of cutting. All of the tissue desired on the slide should be exposed on the face and no scratch marks should be visible on the surface. If scratch marks are visible on the block face, the knife must be moved laterally to use a new portion of the knife edge and the face trimmed again. When the block face is trimmed and the microtome advance is set at the desired thickness for sections will be 5 μ m to 10 μ m. The centre of the blade was the most desirable place to cut. Cool the block face with an ice cube for a moment. Maintain a regular cutting rhythm at a rate that is comfortable to you. Each time the blocks hits the knife it leaves behind a cut section which will slide onto the knife, pushing the previous one ahead, thus a ribbon of section was produced (Fig.1.7). When the ribbon is about 10 to 15cm long, grasp the first section with a fine forceps held in the left hand. A small camel hair paint brush held in the right hand was used to brush away the last section from the knife and with both hands the ribbon was transferred to the water bath.^[26]

Preparing Microscope Slides

1. Using a diamond pen, label the 5 microscope slides^[25] at one end with unique identification number of tissue and numbered sequentially from 1 – 5.
2. Wash the microscope slides with soap and water, and rinse free of soap with tap water.
3. Place the slides in a coplin jar and rinse several times with distilled H₂O.
4. Handling the slides only by their edges, place the slides in your slide storage box, and allow them to dry.

Mounting of Section on a Microscope slide

In mounting float the ribbon on warm water flotation bath^[26] (Fig.1.7) maintained at a temperature of about 46° for flattening and smoothening. Pick one which was flat and fully expanded, without scratches or cracks by camel brush. An albumin coated slide is dipped obliquely into the water as close to the section as possible. If water in the water bath contains adhesive (gelatine and

potassium dichromate) an uncoated clean slide can be used. Slowly withdraw the slide allowing its surface to touch the edge of the section. Completely remove the slide with the attached section from the water. Adjust the section to a suitable position on the slide with a mounted needle. Drain off the excess water and lay the slide flat on the table. Then transfer the slide to an incubator or hot plate (40° to 50°) for at least *one hour* or to dry overnight in the storage box to ensure that the section is thoroughly dried (Fig1.8). Once all the sections are dried they are ready for staining.

Routine Staining Procedure

In routine histology laboratory, haematoxylin-eosin^[15,29-33] is the standard stain using for identification and diagnosis (Fig.1.9).

Preparation of staining

Prior to staining procedures the paraffin must be removed from the section on the slide. The following are the steps involved in the process viz. Drying, Deparaffinising, Hydration.

Drying: Carefully check that the slide is completely dry in the oven before proceeding for de-waxing or removal of the paraffin.

Deparaffinising: To remove the paraffin from the sections, take the warm slide from the oven and allow it cool to room temperature. The slide was placed in Xylene for 3 to 5 minutes and then for an additional 5 minutes in a second xylene bath which was adequately removed the paraffin from the sections. Paraffin was dissolved by agitation of the slide in xylene.

Hydration: Take the section to water through downgraded alcohol bath (100%, 90%, 80%, 70%) for 30 to 60 seconds in each. Wash in tap water and rinse in distilled water for 1 minute.

Staining by Haematoxylin

Haematoxylin (working solution) was transferred to couplin jar, the slide were stained for 3 to 5 minutes. Slide was washed in running tap water for 15 seconds. Dipped the slides in and out of 0.5% hydrochloric acid (working solution) and exam under microscope for differentiation of nuclei and cytoplasm with dark purple and very pale respectively. If the nuclei are not dark enough, rinse in distilled water and repeat the staining. Wash briefly in distilled water for 30 to 60 seconds. Dipped the slides several times in dilute ammonia (working solution) which leads to blue colour for tissue. Again wash in water and Rinse in 95% alcohol.^[15,29-33]

Bluing: Change the reddish purple haematoxylin to blue or purple blue colour by using Ammonia solutions, Tap water, Scott's solution and lithium carbonate.

Eosin staining

Eosin solution was used as a counter stain that stains the cytoplasm rose coloured.^[15,29-33] Transfer Eosin-Y (working solution) to coupling jar and agitate the slide for 10 to 60 seconds based on the age of the stain.

Dehydration: Drained the stain before going to next step by dehydration. Placed the slides in 70% and 95% alcohol for 30 to 60 second each. Placed the slide in absolute alcohol (100%) for two bath for 30 to 60 seconds each. Clear the slide with Xylene for two changes for 30 to 60 second each and drain the excess stain.^[29-33]

Mounting: In this process the sections are permanently attached to microscope slides. For conserving microscope by sandwiching the sample between a microscope slide and a glass cover slip. The slide and cover slip must be free of optical distortions to avoid viewing artifacts (Fig1.10).

1. Hold the slide between the thumb and the forefinger of one hand and wipe with a clean cloth both ends of the slides. Make sure the side of the sections/tissue is present.
2. Clean carefully around the section and lay on a clean blotting paper with section uppermost along with appropriate cover slip which has already been polished.
3. Placed a drop of mountant (Canada balsam/Xylene balsam) or Distyrene Plasticise and Xylene (DPX) on the slide over tissue.^[25&29-33] Invert the slide over the cover slip and lower it so that it just adheres to the cover slip quickly turn the slide over, then lay it on a flat surface to allow the mountant to spread. Do not press or push the slide at all which damage the section.
4. After the mountant has spread to the edge of the cover slip wipe around it for neatness. If proper care has been taken there should be no air bubbles. If many air bubbles are present, slide should be returned to the xylene to remove the cover slip. It will slip off and remounting is done. No attempt should be made to pull the cover slip. Slight warming of the slide from below will make the small air bubbles to escape from the slide of the cover slip.
5. Cover slip should be in the centre of the slide with neatly written label on one slide.

Steps to Focus Tissue under Microscope^[29-33]

To focus a slide under low (L/P) and High power (H/P) objectives (Fig1.11&12).

- Turn the low power objective 10X in position and check that all optical systems are in the same straight line.
- Illuminate the field with light by turning the mirror towards the light source.
- Clean the microscope slide with a dry cloth and make sure the cover slip surface.
- Keep the slide on the stage with the cover slip surface directs upwards. Ensure that the section is in line with the optical system.
- Slowly lower the body tube using coarse adjustment screw until the object is focused.

- For using high power, the condenser may be lifted up and the diaphragm aperture may be reduced. Now bring the section to the centre of the field and turn the nose piece so that the high power objective 40X is in line with light pathway.
- Use the fine adjustment screw for fine focusing. Never use the coarse adjustment screw while using high power, because the working distance between the slide and the objective is very little.

Calibration of Tissue by Micrometry

Calibration is the process by which to find out the actual size of the specimen in microscope slides. It requires one stage Micrometer and Ocular micrometer, apart from microscope. In order to measure the actual size of the specimen, multiply the specimen size with 25 μ m, 10 μ m and 2.5 μ m in 4X, 10X and 40X objective respectively.^[34] Take the data of the samples and record the average and analyse in an excel sheet or any software, whether any significant difference between the normal tissue and the diseased.

Observation & Discussion

The current methodology observed that the conventional histotechnique has been come up with knowledge with reference to study of the architecture of microscopic Anatomy of human liver.^[33] 10% Formaldehyde was preserved tissue permanently without altering its structural integrity. Water was the removed by dehydration in which increasing strength of alcohol, depends upon the size of tissue. Alcohol was removed from tissue by clearing with Xylene. The other clearing agents are Toluene and chloroform. Xylene was removed by impregnation and infiltration in which the cavities of the tissue was filled and permeated paraffin wax which harden and produce wax block within optimum temperature unless the tissue will be cooked and distorted. The impregnated & infiltrated tissue was solidified by embedding/casting in paraffin wax within Ls moulds. The sections were obtained in sequence which joined to form a ribbon shaped slices by using rotator microtome with 5-10 microns thickness and 10-15cm. The availability of ribbon shaped slice was depends upon the sharpness and quality of the knife and cutting of section at centre of blade with an optimum cutting temperature. Flattening and smoothening of the ribbon by keeping the ribbon in floatation bath maintained at 46° temperature. One sample needs to have 5 clean microscope slides marked with unique identification number which stored in coplin jars. Albumin coated slides were used for mounting, dried for one hour/dry overnight in storage box/ hot plate at 45°. However adhesive like gelatine and potassium chromate did not need albumin. Investigators has to know the pre-staining procedure before treatment with H&E dyes in which slide were drying on oven before deparaffinsing, agitating with Xylene was done for adequate removal, dissolution of paraffin/deparaffinsing and hydration of specimen by treating slide with descending grades of alcohol for 30-60 seconds, wash in tap water and rinse in

distilled water. Haematoxylin is basic dye which stains blue for nucleus and cytoplasm but hydrochloric acid removes blue from cytoplasm and left in nucleus only for 3-5 minutes. The reddish purple nucleus changed to blue colour by bluing with treatment of ammonia solution and tap water. Counter staining with acid dye eosin that giving's light rose shade to cytoplasm by dipping 10-60 seconds based on age of stain. H&E staining has been routinely using in histopathology divisions to examine tissues from biopsies or post-mortem specimens because it provides a clear contrast between different structures in a sample, making it easier to pathologist to identify the alterations in different types of cells and tissues. Excess stains were drained by dehydration with ascending grades of alcohol. H&E stains are preserved by using mountant DPX /Canada balsm/Xylene balsm sandwiched between slide with tissue and coverslip. Coverslip protect the tissue and stains from contamination from environment and protect the lens of the microscope from contacting specimen and also it increases resolution of microscopy. The significance of microscopy is increasing the magnification, the lens focus on the centre of the specimen in which the coarse focus knob is used to bring into the field of view using an objective with low magnification where as in fine focusing knob changes the distance very slowly and permits better viewing of the sample. Micrometry was used for calibrating the actual size of the target area of specimen/sample.^[34]

CONCLUSION

An Insight into the Conventional Micro Anatomy technique / Paraffin method being useful for gathering details of general and fine structure of tissues under microscope which attributes to know the altered state of tissues for diagnosing the pathological implications.

ACKNOWLEDGEMENT

My Gratitude to the then Vice-chancellor, Director, Teaching & nonteaching staffs of SME MG University Kottayam, Kerala, India. Though our Senior Professor of Anatomy & my mentor Dr. Annamma paul left us but her valuable suggestions and advises during my Postgraduation and working as a faculty with her still showering inspiration and motivation for writing this paper, therefore she was included as co-author.

REFERENCES

1. Bichat, Xavier (1771-180). *Auter du texte* (1812) *Traite D'Anatomie Descriptive* par Xav. Bichat Tome1/Nouvelle Edition A Paris, 1812.
2. Albert Van Helden; Sven Dupre; Rob van Gent(2010). *The origin of Telescope Amstredam* University Press. p. 25 ISBN 978-90-6984-615-6.
3. Anderson, Douglas. *Animacules*. Lens on Leeuwenhoek. Retrieved 09. 10. 2019.
4. Lister, Joseph Jackson (1858) *On the minute structure of Involuntary muscular fibre*. *Journal of Cell Science*, s1-6(21): 5-14.

5. Johannes Muller (1838). On the Nature and structural characteristics of Cancer, and those Morbid Growths.
6. Hill, John(1770). The Construction of Timber, from its Early growth, Explained by Microscope and Proven from Experiments, in a great variety of Kinds London.
7. Quekett, John Thomas(1896). Dictionnary of National Biobraphy.
8. Darwin, Horace. Philosophical Transactions of Royal Society London, 198: 235-299.
9. Jung Thomas. A modification of sliding microtome.
10. Caldwell Automatic microtome, 1882.
11. Edwin Klebs. Nature, 1935; 136: 675-676.
12. Hermann Lebert. A pioneer of Diagnostic Pathology. Virchows Arch Germany, 455(3): 301-5.
13. Wilhelm Von Waldeyer, A great forefather. His Contributions to Anatomy with Particular attention to his Fascia. Front Surg, 4: 74.
14. Ernst Abbe, (1873). About a new Illumination Apparatus to the Microscope. Bonn Germany: Verlag von max cohen & sohn, 9: 469-480.
15. Wittekind D (2003). Traditional staining for routine diagnostic pathology including the role of tannic acid. Value and limitations of hematoxylin –eosin stain Biotech Histochem, 78(5): 261-70.
16. Acid-Fast stain –Principle, Procedure, Interpretation and Examples. May 8, 2015 by Sagar Aryal.
17. Fox CH, Johnson FB, Whiting J, Roller PP. Formaldehyde fixation. J Histochem Cytochem, 1985; 33: 845-53.
18. Riddell JL(1854). On the binocular microscope. QJ Microsc Sci, 2: 18-24.
19. Giemsa G (1904 Eine Vereinfachung und Vervollkommnung meiner Methylenbalu-Eosin-Farbemethode zur Erzielung der Romanoswsky-Nochtschen Chromatin farbung. Centralbaltt fur Bacteriologie/Abteilung, 32: 307-313.
20. McManus, JFA : Stain Tech, 23 99 (1948).
21. Hayat MA (31 March 1993). Stains and Cytochemical Methods. Springer Science & Business Media. ISBN 9780306442940.
22. Winsor L. Tissue processing. In Woods A and Ellis R eds. Laboratory histopathology. New York: Churchil Livingstone, 1994; 4. 2-1-4. 2-39.
23. Fixation of Tissue Processing in Immunochemistry. DG Baskin, in Pathology of Human Disease 2014b3797-3806.
24. Transactions of Microscopical Society of London. John Van Voorst, 1844-66.
25. Barcigridle, Brain. The development of biological preparative techniques for light microscopy, 1839.
26. Histopathologic Techniques. Jocelyn H. Bruce-Gregorios. 86-87 Second Edition. Goodwill Trading Co., INC. 388 Quezon city; ISBN: 971-12-0270-0.
27. Coons AH, Crrech HJ, Jones RN. Immunological properties of an antibody containing a fluorescent group. Proc Soc Exp Biol Med, 1941; 47: 200-202.
28. Hawkes, Peter W(1990-07-01). Ernst Ruska. Physics Today, 43(7): 84-85.
29. Bancroft JD, Gamble M. Theory and Praticce of Histological Techniques. 6th ed. Philadelphia, PA: Churchil Livingstone/Elsevier, 2008.
30. Carson FL, Histopathology A self Instructional Text 2nd Ed., ASCP Press, Chicago IL 1990.
31. Luna, Histopathologic Methods and Colour Atlas of Special Stains and Tissues Artifacts. American Histlabs, Inc., Gaithersbrug, MD, 1992.
32. Sheehan, Dezna and Hrapchak, B. Theory and Practice of Histotechnology2nd Ed. , Battelle Press, Ohio, 1980.
33. A. Manoj, Annamma Paul.An Architecture of Microscopic Anatomy of Human liver. wjpmr, 2019,5(5), 101-105
34. Manoj A, B. Vishnu Bhat, C. Venkatesh, Z. Bobby. Manual calibrations of Comet tail by Using Micrometry.