

CLINICAL CASE STUDY OF KSHARSUTRA LIGATION IN THE MANAGEMENT OF 3RD DEGREE HEMORRHOID**Dr. Vivek Kumar Tiwari¹, Dr. Rajendra Kumar Dixit² and Dr. Poorvi Pachouri^{*3}**¹Asst. Prof., ²Asst. Prof., ³P.G. Scholar

Dept. of Shalya Tantra, Rani Dullaiya Smriti Ayurved P.G. College and Hospital, Bhopal.

***Corresponding Author: Dr. Poorvi Pachouri**

P.G. Scholar, Dept. of Shalya Tantra, Rani Dullaiya Smriti Ayurved P.G. College and Hospital, Bhopal.

Article Received on 01/06/2023

Article Revised on 21/06/2023

Article Accepted on 11/07/2023

ABSTRACT

Ayurveda, originating from ancient India, is a holistic system of medicine that encompasses a profound understanding of the human body, mind & spirit. *Shalya Tantra* is one of eight limbs of *Ayurveda*.^[1] *Acharya Sushruta* is the father of Surgery. *Sushruta Samhita* is one of the three *Brahattrayi* texts of classical *Ayurveda* and is the chief treatise of its surgical school i.e. *Dhanvantari sampradaya* founded by *Dhanvantari*.^[2] *Ksharasutra* therapy is a minimal invasive *Ayurvedic* para -surgical procedure and time-tested *Ayurvedic* technique in management of Anorectal disorder's. *Ksharasutra* treatment is absolutely effective, safe and affordable. This therapy described in *Ayurveda* by *Acharya Sushruta*, *Charak* and *Vagbhata*.

KEYWORDS: *Ksharasutra*, *Shalya Tantra*, *Sushruta*.**INTRODUCTION**

In *Ayurveda Arsha* [Hemorrhoid] is considered under the *Astamahagad* due to difficult to cure. It is manifested due to improper diet, prolonged standing and faulty habits of defecation causing disarrangement of *Tridosha* mainly *vata dosha*. Acc to modern- Hemorrhoid is dilated plexus of superior haemorrhoidal vein in the relation to anal canal characterized by bleeding per rectum constipation, pain, prolapse and discharge.^[3] Type Acc to tendency- 1st degree – only bleeds no protrusion. 2nd degree- protrude during defecation, goes automatically. 3rd degree- protrude and replaced manually. 4th degree- protrude rather than defecation as coughing, sneezing, and laughing and remains outside the anal verge.^[4] In *Ayurveda Arsha* treated with 4 measure's 1- *Aushadha*, 2- *Kshara*, 3- *Agni*, 4 – *Shastra*.^[5] In this study a case of 3rd degree hemorrhoid at 3, 7, 11 o'clock position of anus was treated by *Ksharasutra* ligation. *Ksharasutra* is prepared using a plant based alkaloid. *Ksharasutra* is prepared by repeated coating of *snuhi ksheer*, *Apamarga kshara* and *Haridra churna*. *Snuhi ksheer* = 11times. *Snuhi ksheer* + *Apamarga Kshara* = 7 times. *Snuhi ksheer* + *Haridra churna* = 3 times. Total 21 coating was done in surgical linen thread 20 no.^[6]

CASE REPORT

A 25-year-old patient presented to Shalya Tantra OPD, RD MEMORIAL P.G. COLLEGE AND HOSPITAL, BHOPAL having complaints of pain during and after

defecation for past 3 years, constipation, and protrusion through the rectum during defecation for 1.5 years. Patient had grade 3 haemorrhoids at 3, 7 and 11 o'clock with a sentinel tag at 6 o'clock position of anal canal. All Pile masses were treated by *Ksharasutra* ligation under local anaesthesia without any complications. A postoperative evaluation was performed. Observation of the patient's signs and symptoms daily to see the extent of remission. The ligated pile masses were cut until the 8th postoperative day and the wound healed after 21 days.

Examination

On Inspection: Sentinel tag at - 6 o'clock
Position: Internal pile at - 3, 7, 11 o'clock position

Aim and Objective

To evaluate the effect of *Apamarga Ksharasutra* ligation on 3rd degree hemorrhoid.

Surgery Plan

The patient was admitted to RD MEMORIAL AYURVEDA P.G. COLLEGE AND HOSPITAL where he underwent the following treatment

1. Laboratory test- blood and urine test including BT, CT, CBC, Blood urea, fasting blood glucose, HIV, HbsAg1.
2. Instrument's- Mosquito forceps, Pile holding forceps, scissors, towel clamp, Allis forceps, Artery forceps, syringe, Sponge holding forceps, thread, suturing needle should be placed ready on a trolley.

Pre-Operative Plan

1. Patient NBM before 6 hrs of surgery
2. Injection xylocaine sensitivity 2% .1ml ID was performed.
3. Injection T.T .5ml was given.
4. Enema was given.
5. Painting and draping of the surgical area.
6. Consent of the patient and his attender was taken before the procedure.

Operative Procedure

The patient lies in the lithotomy position. Painting of anus and peri-anal area with sterile and antiseptic solution is done. Followed by aseptic draping. Under local anesthesia all internal pile masses was hold by pile holding forceps and trans fixation and ligation of internal pile masses at 3, 7 and 11 o'clock position. one sentinel tag at 6 o'clock position was ligated and excised. Dressing was done and patient was shifted to recovery room with stable vitals.

Post Operative Procedure

1. Hot sitz bath with *Triphala Kwath* to relax the sphincter and wound cleaning was advised.

2. Syp. livomyn 2 tsf BD
3. *Triphala Gugullu* 2 BD
4. *Matra Basti* with *Jatyadi Tail*
5. *Nagkesar Churna* 3gm BD
6. *Erand bhrith haritaki Churna* 5gm HS

By 8th post-operative day, ligated pile masses were sloughed out.

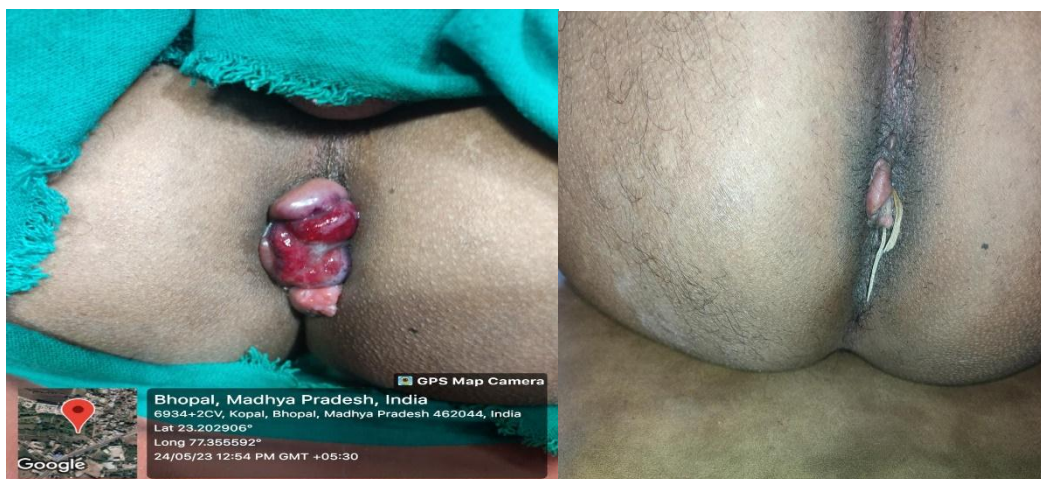
By the end of 21th post-operative day all wound were observed healed and there was no complication.

Diet

Daliya, Daal, green-vegetables, fruits and plenty of water Patient was also advised to avoid junk food, non-veg, spicy food.

OBSERVATION AND RESULT

Complete recovery of the wound took place in about 21 days. The *Ksharasutra* ligation in 3rd degree hemorrhoid was applied with successful treatment without any complication.

**DISCUSSION**

In contemporary science there are many treatment option for piles like cryosurgery, sclerosant injection therapy, rubber band ligation and hemorrhoidectomy etc. There treatment modalities have their own limitations in respect of post-operative complication like hemorrhage, delayed bleeding, pain etc. In comparison to these treatments *KSHARASUTRA* LIGATION therapy is said to be best as it has minimum complication.

In this case there was no any post-operative complication after *Ksharasutra* ligation.

In this study *Ksharasutra* was applied under local anesthesia and it was dislodge by 8th post-operative day. The applied *Kshara* on thread act's as anti-inflammatory, anti-microbial property and chemical cauterization which promotes healing process after sloughing out of pile

masses. *Hridra Churna* which is present in *Ksharasutra* helped for healing process. All drug are best formulation for cutting of pile masses as well as healing of resulting wound.

CONCLUSION

This case demonstrated that 3rd degree hemorrhoid can be treated with *KSHARASUTRA* LIGATION THERAPY without any complication.

Besides this very minimum recurrence rate and no side effect occur during this case study and this procedure can be practiced safely.

REFERENCES

1. Ambika Dutt Shastri, Shusrut Samhita Vol.1, Chaukhamba Prakashan, Varanasi.

2. Prof. G.D. Singhal, Shusrut Samhita, Ancient Indian Surgery, Chowkhamba Surbharati Prakashan Part 2, 2015.
3. K Rajgopal Shenoy Anita Nileshwar, Manipal Manual of Surgery, v-2, 6th edition.
4. Vaidya Anantrao Shekokar Shalya Tantra Part 2, Shantanu Prakashan, 2014.
5. Anantram Sharma, Sushruta Samhita Part-2 Chokhamba Prakashan, Vanarasi. 1St edition, 2004.
6. Vaidya Anantrao Shekokar Shalya TantraPart-2, Shantanu Prakashan, 2014.